

ROENTGENOLOGIC STUDIES OF THE ORIGIN AND
DEVELOPMENT OF JUVENILE KYPHOSIS, TOGETHER
WITH SOME INVESTIGATIONS CONCERNING THE
VERTEBRAL EPIPHYSES IN MAN AND IN ANIMALS

BY
H. SCHEUERMANN,
Copenhagen

In the large literature on curvatures of the spine most of the attention has always been given to scoliosis, because a fixed lateral curvature is an abnormality, while the difference between the merely kyphotic posture and the actual, fixed, abnormal kyphosis is only a matter of degree.

The *kyphotic posture*—the rounded back— is so common that in its milder degrees it cannot be considered as an abnormality. Just as it is impossible to define exactly what constitutes the »normal« posture, as distinguished from either flat or rounded back, so is it difficult in the individual case to show the existence of that abnormal kyphotic posture which depends on various conditions of race, heredity or the age of the subject.

As abnormal we may however consider the rounded back which is unable to straighten itself so much that the thoracic portion of the spine does form an unhandsome, arched convex.

We distinguish between the following forms:

- 1) *congenital* kyphosis, which is rare;
- 2) *degenerative* kyphosis, which in some imbecile individuals is characteristic by the strong fixation;
- 3) *rachitic* kyphosis in small children;
- 4) *the kyphotic posture*,—the slackly rounded back, which usually disappears after the school-age;
- 5) *occupational* kyphosis (= *kyphosis juvenilis*);
- 6) *senile* kyphosis.

The terms occupational kyphosis, apprentice's kyphosis and muscular kyphosis, or occupational stoop, were introduced into the literature by *Schanz*, in 1907.¹⁾ Several authors agree with his views and accept the term: *insufficiencia vertebræ*, which occurs again and again in his writings, and by which he understands a feeling of fatigue in the back, pains in the same region, radiating downwards into the sides or the legs, pains in the head and tenderness of the spinal processes; all of which he ascribes to abnormal distribution of pressure. In a paper published in 1913,¹⁾ his pupil *Elsner* deals at length with the same question. From among a material of 187 patients with deformities of the back he was able to pick out 29 cases of the character described, of whom he reproduces pictures, and whose sick-journals he publishes. Most of the twenty-nine belonged to the working class, and were young people who, by the time they had finished going to school, at the age of from fifteen to nineteen years, showed—in many cases even considerable—deformities, just at the period when great demands began to be made on the strength of their backs. Some of them declared that their deformity had developed more or less recently, a lesser number stated that although they had had a slight curvature from infancy or since their early school-days, the deviation had been getting more pronounced since they had begun to be engaged in bodily work.

While *Schanz* thus deserves the credit for having called attention to the occupational, or apprentice's, deformities, his theory of the muscular kyphosis as being due to the muscles of the back becoming slack or losing their strength through over-fatigue has proved incorrect. As a matter of fact, the musculature of the back is very powerful in most of these patients, and the cause of the kyphosis must be sought in the spine, as I demonstrated roentgenologically already in 1920.²⁾ The term:

¹⁾ Eine typische Erkrankung der Wirbelsäule. Berl. klin. Wochenschr. no. 31, 1907.

¹⁾ Zeitschr. f. orthop. Chir. vol. XXXII, 1913; p. 277.

²⁾ Ugeskr. f. Læger no. 12, 1920; p. 385. (Zeitschr. f. orthop. Chir. vol. CLIII, 1928; p. 35.)

juvenile kyphosis I must limit to denote only those forms of kyphosis, originating in late childhood, in which there clinically exists a rigid, arcuate, backward curvature, and, at the same time, roentgenologically demonstrable changes in the bodies of the vertebræ. Those changes consist in irregularities of the margins of the latter, opposite the intervertebral discs, and result in a more or less cuneiform shape. At the time, I believed that they must be due to a developmental disease in the annular epiphysis, but after *Schmorl's*¹⁾ investigations have shown that the zone from which the growth of the vertebræ takes place lies on the side of the cartilage plate facing the corpus I rather think that the cause must be sought there. Since the publication of my communication, in 1920, the question has engaged the attention of several authors, immensely aided by the appearance, just above that time, of that new device, the *secondary diaphragm*, which has made it possible to obtain far better roentgenographs. In my first investigations I had to use a tube diaphragm, and therefore could get in only four or five vertebræ on each film.

The first studies published on these diseases of the back were a series of articles by *Hahn* and *Mau*, in 1923—1925. After them, several other German authors took up the investigations, notably *Schmorl* and his pupils. *Schmorl* began a systematic collection of material already in 1925, and by the time of his death, in 1932, had examined not less than 8000 vertebral columns. Though the subject has not yet been fully cleared up, the excellent contributions toward the solution of its problems that have appeared in the years between 1925 and 1933 have brought the matter a great step forward. In France, where the disease is termed: *épiphysite vertébrale de croissance*, it has engaged the attention of *Lance*, *Sorrel*, *Delahaye*, *Mathieu*, *Mouchet* and *Roederer*, *Calvé* and *Galland*, and others; in America it has been studied by *Levin*, *Christie* and *Boorstein*; in Holland by *Timmer*; in Russia by several authors; in Italy by *Zuco*, *Galeazzi* and *Valtancoli*; in Sweden it has been the subject of several im-

¹⁾ Arch. f. klin. Chir. vol. CLIII, 1928; p. 35.

portant publications by *Robert Hanson*; and in recent years it has been constantly written about, for instance at length in the *American Journal of Roentgenology and Radium Therapy* for 1926.

It is however still a matter for discussion whether the affection should be regarded as a developmental disease or not. Its etiology is not known, and its pathogenesis only partly understood. As regards the etiology, we are still unable to trace the primary cause; of the pathogenesis we feel that we understand something more, as it can be followed by means of the roentgenographs and the microscope. By the results of the investigations recorded in the following pages I hope I may be able to contribute something to the better understanding of the pathogenesis and development of the disease, as those results are based on several years' observation in all the cases.

Eighteen Cases of Juvenile Kyphosis.

All the cases have been followed up for several years, both clinically and roentgenologically. In those where it was found impossible, for some reason or other, to get the patient to come to me for examination, he—or she—has been roentgenographed at the nearest county hospital, and he, or his physician, has answered a series of questions on a card sent for the purpose.

Originally, I intended to have the examinations made every six months, but this proved impracticable, because these patients, who do not feel sick, did not show up in spite of requests to do so. I found, however, that it was possible to form a clear idea of the development of the process, nevertheless. In the cases where I succeeded in getting the roentgenographs every six months the differences between these were namely so slight that I realised that there was no necessity, after all, for such frequent examinations, and that information obtained at intervals of from one to two years was sufficient to give an idea of how the final appearance and shape of the vertebræ would turn out. All the patients came from the *Cripples' Hospital in Copenhagen*, to whose senior surgeon, Dr. *Guildal*, I am indebted for the loan of the journals.

Sex: Of the patients examined, 13 were boys, 5 girls.

Age: At the time of first examination, 9 to 18 years.

Boys:			Girls:		
9 years old	1	14 years old	1
13 » »	1	15 » »	1
14 » »	2	17 » »	2
15 » »	3	18 » »	1
16 » »	5			—
17 » »	1			5
		13			

Time of first clinical Manifestation.

As earlier investigations have shown, this form of kyphosis is much more frequent in boys than in girls. In boys, the age at which it oftenest manifests itself, or causes the patient to consult a doctor, is the fifteenth or sixteenth year. As regards the girls, the figures are more casual, and too small to yield any information.

The kyphosis rarely develops in the course of a few months. As a rule, there goes from six months to a year before the patient decides to consult a physician because his surroundings have noticed the curvature of his back, and have realised that it is getting worse. If we look through the journals, we find the statements in regard to the *time* during which *the development of the curvature* had been observed in our cases to be as follows:

Case No.

- I—6 months.
- II 3 years.
- III about 3 months.
- IV 6 months.
- V ?—Stated to have been roundbacked since the age of 6 years.
- VI 6 months.
- VII 1 month?
- VIII 1 year.
- IX 2 years.
- X 2 »
- XI several years.
- XII 1 year.
- XIII 18 months.

TAB

Case No.	Journal No.	Sex	Age	Physique	Occupation	Fatigue, Pain	Tenderness	Lateral deviation	Fixation	Length of time observed	Vertebrae altered
I	2817/28	♂	16	tall, str.ly built	page boy	at first rather much, after the kyphoses began to develop, moderate	none	none	at first none, later strong	4 years (5 times roentgenographed)	9th-11th thoracic
II	2477/28	♂	15	tall, str.ly built	farm boy	at first fatigue in back, in the course of 2 years pain when working	none	none	some, from the first	3½ years (4 roentgenographs)	10th-12th thoracic
III	1823/28	♂	16	str.ly built	plumber's apprentice	at first none, a year later some pain when working, later again none	none	none	from the first	3½ years (3 roentgenographs)	7th-9th thoracic
IV	1224/28	♂	14	str.ly built	school boy	some pain and fatigue, which gradually disappear	none	slight dext. lumbar scoliosis, owing to right leg being about 1 cm short. than left.	at first longkyphosis, not fixed, increasing in the course of 6 months	3½ years (2 roentgenographs)	9th thoracic

Position of limbic nuclei	Shape of limbic nuclei	Lasting wedge-sh. of verteb.	Contour of vertebral marg.	Nucleus prolapses	Hook-shaped proj. anteriorly	Transition from normal to pathological shape in the roentgenographs
at first nearly normal later close to corpora	only irregular at caudal corners of 10th and 11th thoracic v.	yes	some-what irregular	a few minor ones, at inferior contour of 11th thoracic	none	Almost imperceptible transition; relatively slight roentgenol. changes, but in the end typical wedge-shape. Clinically pronounced deformity.
at first nearly normal, later close corpora	normal step-formations	yes	some-what irregular	one, the size of a pea, at anterior contours of 9th thoracic v. first seen during second year of observat. less dist. in last roentgenogr.	on 11th thoracic	Some wedge shape already in the first-picture, somewhat more pronounced in the following ones. Clinically, strong kyphosis
normal	those in the 7th-9th t. v. indistinct and feebly developed, those of the normal vertebræ below than strongly develop.	yes, the 9th thoracic v. some-what wedge-shaped	some-what irregular	small nucleus prolapses barely the size of a pea, at anterior contour of 9th thoracic	on 7th and 8th thoracic v.	Vertebræ rather markedly wedge-shaped already in the first picture, even more strongly accentuated in the following ones. Clinically, strong kyphosis.
pressed into the deep indentation anteriorly and inferiorly	much enlarged, some-what irregular	yes, 9th thoracic v. some-what wedge-shaped	some-what irregular	a slight one posteriorly at interior contour of 8th thoracic	none	9th thoracic v. greatly altered, but no fixation.

TABLE I.

Case No.	Journal No.	Sex	Age	Physique	Occupation	Fatigue, Pain	Tenderness	Lateral deviation	Fixation	Length of time observed	Vertebrae altered
V	1984/27	♀	14	str.ly built	house servant	none	none	none	from the first increasing during the first year	2 years (2 roentgenographs)	9th-11th thoracic
VI	421/29	♂	14	asthenic	farm boy	yes	none	none	some from the first, increasing later	3 $\frac{1}{2}$ year (2 roentgenographs)	at first examination normal condition later changes in 8th-12th thoracic v.
VII	1804/29	♂	16	tall, slender, lean build	farm boy	only for a month past.	none	none	from the first	3 years (4 roentgenographs)	8th and 9th thoracic
VIII	2591/29	♂	15	tall, str.ly built	school boy	fatigue	none	none	at first none	3 years (2 roentgenographs)	8th-12th thoracic
IX	3111/30	♂	15	str.ly built	farm boy	none	none	none	from the first	15 months (2 roentgenographs)	9th-11th thoracic

(cont.)

Position of limbic nuclei	Shape of limbic nuclei	Lasting wedge-sh. of verteb.	Contour of vertebrae marg.	Nucleus prolapses	Hook-shaped proj. anteriorly	Transition from normal to pathological shape in the roentgenographs
close to corpora, do not extend all the way to anterior borders. Step-formation	very irregular	yes	very irregular	none	none	vertebrae considerably wedge-shaped from the first. Pronounced kyphosis.
at first normal, later close to corpora	normal, but present only in 11th thoracic v. and the adjoining one above it. Later irregular	yes	somewhat irregular	none	none	vertebrae normal at first examination, later typical wedge-shape and strong kyphosis.
close to corpora do not extend all the way anteriorly	normal	yes	very irregular	none	none	Vertebrae wedge-shaped from the first, and remain so without change.
in step-formed depressions, those of the 8th and 9th thoracic close to corpora	large, irregular	yes, to some extent	very irregular	large, prolapses in inferior contour of 8th-12th thoracic	none	At first long, even not rigid kyphosis, which gradually becomes fixed, but without greater accentuation of the curvature. In others words, only slight aggravation of the condition.
from the first rather close to corpora later closer yet	normal	yes	sl.ly irregular	2 minor ones posteriorly at inferior margins, of 10th and 11th thoracic	none	At first, the changes are slight, the vertebrae being slightly wedge-shaped, later there is somewhat greater rigidity.

TABLE 1

Case No.	Journal No.	Sex	Age	Physique	Occupation	Fatigue, Pain	Tenderness	Lateral deviation	Fixation	Length of time observed	Vertebrae altered
X	2991/30	♀	17	tall, str.ly built	farmer's daughter, much house and farm work	fatigue	none	none	some	2 $\frac{1}{4}$ years (3 roentgenographs)	11th and 12th thoracic and 1st lumbar
XI	79/31	♀	18	strong build good health	house-painter's daughter	yes	none	left lumbar scoliosis to 1.5 cm shortening of left leg.	strong from the first	16 months (2 roentgenographs)	9th-11th thoracic
XII	64/31	♂	17	str.ly built	mes-senger	yes	none	none	from the first	1 year (2 roentgenographs)	9th-12th thoracic
XIII	486/31	♂	16	tall, str.ly built	farm boy	yes	none	none	strong from the first	2 years (3 roentgenographs)	8th-10th thoracic
XIV	63/31	♂	13	str.ly built	milkman's assistant	none	none	none	some from the first, later strongly	2 years (3 roentgenographs)	9th thoracic
XV	2698/28	♂	16	str.ly built	farm by	at first fatigue later pain	none	none	strong from the first	4 $\frac{1}{2}$ years (2 roentgenographs)	11th and 12th thoracic

(cont.)

Position of limbic nuclei	Shape of limbic nuclei	Lasting wedge-sh. of verteb.	Contour of vertebral marg.	Nucleus prolapses	Hook-shaped proj. anteriorly	Transition from normal to pathological shape in the roentgenographs
no nuclei on diseased vertebrae, later placed close to corpora, somewhat backw.	at first no nuclei later very feeble ones	yes, very marked	irregular	a small one at inferior border of 11th und 12th thoracic	slight	Changes pronounced from the first, somewhat more marked later.
close to corpora, do not extend all the way forward	rather irregular, smaller than the others	yes	yes	none	yes	Changes from the first, later slightly more pronounced.
at anterior margin, but pressed close to corpora	rather regular	yes	rather strong irregularity	yes, at inferior margin of all 4 vertebrae	none	Changes from the first, kyphosis increased.
not extending all the way, anteriorly pressed close to corpora	rather regular	yes	irregular	none	slight	Changes at first slight, later somewhat more pronounced. Clinically, dome-shaped kyphosis. Some disproportion between wedge-shape and deformity.
close to corpus	larger than the others	yes	slightly irregular	none	none	Change involves only 1 vertebra, yet results in marked kyphosis.
pressed close to corpus, lacking on 12th thoracic	small	yes	irregular	one at inferior margin of 10th thoracic, and one at superior margin of 12th thoracic	none	Wedge-shape, present to some extent from the first, gradually becomes very pronounced. Strong kyphosis. Aggravation.

TABLE I

Case No.	Journal No.	Sex	Age	Physique	Occupation	Fatigue, Pain	Tenderness	Lateral deviation	Fixation	Length of time observed	Vertebrae altered
XVI	1854/26	♀	15	slender build	domestic work	none	none	slight (thoracic dex., lumbar sin.)	from the first some later stronger	5 years (4 roentgenographs)	8th thoracic
XVII	1346/26	♀	15	tall, str. ly built	domestic	none	none	none	from the first	3 $\frac{1}{2}$ years (3 roentgenographs)	10th and 11th thoracic
XVIII	2926/28	♂	9	fairly strong build	school boy	none	none	none	from the first	4 years (5 roentgenographs)	9th and 10th, later 8th-10th thoracic

XIV 2 years.

XV 6 months.

XVI 1 year.

XVII several years.

XVIII ?

Thus, the time during which the kyphosis is stated to have developed was:

in 1 case 1 month.

1 » 3 months.

4 cases 6 »

4 » 1 year.

4 » 2 years.

2 » several years.

2 » ?

According to the information elicited,—which must always be accepted with reservation, however, as the first observation

(cont.)

Position of limbic nuclei	Shape of limbic nuclei	Lasting wedge-sh. of verteb.	Contour of verte-br. marg.	Nucleus prolapses	Hook-sha-ped proj. anteriorly	Transition from normal to pathological shape in the roentgenographs
not isible	not visible	yes	irregular	at inferior margins of 8th-12th thoracic	none	Wedge-shape from the first, no particular aggravation. Condition more or less unchanged since first examination.
incipient fusion	incipient fusion, rather regular	yes	irregular	3 at inferior margins of 9th-11th thoracic	between 9th-11th thoracic	Wedge-shape from the first, no change afterwards, medium strong kyphosis.
not visible at first, large step-formation	irregular	yes, und. but edly, but proc. of ossific. not yet terminated	very irregular	none	none	Unusual carc.-kyphosis somewhat rigid from the first. Large step-formed depression in 9th thoracic v., which takes a long time in ossifying. Some aggravation. Medium degree kyphosis.

of the condition often happens more or less incidentally,—the age at which *the kyphosis began* was:

<i>Boys:</i>		<i>Girls:</i>	
at the age of	9 years	at the age of	5—6 years
	1 (?)
	11 »	13 »	... 1
	12 »	15 »	... 1
	13 »	? »	... 2
	14 »		—
	15 »		5
	16 »		

In most of the boys it thus began at the age of from fourteen to sixteen years.

The most important is however to be able to ascertain the time at which fixation occurs; that is, when the condition chan-

ges from that of simple kyphotic posture to actual, fixed kyphosis; but this is very difficult, because the change takes place gradually. The best way to ascertain an incipient fixation is perhaps to have the boy bend forward with his arms raised straight above his head. As the Danish State Director of Physical Culture, Mr. *Knudsen*, has shown, this will often enable one to see that at a certain point the spine is for a short distance fixed, either straight or slightly kyphotic. In most individuals, this condition will persist without any change; only in the minority of cases does it develop into actual kyphosis, with cuneiform vertebræ.

Commencement of Changes in the Vertebræ.

To me there is no doubt but that the beginning of the changes in the vertebræ in most instances coincides with the formation of the *limbus vertebralis*. The changes show themselves in the fact that the calcification of the cartilage, which normally begins at the place where the final contour of the vertebral body is to be, begins farther back, close to the contour of the body, as we shall see in the following, when we come to speak of the development of the kyphosis. The difficulty, however, of demonstrating in what cases the changes are abnormal lies also in the fact that it is not always easy, while those changes are yet in the initial stage, to decide whether, in the given case, they are merely a matter of anomalous development which will gradually correct itself, or of permanent, pathologic change. I have succeeded in finding, and have followed up for several years, five such borderline cases between the normal and abnormal. I shall discuss these later on, after dealing with the pathologic forms, because I believe that thus the difference in their development will be more clearly realised.

As we know, the period at which the formation of the *limbus* takes place is liable to great individual variation. In some cases the development may be at a standstill for several years, while in others it proceeds so rapidly that the picture changes considerably within a year. This is associated with the growth of the individual during the period of puberty, and during that

period we will now see whether the development takes a normal or an abnormal course.

Build.—Most of these young people were strongly built. Of the thirteen boys, only two were thin and poorly developed; the others were robust, several of them even tall and big. Also the five girls were physically strong.

Occupation.—Of the boys, 6 were in agricultural service, 3 school boys, 1 baker's apprentice, 1 page boy, 1 messenger, 1 milkman's assistant. Of the girls, 2 were servant girls, 3 did domestic work at home. The category of boys in whom the affection is oftenest met with are those engaged in farm work; it is therefore natural to conclude that the heavy tasks which that occupation involves may have had something to do with their condition. On the other hand, we see that among my patients there were three school boys, and these all declared that they had never done any heavy physical work.

Familial disposition.—As regards my case no. IX it was stated that his father and four paternal uncles had been round-backed since their youth, in the same manner as the patient. No. XVII and no. XVIII were brother and sister; in them both the kyphosis was slight. In none of the other cases was there any information that might point to heredity as a factor in the development of the disease; nor have I, in reading through a great number of journals, found anything that might support a theory to that effect.

Pain. Fatigue.—These are symptoms that accompany the development of the kyphosis. As a rule, the two sensations cannot be dissociated; perhaps they might be better spoken of as one symptom,—*painful fatigue*. The appearance of this does not always coincide with the time when the kyphosis first becomes manifest; in many cases it does not come on until six months or a year later, and may then disappear again, or be experienced only after some strong bodily exertion. It is mostly felt only when the patient is standing, and disappears when he lies down; though sometimes it may persist for some time even after he has gone to bed. Of the fifteen boys, ten were subject to such pains, of the five girls only one. In my after-examinations I have

ascertained that *in severe cases these pains may persist in later life*. The individual statements on this point differed somewhat, however, and should perhaps not be altogether relied upon, as the mind of several of these patients had already begun to dwell on the idea of possible invalidity,—and the chances of indemnity for such. Also after the attainment of full growth heavy work can in some individuals give rise to pains in the back and make it impossible for the person thus afflicted to keep pace with his workfellows; but in no such case will the deformity be so great as to reduce his capacity for work by one-third. In none of the cases was there any *tenderness of the spine*, either subjective or objective.

Lateral deviation.—In most cases the curvature is strictly kyphotic. In two of my cases the kyphosis was combined with a slight scoliosis, in two others a shortened leg caused some lateral deviation of the curvature.

Fixation.—In all the eighteen cases the kyphosis was more or less fixed; only in two—nos. I and IV—could the spine be straightened at the time when the patient was first examined, but also in these the curvature became fixed within six months or a year. In the roentgenologic picture there is nothing to indicate that fixation has occurred. The cause of its occurrence is not clear; but as *Guentz* has shown,¹⁾ fibrous degeneration of the intervertebral discs, between the diseased vertebræ is not uncommon. According to *Schmorl*, the change from the elastic condition should be due to prolapse of the nuclei; the intervertebral disc losing part of its elasticity when some of its tissue penetrates into the spongiosa. Against this it may be argued that in many cases there is nothing in the roentgenologic picture indicating prolapse of the nuclei; but to this question we shall come back later, in the following. It has occurred to me that in the cases where the kyphosis can be straightened out passively during the first few months, the explanation might lie in the existence of an *initial, spastic stage*, during which the condition

¹⁾ Versteifung der Wirbelsäule durch Fibrose der zwischenwirbelscheiben. *Mitteil. u. d. Grenzgeb. d. Medizin u. Chir.* vol. XLII, 1931, p. 505.

would then be similar to what we find in cases of genu valgum, pes planus and Perthes' disease; namely, a muscular fixation of the osseous parts involved, due to the pain occasioned by every movement of the back.—On clinical examination the fixation of the kyphosis is very soon discovered. The patient can neither straighten that part of his spine actively, nor can the straightening be done passively, either with the subject suspended or lying on his stomach. Also lateral movements can be executed only to a minimal extent. The degree of the fixation can, of course, be highly various, from slight stiffness to absolute rigidity. In its mildest degree it may be found in children even before the age of ten years, and it can then often be difficult to detect it, as it may exist in youngsters otherwise entirely normal. As already mentioned, it is best observed when the subject stands erect, with arms raised, as described by *K. A. Knudsen*.¹⁾ He found it in about 50 per cent. of the youthful subjects he examined, and it must therefore be considered as a condition of the thoracic spine midway between normal and abnormal. I have myself roentgen-examined ten such boys without finding anything irregular whatever.

This whole question of early fixation of the thoracic spine, and its subsequent course, has not yet been thoroughly studied, and there have been no regularly repeated examinations, extending over a number of years, of these children; consequently, we have no certain knowledge of what such a fixation may imply. It results in a certain stiffness of the back; yet we see that young fellows with even rather pronounced fixation may nevertheless be good gymnasts. There is therefore hardly any reason to regard the fixation, in the case of those otherwise normal individuals, as anything serious; only if it is accompanied by evidences of incipient kyphosis need any lasting changes be apprehended. In the latter case it may then happen that at the first examination of the subject one finds nothing to note except the existence of *fixation + kyphosis*; while the roentgenographs show nothing irregular, because the abnormal conditions

¹⁾ »Folkeskolen«, 1933, no. 2.

in the spine begin to develop only later, in the course of a year or so. This was the case with two of my patients (Cases II and VI).

Period of Observation.—My purpose with the investigations recorded in these pages has been to follow the kyphosis, if possible, from its earliest beginning until what might practically be considered as its final development, or at least until the vertebræ had assumed their ultimate shape. This has not been possible, however, as regards the whole number of cases in which a first examination had been made, because several of the patients could not be reached, or did not respond, when the time came for a subsequent examination. My material was thus somewhat larger to begin with than the 18 cases comprising the series with which I have been able to carry the investigations through in the manner intended. These eighteen patients have been under observation for from 1 to 5 years; most of them for about 3 years, with, on the average, one examination per year.

The Vertebræ.

The question as to which vertebræ undergo a change can only be answered with the aid of the roentgenographs. With regard to the above series we find that in 3 cases only one had altered, in 9 cases two, in 5 cases three, in 1 case four. In most cases the change involves two or three. In three cases only a single one was affected, viz. either the eighth or ninth thoracic. The greater the number of vertebræ affected, the more pronounced will, as a rule, the kyphosis be; if it is only a question of a single one the curvature will be relatively slight. As the bodies of the vertebræ never become entirely wedge-shaped as in tuberculous spondylitis and in cases of compression fracture, because even in extreme cases their anterior vertical width does not become less than one half of the posterior, the kyphosis will never become angular, but only arcuate.

The changes have been in the eighth to twelfth thoracic vertebræ, and have been greatest in the ninth to eleventh. This agrees with what has been noted by other investigators. *Lindemann*¹⁾

¹⁾ *Lindemann*: Die lumbale Kyphose im Adoleszentenalter. Zentralbl. f. Chirurgie 1933, p. 832.

has recently reported four cases of kyphosis of the lumbar region. I have myself seen only one such case, in a young female patient. Why the lower part of the thoracic spine is particularly liable to those changes is at present a matter of conjecture. It is usually stated that the mobility in the spine is greatest between the twelfth thoracic and the first lumbar vertebræ. *Waldenström*¹⁾ has shown that tuberculous spondylitis most frequently attacks the ninth to eleventh thoracic vertebræ, while according to *Businger*²⁾ those from the ninth thoracic to the fourth lumbar are attacked with equal frequency. It is possible that traumatic influences play a part in that respect. Something similar may perhaps be the case in kyphosis, though there it would probably not so much be a matter of direct traumata, from excessive movements, as the result of more indirect influences. It is thus conceivable that the shock of an impact in the direction of the longitudinal axis of the spine, for instance at the end of a jump or from the weight of a heavy burden, might affect the vertebræ in the middle of the elastic vertebral column.

What is the Nature of the Changes in the Vertebræ?

Formation of the limbus vertebralis.—The changes which one observes in lateral roentgen pictures of the spine are confined entirely to the superior and inferior contours of the vertebral bodies, especially in front, where both the position and the shape of the limbus vertebralis are affected during the development of the latter. One has to be thoroughly acquainted with the position and shape of the limbus of the normal vertebra in order to recognise the incipient abnormalities, which can often be very difficult. As a rule, a basis for such recognition may be found, however, in a comparison of the supposed pathologic changes with the condition of the adjoining, normal vertebræ above and below.

Not only the limbus, but also the zone of growth—the columnar layer of cartilage between the intervertebral discs and

¹⁾ *Waldenström*: Acta Chir. Scand. vol. LVI, 1924, p. 463.

²⁾ *Businger*: Schweiz. med. Wochenschr. no. 14, 1928, p. 355.

the spongiosa—is affected. Before the nucleus of the limbus is formed, the normal vertebra appears with blunt angles anteriorly, its contours towards the epiphyseal plates regular, with well defined margins, and in the thoracic region its form, as seen from the side, is very nearly rectangular. At the anterior and posterior corners there now appears—from about the eighth or ninth year in girls (*Robert Hanson* has even observed it at the age of six) and from the thirteenth year in boys—a small calcareous shadow, normally flat, but sometimes curving downwards over the anterior corners. This shadow, which to begin with only represents a calcareous formation in the cartilage, gradually changes into true spongy tissue, and corresponds to the annular epiphysis, by *Schmorl* termed: *die Randleiste*, by *Hellmer*¹⁾: *the limbus vertebralis*. This limbus, which thus appears as a small, flat shadow at the anterior and posterior borders of the vertebra, begins to form first at the lower anterior corners of the ninth to twelfth thoracic vertebræ, the process extending thence up and down the column. Little by little, it appears as a thin osseous line along the borders of the vertebræ, with which it fuses by the twentieth to twenty-fifth year. In some children of eight to ten years, and sometimes some years older, one does not in the roentgenographs find the usual quadrilateral shape of the vertebral bodies, but a *step-like form*, which in the side view makes them appear with deep rectangular incisions in the upper and lower anterior corners. These incisions are filled with cartilage, and in this the nucleus of the limbus normally develops.

If the vertebra is to get a normal shape, it is now necessary that the formation of the limbus should begin sufficiently far out in the cartilage, so that it will come to lie in the right place when the ossification in these step-like incisions sets in, and the vertebral body thus gradually become rectangular. In the cases where the vertebræ become wedge-shaped we find that the formation of the limbus has not begun at the normal place, but farther in towards the anterior, oblique corners of the vertebral

¹⁾ *Acta Radiologica* 1932, p. 485.

body, or else, more rarely, that the limbus is either very feebly developed or its shape irregular. If the vertebra is step-formed, it can be seen that the nucleus, which lies in the notch, is also pressed in against the body of the vertebra, as, for instances in my cases no. IV and VIII. Thus, in no. IV, where the picture is very typical, the broad nucleus of the limbus is distinctly seen lying too far in towards the bottom of the incision. Besides, it is seen that it does not lie as far out towards the anterior side of the vertebra as it should, in relation to the place of the nuclei above and below it.

As these facts with regard to the development of the limbus have not been discussed before in the literature, and as I consider the knowledge of them indispensable for the diagnosis, I shall deal with them in some greater detail. If we study the roentgenographs we make the following observations:

1.—*The limbic nucleus may be entirely lacking anteriorly.* It is present in the adjoining vertebrae, but not in the affected one. It is consequently not found at the first roentgen examination, nor does it make its appearance later. The contours of the vertebra merely become gradually sharper and more regular. This will, of course, eventually lead to its becoming decidedly wedge-shaped. We see examples of this in nos. III, X and XVI. The condition may be found in a single vertebra or in two adjoining ones. Most distinctly is it seen in no. X, where two of the vertebrae are only half as high anteriorly as posteriorly. The nuclei of the limbus are here lacking anteriorly, while they are distinct, and even rather large, posteriorly in the same vertebrae. The development of the limbus can thus be entirely suppressed anteriorly. There is absolutely no calcification or ossification in the anterior part; only at the middle of the corpus does the development begin, quite faintly, and rises thence to its full height posteriorly. As a result of this, the wedge-shape of the vertebral body becomes very marked right from the onset of the affection and until the fusion between the limbus and the body takes place, so that the latter ends by being only half as high anteriorly as posteriorly.

2.—*The nucleus of the limbus is placed close to the anterior*

corners of the corpus. This is the condition most frequently observed. It is found in 14 of my eighteen cases; only in 4 it is not so. As already mentioned, it is the case also when the vertebra in the lateral roentgen view appears with the step-like shape described in the foregoing.

3.—*The nucleus of the limbus does not, as in the normal vertebra, lie away out by the anterior corner, but until 1 cm. behind the anterior contour.* Some of the roentgenographs show this very distinctly. The nucleus may be strongly developed, though; so that the anterior part of the ring is seen as a small curved shadow at some distance from the anterior margin. In the roentgenographs we find this in five cases (nos. V, VI, VII, XI and XIII). In the second picture of no. V the anterior outline of the limbus in the tenth thoracic vertebra is clearly seen to lie 0.5 cm. behind the margin of the vertebral body.

The changes here described under points 1, 2 and 3 are particularly characteristic of incipient kyphosis formation. At least one of them will always be present, and a combination of two, or of them all three, is quite frequent.

4.—*Variations in the form of the nucleus are frequent.* Often it is of the same size and appearance as those of the adjoining vertebræ, but it is not unusual to find it irregularly enlarged, blurred, and ragged of outline. This is the case especially in the vertebræ with deeply incised anterior corners, where the nucleus of the limbus develops in the middle of such an incision, and not, as normally, farther out, corresponding to the final contour. The large, blurred, calcified mass gradually undergoes conversion into true spongy, osseous tissue, which fills the whole of the incision, without however giving the vertebra the same, normal form as the others. This is seen most distinctly in no. IV (ninth thoracic), no. V and no. VIII.

As norm for the origin and development of the process, *Mau*¹ sets up the following three stages: (1) stage of congestion (Reizstadium), (2) stage of deformation and destruction, (3) stage of repair. A similar division and nomenclature is used by

¹ *Mau*: Zeitschr. f. orthop. Chir. vol. XLVI, 1930, p. 173.

French authors: (1) phase de congestion, (2) fragmentation, (3) période de reconstitution. I find it difficult to accept these three stages, which pass so gradually into one another; especially the »stage of congestion«. I do not quite understand on what those authors build their assumption of an actual congestion taking place to that part of the vertebral border. It is, on the whole, very difficult to get specimens for microscopical examination from this disease, and nobody has yet possessed, and been able to thus examine, a specimen from its early stage. It is on that very ground that *Walther Müller*¹⁾ has criticised *Schmorl's* theory concerning the pathogenesis of kyphosis,—that it is founded on cases in which the disease was already more or less advanced.

As basis for our conclusions on this point we therefore have only the roentgenographs and such information as the clinical observation can give. As regards the roentgenological picture, it is only the blurred, irregular appearance of the nuclei that can suggest the idea of congestion; but, as a matter of fact, any process of calcification in cartilage presents that appearance; it is only after that process has been completely terminated that the limits become sharp, and the picture stands out clearly.

As regards the clinical observations, it must be the incipient kyphosis, with the fixation localised to one particular point of the spine, and the possible pain and tenderness at that point, that suggest the idea of congestion. But those symptoms vary more or less, and hardly justify the expression: stage of congestion. *Mau* mentions as a special characteristic the occurrence, simultaneously with the changes in the vertebræ, of »a more or less pronounced atrophy of the vertebral body at the summit of the kyphosis«. I have never observed any such. On the contrary, I have often wondered that the changes did not go more deeply. The estimate with regard to calcareous deficiency in a vertebra, from a roentgenological side view, is difficult, and must always be more or less subjective.

¹⁾ Das röntgenologische Bild und die klin. Bedeutung der sogenannten Knorpelknötchen der Wirbelsäule. *Brun's Beitr. z. klin. Chir.* vol. CXLV, 1929, p. 191.

The wedge-shaped vertebra.—If we study the roentgenographs serially, we see how the limbus, where any such is present, gradually extends and fuses with the body of the vertebra, while the latter becomes wedge-shaped. If only one vertebra has been affected it will be the only one to get this shape. The degree to which the wedge-shape develops is very different, but in no case will the vertical height anteriorly become less than one half of the posterior, and the vertebra will retain this wedge-shape henceforth, through the rest of the patient's life. The wedge never becomes quite pointed anteriorly.

The border of the vertebra.—As it might be expected, the contour of the vertebræ towards the epiphyseal plate presents an uneven appearance; especially its anterior half, as the development of the limbus there takes place at different times, more or less irregularly. The step-like form is frequent, and contributes to the abnormal pictures observed. The irregular contour is the rule. We find it in all my eighteen cases; only in nos. IX and XIV is the irregularity slight. In no. IX the kyphosis is not particularly pronounced, the form of the limbic nuclei is normal, and in no. XIV only a single vertebra has undergone a change. But besides the irregular limbus the unevenness of the vertebral borders may also be due to another cause, namely to:

*Prolapse of the nucleus.*¹⁾—the questions pertaining to this have now been cleared up, thanks to *Schmorl's* investigations. We know that the nucleus pulposus can force its way through the layer of cartilage covering the end-plate of the vertebra, which during the period of growth is much feebler than in later life. It can be seen how the nucleus causes the cartilage to bulge into the spongiosa and sometimes breaks through into the latter, whereupon a reactive zone of cartilage forms around the invading portion. The base of this prolapse may be more or less broad, and in the side view we then see notched indentations in the contour of the vertebra, as much as 8 mm. deep and 2 mm. wide, sometimes more flat, or slanting; and these indentations

¹⁾ Über Knorpelknötchen. Fortschr. a. d. Geb. d. Roentgenstr. vol. XXXVIII, 1928, p. 265; and Die pathol. Anatomie der Wirbelscheiben, Braun's Beiträge z. klin. Chir. vol. CLI, p. 360.

contribute very much to the irregularity of the contour.—The wavy contour is a characteristic pertaining to the age of youth, and is due to the formation of the limbus.

If we examine the roentgenographs of my eighteen cases, we find prolapse of the nucleus in eleven of these. The condition has never been observed prior to the age of puberty, but is otherwise found in all individuals from that age onwards; most frequently in those engaged in bodily work, and often in connexion with kyphosis juvenilis. The cause of its occurrence is in a paper by *Schmorl*, from 1930, explained as follows: As it can be found at an early age it may be supposed that it is due to faulty development of some kind or other; probably to some congenital weakness or abnormality in the structure of the hyaline cartilage, which locally makes it less resistant. *Schmorl* has namely in many instances found positive microscopical changes in the cartilage discs though the intervertebral discs macroscopically looked perfectly normal, and in some cases those changes could with almost absolute certainty be traced to changes during the period of development.

Prolapses of the nucleus pulposus are most frequently observed in the thoracic and lumbar regions, not in the cervical one. Their size varies from very small to nearly 1 cm. in diameter. Their form is hemispheroidal, as a rule confined to the region of the nucleus; but they can also be triangular or square, pointing obliquely backwards or forwards. They often lie symmetrically on both sides of the intervertebral disc, which sometimes seems narrower, because part of its tissue has gone to form the prolapse. This is not seen in the roentgen picture, however. The most probable is that the prolapses are not in themselves a malformation, but rather the result of some slight trauma sustained by the vertebral column, whose tissues in some individuals, for reasons which we cannot explain, are congenitally weak. Originally, *Schmorl* used the term: cartilage hernia, on account of the formation of cartilaginous tissue which, in cases of such prolapse, takes place in the surroundings of the latter. At that time he had not formed for himself any clear idea in regard to the course of the process. The term is

still used by many authors, though *Schmorl* himself has since declared it to be wrong; the fresh formation of cartilage being merely a reaction on the part of the tissue, wherefore the correct designation for the phenomenon is either *nucleus prolapse* or *Schmorl's nodule*.

Compère and *Keyes*¹⁾ have succeeded in provoking nucleus prolapse experimentally in dogs by lesioning the intervertebral discs and the annulus fibrosus with a drill and a chisel. From two to six months after, they examined the vertebræ both macro- and microscopically, and found in them a process exactly similar to the one observed in cases of spontaneous prolapse. When the intervertebral disc had not been injured, but only the vertebral body fractured, no prolapse occurred.

Though prolapse of the nuclei is often observed simultaneously with kyphosis I find it difficult to believe that the process has anything directly to do with the development of the latter. It can be found in subjects in whom there is not the slightest sign of any incipient kyphosis, in schoolboys who have never been doing any hard physical work, and may be seen in vertebræ quite outside the kyphotic section of the spine. Thus, in my patient no. XVI, in whom only the eighth thoracic vertebra is wedge-shaped, it will be seen (best in the first roentgenograph, no. 420/28) that there are prolapsed nuclei in the inferior margins of the eighth to twelfth thoracic vertebræ, though the form of the ninth to twelfth is perfectly normal. *Wissing*²⁾ has examined the roentgenographs of 421 subjects and found prolapse in 13.5 per cent. of them. He does not believe that severe traumata have anything to do with their occurrence. *Schmorl* found prolapse of nuclei in 38 per cent. of the spines he examined. At first he did not think it a feature of any pathological significance, but when he found that it was particularly frequent in the early part of life, in juvenile kyphosis, the prolapsed nuclei sometimes lying in a straight line, one below the other, in the thoracic and lumbar regions, he concluded that they must be pathologic after

¹⁾ *Compère* and *Keyes*: Roentgenological Studies of the intervertebral disc. Am. Journal of Roentgenology, June 1933, p. 774.

²⁾ Acta Pathol. et Microbiol. Scand., Suppl. III, 1930, p. 499.

all, and believed that they were the cause of the kyphosis. His argument was that lesions of the cartilage discs, in combination with the prolapse, produce a change in the elasticity of the discs, and that in individuals habitually working in a bent posture the pressure on the anterior portion of the vertebræ must therefore in the long run result in the growth of that portion becoming less vigorous, just as the uneven contour of the vertebra may be imagined to be the result of irregular pressure of the intervertebral disc during the continued growth; and an additional reason he sees in the opposition which the ligaments and the whole construction of the vertebræ offer to approach between the latter when the intervertebral discs have become narrower through loss of substance to the prolapse, as a result of which only their anterior borders can come into contact with each other.

I cannot agree with *Schmorl* in this view of the matter; for we know from his own investigations that prolapse of the nuclei occurs only in 38 per cent. of cases, and if he were right in his arguments it must necessarily follow that kyphosis would be more frequent. I can much easier imagine that the pressure to which the intervertebral disc and the vertebral bodies are so often subjected as a result of the erect and frequently bent posture *will cause the whole anterior portion of the cartilage layer to bulge into the spongiosa*. I have succeeded in finding several prepared specimens of human vertebræ in which the nucleus is seen bulging in towards the spongiosa. One sees how the line of the cartilage is forced back, but is not yet broken; only its most prominent part shows some degeneration and a considerable thinning of the cartilage layer. When one thus under the microscope sees how the unbroken line of the cartilage can bend under the pressure of the nucleus there is absolutely no difficulty in conceiving that the whole cartilage bed, with the zone of growth, may be pressed into the vertebral body anteriorly.

In these vertebræ the intervertebral disc is thus stronger than the spongiosa, which yields to the pressure. We therefore see that several intervertebral spaces gape anteriorly; but this compensation is not sufficient to prevent kyphosis from developing. Nor

does the fact that the intervertebral spaces hardly ever get narrower, but sometimes can get broader anteriorly, fit with *Schmorl's* theory concerning the tissue's contribution to the prolapse and the consequent narrowing of the intervertebral disc as contributive factors toward the kyphosis. Those features are not usually found in the roentgenographs, and when they are, their presence is generally due to a lateral inclination of the spine.

Why only the spongiosa of these vertebræ yields to the pressure, while that of the adjoining ones above and below does not, can only be surmised. It may possibly be because the section of the spine from the eighth thoracic to the first lumbar vertebra is the one most exposed to traumatic lesions from movements of the trunk and from the weight of excessive loads. It is quite conceivable that the effect on the elastic spinal column may be confined to a single vertebra, or to a few adjoining ones; on the other hand it is impossible, in cases where the process is more or less pronounced, to exclude the possibility of the existence of some individual factor. Thus, *Walther Müller*,¹⁾ for instance, conjectures the existence of local osteoporosis due to endocrine causes. In cases of senile kyphosis the curvature is usually situated somewhat higher, around the fifth to seventh thoracic vertebræ; but in individuals between the ages of fifty and sixty one not infrequently sees, among the members of the series from the tenth to the twelfth thoracic, characteristic examples of what are known as »fish vertebræ«. In those cases the condition is due to senile or pre-senile osteoporosis, and is found not only in bodily workers. I have found it myself in business men who declared that they had never done any heavy physical work.

It can therefore not be osteoporosis that causes the spongiosa to yield in cases of juvenile kyphosis. As I have already said, the most likely supposition is that it is the cartilage layer which is affected;—that *it is the pressure, directly, which pushes this part into the spongiosa*; and as the pressure is strongest anteriorly this is the direct cause of the kyphosis. This theory also

¹⁾ op. cit., p. 210.

squares with the fact that one sometimes can see indications of an incipient wedge-shape right at the beginning of the disease, even before the nuclei of the limbus have made their appearance; as may be noticed, for instance, in case no. XVIII. Also a certain check on the capacity for growth in the places where the pressure is greatest may possibly contribute to the wedge-shape of the bone.

It seems to me that this is a more natural conception of the matter than *Schmorl's* theory, according to which the determining factor should be the nucleus prolapse and its influence on the elasticity of the cartilage disc, and on the vertebral growth anteriorly. It is true that there are cases in which the prolapse seems to meet some hindrance to its direct penetration into the spongiosa, and therefore merely breaks through the cartilage disc and extends itself obliquely in an anterior direction along the inner side of the zone of growth, where it undoubtedly can affect the latter; but those cases are rare. *Schmorl* is also inclined to think that slight prolapses of the nuclei have something to do with the irregular contour of the vertebræ, but in many roentgenographs I have found that in that respect the manner in which the limbus develops plays a very important rôle. I believe that this question can be decided with greater certainty by means of the roentgenographs than by examination of the prepared vertebræ, which are very liable to be damaged in the course of such preparation. *The irregular contour must be considered to be the result of irregular development of the limbus; only occasionally the result of prolapse of the nuclei.*

Hook-shaped Projections.

In some cases, especially in severe ones, there are seen on the anterior edges of the vertebræ small curved projections, which, just as in spondylitis deformans, can grow together, so that finally a bone bridge is formed between the middlemost vertebræ at the apex of the kyphosis, which thus becomes absolutely rigid. Such projections were found in 5 of my eighteen cases, but only in 2 were they developed to any considerable extent.

Prolapse in posterior Direction, into the spinal Canal.

It might be asked why one does not also observe prolapse of the nuclei in anterior or posterior direction. Prolapse on the posterior aspect of the vertebral body is however not so infrequent as formerly supposed. *Schmorl* found it in 15.2 per cent. of the vertebræ he examined, and *Andræ*¹⁾ has found it in 11.5 per cent. of 174 spinal columns of male subjects. They can project for a little distance into the spinal canal, but seldom give rise to nervous symptoms. *Dandy*,²⁾ however, describes two cases in which the symptoms were so strong that the projections had to be removed by operation. His microscopy hardly leaves any doubt but that they were actual nucleus prolapses. In recent years there have been published a number of cases in which operation was necessary; but in these the cause was not nucleus prolapse, but either true osteomas or chondromas, or else prolapse of the annulus fibrosus. All these cases are described in *Mauric's* work: »Le disque intervertebral«. The most recent case reported is one communicated by *Hellmer*,³⁾ (Stockholm). This was a case of chondroma and calcification, and also in this operation was necessary.

Anteriorly, nucleus prolapse never occurs, because the anterior longitudinal ligament prevents it; what the thin posterior longitudinal ligament is not strong enough to do.

Prognosis.

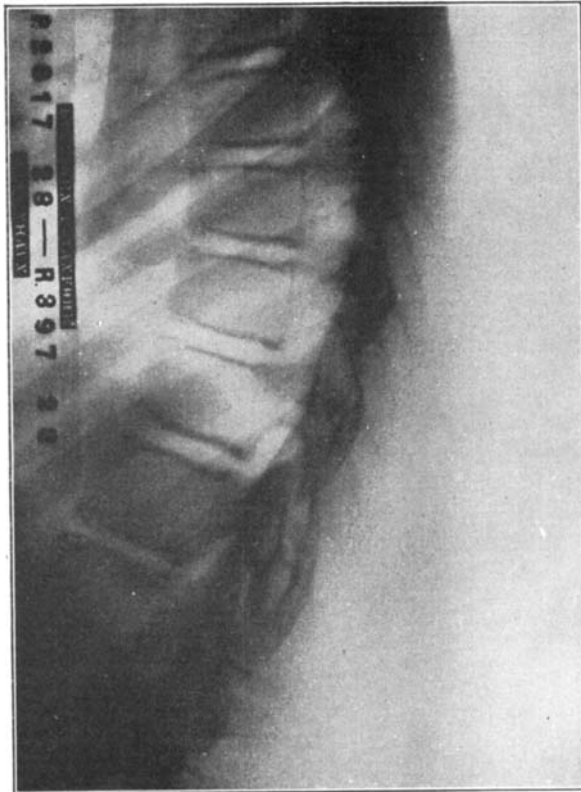
It is probable that an idea of the prognosis may be formed by studying the whole series of cases and comparing the details of the earliest pictures of each with the later ones from the same case, at the same time taking note of the relation between

¹⁾ Über Knörpelknötchen am hinteren Ende der Wirbelbandscheiben im Bereich des Spinalkanals. Beitr. z. path. Anatomie 1929, vol. LXXXII, p. 464.

²⁾ Loose cartilage from intervertebral disc, simulating tumor of the spinal cord. Arch. of Surgery vol. XIX, 1929, p. 660 (cit. *Mauric*: Le disque intervertebral. Paris 1933, p. 122).

³⁾ Ein Fall von Verlagerung von Bandscheibengewebe nach hinten. Acta Radiologica, vol. XIV, 1933, p. 165.

the roentgenological changes and the degree of the kyphosis. The matter is a very difficult one, however; because the degree to which the condition has developed when the patients first come in for examination varies so greatly. Comparatively few

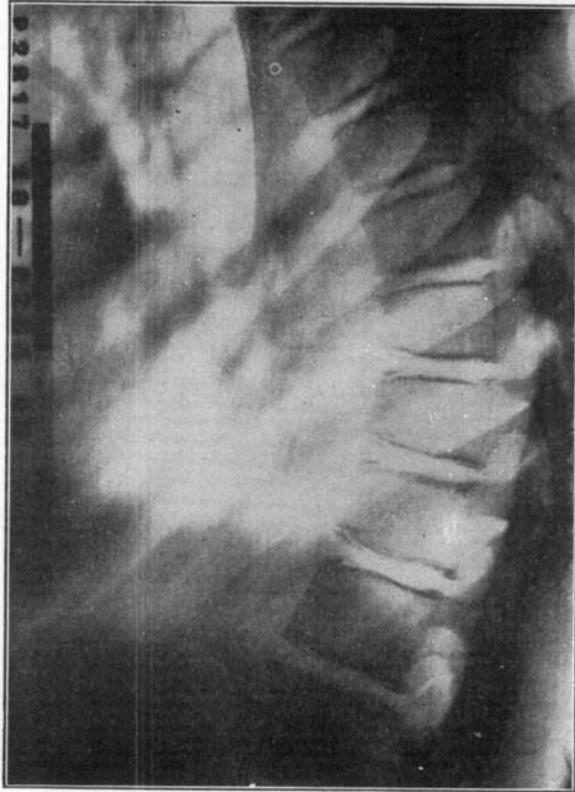

Journal Nr. 1. Aged 16 years ♂ I. 2817/28 21st Nov. 1928. Clinically slight kyphosis. Limbic nuclei visible. Vertebrae normal. The only abnormal feature is that in the caudal corners anteriorly the nuclei lie pressed closely in against the bodies of the vertebrae. The case must be considered as a borderline case between normal and abnormal.

come while the disease is yet in its early stage; mostly this depends on whether it is attended with pain or not. The prognosis is therefore uncertain.

Remarks on the individual Cases.

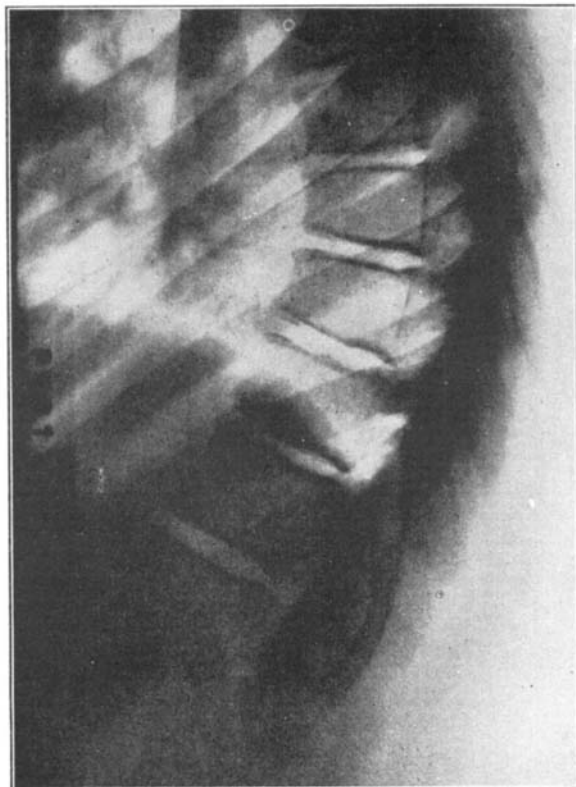
No. I is one of the typical cases. A boy sixteen years old presents himself for consultation. Examination shows merely a tendency to kyphotic posture, which is easily straightened out by suspension. No fixation. *The roentgenograph shows normal*



Journal Nr. 1. II. 22nd May, 1929. The difference from the earlier picture is especially in the obliqueness of the inferior anterior corner of the eleventh thoracic vertebra.

vertebræ, with normal limbic nuclei except in the tenth and eleventh thoracic, in which there are two separate nuclei anteriorly in the inferior part of the bodies, and these are situated a little closer to the corner of the latter than in the other *vertebræ*. This irregularity is however so slight that one would be

most inclined to regard the case as either normal or, at most, as a borderline case, which might perhaps make it advisable to keep the patient under observation. This was done, and we now see an almost imperceptible transition from normal to abnormal conditions, though with only slight roentgenologic changes. The

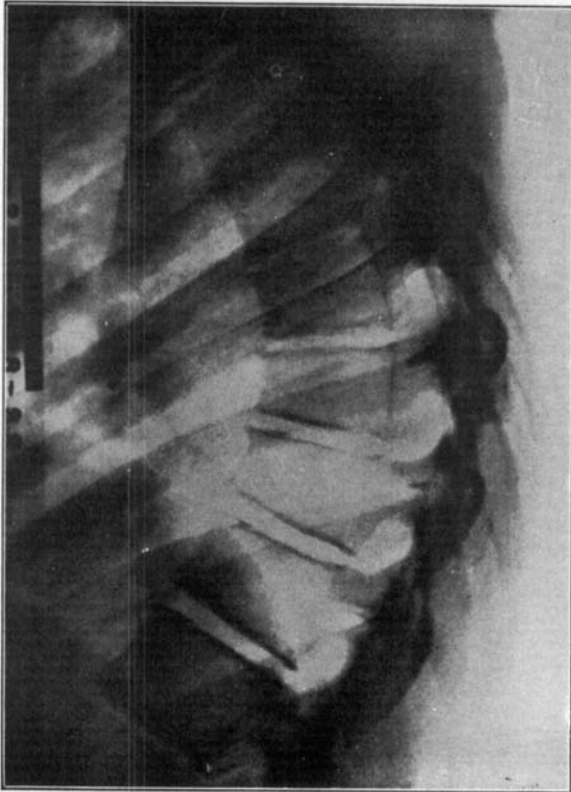

Journal Nr. 1. III. 3rd Apr., 1930. Ninth to eleventh thoracic vertebrae slightly wedge-shaped. Kyphosis intensified. The limbus shadows lie close to the bodies of the vertebrae.

Journal Nr. 1. IV. 25th Oct., 1930. Difference from preceding picture only slight.

irregularity of the limbic development in the tenth, and especially in the eleventh thoracic vertebrae persists during the following years, until it is finally evened out and a beginning of

fusion is noticed four years after the first examination. By the end of this time the ninth to eleventh thoracic vertebræ are somewhat wedge-shaped, but there is an apparent disproportion between the marked kyphotic deformity and the wedge-shape of the vertebræ. In this case we thus see that a moderate wedge-shape of three vertebræ is sufficient to cause marked kyphosis.

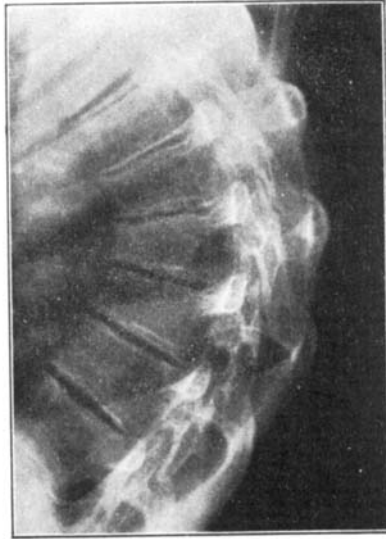

Journal Nr. 1. V. 17th Feb., 1932. Kyphosis very pronounced. Ninth to eleventh vertebræ wedge-shaped. The intervertebral spaces broad, gaping anteriorly. The limbus shadows had fused with the bodies of the vertebræ. Clinically, entirely rigid kyphosis. It would thus have been impossible to diagnose the incipient kyphosis at the first examination.

This shows the impossibility of basing any prognosis on the indications furnished by the first roentgenographic picture. All

one can say is that there is an irregularity in the primitive development of the limbus in two vertebræ; it *may* not mean very much, but on the other hand the development may be such that will result in actual deformity.

No. II.—At the first examination the tenth to twelfth thoracic vertebræ are somewhat wedge-shaped. This wedge-shape gradually becomes more pronounced, and 3½ years later it is



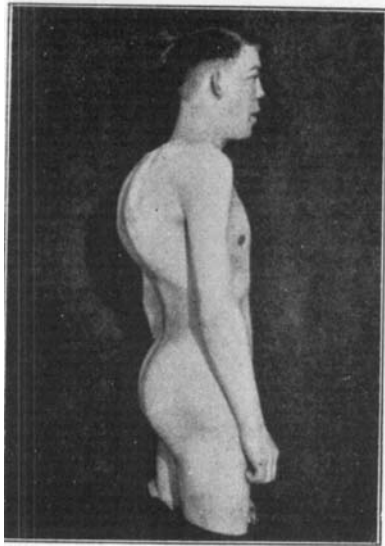
Journal Nr. 3. Male, aged 17 years. 1823/27. Three roentgenographs taken in the course of 3½ years. Seventh to ninth thoracic vertebræ affected. The last picture is reproduced in order to show the dome-shaped kyphosis.

typical in two of the vertebræ, and at the same time there is marked kyphosis. In this case the degree of the latter is proportionate to the wedge-shape. Already on first examination one will consider the prognosis as bad, because the patient has not come under observation until several years after the condition began to develop.

No. III.—The first examination shows marked wedge-shape of the seventh to ninth thoracic vertebræ. The disease had begun one year previously. It develops into a very pronounced, almost semicircular kyphosis, with small intervertebral spaces. The

degree of the kyphosis is proportionate to the wedge-shape of the vertebræ.

No. IV.—A more unusual case. The patient is a boy fourteen years old, only the ninth thoracic vertebra is affected. At the time of the first examination there was merely kyphotic posture, which could be completely straightened out; *already six months after there is kyphosis with fixation.* Three and a half years later



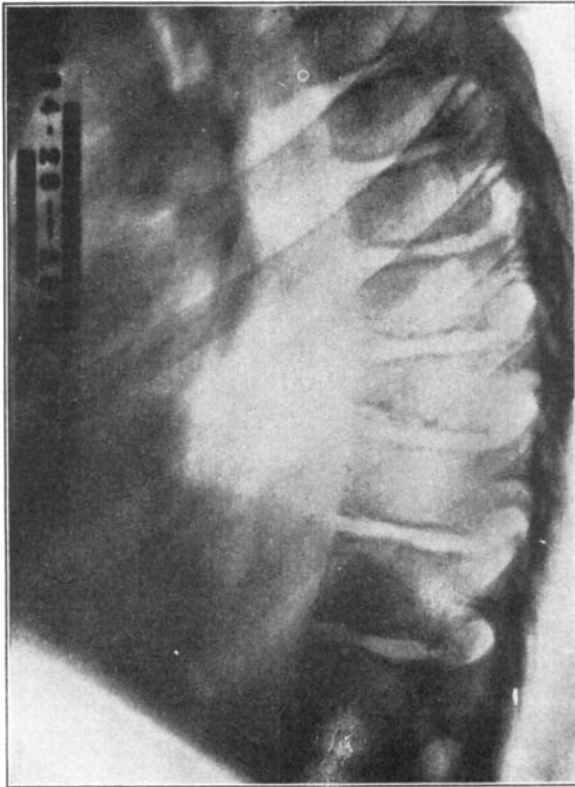
Journal 3. 20 years. ♂.

the cavity of the vertebra is filled with osseous tissue. The vertebra is slightly wedge-shaped, the fixed kyphosis correspondingly slight.

No. V.—The first examination shows the ninth to eleventh thoracic vertebræ to be wedge-shaped, their margins very irregular. In the course of two years the wedge-shape becomes very pronounced, and there is proportional, very pronounced kyphosis.

No. VI.—The first roentgenograph taken of this boy, who was fourteen years old at the time, shows normal conditions, with incipient limbus formation. Clinically there was merely a

kyphotic posture, with some fixation. He presents himself because he has been having a pain in his back for eighteen months past, and because he has become roundbacked. Three and a half years after, the eighth to twelfth thoracic vertebræ have become wedge-shaped, with irregular limbic nuclei and *pronounced*,



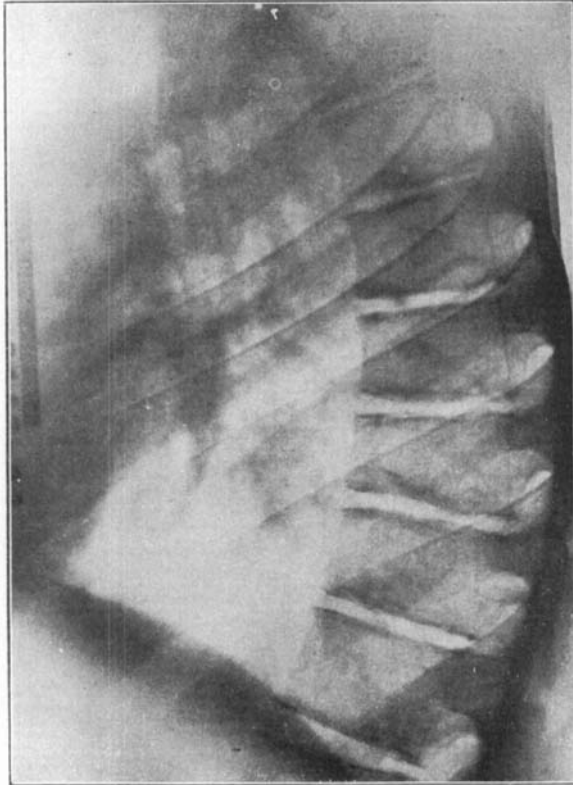
Journal Nr. 4. I. Male, aged 14 years. 1224/28. More unusual form. Only the ninth thoracic vertebra affected, with concave depression at caudal anterior corner, where the limbic nucleus is seen lying close in against the body of the vertebra.

rigid kyphosis. The degree of the latter is proportionate to the wedge-shape of the vertebræ.

As in No. I, the first roentgenograph shows entirely normal conditions, and also in this case it is therefore impossible to

prognosticate anything with regard to the outcome, which in both cases has been *mala quoad sanationem*.

No. VII.—At the first examination the eighth and ninth thoracic vertebræ were found somewhat wedge-shaped, and there was rigid kyphosis. Three years after, the wedge-shape is perhaps



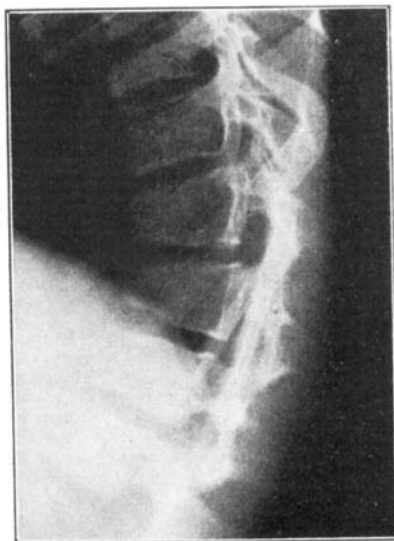
Journal Nr. 4. II. $3\frac{1}{2}$ years later. The cavity is filled, the limbus has fused. Slight wedge-shape. Clinically rigid kyphosis.

a little more pronounced; the limbus has fused, but otherwise the condition is unchanged. The kyphosis is rigid, pronounced, and proportionate to the wedge-shape of the vertebræ.

No. VIII.—Slight wedge-shape of the eighth to tenth thoracic vertebræ of a boy fifteen years old, with some kyphosis, but no fixation. From the roentgenological changes, with the very ir-

regular vertebral margins, there was reason to suppose that the case would develop into very pronounced kyphosis. This was not the case, however. *Three years after, the kyphosis had become fixed, but had not increased.* Its degree is proportionate to the wedge-shape of the vertebræ.

No. IX.—In a boy fifteen years old, with kyphosis in medium degree, the first examination shows slight wedge-shape of the

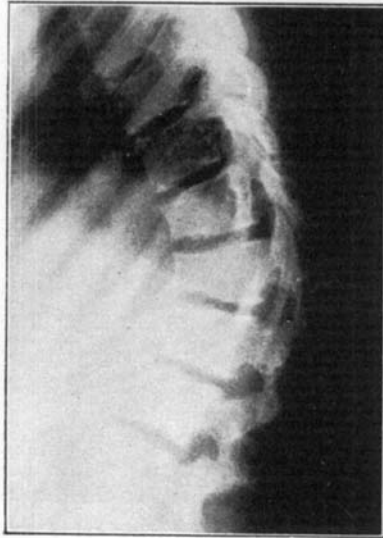


Journal Nr. 10. Female, aged 17 years. 2991/30. I. Eleventh and twelfth thoracic and first lumbar vertebræ affected. Immediately strong deformity. The vertebral bodies only half as high anteriorly as posteriorly. No limbic nuclei visible, though such are present, and normal, in the adjoining vertebræ.

ninth to eleventh thoracic vertebræ. In the course of eighteen months *the kyphosis does not get more pronounced*; the limbic nuclei develop well, but are situated close in against the bodies of the vertebræ. Also this is a case in which one would expect the condition to get worse. The degree of the kyphosis is proportionate to the wedge-shape of the vertebræ.

No. X.—The first examination shows marked wedge-shape of the eleventh and twelfth thoracic and first lumbar vertebræ,

which are only half as high anteriorly as posteriorly. The patient is a young girl, seventeen years old, who, when first seen, had already been suffering from kyphosis in a considerable degree for several years. The singular feature of this case is that in the diseased vertebræ *the development of the limbus is completely suppressed*, and only begins to appear, very faintly, when the patient has reached the age of twenty years. The kyphosis has by then become somewhat more pronounced, and is almost



Journal Nr. 10. II.—Taken fifteen months after the preceding one. The kyphosis much more accentuated than before. In the normal vertebræ the limbus has commenced to fuse, and the same is seen to be the case posteriorly in the affected case. A year later, the roentgenological picture was more or less unchanged.

angular. Its degree is proportionate to the wedge-shape of the vertebræ.

No. XI.—Young man, eighteen years old when first examined. The ninth to eleventh thoracic vertebræ are at that time found somewhat wedge-shaped; there is a smooth, rigid kyphosis, but the condition becomes *only slightly worse* during the following fifteen months. The degree of the kyphosis is proportionate to the wedge-shape of the vertebræ.

No. XII.—The first examination shows the ninth to twelfth thoracic vertebræ to be wedge-shaped; the condition gets somewhat worse in the course of a year. The degree of the kyphosis is proportionate to the wedge-shape of the vertebræ.

No. XIII.—The first examination shows the eighth to tenth thoracic vertebræ to be somewhat wedge-shaped, and there is a rather considerable rigid kyphosis (present for eighteen months past), of a degree which seems out of proportion to the not very pronounced roentgenological changes. In the course of two years the wedge-shape of the vertebræ gradually increases.

No. XIV.—Affection of the ninth thoracic vertebra in a girl thirteen years old. Marked step-formation anteriorly on the caudal side, with large limbic nucleus, *just as in No. IV*, where likewise the ninth thoracic vertebra was affected. In the course of a year one observes incipient ossification of this part. The kyphosis is of medium degree and quite rigid, but has not become more pronounced. Its degree is fairly proportionate to the wedge-shape of the vertebra.

No. XV.—At the time of the first examination, when the boy was sixteen years old, the eleventh and twelfth thoracic vertebræ were wedge-shaped. Four and a half years after, the wedge-shape is very pronounced; the margins of the two vertebræ are uniform, smooth. Very pronounced, rigid kyphosis; the intervertebral spaces rather wide anteriorly. The degree of the kyphosis is proportionate to the wedge-shape of the vertebræ.

No. XVI.—The first roentgenograph taken of this girl, when she was fifteen years old, shows wedge-shape of the eighth thoracic vertebra. The *limbic nuclei are lacking*, though such are present in the other, normal vertebræ. There is a certain degree of fixed kyphosis. In the next picture, taken two years after, the nuclei are still lacking. In the last picture, taken five years after the first, the vertebræ are, if anything, a little less wedge-shaped; their margins fairly uniform. The condition has not become worse, but is, on the whole, unchanged.

The case thus resembles that of No. X, inasmuch as the nuclei of the limb are suppressed, and only begin to develop feebly after the age of twenty, whereby the wedge shape becomes

less apparent. The degree of the kyphosis is proportionate to the wedge-shape of the vertebræ.

No. *XVII*.—Girl, seventeen years old. At the first examination the tenth and eleventh thoracic vertebræ are wedge-shaped; there is a certain degree of fixed kyphosis. The development of the affection is already far advanced. The condition does not grow worse, and the kyphosis is rather slight. The patient is a sister of

No. *XVIII*.—A very early case, of a *boy nine years old*, with lengthy cartilaginous stage of the step-formed depression in the ninth thoracic vertebra; constriction of the intervertebral disc between the latter and the tenth thoracic. This condition remains unchanged for several years. Four years after, the depression is still large, and also in the eighth and tenth thoracic vertebræ there are now step-formed depressions, with very irregular limbic nuclei. In spite of this the kyphosis is slight, though fixed. The observation of the case is not yet ended, but *it is very interesting by being the earliest demonstrated one of all my cases.*¹⁾

The conclusions to be drawn from these cases may be summarised as follows:

1.—*It is not always possible to make an accurate prognosis on the basis of the first roentgenograph, taken at the beginning of the disease.* There are patients whose posture is kyphotic, in whom the roentgenograph discloses nothing abnormal, and in whom the condition nevertheless goes in the direction of fixed kyphosis and wedge-shaped vertebræ, without it being possible on first examination to prognosticate anything in regard to the eventual course. We see this from the two cases no. I and no. VI, which both developed into pronounced, rigid kyphosis. The only way to obtain a result is by keeping the patient under sharp observation, so as to be able to intervene with treatment (reclination) at the right moment.

2.—*Fixation of the kyphosis can occur within a time of six months* (see no. I and no. IV).

¹⁾ A similar case is described by *Walther Müller* in the *Deutsche Zeitschr. f. Chirurgie* vol. CCXXXV, 1932, p. 447.

3. *An incipient, fixed kyphosis can show an absolutely normal roentgenological picture* (no. I and no. VI). If the fixation is not muscular, in the nature of a spastic fixation, it must be due to the intervertebral discs.

4.—*The development of the limbus may be entirely suppressed for several years* (no. X and no. XVI), while the limbic nuclei are present in the adjoining vertebræ.

5.—*If only one vertebra is affected, as is nos. IV and XIV (in both cases the ninth thoracic), the kyphosis will only be of middling degree.*

6.—*If several vertebræ are affected, the degree of the kyphosis will be proportionate to the wedge-shape of these.* If there is any disproportion in this respect, as in no. XIII, it will be because the intervertebral discs have become narrowed, and thus help to intensify the curvature. The case is not usual, but in this instance the narrowing can be seen already in the first roentgenograph, between the eleventh and twelfth thoracic vertebræ.

7.—By the time the patients present themselves for first examination they are, as a rule, already suffering from a certain degree of kyphosis of two or three vertebræ, which during the following time gradually become more or less wedge-shaped, so that the condition almost invariably gets worse, though in some cases only slightly so (no. VIII). This wedge-shape then remains unchanged during the rest of the patient's life.

Intermediate Forms of the Vertebræ.

In the foregoing I have described the cases of indubitable juvenile kyphosis whose development I have been able to follow for several years. The following 5 cases are of patients who presented themselves for examination owing to kyphotic posture. Also these I have been able to follow, both by personal examination and through roentgenographs, for a length of time, ranging from eighteen months to four years. In all of them the kyphotic posture has since the first examination either completely disappeared or has at least not become more accentuated. All of them were school-children who had been complaining more or

TABLE II. *Forms intermediæ*

Case No.	Journal No.	Sex	Age	Physique	Occupation	Fatigue, Pain	Tenderness	Lateral deviation	Fixation	Length of time observed	Vertebrae altered
1	1102/29	♀	12 ¹ / ₂	tall, strongly built	school girl	some	none	none	some	3 years (2 roentgenographs)	9th-11th thoracic
2	2184/30	♀	12		school girl	fatigue	none	none	none	4 years (6 roentgenographs)	1st lumbar
3	2659/30	♀	13		school girl	yes	some, direct tenderness	none	some	18 months (2 roentgenographs)	10th and 11th thoracic very slight wedge-shape
4	213/27	♀	14	slim (in a stage of rapid growth)	school girl	yes	none	none	none	3 years (2 roentgenographs)	2nd lumbar
5	2876/30	♂	8		school boy	yes	some	none	some	2 ¹ / ₄ years (2 roentgenographs)	7th thor. very slight wedge-shape

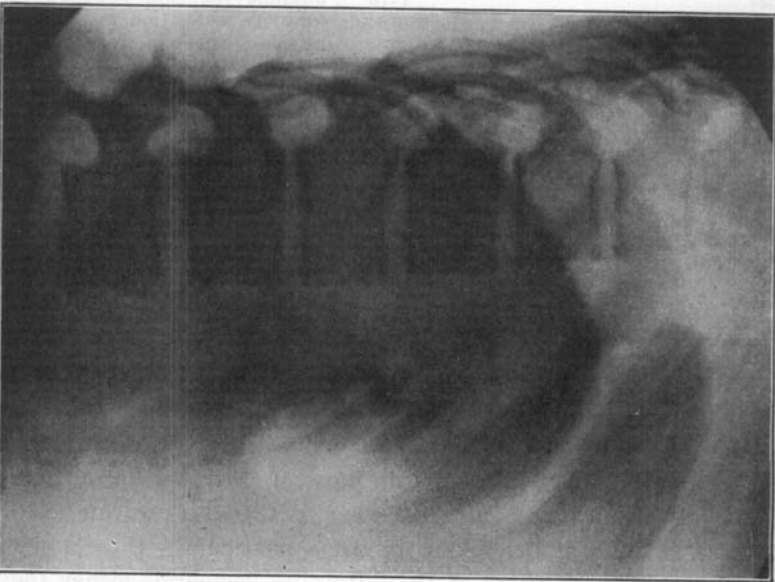
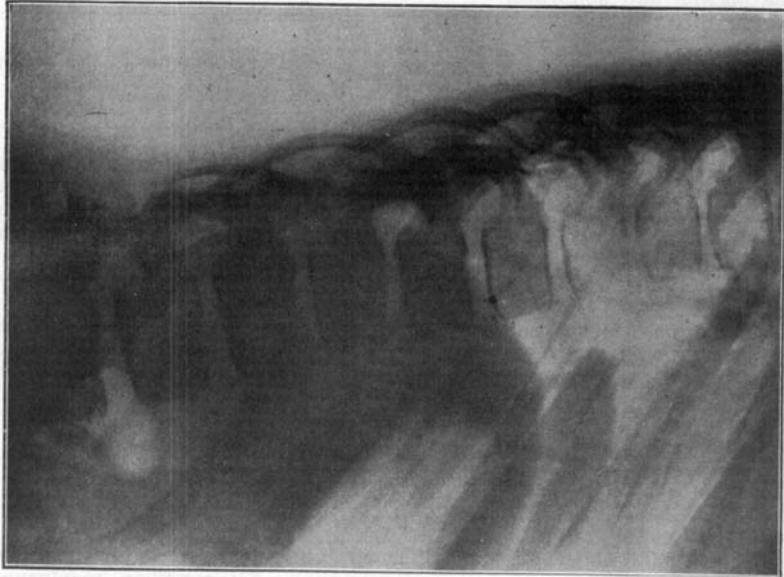
less of pain and tiredness in their backs, two of them also of a slight tenderness of the spine. In two of them there was some fixation of the kyphotic part of the latter. Four of them were girls, the fifth a boy eight years old.

In two of the girls the ninth to eleventh thoracic vertebrae were affected, in the two others only a single vertebra (respectively the first and second lumbar), while in the boy it was the seventh thoracic. Already this difference indicates that the na-

between normal and abnormal.

Position of limbic nucleus	Shape of limbic nuclei	Later changes	Contour of vertebr. marg.	Nucleus prolapses	Developments in the roentgenological picture
Does not extend all the way forwards	large, round, while the surrounding ones are flat	none	regular	none	It might be thought that the large limbic nuclei, which do not lie quite anteriorly, would develop pathologically, but 3 years after it is seen that this has not been the case. The kyphotic posture remains.
normal only the upper margin is irregular. The limbic nuclei appear earlier in the 11th thoracic v. and the ones above it than in the 1st lumbar.	normal	none	superior margin irregular	at first 2 large ones, later smaller	At first, one is inclined to think that the vertebra will become wedge-shaped, but gradually the contour is completely regenerated. No kyphosis.
faint (large on the vertebræ below)	normal	none	regular	2 small ones betw. 10th and 11th thoracic	Clinically, incipient kyphosis, with some fixation. Yet condition roentgenologically fairly normal, except for slight wedge-shape. It is possible that the patient's being kept for a time in reclination position has arrested the process; she has since been well; the vertebræ normal.
normal	large, somewhat irregular	none	regular	none	Incidentally roentgen-examined on account of a fall. Only an anomaly in the ossification of the lumbar at the caudal anterior margin of the 2nd lumbar v.; since entirely well, with vertebra almost normal.
none		still slight wedge-shape	regular	none	Kyphotic posture, with some fixation; unchanged 2 $\frac{1}{4}$ years after, with no aggravation. Is to be examined again in 3 years.

ture of the affection was not the same, but that it was a matter of more incidental disturbances of the ossification. The same is the result one comes to by considering the form and location of the limbic nuclei, which in most of the cases are normal. The irregularities one finds are so slight that they can hardly be called abnormalities. Yet in some particulars these nuclei are different from those of the adjoining vertebræ; either they are larger and rounder, or else more feebly developed, and can



Intermediate Form. Journal Nr. II.—Female, aged 12 years. 2184.
Irregular ossification of superior contour of the first lumbar vertebra. One might suspect a beginning wedge-shape formation, but gradually the contour is to some extent restored. Four years after. The conditions are normal, also clinically. Large nucleus prolapse in second lumbar vertebra.

resemble those whose development becomes abnormal later on. As the prognosis was thus uncertain, the children were kept under observation.

In the boy, who was only eight years old, there was, of course, no limbus yet; nor has it made its appearance two years later. The curious feature of his case is that the seventh thoracic vertebra is slightly wedge-shaped, and that this wedge-shape still persists two years and three months later. It is possible that it may eventually become entirely compensated by the development of the limbus, but as to that it is impossible to be in any way certain, also because there is some fixation of his spine. It may be,—and I would even think it probable—that we have to do here with a case of incipient juvenile kyphosis just as we saw it in the boy, aged nine years, whose case I have described in the foregoing under no. XVIII.

These two boys, respectively eight and nine years old, thus represent the earliest beginning of a kyphosis among all the cases. The wedge-shape of the vertebræ, present already before the appearance of the limbic nuclei, thus shows that the primary cause must be sought in the line of growth, which either becomes pressed into the spongiosa or whose development anteriorly is behindhand.

In none of the four other cases did the affected vertebræ become wedge-shaped, nor was there any irregularity of the vertebral margins of any importance. In two of them there was prolapse of the nuclei, though; especially noteworthy in the case of no. II. This patient was a girl who, when she was twelve years old, had been run down by a motor lorry. For two years after, she suffered from pain in her back, wherefore she was roentgen-examined, and an irregularity was found in her first lumbar vertebra. Gradually the bone develops normally, however; as a matter of fact it is only in the step-formed corner of that vertebra that the cartilage has persisted longer than in the others. There are now discovered nucleus prolapses both in this first lumbar and in the twelfth thoracic and second lumbar vertebræ; the two last ones particularly deep. Yet there has been no kyphosis formation. *This case confirms the theory that*

nucleus prolapse has nothing to do with the development of kyphosis. In the other case two slight nucleus prolapses were found between the tenth and eleventh thoracic vertebræ in a girl thirteen years old; neither in this case was there any development into wedge-shape.

As for the kyphotic posture, it persisted only in the cases of no. I and no. V; the three others recovered completely. As we have seen, the changes in these »intermediate« cases are not considerable, but in their incipency they can precisely resemble those that lead to lasting deformity of the vertebræ.

Some Studies of the vertebral Epiphyses in Man and in Animals.

The vertebral Epiphysis in Man. The Limbus vertebralis.

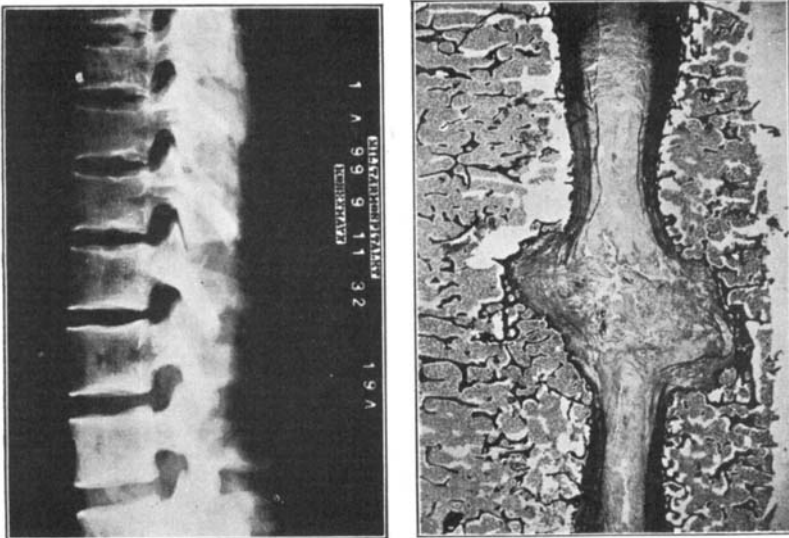
The first to demonstrate the development of epiphyses roentgenologically was *Koehler*, who in his book published in 1915 describes the appearance of their primitive centres in the inferior thoracic vertebræ of a girl, in a lateral view of the spinal column, in the form of small triangular shadows near the anterior corners of the vertebral bodies, best developed along the margins, less distinct farther in towards the centre. He says¹⁾ that granules and lumps of lime salts first begin to appear in the cartilage at the superior and inferior margins of the vertebræ about the tenth or eleventh year, and by the twelfth to thirteenth year unite into a continuous line, which by the twenty-second to twenty-fourth year ossifies and fuses with the vertebræ; first with the cervical, latest with the lumbar ones. All the vertebræ, with the exception of the atlas and three last occygeal vertebræ, have these epiphyses, which are broadest in the lumbar section.

As late as in 1924, *Koehler* thought that the ability to recognise these epiphyses in the roentgenographs was of practical value only medicolegally, as a means of identification in the rare cases where the parts of a found body included only portions of the spine.

The age at which the limbus vertebralis begins to develop

¹⁾ 4th ed., p. 175.

varies somewhat. It is now commonly agreed that its development begins between the eighth and thirteenth year, somewhat earlier in girls than in boys. Among forty spinal columns secured *post mortem* I have found limbic nuclei in one of a boy eight years old, and in one of a girl aged nine. *Hanson* has found them in a girl aged six, and in a boy aged eight years. If there are step-formed indentations in the corners of the vertebræ, the



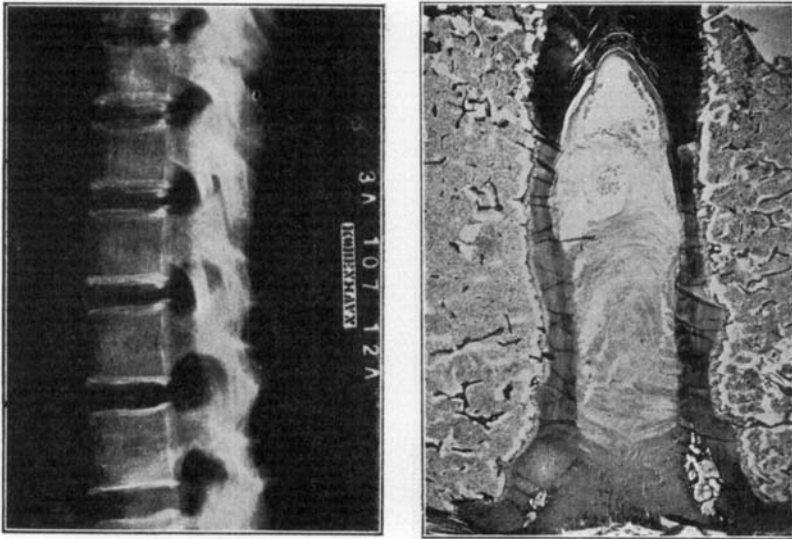
Male, aged 19 years. Normal vertebræ, still showing transverse fissures across the middle. Symmetrical nucleus prolapses in the ninth to eleventh thoracic and first lumbar vertebræ. *Microscopically*: The entire cartilage layer, with the zone of growth, pressed into the spongiosa. The cartilage disc is here quite thin, in parts lacking, more faintly colored.

nuclei show as small hooks curving around these corners. This epiphyseal ring (= Randleiste, limbus vertebralis) fuses with the body of the vertebra by the twentieth to twenty-fifth year, sometimes not until the thirtieth.

In man and in the higher apes the epiphysis is annular; in the latter somewhat broader than in the former. According to *Virchow*¹⁾ it is also annular in elephants.

¹⁾ Berl. Med. Wochenschr. 1916, p. 32.

The form and location of the limbus have been mentioned in the foregoing. I have dissected out *post mortem* and roentgenographed seven or eight specimens, either entire vertebræ or vertebral bodies alone, and have sawed out, for microscopical examination, an intervertebral disc with the contiguous osseous parts. The staining was done *ad modum* van Gieson and with eosin. I reproduce some microphotographs, 6 times enlarged.



Text to Roentgenographs with Microphotographs juxtaposed.

Female, aged 12 years. Vertebræ normal. Limbic nuclei strong. In the microphotograph the latter is seen anteriorly as a small area of cancellous bone. Around the intervertebral disc there is a strong unbroken layer of cartilage, with zone of growth towards the diaphysis.

The vertebral Epiphyses in Animals.

The veterinary literature contains only little information in regard to the vertebral epiphyses. In *Max Weber's* work on the mammals¹⁾ it is stated that the anterior and posterior aspects of the vertebræ is covered with a bone plate, the epiphysis, which develops from a separate osseous centre, and does not fuse with

¹⁾ *Max Weber*: Säugetiere. 1927, p. 104.

the body of the vertebra until the animal is full-grown. In the cetaceæ they remain separate for a long time; in the kangaroos they are rudimentary.

In the »Handbuch der mikroskopischen Anatomie des Menschen«¹⁾ it is stated that blood vessels penetrate from the perichondrium into the epiphyseal cartilage before the osseous centre is formed, and that the growth of the epiphysis takes place in all directions, on which account there is no formation of columnar cartilage or of beams of cartilaginous ground substance. The cartilage is disposed more in lines around the medullary spaces; only isolated remnants of it remain, and project into the latter. At the diaphysis there is columnar cartilage. As the individual grows older the cartilage plate becomes thinner, and finally it is broken through, so that communication is established between the epiphysis and the diaphysis.

Prompted by *Schmorl's* investigations concerning the vertebrae, *O. Beadle* has made some comparative studies of the vertebral epiphyses in man and in animals.²⁾ His investigations included

- 1 vertebra of a calf 12 months old.
- 1 » » » » 15 » » .
- 1 » » » fetus of calf, 8 months old.
- 1 » » » » » » 4 » » .
- 1 » » » horse 19 months old.

Besides vertebrae of some pigs, young and old, and of small domestic animals.

I, too, have made some similar studies, with a view to ascertaining whether nucleus prolapses occurred also in animals. The material was kindly furnished me by the Pathoanatomical Institute of the State Agricultural College in Copenhagen, to whose chief, Prof. *Foelger*, I here express my thanks for his courtesy in this matter. It included twenty-two young animals; namely, 6 dogs, 2 cats, 3 goats, 3 pigs, 1 calf, 1 heifer, 1 wolf,

¹⁾ Handbuch d. mikrosk. Anatomie des Menschen, 1930, vol. II, p. 457.

²⁾ *O. Beadle*: Vergleichende Untersuchungen über die Wirbelkörper-epiphyse beim Menschen and beim Tiere. Beitr. z. pathol. Anatomie, vol. LXXXVIII, 1931, p. 101.

1 rabbit, 2 rock badgers, 1 polecat and 1 hare. From all these animals, the thoracic and lumbar spine was dissected out and sawn through lengthwise in the midline, whereupon they were first examined macroscopically for nucleus prolapse, then roentgenologically, both in antero-posterior and in lateral projection. At either the twelfth thoracic or the first lumbar vertebra an intervertebral disc, together with half of the vertebral body on each side, was dissected out for microscopical examination.

When the spine of an animal is sawn through, one sees that the nucleus pulposus projects much more strongly than in children. This is the case especially in pigs, where, on the other hand, the epiphysis is rather narrow. The nucleus pulposus must consequently, in these young animals, be either very tightly spanned in, or else very elastic. A distinct epiphyseal plate was found in them all, except in a fox-terrier seven months old, in the two badgers, and in the polecat; in which four there was no epiphysis.

Beadle says that in man there is a cartilage layer underneath the intervertebral disc, with a zone of growth towards the spongiosa, the intervertebral disc in animals is directly contiguous to the epiphysis, because the cartilage disc is lacking. According to him, the tissue of the annulus fastens directly onto the end-surface of the epiphysis; the fibres of the lamellar annulus sinking themselves, like Sharpey's fibres, into the end-plate of the epiphysis, which consist of compact osseous tissue. My investigations show that this is not the case. *Also in animals there is a cartilage layer between the intervertebral disc and the epiphysis*, but it is relatively thinner and not so distinctly circumscribed as in man; its thickness varying in different animals. The longitudinal growth takes place, in animals, on the side of the intermediary cartilage facing the diaphysis, where a zone of growth can be seen, consisting of cartilage cells disposed in columnar formation. The nucleus pulposus is never seen to force its way in through the epiphysis; in every place one finds an unbroken cartilage layer.

In order to investigate the vertebral column also of larger animals, with respect to nucleus prolapse, I have examined, at

the Municipal Cattle Market and Slaughter House, about 400 spinal columns of bulls, cows and calves and 25 horses, besides the sawn-through spines of about 200 pigs; and in none of them did I find any signs of nucleus prolapse. On the basis of all these investigations I feel justified in saying that *nucleus prolapse* does not occur in animals of any of the species which I

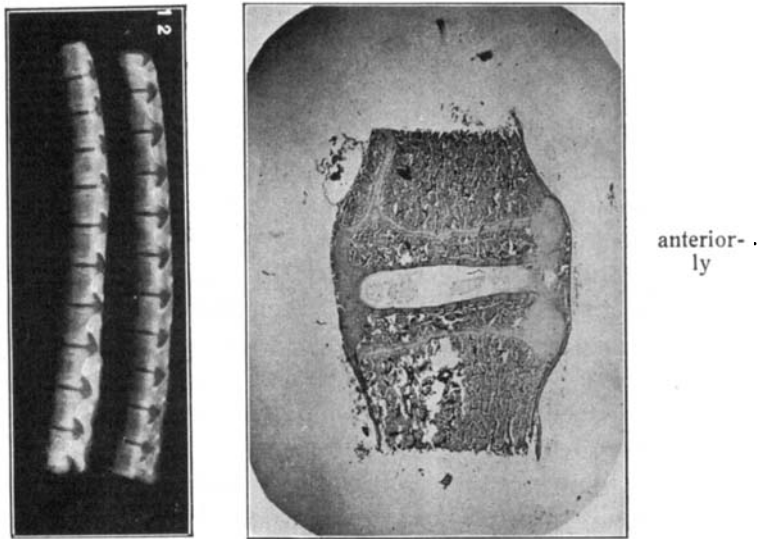


Fig. 2 months old. Rather narrow epiphyseal plates; nuclei protruding. Anteriorly, step-formed depression filled with cartilage. *Microscopically*: Unbroken cartilage beds, with zone of growth on the intermediary cartilage towards the diaphysis.

have had occasion to examine. Why this is so can only be conjectured. Possibly the horizontal position of the spine may have something to do with the matter. In the vertically disposed spine the intervertebral discs are constantly under a stronger pressure, and it is quite imaginable that this pressure, with the effect of some traumatic influence added to it, may overtax the resisting power of the disc to such an extent that the nucleus breaks through the locally weaker cartilage layer. It is also possible that *Beadle* may be right when he says that the spongiosa

is stronger in animals than in man, but of this I have never been able to find any evidence in my specimens. My impression, from examinations made with the same enlargement as used by him, is that the density of the spongiosa is very much the same in man and in animals.

A specimen, from a pig two years old, is shown in the accompanying illustration.

SUMMARY

The terms: occupational kyphosis, apprentice's kyphosis and muscular kyphosis, or occupational stoop, were introduced into the literature in 1907, by *Schanz*, as expressions for certain pathological conditions which by him were ascribed to what he called: *insufficiencia vertebrarum*. In a paper published in 1920 I showed by means of roentgenographs that those conditions were due to an alteration in the form of one or several vertebræ in the spine of the subjects concerned, as a result of which these became wedge-shaped; and at that time I rather believed the affection to be some form of osteochondritis.

I now present the results of my examination of 18 cases—13 boys and 5 girls, of ages ranging from nine to eighteen years—all observed for from 1 to 5 years, with roentgen examination every year.

The affection most frequently develops at about the fourteenth to sixteenth year, and as a rule the kyphosis develops in the course of from six months to one year. In most cases, the changes involve two or three vertebræ, oftenest the ninth to eleventh thoracic. In severe cases the pains in the back can persist through life, called forth by any untoward exertion, but they never result in actual invalidity.

In several instances a mobile kyphosis has been seen to become fixed in the course of six months without any changes being observable in the roentgenographs. Such changes only occur in the course of a year or so.

The change in the shape of the vertebræ usually commences

simultaneously with the first development of the limbus vertebralis, and manifests itself either by (a) total absence of the limbus, (b) the limbus being situated close to the anterior corners of the vertebral body, (c) the limbus not extending all the way to the anterior margin of the vertebral body, or (d) the form of the limbus being irregular. Sometimes, though rarely, the changes begin several years before the first development of the limbus.

The result is that the bodies of the vertebræ become wedge-shaped; probably because the cartilage layer of the vertebral body becomes pressed into the spongiosa, probably also owing to some check in the growth.

Schmorl's theory, according to which nucleus prolapse should be the primary factor, cannot be accepted, as in many instances there is no such prolapse.

The irregular contour of the wedge-shaped vertebræ must be supposed to be due to the irregular development of the limbus vertebralis, and, in some instances, to nucleus prolapse.

The prognosis cannot be established at the beginning of the disease. Of cases, all carefully roentgen-examined, which, when first observed, showed merely a mobile kyphotic posture, some in the course of a year developed into rigid kyphosis, which gradually got worse; while others neither got worse nor developed into fixed kyphosis. The fixation is probably due to fibrous degeneration of the intervertebral discs.

The youngest subject in whom the beginning of the disease was found, and in whom it eventually developed into true kyphosis, was a boy aged 9 years.

My studies have dealt also with the annular epiphyses (= limbus vertebralis) in man, and with the zone of growth beneath the cartilage layer, opposite the spongiosa. Roentgenographs and some microphotographs are reproduced.—

As a supplement to these studies of juvenile kyphosis I have made some studies of the vertebral epiphyses in animals. I have examined the spines of 22 young animals; viz., dogs, cats, pigs, goats, calf, heifer, wolf, rabbit, rock badger and polecat, both by roentgen, macroscopically (after the specimens had been sawn

through) and microscopically. Also, macroscopically, the sawn-through spines of about 400 bulls, cows, and horses, and of 200 pigs.

In young animals there is a marked projection of the nucleus pulposus. The cartilage layer which separates the intervertebral disc from the epiphysis is considerably weaker than in man; in some animals it is entirely lacking. The width of the epiphyseal plate varies in the different animals; it is separated from the diaphysis by a small intermediary cartilage. On the side of the latter opposite the diaphysis is found the zone of growth,—the columnar cartilage. *Nucleus prolapse is not seen in animals.* Step-formation of the vertebræ is sometimes found, just as in man.

RÉSUMÉ

Les affections comprises sous les noms de cyphose du travail, cyphose de l'apprenti, cyphose musculaire ou dos voûté professionnel, ont été introduites dans la littérature en 1907, par *Schanz*. L'agent étiologique allégué est »l'Insufficiencia vertebrarum«. En 1920, l'auteur de l'article ci-dessus a démontré, par des radiographies, qu'une déformité cunéaire des corps vertébraux marquait le début de la maladie, qu'il regardait plutôt comme une ostéochondrite.

A présent l'auteur publie des recherches portant sur 18 cas, 13 garçons et 5 filles, âgés de 9 à 18 ans, et qu'il a suivis pendant 1 à 5 années, avec des radioscopies répétées chaque année. L'affection se déclare le plus souvent à l'âge de 14—16 ans, la cyphose se développant généralement au cours de 6 à 12 mois. Dans le plus grand nombre des cas, 2 ou 3 vertèbres sont déformées, le plus souvent les 9—11 vertèbres dorsales. Dans les cas graves, les douleurs au dos reviennent même après des années, à la suite de fatigues, sans causer cependant une invalidité réelle.

Plus d'une fois l'auteur a constaté qu'une *cyphose mobile s'immobilise au cours de 6 mois*, sans que la radiographie révèle

des conditions anormales. Celles-ci n'apparaissent qu'après un an environ.

Les déformations des vertèbres coïncident le plus souvent avec l'ébauche et le développement du limbus vertebralis; elles se présentent sous les aspects suivants:

a: L'ébauche du limbus fait défaut. *b*: Le limbe ébauché est placé tout contre les angles antérieurs du corps vertébral. *c*: Il n'atteint pas le bord antérieur. *d*: La forme en est souvent variée. *e*: Dans les rares cas, les déformations commencent plusieurs années avant que le limbus ne s'ébauche.

De ces altérations résulte la forme cunéaire des corps. *La cause* est probablement que la couche cartilagineuse des corps est enfoncée dans le tissu spongieux; peut-être aussi le processus se combine-t-il avec une retardation de la croissance.

Schmorl a mis en avant la théorie que le prolapsus du nucléus serait le facteur primaire. L'auteur ne peut pas accepter cette théorie, comme beaucoup de cas ne présentent pas de prolapsus nucléaire.

Le contour irrégulier des vertèbres cunéaires doit s'interpréter comme la conséquence du placement irrégulier du limbe vertébral, et quelquefois d'un prolapsus nucléaire.

La prognose ne se laisse pas établir au début de l'affection. Parmi les cas soigneusement étudiés par radioscopie, lesquels à la première inspection ne présentent qu'une attitude cyphotique mobile, il arrive qu'un cas évolue, au cours d'une année, en une cyphose immobile qui s'aggrave avec le temps, tandis qu'un autre cas ne s'aggrave pas, et les articulations ne s'immobilisent pas.

Chez un garçon de 9 ans, une première inspection a fait constater une lésion qui est devenue une vraie cyphose, c'est le cas le plus précoce que l'auteur a rencontré.

L'auteur a fait des recherches sur des épiphyses annulaires humaines, sur le limbe vertébral et la couche proliférante qui se trouve sous le disque cartilagineux, contre le tissu spongieux.

L'article apporte des radiographies et quelques microphotographies.

En outre on a fait des recherches sur les épiphyses vertébra-

les chez les animaux. On a étudié les colonnes dorsales de 22 jeunes animaux des espèces chien, chat, chèvre, pourceau, veau, génisse, lapin, daman, putois et lièvre, d'abord par radioscopie, et puis, les colonnes dorsales fendues à la scie, par inspection macro- et microscopique. De plus, inspections macroscopiques de 400 colonnes vertébrales fendues à la scie, des espèces taureau, vache, cheval, et de 200 porcs.

Chez les jeunes animaux on trouve un nucléus pulposus très saillant. La couche cartilagineuse est considérablement plus faible que chez l'homme; elle sépare le disque ligamenteux d'avec l'épiphyse, chez un petit nombre d'animaux elle fait complètement défaut.

La plaque épiphysaire, plus ou moins large selon l'espèce de l'animal, est séparée de la diaphyse par un étroit cartilage intermédiaire, qui porte, sur la face tournée vers la diaphyse, la couche proliférante, avec sa disposition par colonnes des cellules cartilagineuses. Le prolapsus nucléaire n'est pas constaté chez les animaux. On y trouve quelquefois des contours à gradins comme chez l'homme.

ZUSAMMENFASSUNG

Der Begriff der Arbeitskyphose, Lehlingskyphose, muskulärer Kyphose oder des Berufs-Rundrückens wurde 1907 von *Schanz* in die Literatur eingeführt. Als Ursache wird »Insufficiencia vertebrarum« angenommen. 1920 wies ich an Röntgenbildern nach, dass die Ursache in der Keilförmigkeit der Wirbelkörper zu finden ist, und ich fasste damals das Leiden noch am ehesten als eine Osteochondritis auf.

Es liegt nun eine Untersuchung über 18 Fälle vor (13 Knaben und 5 Mädchen zwischen 9 und 18 Jahren), welche 1—5 Jahre hindurch mittels jährlicher Röntgenuntersuchung durchgeführt wurde.

Das Leiden entsteht am häufigsten im Alter von 14—16 Jahren, und die Kyphose entwickelt sich in der Regel im Laufe von $\frac{1}{2}$ —1 Jahr. Im allgemeinen sind 2—3 Wirbel verändert, und das sind meist der 9.—11. Dorsalwirbel. Rückenschmerzen kön-

nen sich in schweren Fällen bei Anstrengungen bis ins spätere Leben hinein erhalten, aber sie verursachen niemals eine wirkliche Invalidität.

Es wurde wiederholt konstatiert, dass eine mobile *Kyphose im Laufe eines halben Jahres fixiert wird*, ohne dass das Röntgenbild abnorme Verhältnisse aufweist. Diese treten erst im Laufe eines Jahres auf.

Die Wirbelveränderungen fallen meist zusammen mit der Anlage und Entwicklung des Limbus vertebralis und gestalten sich folgendermassen: a) Die Limbus-Anlage kann vollständig fehlen. b) Sie liegt dicht an den Vorderhörnern des Corpus. c) Sie reicht nicht bis an den Vorderrand heran. d) Ihre Form ist oft wechselnd. e) In seltenen Fällen beginnen die Veränderungen mehrere Jahre, bevor der Limbus angelegt wird.

Das Ergebnis ist eine Keilform der corpora. Als *Ursache* hierzu muss angenommen werden, dass die Knorpelschicht an den corpora in die Spongiosa hineingedrückt wird, wahrscheinlich kombiniert mit einer Verringerung des Wachstums.

Schmor's Theorie, ein Nucleusprolaps sei der primäre Faktor, kann nicht anerkannt werden, da ein Nucleusprolaps in vielen Fällen gar nicht vorhanden ist.

Die unregelmässige Wirbelkontur an den keilförmigen Wirbeln muss als eine Folge des unregelmässig angelegten Limbus angesehen werden und hin und wieder als Folge eines Nucleusprolapses.

Die *Prognose* kann im Beginne der Krankheit nicht gestellt werden. Es liegen genau röntgenuntersuchte Fälle vor, die bei der ersten Untersuchung nur eine mobil kyphotische Haltung aufweisen. Im einen Falle entwickelt sich im Laufe eines Jahres eine steife Kyphose, die sich allmählich verschlimmert; im anderen Falle kommt es zu keiner Verschlimmerung und keiner Fixation. Diese ist vermutlich auf eine fibröse Degeneration der Zwischenwirbelscheiben zurückzuführen.

Der erste Beginn mit nachfolgender wirklicher Kyphose wurde bei einem 9jährigen Knaben konstatiert.

Es wurden Untersuchungen angestellt über den ringförmigen

Epiphysen-Limbus vertebralis des Menschen und die Wachstumsschicht, die unter dem Knorpel nach der Spongiosa zu liegt.

Es werden Röntgenbilder und einige Mikrophotographien beigebracht. Zugleich wurden *Untersuchungen über Wirbelepiphyphen bei Tieren* angestellt.

Es wurden die Wirbelsäulen von 22 jungen Tieren untersucht, und zwar von: Hunden, Katzen, Ziegen, Schweinen, Kälbern, Färsen, Wölfen, Kaninchen, Gebirgsdachsen, Iltissen, Hasen, mit Röntgen, makroskopisch nach Durchsägung und mikroskopisch. Ferner makroskopisch 400 durchgesägte Wirbelsäulen von: Stieren, Kühen, Pferden und 200 von Schweinen.

Bei jungen Tieren findet sich ein stark hervorspringender Nucleus pulposus.

Die Knorpelschicht, welche die Zwischenwirbelscheibe von der Epiphyse trennt, ist bedeutend schwächer als beim Menschen, bei einzelnen Tieren fehlt sie ganz.

Die Epiphysenfläche ist, je nach der Art des Tieres, breiter oder schmaler, von der Diaphyse durch einen schmalen Intermediärknorpel getrennt, welcher auf der der Diaphyse zugeordneten Seite die Wachstumsschicht, den Säulenknorpel, trägt.

Ein Nucleusprolaps ist bei Tieren nicht zu sehen.

Man kann Treppenfiguren wie beim Menschen finden.