

ARVID HELLSTADIUS, STOCKHOLM:

APPARATUS FOR FIRM APPPOSITION OF
RESECTIONAL SURFACES IN INTRA-ARTICULAR
ARTHRODESIS

A forcible joining of the resectional surface in intra-articular arthrodesis is always of great advantage. It prevents an otherwise possible diastasis between the resectional end of the bones, and it further affords an immobilization that cannot be obtained by mere plaster bandaging. The immobilization in a simple plaster cast is far from being complete. That forcible apposition of the resectional surfaces to each other greatly promotes the consolidation can be observed particularly often in cases where intra-articular arthrodesis is performed on knee-joints with pronounced flexion contractures. In such cases it is necessary to resect a considerable piece of the ends of the bones, but in order to make the resulting shortening of the limb as small as possible, the least possible is resected from the ends of the bones. When the knee is straightened, the posterior soft parts are put on the stretch, constituting a certain resistance, and thus the resectional surfaces are forced hard against each other. In such cases the consolidation usually is established after a surprisingly short period as compared to the length of time it generally takes in ordinary resections on the knee-joint, where no fairly strong compression of the contact surfaces takes place.

So, when the resectional surfaces after intra-articular arthrodesis are kept fixed against each other under forcible compression, a rapid and reliable consolidation is promoted. For this purpose I have constructed an apparatus by means of which it is practicable to force the resectional surfaces against each other and produce a powerful compression of the contact sur-

faces. It can be employed for the talocalcaneal joint as well as for the ankle and the knee.

In particular it is of advantage in intra-articular arthrodesis of the ankle to be able to screw the resectional surfaces tightly against each other and thus accelerate the osseous ankylosis. In arthrodesis of this joint it otherwise takes a relatively long time—for instance, as compared to arthrodesis of the knee-joint—before the bony ankylosis becomes so solid and reliable that the patient may be allowed to walk without a plaster cast. When, on walking, the patient puts his entire body weight on the anterior part of the foot, it means a very hard strain on the ankylotic ankle-joint. In arthrodesis of the ankle, therefore, it is essential to insist upon the formation of a particularly strong and dependable bony ankylosis before weight is put on the foot without bandage, and thus the foot has to be kept fixed in plaster for a rather considerable length of time. This, in turn, brings about an atrophy of the bones of the whole foot that usually is most significant. And it is especially in the foot that bony atrophy gives marked and protracted inconvenience.

When finally a dependable ankylosis is obtained in the ankle-joint, and the plaster bandage is discarded, there usually will long remain some pain in the foot when weight is put on it, besides a considerable swelling of the foot, so that in general it will still take a long time before the patient is able to resume work. Under such conditions protraction of the consolidation and thus reduction of the immobilization time are particularly desirable in arthrodesis of the ankle. As pointed out before, an acceleration of the consolidation and, through this, a shortening of the immobilization time may be obtained through compression of the resectional surfaces against each other, and this will also lower the risk of pseudarthrosis formation.

Of course the resectional surfaces may be held in apposition by osteosynthesis with metal wire or screws. But the usually early absorption of bony tissue round these foreign bodies brings about that the close contact between the resectional surfaces often soon becomes more or less defective; besides, the osteo-

synthesis complicates the operation not inconsiderably. Also tenodesis has been employed. Thus, for instance, Biesalski has divided the tendons of the extensors and tibialis anterior proximally to the ankle-joint, whereafter he drilled some longitudinal canals in the tibia—from inside the joint, immediately back of the anterior edge of the tibia—opening on the anterior surface of the tibia, drew the divided tendons through these




Fig. 1.

canals, and fastened them on the anterior surface of the tibia. In this way, naturally, the trochlea of the talus becomes somewhat backward displaced in relation to the tibia, reducing also the area over which the resectinal surfaces are in direct contact. In arthrodesis of the ankle, I think, neither osteosynthesis nor tenodesis are being employed to any great extent.

On the other hand, there are a good many orthopedists who in order to obtain a good compression of the resectinal surfaces place the limb, after plastering, in a vertical position, so that the weight of the plaster as far as possible is placed on the sole of the foot, and, for further increase of this pressure effect, weights are attached to the plaster. The vertical position of the limb causes a great deal of inconvenience, however, especially in older patients.

For these reasons I employ an apparatus for the joining of the resectinal surfaces the appearance of is shown in Fig. 1.

It consists of a quadrangular metal frame with a vertical supporter in each corner. The lower end of these supporters is provided with a sort of clutch. One side of the frame is movable, and by means of a screw it can be shifted so that the distance between the anterior and posterior parts of the frame—and thus

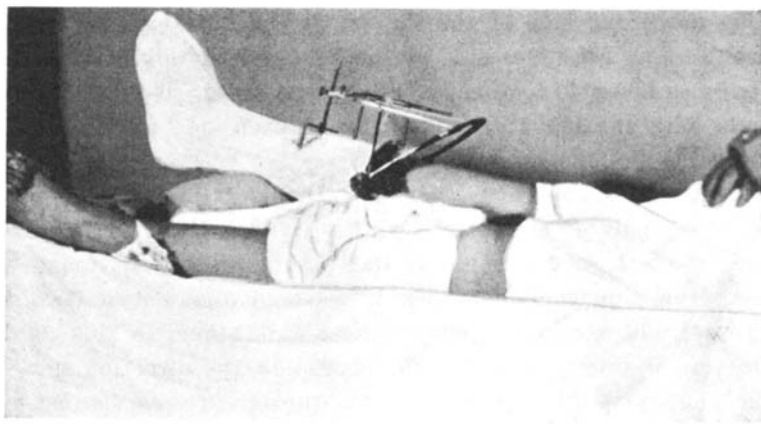


Fig. 2.

between the anterior and posterior supporters too—can be increased or decreased.

If the case involves an arthrodesis of the ankle, after the conclusion of the operation itself, a Kirschner wire—such as usually employed for wire stretching—is drilled through the upper part of the tibia. A padded plaster bandage is applied around the foot and the leg, up to a little below the site of the Kirschner wire. The pad under the sole of the foot is made up of a thick piece of felt. After plastering, the Kirschner wire is tightened through the metal bow that usually is employed in wire traction. When the plaster is thoroughly dry, the screw apparatus is applied so that one pair of supporters with their clutch-like lower end take hold of the Kirschner wire at the upper end of the tibia, the supporters clutching the wire on each side of the leg immediately inside the bow that keeps the wire tight, while the other pair of supporters take hold in thick strings that are fastened in the plaster of the leg (see Fig. 2).

The strings are fastened securely in the plaster in the form of loops, on the upper part of the leg cast, one on the lateral side, one on the medial. In order to ensure that the in-plastered strings will not slip out when the screw apparatus is functioning, I sometimes use only one string with a loop at each end. Then I have placed this string outside on the plaster cast, running down one side of the leg, under the anterior part of the heel and up the other side of the leg cast. In this position the string is fastened by means of a plaster band, so that only the ends with the loops are free, one on each side of the leg, as fastenings for the screw apparatus.

The screw apparatus thus takes hold of the Kirschen wire with one pair of supporters, and with the other pair it takes hold of the looped strings fastened in the plaster. By means of the screw the frame can then be screwed together so that the two pairs of supporters come nearer each other. In this way a traction is exerted on the foot plaster in the direction toward the knee, and the foot plate of the plaster presses against the inferior surface of the foot, effectuating a compression between the resectional surfaces of the tibia and the upper surface of the trochlea of the talus. The degree of compression between the two resectional surfaces may be adjusted as wanted by means of the screw on the frame.

As mentioned above, the plaster under the sole of the foot is padded with a thick piece of felt. This is important in order to avoid injury from pressure when the screw apparatus is functioning and the plaster is forced against the sole of the foot. The apparatus must not be applied till the plaster has dried thoroughly. This applies not least if the string at which the apparatus pulls is runs down under the sole; for otherwise the string may then very readily make impressions in the plaster if this is not completely dry, or if the layer of plaster between this string and the felt under the foot is too thin.

Too great a pressure under the sole gives discomfort in the sole, and the degree of screwing has to be adjusted accordingly. Usually the frame may be screwd together not inconsiderably during the first period after the operation.

After the articular surfaces have been chiselled off in intra-articular arthrodesis of the ankle, the trochlea of the talus is more narrow and the malleolar fork wider than before, and the trochlea can be shifted from side to side between the two malleoli. There results a certain diastasis between the trochlea and the malleoli. This diastasis increases the more the foot is placed in equinus position because the posterior part of the trochlea is more narrow than the anterior. The lateral surface of the trochlea recedes posteriorly toward the midline. Like many other orthopedists, in arthrodesis of the ankle I usually place the foot in a somewhat plantar-flexed position, with a view to the heel of the shoe, and in this position the diastasis between the trochlea and the malleoli is greater than when the foot is in the middling position. As naturally it is of advantage to the consolidation that also the malleoli are in contact with the trochlea, the operating technique has been modified in various ways in order to establish this contact, and these variations are of some significance too when the screw apparatus is employed.

Goldwait has suggested to chisel off both malleoli and press them in against the trochlea. Other surgeons adjust the trochlea in contact with the medial malleolus, and eliminate the resulting diastasis between the trochlea and the lateral malleolus by osteotomy of the lateral malleolus and pressing it in against the trochlea. Wittek chisels off bone lamellæ where the fibula and tibia are in contact, reducing thus the width of the malleolar fork. Bouvier chisels a bone lamella from the medial part of the medial malleolus, and presses this bone lamella against the trochlea. Staub divides the trochlea, and drives a bone wedge from the neck of the talus into the crack, obtaining thus an increase in the width of the trochlea.

If in the intra-articular arthrodesis the lateral malleolus is chiselled off, or if the operation is performed with the technique given by Wittek, and the screw apparatus then is employed to obtain a compression of the upper resectional surface of the trochlea against the tibia, it is essential to see that the resectional surfaces are not placed obliquely, so that the talus slides after the resectional surface of the tibia against the lateral

malleolus, forcing this structure outwards. I have seen one case myself where the talus in this way as displaced laterally, pressing the osteotomized lateral malleolus outwards. In most anatomical text-books it says that the upper surface of the talus and the corresponding inferior articular surface of the tibia are not fully horizontal but sloping slightly from the medial side upward laterally; and under such conditions, naturally, there may readily be a sliding of the talus toward the lateral malleolus, if not particular measures are taken at the operation, aiming to alter the position of the resectional surfaces, so that no sliding may take place.

In feet paralyzed from poliomyelitis I generally have made use of a tri-articular subtalus-arthrodesis for stabilization of the foot—that is, an intra-articular arthrodesis of the talonavicular, calcaneocuboidal and talocalcaneal joints—and, in addition, I have performed intra-articular arthrodesis of the ankle itself. Employment of the screw apparatus in these cases gives a compression of the resectional surfaces against each other, not only in the ankle but also in the talocalcaneal joint, whereas the consolidation in Chopart's joint is not influenced upon.

Also in isolated resection in the talocalcaneal joint, as employed sometimes in tuberculosis of this joint, the use of the screw apparatus ought to offer some advantage, it seems to me, even though I have not had occasion to employ it in such a case.

As pointed out already, the screw apparatus may be employed also in intra-articular arthrodesis of the knee-joint even though it here as a rule its employment here is not quite so significant as in arthrodesis of the ankle. In arthrodesis of the knee the consolidation usually proceeds relatively rapidly and dependably also without mechanical compression of the resectional surfaces. In arthrodesis of the knee it is not necessary to have such a strong and massive osseous consolidation as in arthrodesis of the ankle before the plaster is taken off, as the mechanical strain on the knee in walking is considerably less than that on the ankle. In arthrodesis of the knee there is not so much breaking strain on the site of the arthrodesis, the weight exerting its chiefly in longitudinal direction. Many surgeons let

patients with arthrodesis of the knee put weight on the extremity in plaster bandage before complete clinical consolidation has been established, and think that this practice promotes the consolidation. If this procedure is adopted in arthrodesis of the ankle, it is advisable to let the weight be placed on a walking hoop fastened in the plaster, for otherwise there may readily come a break in the site of the arthrodesis.




Fig. 3.

Even though osseous ankylosis as a rule forms relatively rapidly and firmly after intra-articular arthrodesis of the knee, the consolidation is still being promoted if the resectional surfaces are held firmly compressed against each other.

Pseudarthrosis may develop also after intra-articular arthrodesis of the knee even though this happens more seldom. But in certain cases—for instance, in deep and extensive tuberculosis, or extensive sclerosis, where relatively large parts of the articular surfaces have to be resected—it may be necessary to adopt particular measures in order to keep the ends of the bones in close apposition to avoid pseudarthrosis. For this purpose, use has been made of osteosynthesis of some sort or other, or elevation of the leg in vertical position, as in arthrodesis of the ankle. Instead of these various methods it may be of advantage to employ the screw apparatus described above and thus obtain a firm compression of the resectional surfaces.

Thus, after performance of intra-articular arthrodesis of the knee, I have drilled a Kirschner wire through the femur above the knee and another wire through the tibia below the knee. Then the limb is put in plaster, and fenestræ are cut in the plaster round the Kirschner wires. After this, a metal bow is applied to the upper wire, and another to the lower wire, by which the wires tightened. Finally the screw apparatus is applied so that the clutches of one pair of supporters take hold of the upper wire while the other pair of clutches take hold of the lower wire, inside the bows (see Fig. 3). By screwing the frame together then the resectional surfaces of the tibia and femur are pressed against each other. As it often will happen that the two wires do not run quite parallel or in the same plane, one of the supporters of the metal frame is made adjustable, up and down, back and forth, so that all the supporters can be placed on the Kirschner wires even if they are bored through the bone somewhat obliquely to each other.

After intra-articular arthrodesis of the knee in the presence of flexion contracture, the tightening of the posterior soft parts in straightening of the knee effectuates a firm compression of the resectional surfaces against each other, and hence it would be superfluous of course in such cases to employ the screw apparatus. The same applies to intra-articular arthrodesis of the ankle in the presence of plantar flexion contracture. In these cases the shortened muscles of the calf and Achilles tendon offer a certain resistance when the foot is set in the wanted position, pulling the talus up in the fork of the ankle and establishing a compression of the resectional surfaces.

By means of the screw apparatus here described, then, a strong compression of the resectional surfaces against each other may be obtained in the ankle, knee or talocalcaneal joint that promotes the osseous consolidation, and offers certain advantages above other methods employed for this purpose. It is true that employment of the screw apparatus complicates the operation somewhat, as the Kirschner wires have to be bored through the bone, but I think this trouble means but little in proportion to the advantages it offers.