

THE EFFECT OF A SINGLE VIOLENT TRAUMA ON THE SPINE OF THE DOG

By

HANS-JÖRGEN HANSEN and STEN-ERIK OLSSON

The rôle of trauma in the genesis of disc protrusions in man has been a subject of much discussion. *Beadle* (1931), *Barr* (1937), *Love and Camp* (1939), *Donohue* (1939), *Bradford and Spurling* (1947) and others put traumatic-mechanical factors in the foreground. In addition *Unander-Scharin* (1950) and *Junghanns* (1951) have mentioned the jolting effect of modern transport as a probable cause. However, research during the last few years (*Friberg and Hirsch* (1949), *Günther* (1949), *Stimpfl* (1950), *Jaeger and Grill* (1951), *Hirsch* (1951), *Bürkle de la Camp* (1951), *Kuhlendahl and Richter* (1952), and others) has more often emphasized those processes in the disc which precede and are a pre-requisite condition for a prolapse. As far as our domestic animals are concerned, disc degeneration in certain breeds of dog is in the first place a systemic disease dependent on constitutional factors, and the prolapses resulting from this degeneration appear in those parts of the spinal column which are subjected to the greatest mechanical stress (*Hansen* 1952).

Thus, if disc degeneration and disc prolapse in dog should only be attributed secondarily to traumatic-mechanical factors, there are cases in which a single violent trauma has caused the rupture of a disc, degenerated or not. It is for these cases that the diagnosis of "traumatological disc prolapse or disc rupture" should be reserved. Long before the disc-epoch, which was started by *Schmorl* (1928), and given additional impetus by *Mixter and Barr* (1934), such cases, belonging to pure traumatology, had been described in man (*Kocher* 1896, *Middleton and Teacher* 1911).

In order to throw further light upon the connection between trauma and disc injury we thought it desirable to investigate the effect of a single violent trauma on the spinal column. *Mayr* (1950) and *Bürkle*

de la Camp (1951) have stated, that a trauma on a completely sound human spinal column will more often result in a fractured vertebra than in a ruptured disc. We have framed our question thus: what will be the effect of a single violent trauma on the spinal column of dogs of different breed and age groups with reference to the relation between fractured vertebrae and ruptured discs?

MATERIAL AND METHODS

For humanitarian reasons a study of this kind could not possibly be conceived as an experimental one. Instead our material has consisted of 122 roentgenologically and/or pathologic-anatomically examined cases of dogs subjected to different kinds of violent traumata in accidents: animals run over by cars, fallen from heights, injured in fights, etc. The material was divided into two breed groups—chondrodystrophoid dogs, which are strongly disposed to disc injuries, and dogs belonging to other breeds, the non-chondrodystrophoid ones. A distinction was also made in each group between dogs of less than 1 year and dogs of 1 year or more. This limit between the groups was chosen because the coalescence in the epiphysial lines is, in the dog, completed at this age.

RESULTS

In this investigation attention was given only to discs and vertebral bodies, changes in the vertebral arches not being included. When estimating the relation between fractures of vertebrae and disc ruptures one must of course define a vertebral fracture as a fracture of the vertebral body, if the comparison is intended to show the general importance of the trauma in disc injuries. Table 1 shows the distribution of the material as regards type of injury, age and breed group of the dogs. This table shows that fractures in the vertebral body are about twice as frequent as disc ruptures. Table 2 shows a χ^2 -analytical comparison between the two breed groups. There is no statistical or even probable difference between the two breed groups concerning the ratio fracture of vertebral body-disc rupture. Table 3 shows a χ^2 -analytical comparison between young and old dogs. In this case there is a probable difference, fractures of vertebral bodies seeming somewhat more common in young dogs than in old ones.

A case of traumatical disc rupture in dog has been described in an earlier work (*Hansen* 1952). These disc injuries are characterized by a more or less total destruction of, above all, the *annulus fibrosus* and, in the most serious cases, a total loss of continuity in the intervertebral

TABLE 1

Type of injury	Chondro-dystrophoid dogs		Non-chondro-dystrophoid dogs		
	< 1 year	1 year and more	< 1 year	1 year and more	
Vertebral body fracture ...	6	10	33	30	79
Disc rupture	1	3	9	22	35
Vertebral body fracture + disc rupture		1	2	5	8
					122

TABLE 2

Type of injury	Chondro-dystrophoid dogs	Non-chondro-dystrophoid dogs
Vertebral body fracture	16	63
Disc rupture	4	31

$$\chi^2 = 2.58 \text{ (degrees of freedom = 1)}$$

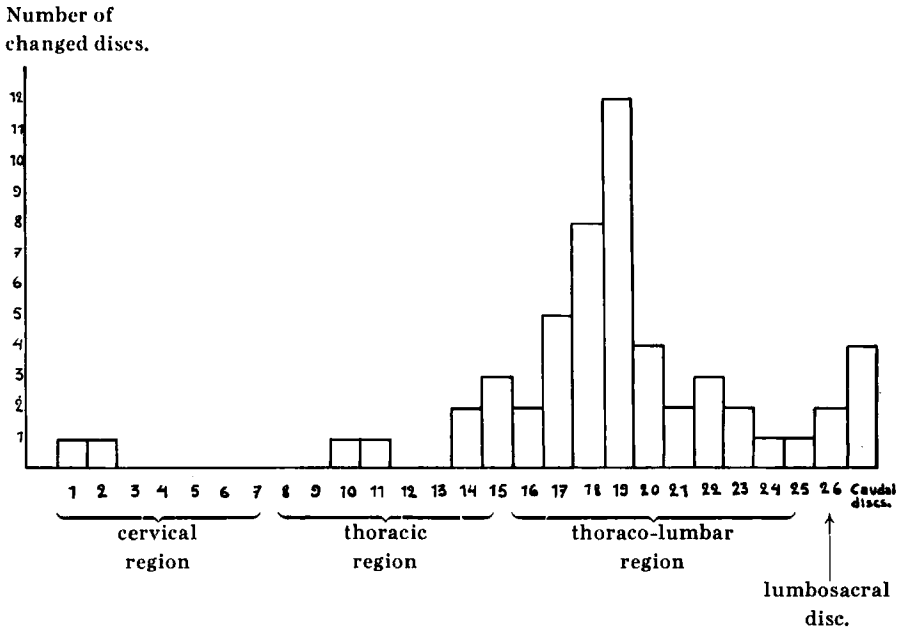
TABLE 3

Type of injury	< 1 year	1 year and more
Vertebral body fracture	39	40
Disc rupture	10	25

$$\chi^2 = 4.23^* \text{ (degrees of freedom = 1)}$$

space. This loss of continuity may result in a protrusion of the *nucleus pulposus*, a reduction in the width of the intervertebral space and a varying degree of luxation. Thus traumatic disc ruptures are not as a rule limited to the dorsal side of the *annulus fibrosus*. The location within the vertebral column of course depends on how the trauma strikes the body. However, Figure 1 shows an agglomeration of the cases to the thoraco-lumbar region in the same way as disc prolapses in systemic disc degeneration. But traumatic disc ruptures are also found in the thoracic and the caudal regions, which are otherwise free from disc prolapses.

Fig. 1.



DISCUSSION

The investigation has thus showed that a single violent trauma in the back of the dog will more often result in a fractured vertebral body than in a disc rupture. This tendency is more marked in young dogs than in old ones. These observations tally completely with the experience of *Bürkle de la Camp* in human traumatology. A great number of the fractures of the vertebral bodies in younger dogs is most likely to be classed as traumatic epiphysiolysis (23 % in our series) and the relatively greater vulnerability of the vertebral bodies is due to this fact, which can be statistically proved. The ratio between the resistance of the vertebral body and that of the disc to a trauma should thus remain unchanged with growing age. However, with increasing age the discs are subject to a successively increasing fibroid or chondroid metamorphosis together with degenerative changes. Thus, their absolute resistance to traumatic action must decrease. The unchanged relation between disc and vertebral body in this connection indicates that, with increasing age, the vertebral bodies, too, become more vulnerable to traumatic action. Concerning man, *Bick and Copel* (1950) have stated, that fractures of the vertebral bodies of old individuals should be regarded more or less constantly as "pathological fractures", i.e. fractures of bone that has been pathologically changed.

Furthermore, in our series the frequency of fractures of vertebral bodies compared to that of disc rupture after a single violent trauma is the same in the different breed groups. *Thus, the chondrodystrophoid breed group, which has been found to possess a pronounced disposition for disc degeneration and disc protrusion does not show a greater frequency of traumatic disc rupture in comparison to fractures of vertebral bodies than do other dogs.* So our investigation seems to show that the effect of a single violent trauma on the spine of the dog will be more often a fracture of a vertebral body than a disc rupture, and that age and breed are not significant factors.

Finally, the pathological anatomy of the traumatic disc protrusion only coincides in a few points with that of other disc prolapses. The consequences of a single violent trauma on the spinal column of the dog thus differ in every essential respect from the picture found in the most usual type of disc protrusion in dog.

S U M M A R Y

1. In the beginning the authors recall the fact that disc degeneration and disc prolapse in dog are, in the first place, a systemic disease and should only be attributed secondarily to traumatic-mechanical factors. The authors have made a roentgenological and pathologic-anatomical study on the relation vertebral body fracture—disc rupture in traumatic spine lesions in dog in order to throw further light upon the connection between trauma and disc injury. They have then applied the diagnosis “traumatic disc rupture” to cases in which a single violent trauma has ruptured discs, degenerated or not.

2. The result of the investigation indicates that the effect of a single violent trauma on the spine of a dog will more often be a fracture of the vertebral body than a disc rupture, and that age and breed are no significant factors in this respect.

3. The traumatic disc rupture also differs pathologic-anatomically from the most common type of disc protrusion in dog, viz. that found above all in chondrodystrophoid dogs and which may be traced back to a systemic disc degeneration.

R E S U M E

1. Au début, les auteurs rappellent le fait que la dégénération du disque et le prolapsus discal chez le chien sont en premier lieu une maladie systémique et doivent être attribués uniquement à des facteurs

traumatiques-mécaniques, en second lieu. Les auteurs ont procédé à une étude roentgenologique et anatomo-pathologique du rapport fracture du corps vertébral-rupture du disque dans les lésions traumatiques de la colonne vertébrale chez les chiens afin de mieux élucider la relation entre le trauma et la lésion discale. Ils ont alors posé le diagnostic « rupture traumatique du disque » dans les cas où un seul trauma violent a provoqué une rupture du disque, dégénéré ou non.

2. Le résultat de ces investigations indique que l'effet d'un seul trauma violent de la colonne vertébrale du chien est plus souvent une fracture du corps vertébral qu'une rupture du disque, l'âge et la race étant des facteurs insignifiants à cet égard.

3. La rupture traumatique du disque diffère aussi au point de vue anatomo-pathologique du type le plus commun de protrusion du disque chez le chien, constatée avant tout chez les chiens chondrodystrophoïdes et qui peuvent remonter à une dégénération systémique du disque.

ZUSAMMENFASSUNG

1. Im Beginn der Arbeit bringen die Verfasser die Tatsache in Erinnerung, dass Diskus Degeneration und Diskusprolaps in Hunden in erster Linie Systemerkrankungen sind und dass sie nur in zweiter Linie auf traumatisch-mechanische Ursachen zurückgeführt werden sollten. Die Verfasser haben röntgenologische und pathologisch-anatomische Untersuchungen über die Beziehung Wirbelkörperbruch-Diskusruptur in traumatischen Wirbelsäulenverletzungen bei Hunden vorgenommen um den Zusammenhang zwischen Trauma und Diskusverletzung weiterhin zu beleuchten. Sie haben die Diagnose "traumatische Diskusruptur" in jenen Fällen angewendet, in denen ein einziges heftiges Trauma eine Diskusruptur zur Folge hatte, gleichgültig ob dieser degeneriert oder nicht degeneriert war.

2. Das Ergebnis der Untersuchung zeigt, dass die Folge eines einzigen heftigen Traumas auf die Wirbelsäule des Hundes häufiger ein Bruch eines Wirbelkörpers als eine Diskusruptur sein wird und dass Alter und Rasse in dieser Hinsicht keine wesentliche Rolle spielen.

3. Die traumatische Diskusruptur unterscheidet sich auch pathologisch-anatomisch von der beim Hunde am häufigsten gefundenen Art von Diskusprolaps, nämlich jener, die vor allem in chondrodystrophischen Hunden gefunden wird und die auf eine generelle Diskusdegeneration zurückgeführt werden kann.

REFERENCES

- Barr, J. S.*: J. Bone Joint Surg. 19: 323, 1937.
- Beadle, O. A.*: The Intervertebral Disc. Med. Res. Council Spec. Rept. Ser. n:r 161. London 1931.
- Bick, E. M. and J. W. Copel*: Geriatrics 5: 74, 1950.
- Bradford, F. K. and R. G. Spurling*: The Intervertebral Disc. Ch. C. Thomas, Springfield, Illinois, 1947.
- Bürkle de la Camp, H.*: Arch. klin. Chir., 267: 479, 1951.
- Donohue, W. L.*: Am. J. Med. Sciences 198: 419, 1939.
- Friberg, S. and C. Hirsch*: Acta Orthop. Scand. 19: 222, 1949.
- Günther, E.*: Monatschr. Unfallheilk. 52: 257, 1949.
- Hansen, H.-J.*: A pathologic-anatomical study in disc degeneration in dog. Acta Orthop. Scand. Suppl. XI, 1952.
- Hirsch, C.*: Acta Orthop. Scand., 20: 261, 1951.
- Jaeger, F. and W. Grill*: Med. Monatschr. 5: 178, 1951.
- Junghanns, H.*: Arch. f. klin. Chir. 267: 393, 1951.
- Kocher, Th.*: Mitt. Grenzgeb. Med. u. Chir. 1: 415, 1896.
- Kuhlendahl, H. and H. Richter*: Arch. f. klin. Chir. u. Deutsch. Z. Chir. 272: 519, 1952.
- Love, J. G. and J. D. Camp*: J. Bone Joint Surg. 19: 776, 1937.
- Mayr, S.*: Wiener Med. Wschr. 100: 271, 1950.
- Middleton, G. S. and J. H. Teacher*: Glasgow Med. J. 76: 1, 1911.
- Mixter, W. J. and J. S. Barr*: New England J. Med. 211: 210, 1934.
- Schmorl, G.*: Zbl. f. Chir. 55: 2305, 1928.
- Stimpfl, A.*: Zbl. f. Chir. 75: 1528, 1950.
- Unander-Scharin, L.*: On low back pain, Acta Orthop. Scand. Suppl. V, 1950.