

DOUBLE-CONTRAST ARTHROGRAPHY OF KNEE WITH HORIZONTAL ROENTGEN RAY BEAM

By

LARS ANDRÉN and LENNART WEHLIN

Of the various methods of arthrography of the knee, the double-contrast technique is being used with increasing frequency despite the good results also obtained by positive contrast medium only (*Lindblom* and others).

Bircher (1931) was the first to describe double-contrast arthrography of the knee. Soon afterwards a somewhat modified method was used by *Oberholzer* (1933, 1938) in a large series. In 1951 and 1953 *van de Berg* and *Crèvecaeur* published comprehensive papers on the scope of the method. A variety of minor modifications have since been elaborated (*Candardjis et Saegesser*, *Wolfe*, *Ecoiffier*, *Philippon*, *Rüttiman*, *Leroux* and others). Common to these techniques is that all projections are made with the roentgen ray beam vertical.

This paper is concerned with some fundamental details in the double-contrast method, especially the use of a horizontal instead of a vertical beam.

TECHNIQUE

1. The knee is fluoroscoped and the direction of the plateau of the top end of the tibia is marked on the skin with the help of a metal rule.
2. Under local anaesthesia the knee joint is punctured, and any effusion as aspirated. Air and 10 ml. of water soluble contrast medium is injected until the joint capsule feels moderately distended.
3. The patient gets up, walks about, bends both knees a few times with and without body-weight on the affected limb. No preceding or subsequent passive flexing of the knee.
4. With the patient on his side on the examination table and with

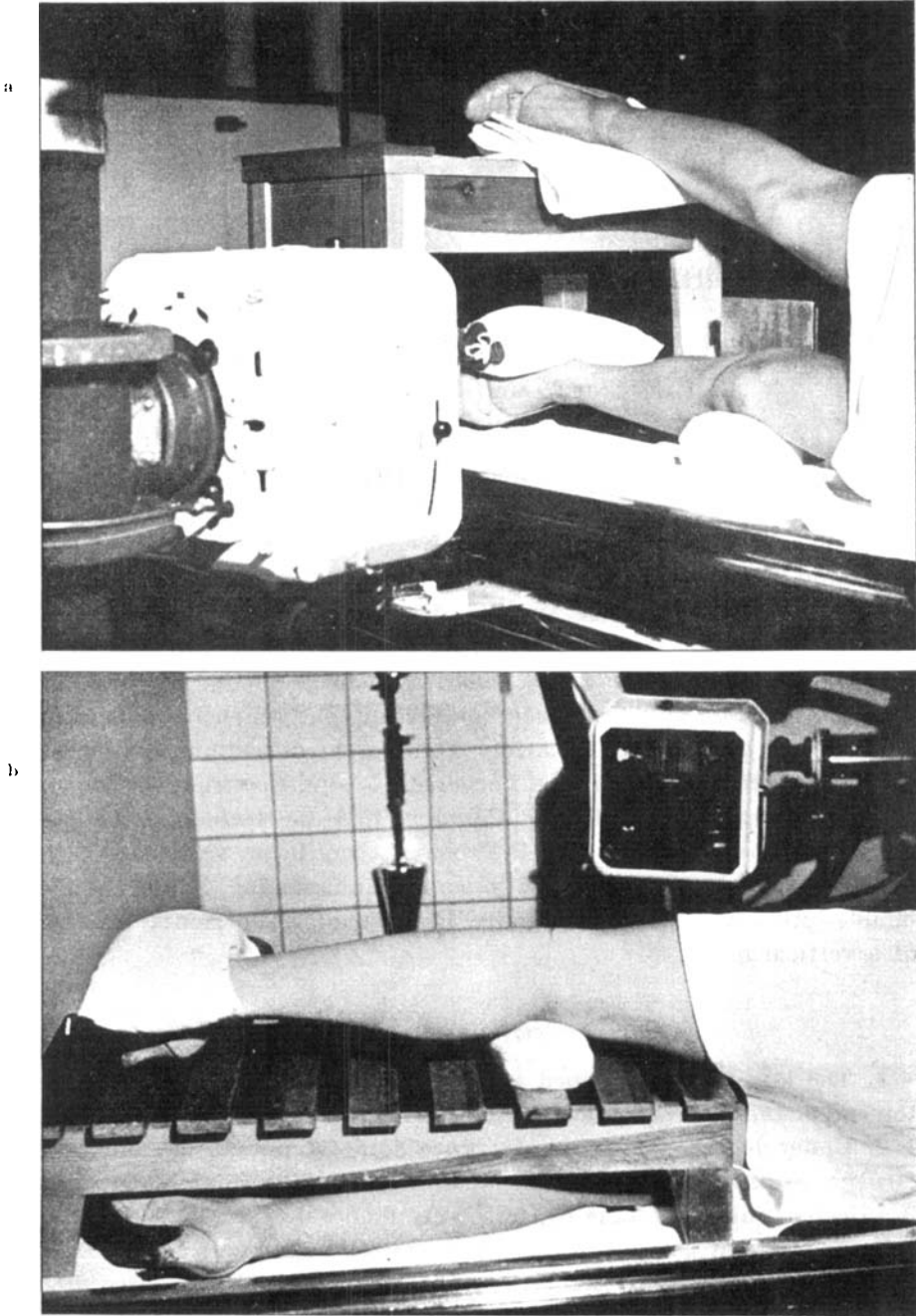


Fig. 1 a and b.

Equipment and position of patient during examination of a) medial and b) lateral meniscus.

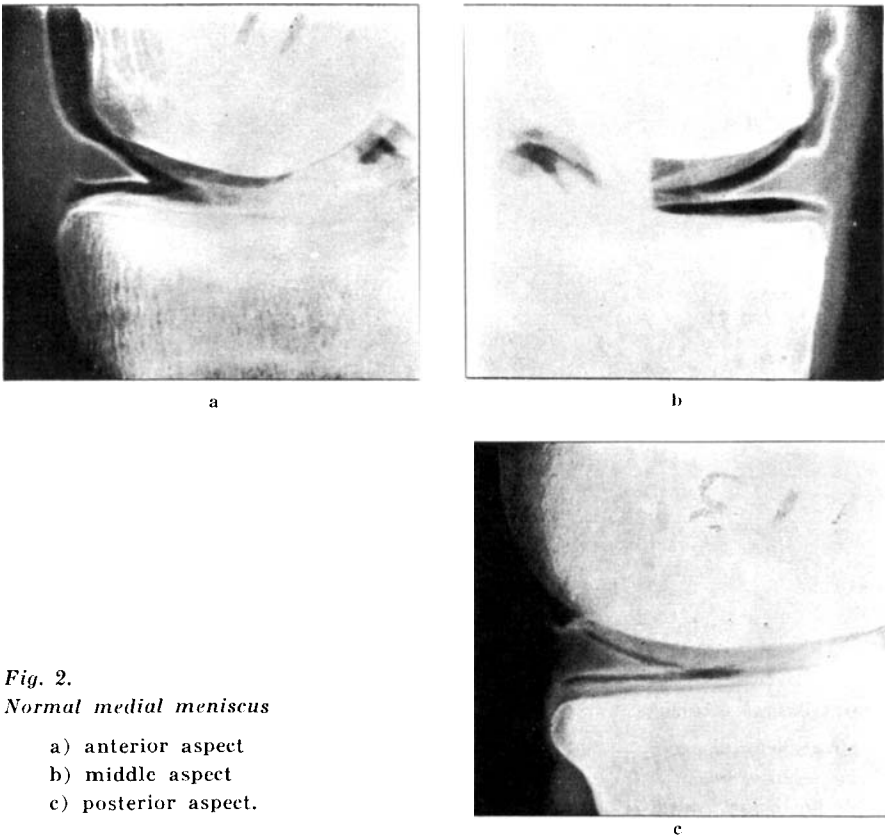


Fig. 2.
Normal medial meniscus

- a) anterior aspect
- b) middle aspect
- c) posterior aspect.

the meniscus to be examined uppermost a firm pad is placed under the distal end of the femur and a small sand bag on the ankle to separate the upper articular surface of the knee joint. No traction or bandage is applied.

5. With the beam horizontal and a film focus distance of 1 m. or more several exposures are made, the leg being rotated 10–15° between consecutive exposures. Film cassettes are placed directly against the knee. Inclusion of the capitulum fibulae in the film facilitates assessment of the proper degree of rotation of the extremity between consecutive films.

6. In order to study the entire joint space and the cruciate ligaments the examination is extended to include a lateral film taken with the beam vertical and possibly a supplementary film with the patient prone and the knee flexed.

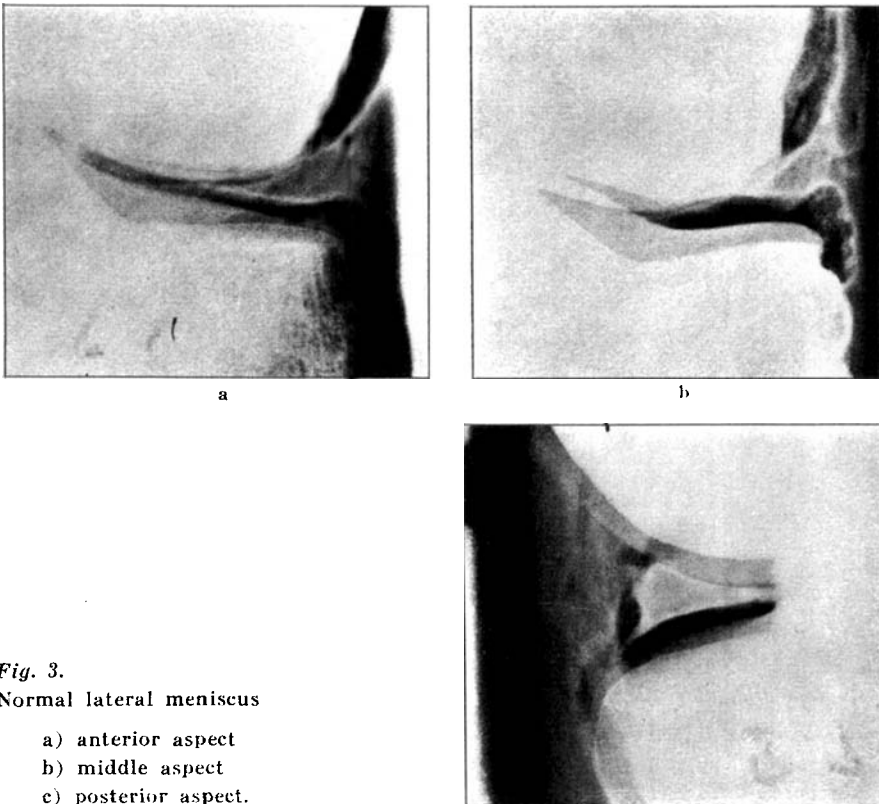


Fig. 3.
Normal lateral meniscus

- a) anterior aspect
- b) middle aspect
- c) posterior aspect.

The procedure for examination of the medial and lateral menisci is illustrated in Fig. 1.

COMMENTS

Since the slope of the plateau of the top end of the tibia varies in normal individuals the x-ray beam can only be properly centered under fluoroscopic control. By careful marking the slope on the skin the beam can be centered without repeated fluoroscopy between consecutive films.

The amount of air injected into the knee joint should be varied according to the size of the joint space, *i.e.*, only sufficient to produce moderate distension of the capsule and elastic resistance of the patella. Undue insufflation increases the risk of rupture of the capsule. To avoid deposition of contrast medium in the soft tissues, which would disturb interpretation of the film, air should be injected before contrast

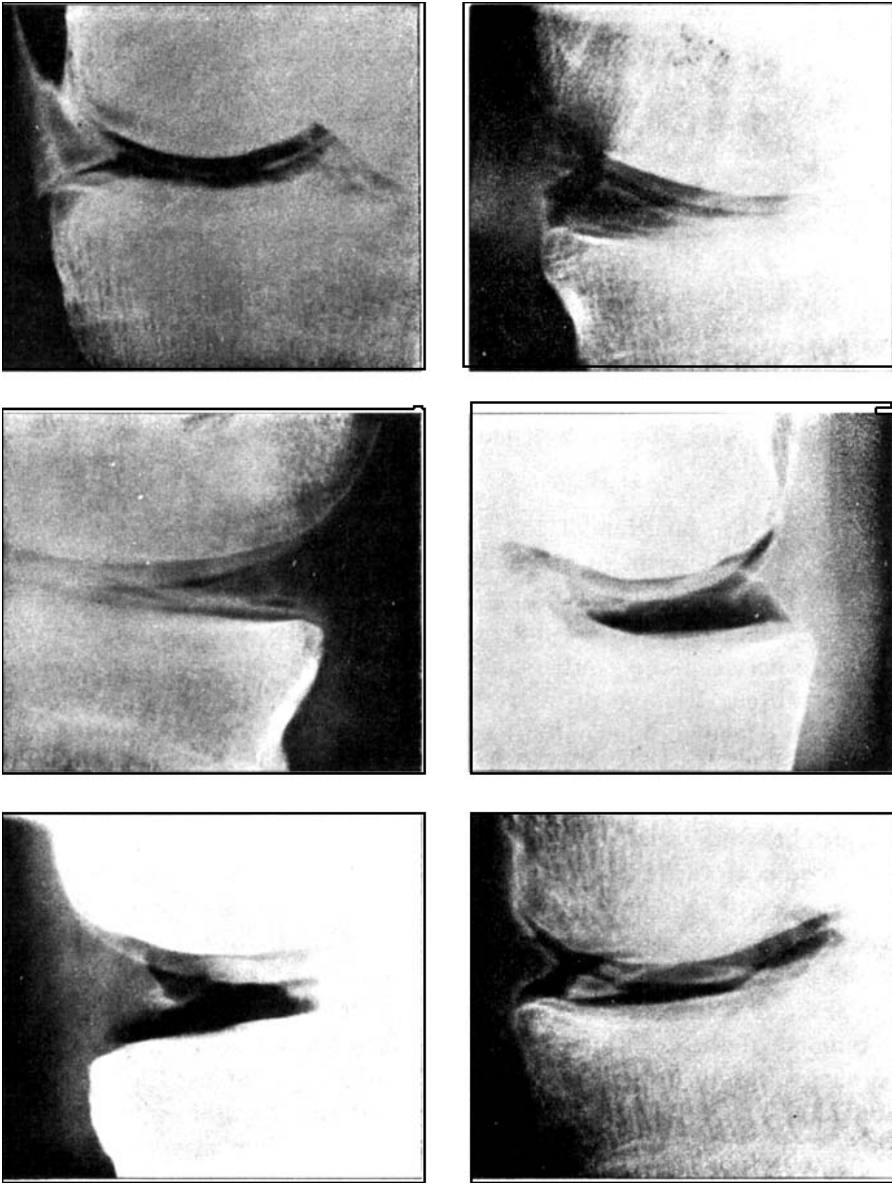
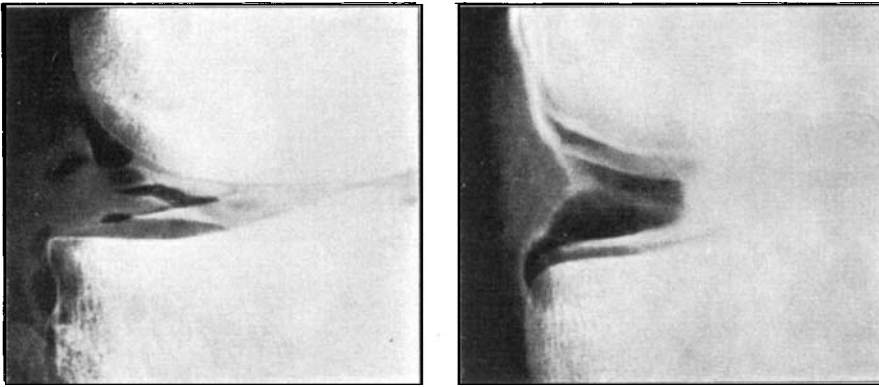


Fig. 4.
Examples of medial meniscal ruptures.

*Fig. 5.*

Examples of lateral meniscal ruptures.

medium if the position of the needle is doubtful. Any infiltration of the soft tissues with air is easily recognized by the typical crackling sensation on palpation.

If optimal contrast coating of the menisci is to be secured, intermixture between the contrast medium and the synovial fluid should be prevented. Passive or active movements in the lying position is therefore avoided. The patient instead stands up so that the contrast medium, being heavier than the synovial fluid, will settle and surround the menisci. Walking and active flexion of the leg with and without weight bearing on the affected side then expels synovial fluid from any meniscal ruptures, which are filled with contrast medium. The advantages of this procedure is most obvious in the examination of hydrarthrosis in which contrast medium otherwise adheres less readily to the menisci. In order to secure good definition of the entire meniscus the amount of contrast medium injected should not be too small.

If good quality double-contrast arthrograms are to be obtained, the meniscus should be lined with only a thin layer of contrast medium and surrounded by air. With the patient on his side and the joint spread, the air in the knee joint surrounds the then upper part of the meniscus while the contrast medium is settled. With the roentgen ray beam vertical the rays would pass through the disturbing underlying layer of contrast medium; with the tube horizontal, however, such superimposition is avoided.

The method requires no traction apparatus or assistant, since the necessary separation of the articular surfaces is more readily obtained

TABLE

Meniscus	Roentgen diagnosis		Op. findings	
	Rupture	No rupture	Rupture	No rupture
medial	{ 51	5	51	2
lateral	{ 11	3	11	2

by the procedure described, provided that care is taken that the knee is not flexed on rotation of the limb. A reasonably long film focus distance is required to secure good definition.

Of 250 patients examined since the full development of the method, 70 (14 lateral and 56 medial) have been operated upon.

It is clear from the table that in no instance did the method suggest a rupture that could not be verified at operation. Eight patients with a long history of typical symptoms without arthrographic changes were operated upon. Operation revealed ruptures in 4 of them but no meniscal changes in the other 4.

Of our total material rupture was demonstrated in 62 (94 %) of a total of 66 surgical ruptures of the meniscus.

It is difficult to compare methods not differing essentially in diagnostic error since the value of such procedures varies with the skill of the examiner and his experience with a given technique. Common to all examiners is, however, that the clearer the meniscus shows up the better are the prospects of making a correct diagnosis. This requirement is fulfilled most completely by the method described above, since it permits a true double-contrast examination of the menisci without overprojection of excess contrast medium (Figs. 2-5). The technique is easy and not time consuming, but as in other methods, great accuracy is necessary, since careful marking of the plateau of the top end of the tibia is essential for proper centering of the roentgen ray beam.

SUMMARY

A method of double-contrast arthrography of the knee is described. The essential features of the method are: horizontal roentgen ray beam, avoidance of intermixture between contrast medium and synovial fluid and a long film focus distance.

RESUME

Une méthode d'arthrographie du genou par double contraste est décrite. Les traits essentiels de la méthode sont: rayon roentgen horizontal, en évitant le mélange entre le contraste et le liquide synovial et une longue distance entre les foyers.

ZUSAMMENFASSUNG

Eine Methode von Doppelkontrastarthrographie des Knies wird beschrieben. Die wesentlichen Charakteristika der Methode sind: Horizontaler Röntgenstrahl, Vermeidung von Vermischung des Kontrastmittels und der Synovialflüssigkeit und eine lange Film-Fokusbildungsdistanz.

REFERENCES

- Bircher, E.*: Pneumoradiographie des Knies und der anderen Gelenke. Schweiz. med. Wschr. 50 (1931), 1210.
- Candardjis, G. et Saegesser, F.*: L'arthrographie du genou par la methode du double contraste. Radiol. clin. 22 (1953), 521.
- Ecoiffier, J.*: Arthrographie du genou. France med. 18 (1955), 3.
- Lindblom, K.*: Arthrography of the knee. Acta radiol. 1948, Suppl. 74.
- Leroux*: Sur la possibilité de réaliser simultanément une arthrographie opaque et une arthrographie mixte. Le Scalpel 3 (1958), 67.
- Philippon, J.*: Appareil et technique simples pour l'amélioration de la pneumoarthrographie du genou. J. radiol. et d'électrol. 36 (1955), 745.
- Oberholzer, J.*: Die Arthro-Pneumoradiographie. Beitr., Bruuns, f. klin. chir. 158 (1933), 113.
- Röntgendiagnostik der Gelenke mittels Doppelkontrastmethode. Georg Thieme Verlag, Leipzig, 1938.
- van de Berg, F. et Crèvecaeur, M.*: Etude anatomique et radiologique du genou arthrographie. J. belg. radiol. 34 (1951), 7.
- La meniscographie en série du genou. Acta orthoped. belg. 19 (1953), 304.
- Rüttiman, A.*: Die Doppelkontrastarthrographie des Kniegelenkes. Fortschr. Röntgenstr. 87 (1957), 736.
- Wolfe, T. F.*: Fundamentals and technizue of arthrography. Off. J. Amer. Soc. X-ray Technicians, 27 (1955), 171.