

ACTA ORTHOPAEDICA SCANDINAVICA
SUPPLEMENTUM No. XLVIII

*FROM THE ORTHOPAEDIC HOSPITAL OF THE INVALID FOUNDATION,
HELSINKI, HEAD: A. LANGENSKIÖLD, M.D. AND
THE DEPARTMENT OF PATHOLOGY, SECTION II, UNIVERSITY OF HELSINKI,
HEAD: PROFESSOR H. TEIR, M.D.*

COXA VARA INFANTUM

BY

PAULI V. PYLKKÄNEN

HELSINKI 1960

Translated by Eva Palmgren

PRINTED IN FINLAND BY
Mercatorin Kirjapaino
HELSINKI 1960

ACKNOWLEDGEMENTS

The theme of this investigation was suggested to me by my honoured former chief and teacher, the late Professor FABIAN LANGENSKIÖLD, M.D., who was Head of the Orthopaedic Hospital of the Invalid Foundation, Helsinki, until July 1956. He outlined the work and generously helped me in its initial stage. For many years before this, I had had the opportunity to become acquainted with his views and to profit from his extensive experience in the treatment of coxa vara infantum, a lesion which had attracted his interest for some length of time.

I am greatly indebted to Docent ANDERS LANGENSKIÖLD, M.D., my present chief, for his encouragement and critical advice during the various stages of my investigation. He has facilitated my work in many ways, and has given me the benefit of his extensive experience on problems relating to the growth of bone.

Professor HARALD TEIR, M. D., Pathological Department, Section II, University of Helsinki, has supervised the histological part of the investigation. I wish to express my sincere gratitude for his untiring guidance in the study of the histological specimens and for valuable help in various ways.

My thanks are also due to Dr. WALTER EDGREN, Head of the Roentgenological Department of the Orthopaedic Hospital of the Invalid Foundation, who kindly assisted me with good advice in the study of the roentgenograms.

In the initial stage of the work some of the histological specimens were prepared at the Institute for Pathology of the Canton Hospital, Zürich, Switzerland. For this I express my gratitude to the Head of the Institute, Professor E. UEHLINGER.

Helsinki, March 1960.

PAULI V. PYLKKÄNEN

CONTENTS

I INTRODUCTION	7
II SURVEY OF THE LITERATURE	8
Coxa vara infantum	8
Physiology, mechanics and statics of the hip joint	17
III PROBLEMS	21
IV MATERIAL AND METHODS	22
V PREOPERATIVE CLINICAL AND ROENTGENOLOGICAL INVESTIGATIONS	29
Case histories	29
Clinical findings	32
Roentgenological findings	35
VI HISTOLOGICAL INVESTIGATIONS	42
Normal postnatal development of the subcapital epiphyseal plate and the neck of the femur	44
The histopathology of coxa vara infantum	47
Comparison of the clinical, roentgenological and histological pictures	63
VII ETIOLOGY AND PATHOGENESIS	68
VIII TREATMENT AND ITS RESULTS	73
Indications for operation	73
Operative methods	74
Results of treatment	79
Untreated cases	103
IX DISCUSSION	104
X SUMMARY	111
XI REFERENCES	115

I INTRODUCTION

Many skeletal deformities in children and adults are due to disturbed growth of the bone. Investigation of the etiology and pathogenesis of these lesions as well as their treatment constitute important orthopaedic problems, in particular when the patient is a growing child.

Coxa vara infantum is a typical lesion of this kind. Attempts to clarify its etiology and pathogenesis have mainly been based on clinical and roentgenological studies. Many different operative methods have been described, and reports on the results of treatment have also been published. By contrast, very few histological investigations have been performed.

Since the lesion in question is closely related to the growth of the bone, I have tried to form an opinion on the course of development of the deformity in relation to growth. Hence I have studied the clinical and roentgenological features of the disease in different age groups, and in order to gain further insight into its etiology and pathogenesis I have also made histological investigations.

In children, operative results are significantly influenced by the steady growth of the skeleton. I have therefore especially studied the treatment of growing children and its results.

The literature contains only a few reports on the treatment of adults, particularly as far as patients with pseudarthrosis of the neck of the femur are concerned. On the basis of my series I have made an attempt to evaluate the possibilities of improving the situation in these neglected late cases.

II SURVEY OF THE LITERATURE

COXA VARA INFANTUM

CLINICAL AND ROENTGENOLOGICAL INVESTIGATIONS

The first clinical description of a lesion of the hip due to bending of the neck of the femur was published in 1881 by the Italian FIORANI. He described 15 patients, mostly children, who had been referred to him for treatment with a diagnosis of congenital dislocation of the hip. In these patients FIORANI observed a slight limp, which had commenced soon after the child had started to walk. He concluded that the disability was due to bending of the femoral neck, and suggested that it was caused by rachitic softening of the bone. At that time his report did not attract much attention, but when the condition had become better known through certain papers published by others, it was established that FIORANI had been the first to describe it. In 1888, MÜLLER published a report »Ueber die Verbiegung des Schenkelhalses im Wachstumsalter. Ein neues Krankheitsbild«, which drew the interest of the surgical profession to lesions of the hip due to bending of the neck of the femur. In the cases which he described it seems obvious that adolescent coxa vara was involved.

HOFMEISTER (1894) reported as many as 45 cases of bending of the femoral neck and suggested the name *coxa vara* for this condition. He assumed that it was not uncommon and that it had previously been erroneously ascribed to tuberculosis. His opinion was that the action of bodyweight was responsible for the deformity, which he thought developed in early childhood in connection with ordinary rickets or, more frequently, during puberty as a result of late rickets.

The first to describe a case of obviously congenital coxa vara was KREDEL (1896). He observed this condition in two children, aged 3 and 5 years, who also exhibited other malformations such as congenital pes equinovarus. KREDEL assumed that the deformity of the hip had also been present from

birth, although it had not been noticed on account of the presence of the other, more obvious abnormalities.

During these years reports on patients with coxa vara were published in increasing numbers. For the sake of clarity, R. WHITMAN (1899) suggested a classification of the different forms of the condition according to etiology.

In a paper called »Die angeborene Coxa vara» HOFFA (1905) gave a clinical and roentgenological description of coxa vara of childhood, which must be regarded as fundamental. He observed this condition in two children, aged 3 and 4 years. In the latter case, in which both hip joints were affected, he performed bilateral resection of the proximal portion of the femur because of marked limitation of movement of the hips. HOFFA examined histological specimens obtained by resection and came to the conclusion that in cases like these a separate type of coxa vara was involved, with its own features, and that the deformity was typically congenital. He stated that this condition had nothing to do with trauma or rickets, but should, on the other hand, be distinguished from cases of coxa vara in which other congenital anomalies were also present.

Subsequently the condition in question, described by HOFFA as a separate clinical entity, has attracted considerable interest, particularly amongst orthopaedists. Attention has been focussed on the question of its etiology, but a great deal has been written concerning its treatment, also. Since the lesion is relatively rare, most writers have reported only a few cases or relatively short series.

In 1906, HELBING reviewed the theories concerning coxa vara presented up to that time and reported 77 personal cases, 17 of which were congenital. In one case the proximal portion of the femur had been resected and histologically investigated by HELBING himself. He, too, subscribed to the theory of a congenital etiology.

At this time a large number of shorter papers on coxa vara were published, the majority being based on clinical and roentgenological study of a few cases only. Different explanations of the etiology were offered. JOACHIMSTAHL (1904) suggested that trauma was an etiological factor, and FROELICH (1904) that coxa vara of this type might be due to osteomyelitis without hyperthermia caused by *Staphylococci*. He collected punctates from the region of the femoral neck in patients with coxa vara and found that *Staphylococcus albus* grew in the specimens. BÖHM (1908) believed that the condition was an atavistic phenomenon. v. FRISCH (1908) put forward an etiological explanation similar to HELBING's, namely, that the cause of deformity was a disturbance of ossification which had a congenital background. MAYER

(1910), HOHMANN (1910) and SCHWARZ (1913) believed that the bending of the femoral neck was due to lack of space in the uterus or to pressure exerted by the uterine wall.

That rickets should be the cause of the condition was suspected from the beginning. This view was held by FIORANI (1881), LAUENSTEIN (1890), SCHULTZ (1892), HOFMEISTER (1894) and ELMSLIE (1907).

All these speculations concerning the etiology date to the time before World War I. During the war and for many years afterwards very little was written on the subject.

It was the problem of its etiology that again attracted the interest of investigators to this relatively rare lesion. NILSONNE (1924) reported a series of 5 cases which he had studied both clinically and roentgenologically. He concluded that congenital coxa vara develops as a result of a disturbance of ossification, the ultimate cause of which is a disturbance of the embryonic circulation in the region of the femoral neck.

KREUZ (1930) and ZIMMERMANN (1938) also regarded a disturbance of endochondral ossification, explicable on a congenital basis, as the most probable cause of the deformity. ZIMMERMANN'S series is one of the largest hitherto published, comprising 65 patients aged 1--18 years. He stated, however, that the evidence in favour of the theory of a congenital etiology could not be regarded as conclusive.

Other adherents to the view that a congenital etiology was involved were those writers who regarded congenital coxa vara as the first stage of a congenital defect of the femur. The first to proffer this explanation was DREHMANN (1910, 1911). Cases of coxa vara associated with a congenital defect of the femur had been described a couple of years earlier by JOACHIMSTAHN (1900) and REINER (1901, 1903). Similar views concerning the etiology have later been advocated by GOLDING (1948), LINDEMANN (1949), EXNER (1950) and BERNBECK (1954).

ERLACHER (1950) expressed the view that dysplasia of the hip was the true cause of congenital coxa vara. By dysplasia he meant congenital underdevelopment or maldevelopment. In his opinion this is the cause of many other pathological conditions of the skeleton, such as congenital short femur, congenital dislocation of the hip, Legg-Calvé-Perthes' disease and adolescent coxa vara.

Evidence in favour of a congenital etiology is afforded by the familial occurrence sometimes observed and, in particular, by the fact that the lesion in question has been diagnosed in identical twins. The occurrence of coxa vara in sibs or in parents and their children has been reported by FRANCKE

(1906), who observed this deformity in three siblings, by BARRINGTON-WARD (1912), LINDEMANN (1941, 1949), PEABODY (1943), LEMESURIER (1948), ALMOND (1956) and MAU (1958). In identical twins this condition has been described by DUNCAN (1938), MARTIN (1943), LINDEMANN (1941).

The theory of a congenital etiology has not, however, met with universal acceptance. As early as 1907, ELMSLIE stated that the unequivocally congenital cases, in which other congenital anomalies are also present, have a different etiology, whilst those cases in which the deformity only appears when the child begins to walk or during the first few years of life represent a separate condition. For this he used the name *coxa vara infantilis*. In his opinion the etiology of this condition was not fully understood. As possible causative factors he suggested accidents, birth trauma and rickets, whilst he considered softening of the bone and disturbed ossification as the immediate causes of the deformity, which was later aggravated by the mechanical influence of bodyweight.

The name *coxa vara infantilis* or *infantum* has subsequently been used by many writers in whose opinion the congenital etiology of the condition has not been established, and by investigators who have attributed the lesion to some disturbance appearing after birth. This denomination was employed by FAIRBANK (1928). He distinguished the congenital form from the infantile, which he also termed cervical *coxa vara*, since the entire neck of the femur is affected, to differentiate it from epiphyseal *coxa vara*. He regarded as an example of the congenital form a case which he had described one year earlier (1927). In this, the presence of the deformity in question was established immediately after birth, and in addition to *coxa vara*, a considerable shortening of the femur was observed in the same limb. FAIRBANK regarded infantile *coxa vara* as a separate condition with a typical clinical and roentgenological picture of its own. The cause of this deformity he considered to be «a developmental error», as a result of which a triangular piece of bone is usually found in the distal portion of the neck of the femur. In his opinion this triangular fragment ossifies from a separate centre. He described the clinical and roentgenological features and their treatment in 18 personal cases. ARMSTRONG (1935), too, regarded pathological ossification of the femoral neck as the most probable cause of *coxa vara infantum* and believed that the triangular fragment plays an important part in the development of the lesion. According to him, this fragment results when the neck of the femur grows in the wrong direction; a triangular piece of cartilage remains in the lower medial portion of the neck and then «degenerates» into bone.

A negative attitude to the theory of a congenital etiology was adopted by BADE (1933) and DUNCAN (1938). The latter used the denomination *developmental coxa vara*.

The essential role of bodyweight in coxa vara of childhood was emphasized by WALTER (1929, 1931, 1933). He regarded congenital coxa vara as a deformity due to excessive weight-bearing. In his opinion the transverse zone of rarefaction visible in roentgenograms of the femoral neck should be regarded as a so-called »Loosers Umbauzone». He stated that »it should not be considered a congenital deformity, but a physiological reaction of the bone to an unphysiological, shearing stress of weight-bearing». As strong evidence in favour of this view he adduced the fact that after subtrochanteric osteotomy, by which the abnormal line of transmission of weight is corrected, rapid healing occurs in the zone of rarefaction visible in the neck of the femur. A congenital lesion would not heal, as this condition often does, in as little as a few weeks. A similar view concerning the etiology was later adopted by SIMONS (1935), PAUWELS (1936), STAUSS (1938) and MAGNUSSON (1954). MAGNUSSON stated that »there does not seem to be any reason to doubt that the fissure is an insufficiency fracture, which at a later stage may proceed to a real pseudarthrosis.»

In regard to the etiology many writers have come to the conclusion that an osteochondritic process in the neck of the femur, resembling Legg-CALVÉ-PERTHES' disease, is involved. Adherents to this view are GUILLEMIN (1924), SCHMIDT (1927), HILGENREINER (1931) and GÖTIG & HERZOG (1932).

All the etiological explanations cited above, except those of HOFFA and HELBING, are based solely on clinical and roentgenological investigations.

HISTOLOGICAL AND EXPERIMENTAL INVESTIGATIONS

There have been very few histological investigations on coxa vara. This is obviously due in part to the rarity of the condition, in part to the fact that subtrochanteric osteotomy has been the operative method most commonly employed. Hence, it has not been possible to obtain specimens without unduly extending the operation.

The first histological investigation on coxa vara was performed by HOFFA (1905), who examined the resected proximal portion of the femur of a 4-year-old patient with congenital coxa vara. HOFFA detected nothing indicative of rickets or trauma. He established that the characteristic histological feature was the complete absence of any signs of growth. In the cartilaginous tissue the typical proliferating zone was lacking, the trabeculae did not

exhibit any growth by apposition, and the bone marrow did not resemble the bone marrow of growing individuals, but showed regressive changes resembling those physiologically occurring at a more advanced age. In brief, the bone lacked bioplastic energy. From all this HOFFA concluded that the most probable etiological explanation was that during intra-uterine life some bone disease had destroyed the growth capacity of the epiphyseal plate.

The next year (1906), HELBING made a similar histological examination of a specimen obtained by resection from a 4-year-old child. He found that the zone corresponding to the epiphyseal line had an irregular outline and that the cartilaginous cells were in complete disorder, without any trace of columnar arrangement. The trabeculae were thin and a peripheral layer of osteoblasts was lacking. HELBING concluded that the cause was a »vitium primae formationis«, manifesting itself after birth as complete absence of, or delay in, ossification.

Histological investigations of single cases were also performed by DELITALA (1913), BARR (1929) and ZADEK (1935). They all observed irregular or disturbed ossification in the subcapital epiphyseal plate of the femoral neck and dystrophic or atrophic changes in the metaphyseal bone. In regard to etiology they did not express any opinion.

The assumption that etiologically coxa vara infantum is an avascular necrosis of bone resembling Legg-Calvé-Perthes' disease was originally based on roentgenological and clinical investigations. The same conclusion was drawn from histological investigations by CAMITZ (1934), who took a specimen from the femoral neck of two children with coxa vara infantum and, in addition, studied a specimen obtained by resection of the proximal portion of the femur in a child who had died of pneumonia. He found that the histological picture corresponded to the previously published descriptions of Legg-Calvé-Perthes' disease. No signs indicative of rickets could be detected. The transverse zone of rarefaction visible in the neck of the femur was obviously an epiphyseal plate in which the process of ossification was disturbed. CAMITZ concluded that coxa vara infantilis and Legg-Calvé-Perthes' disease should be regarded as varieties of the same pathological condition.

Similar conclusions in regard to the etiology were drawn by BURCKHARDT (1946). He investigated histological specimens from the neck of the femur obtained from four adolescent patients in connection with operations. BURCKHARDT found that histologically the situation was characterized by a complex picture of bone formation and bone destruction. The main changes

had taken place in the medial portion of the femoral neck, which showed necrosis of the bone and its substitution by connective tissue and cartilage. Simultaneously, the formation of bone was observed in this site. This parallel degeneration and regeneration of bone is characteristic of the conditions resembling Legg-Calvé-Perthes' disease. In BURCKHARDT's opinion coxa vara infantum was therefore to be regarded as a form of aseptic osseous necrosis.

In addition to histological investigations, *animal experiments* have been performed in order to shed light on the nature of coxa vara infantum. Such experiments have been done by NAGURA & KOSUGE (1938) and NAGURA (1940). In growing rabbits these investigators were able to induce various forms of aseptic necrosis of bone. They traumatized the head or neck of the femur in the experimental animals in such a way that a limited subchondral fracture resulted. After the elapse of a few weeks or a month they observed that the fracture had not healed by ordinary bone formation, but that callous cartilage had first developed. Depending on the location, this was followed by different forms of aseptic osseous necrosis, such as Legg-Calvé-Perthes' disease, osteochondritis dissecans and a condition resembling coxa vara infantum. From his results NAGURA concluded that coxa vara infantum should be regarded as aseptic osseous necrosis and that this condition is traumatic in origin.

In 1948, BURCKHARDT performed experiments resembling those of NAGURA on growing rabbits, and arrived at a similar conclusion in regard to the etiology of coxa vara infantum.

COMPERE, GARRISON & FAHEY (1940) showed in animal experiments that when the epiphyseal plate of the head of the femur is traumatized, its growth is arrested and coxa vara results. Correspondingly, coxa valga can be produced by traumatizing the epiphyseal plate of the greater trochanter.

TREATMENT

In the majority of papers reviewed in the foregoing the treatment of the condition is also discussed, and late results of treatment are reported in some. Among the early writers FIORANI recommended antirachitic treatment, since he considered coxa vara to be due to rickets, and relief from weight-bearing by the use of crutches or a supporting bandage resting on the tuber ischii. In advanced cases he suggested the performance of osteotomy of the femoral neck or even shortening of the normal limb by osteo-

clasia. ELMSLIE recommended six to eight weeks' initial immobilization in a position of abduction and inward rotation and the subsequent use of a Thomas' splint for six weeks, at least. Traction therapy in the initial stage was tried by NILSONNE (1929) and LEMESURIER, but without any success whatsoever. LEMESURIER came to the conclusion that the zone of rarefaction visible in the roentgenogram was too firm to yield to traction. BADE found conservative treatment completely valueless, and ZADEK (1935) stated that it was definitely out-of-date.

Ever since the last century surgical correction of coxa vara infantum has been regarded by most writers as the only effective therapy. The first to attempt operative correction of a coxa vara deformity was KEETLEY (1888). The patient was a 20-year-old woman who had »rachitis adolescentium» — obviously adolescent coxa vara. KEETLEY performed subtrochanteric cuneiform osteotomy involving the removal of a wedge of bone, and thus brought about considerable improvement of the condition. KRASKE (1896) was the first to perform cuneiform osteotomy of the neck of the femur. Osteotomy of the femoral neck was soon abandoned, however, for the reason that the results were very poor. In 1899, WHITMAN reported that he had done subtrochanteric cuneiform osteotomy with good results in many cases of incipient coxa vara. According to HELBING, HOFFA, too, had employed subtrochanteric osteotomy from 1900 onwards. It should be mentioned that at the end of the last century and in the beginning of this, resection of the whole proximal portion of the femur was sometimes performed in children with coxa vara infantum. It is possible that the reason for this radical treatment was the suspicion that the lesion was tuberculous.

During the course of years a large number of different types of osteotomy have been elaborated, as appears from the fact that at the congress held by the German Orthopaedic Association in 1929, PITZEN was able to survey 22 different types of osteotomy described in the literature. According to him, most writers were satisfied with their own methods. Various modifications of subtrochanteric osteotomy have been most used. This technique was employed by SCHANZ (1923), PEABODY (1943), FAIRBANK (1928), LANGE (1937, 1951), JANEK (1937), DUNCAN (1938), POUZET (1938), PLATOU (1938), BURCKHARDT (1946), HORWITZ (1948), JOHANNING (1952) and MAGNUSSON (1954). Internal plate fixation in association with subtrochanteric osteotomy was employed by BLOUNT (1943, 1954) and BABB, GHORMLEY & CHATTERTON (1949).

Since in difficult cases, in particular, the results of subtrochanteric osteotomy have not been satisfactory, but have led to recurrences, many surgeons

have adopted the use of drilling of the subcapital epiphyseal plate or the application of a bone transplant through the epiphyseal plate. In this way closure of the latter is accomplished and exacerbation of the disability is prevented. An operation of this kind either alone or in combination with subtrochanteric osteotomy was employed by ZADEK (1935), LEMESURIER (1948), HORWITZ (1948) and HARK (1950). DUNCAN (1938) regarded the use of this measure in addition to osteotomy as unnecessary, since after osteotomy the epiphyseal plate mostly closes anyway. NOBLE & HAUSER (1926), on the other hand, considered subtrochanteric osteotomy to be futile, since the lesion inevitably soon recurs, and suggested that nothing should be done until progression has stopped. Then, they recommended the performance of a plastic operation on the hip or Lorenz's operation.

PAUWELS (1936), who did pioneering investigations concerning the static-dynamic conditions in the hip joint, also studied these relationships in cases of coxa vara infantum. He developed a personal technique of intertrochanteric osteotomy, the so-called Y-osteotomy. Good results with this method have been reported by many writers, for instance MÜLLER (1957).

A peculiar operative method was described by BRANDES (1924). It was based on the idea that the traction exerted by the gluteal muscles on the greater trochanter is a factor contributing to the varus position. By resection of the greater trochanter this muscular traction is eliminated, and as growth proceeds, the varus position is diminished. Subsequently, BRANDES (1929, 1930) published several papers on this method and reported good results. It was used by RICHTER (1937) in 7 cases of coxa vara infantum, and by MAU (1955) in 18 cases. According to the latter, this method is suitable only in the case of children aged 3—12 years, who have a slight degree of coxa vara. The operation is a minor one, and if no result is observable within a couple of years, final correction for the deformity can still be achieved by osteotomy.

Among late cases of coxa vara infantum, those in which pseudarthrosis of the neck of the femur has developed constitute a special problem. Very little has been written on their treatment, and most reports relate to one or two cases. In only a few papers have results of treatment been reported.

In this type of cases SCHANZ (1924) suggested the use of low osteotomy of the femur, which he employed in adult cases of congenital dislocation of the hip, in particular, and the removal of the detached head. DREHMANN (1911) reported that he had performed Lorenz's operation or subtrochanteric osteotomy alone, without removal of the head. In these papers the operative techniques have only been described in brief in connection with reports on the treatment of other, more common cases of coxa vara. BARR (1929) was

the first to suggest the use of Brackett's operation in cases of coxa vara infantum, but he himself did not try it.

HARK (1950) performed Whitman's reconstruction in 5 patients with pseudarthrosis. The results were discouraging. In no case was the post-operative mobility of the hip over 25° in flexion, and one hip became completely stiff, apart from a few degrees of passive movement. Nonetheless, he recommended the operation in these neglected cases, since stabilization of the hip is thus accomplished, although mobility is impaired.

ZAREMBA (1935), PITZEN (1950) and LIAN (1950) have each described an operative technique employed in one case.

F. LANGENSKIÖLD (1949) reported a series of 11 patients with pseudarthrosis, whom he had operated upon himself and followed up. In 5 cases he performed McMurray's osteotomy. In no case was the result good, and bony union was attained in only 2 cases. Owing to these unsatisfactory results he changed his method and did Brackett's operation in the subsequent 6 cases. The results were now much more encouraging. Bony union was attained in 5 cases, and in all patients the gait showed considerable improvement. But in most cases the mobility of the hip remained very limited. All these patients are included in the present series.

The series of coxa vara infantum reported have usually comprised relatively few cases. The largest series are the following: ELMSLIE: 20 cases, FAIRBANK: 18, DUNCAN: 31, ZIMMERMANN: 65 (in his paper the treatment is not described at all), JOHANNING: 30 and MAGNUSSON: 67 cases (including a follow-up of 47 operatively treated hips). MAGNUSSON's series has the additional advantage that the same operative method was employed in all cases, *i.e.* subtrochanteric osteotomy. In addition, the follow-up period was very long, *i.e.* an average of 16.4 years.

PHYSIOLOGY, MECHANICS AND STATICS OF THE HIP JOINT

In the pathogenesis, development and operative treatment of coxa vara infantum the growth phenomena and the static-mechanical and circulatory relationships in the hip joint play an important part. I have therefore collected from the literature certain data pertaining to these aspects of the problem.

Endochondral ossification of the proximal portion of the femur occurs to a considerable degree at the epiphyseal plate, which is seen in the newborn in the X-ray picture as a coherent line running through the distal portion

of the neck of the femur. With increasing age, this epiphyseal plate shifts in the proximal direction and is divided into the epiphyseal plates of the head of the femur and the greater trochanter. This shift of the border of ossification in the proximal direction, its division into two separate epiphyseal plates and the development of the ossific centres of the femoral head and the greater trochanter are shown in Fig. 1.

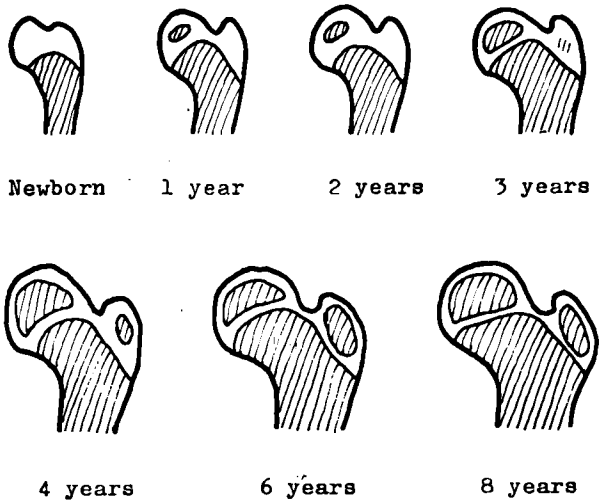


Fig. 1. — Normal configuration of the border of ossification in the proximal portion of the femur in children of different ages (according to Le Damany).

The proximal epiphyseal plate is responsible for one-third of the whole increase in length of the femur and the distal epiphyseal plate for two-thirds (BLOUNT 1954).

The shape of the proximal portion of the femur is to a considerable degree determined by the endochondral ossification occurring at the junctions between the metaphysis and the epiphyseal plates. A disturbance or premature arrest of the process of ossification in these epiphyseal plates gives rise to pathological conditions. As mentioned in the foregoing, this has been experimentally demonstrated by COMPERE, GARRISON and FAHEY. Relevant clinical and experimental observations made at the Orthopaedic Hospital of the Invalid Foundation in Helsinki have been published by LAURENT (1959) (cf. page 96 and Figs. 21 a and b).

Of the numerous investigations performed in order to elucidate the circulation in the proximal portion of the femur, the majority have been done

with a view to disclosing the etiological background of various pathological conditions, *e.g.* Legg-Calvé-Perthes' disease and adolescent coxa vara (WOLCOTT 1943, TUCKER 1949, TRUETA & HARRISON 1953, TRUETA 1957). According to these investigations, the head of the femur in children aged 4—14 years is supplied only by the vessels in the capsule. The blood supply through the ligamentum teres femoris, which immediately after birth is negligible, has no significance whatever during these years. From the age of 14 years onwards it again functions and contributes substantially to the nutrition of the head of the femur. During operative treatment of lesions of the hip in children, in particular, it is important to avoid injury to the capsular vessels.

A thorough acquaintance with the static and mechanical relationships in the hip joint is necessary for an understanding of the clinical picture in coxa vara infantum, and it is also important in operative treatment.

The mobility of the hip joint is influenced by the bony structure of the proximal portion of the femur, the ligament system of the hip joint and the function of the muscles of the hip region (STEINDLER 1955). In the upright position there is an angle between the neck of the femur and the diaphysis in the frontal plane, called the angle of inclination. This varies from 150° in the newborn to 120° in old age, being about 127° in adults (v. LANZ-WACHSMUTH). If this angle is greater than normal, coxa valga is present. In the horizontal aspect, too, there is an angle between the neck of the femur and the diaphysis, known as the angle of declination. Normally, there is anteversion, varying in degree from 4— 25° , depending on the age and sex of the subject (v. LANZ-WACHSMUTH). In coxa vara infantum this angle is smaller than the normal, or retroversion may even be present (STEINDLER, MÜLLER).

The restriction of movement typical of the coxa vara hip is essentially dependent on the size of these angles. Owing to the decrease in size of the angle of inclination the greater trochanter has shifted upwards towards the ilium. Hence, abduction of the femur is limited. Since in coxa vara the angle of declination is usually smaller than normal or retroversion is present, the diaphysis of the femur is to some extent rotated outwards relative to the neck of the femur, and owing to this, inward rotation of the hip is limited. According to STEINDLER, the decrease in size of the angle of declination or the retroversion causes tension of the ilio-femoral ligament and prevents complete extension of the hip. In severe bilateral coxa vara, extension of the hips is usually limited and compensated by marked lumbar lordosis.

In a coxa vara hip muscular function is limited chiefly for the reason that

the greater trochanter is elevated and the diaphysis of the femur to some extent outward rotated. In consequence of this, the function of the pelvitrochanteric abductor muscles, especially the gluteus medius, is weakened and causes a positive Trendelenburg's sign (v. LANZ-WACHSMUTH).

The strain to which the proximal portion of the femur is subjected when the extremity is used is the sum of the pressure of bodyweight and the tension of the pelvitrochanteric muscles. Muscle tension increases this strain many times over. According to PAUWELS (1951), INMAN (1947) and others, the pressure brought to bear on the head of the femur by standing on one foot is normally four times the bodyweight. In coxa vara this pressure is markedly smaller owing to decreased muscular tension. By contrast, the strain on the neck of the femur, which is both a shearing and a bending strain, increases with increase of the varus deformity (PAUWELS).

Acquaintance with these physical aspects contributes to the understanding of both the pathogenesis of coxa vara infantum and certain points related to its treatment.

III PROBLEMS

The purpose of the present investigation was to find an answer to the following questions:

What is the definition of coxa vara infantum in the light of case histories and clinical and roentgenological investigations?

What can clinical and roentgenological studies tell us about the course of development of the deformity during the growing period?

Are the histological changes observable in the metaphyseal portion of the femoral neck in children

- a) correlated with age and with the clinical and roentgenological findings, and
- b) do they warrant any conclusions regarding the etiology and pathogenesis of the condition?

What conclusions regarding the etiology and pathogenesis of coxa vara infantum can be drawn from clinical, roentgenological and histological investigations?

What are the results of treatment?

How are the results of treatment influenced by the patient's age, the type of lesion and the different operative methods, and what can be done to improve them?

IV MATERIAL AND METHODS

MATERIAL

The series comprises all patients with coxa vara infantum treated at the Orthopaedic Hospital of the Invalid Foundation, Helsinki, during a period of 15 years (1944—1958). The numbers of patients annually admitted appear in Table 1.

TABLE 1. — *Annual number of patients with coxa vara infantum treated at the Invalid Foundation during the years 1944—1958 (total 115).*

1944..... 1	1949..... 4	1954..... 8
1945..... 4	1950..... 9	1955..... 9
1946..... 2	1951..... 9	1956..... 11
1947..... 6	1952..... 9	1957..... 12
1948..... 12	1953..... 12	1958..... 7

TABLE 2. — *The patients with coxa vara infantum treated at the Invalid Foundation during the years 1944—1958 divided into children and adults, and operatively and non-operatively treated cases.*

	No. of patients			No. of hips with coxa vara infantum		
	Operated	Not operated	Total	Operated	Not operated	Total
<i>Children</i>	56	—	56	63	9	72
<i>Adults</i>						
No pseudarthrosis ..	18	6	24	22	21	43
Pseudarthrosis	32	3	35	33	6	39
Total	106	9	115	118	36	154

Table 2 shows the distribution of the whole series into adults and children, and into operatively and non-operatively treated cases. The series consists of a total of 115 patients with coxa vara infantum in 154 hips. Preoperative clinical and roentgenological investigations were done in all these cases. The adult patients numbered 59, the children 56. A total of 106 patients (118 hips) were operated upon, whilst 9 patients were discharged untreated.

The limit between adults and children I have drawn at the completion of longitudinal growth of the long bones, which is observable in the roentgenogram as ossification of the epiphyseal plates. This principle seems to be justified for the reason that coxa vara infantum is a disease mainly affecting the epiphyseal plate of the femoral neck and its activity. As long as the epiphyseal lines of the proximal portion of the femur are still open, the deformity may potentially progress. When these lines are fused, the lesion has attained its final stage.

In the majority of cases the limit between adulthood and childhood lay at 15 years. At this age the epiphyseal lines fused and length growth was thus completed. However, three patients under 15 years of age had to be classified among the adults, and one patient over 15 years old was found to belong to the group of children. The age of the patients on admission appears in Table 3.

TABLE 3. — *Age of patients on admission to hospital*

Children		Adults		
Age in years	No.	Age in years	No.	
2	1	14	3	
3	1	15	4	
4	4	16	2	
5	2	17	7	
6	4	18	3	
7	12	19	—	
8	5	20—24	17	
9	5	25—29	6	
10	9	30—34	8	
11	3	35—39	3	
12	4	40—44	4	
13	3	45—50	2	
14	2			
15	—			
16	1			
Total	56		59	115

Among the adults, two groups differing both clinically and roentgenologically may be distinguished, namely, patients with pseudarthrosis of the neck of the femur and patients who did not exhibit this condition.

All the 106 patients operated upon were summoned to follow-up examinations, which were mainly performed during the years 1957—1958. A total of 99 patients attended. However, three of the patients who did not attend

had visited the outpatients' department of the hospital some years after operation. Thus, the data and roentgenograms necessary for evaluation of the results of treatment were available. Four of the patients operated upon during the first few years of this investigation could not be reached or were not able to attend follow-up examination. Thus, the number of patients followed up was 102. In 12 of these cases bilateral operation had been performed, the number of hips with coxa vara infantum operatively treated and followed up being thus 114. See Table 4.

TABLE 4. — *Patients with coxa vara infantum operatively treated and followed up*

	No. of patients	No. of affected hips
<i>Children</i>	55	62
<i>Adults</i>		
No pseudarthrosis	15	19
Pseudarthrosis	32	33
Total	102	114

The follow-up period varied between one year and 13½ years, the average being 5 years and 8 months. The times in the different cases appear in Table 5.

TABLE 5. — *Follow-up period in operated cases*

Follow-up period in years	1	2	3	4	5—7	8—10	11—13	Total
No. of patients	14	18	7	17	23	17	6	102

Of the 114 hips with coxa vara infantum operatively treated and followed up, 69 were operated upon by Professor F. LANGENSKIÖLD, 11 by other surgeons working at the Hospital and 34 by me.

In connection with operation a specimen for histological investigation was taken from the metaphyseal portion of the neck of the femur in 25 children's hips.

For the purpose of comparison, post mortem specimens from the neck and head of the femur were taken from 19 subjects, aged 1 day to 20 years, with normal hip joints and no vascular or bone disease.

Of the present 115 patients with coxa vara infantum, 64 were males and 51 were females. The ratio is 1.3: 1. The corresponding ratios in the largest series published by others during the last few years are 1.7: 1 (MAGNUSSON) and 1.1: 1 (JOHANNING). By contrast, ZIMMERMANN'S series comprised slightly more females than males, the corresponding ratio being 1: 1.2. In the pub-

lication *Modern Trends in Orthopaedics* (1956), SCOTT treated the question of coxa vara infantum. From the literature in the English language he collected 165 cases described under the names congenital, cervical, infantile or developmental coxa vara. Of these, 85 were males and 80 females, the ratio being 1.1: 1. Obviously there is no clear difference between the sexes in regard to the incidence of this disease.

The present series comprises 74 unilateral and 40 bilateral cases. The ratio is 1.9: 1. In MAGNUSSON's series the corresponding ratio is 2.7: 1, in JOHANNING's 2.2: 1 and in ZIMMERMANN's 3: 1. The series collected by SCOTT comprises 105 unilateral and 60 bilateral cases, the ratio being 1.75: 1. The difference between the series may in part be due to differences in the criteria adopted for the diagnosis coxa vara. The milder and earlier the lesions included in the series, the larger is the number of bilateral cases. This is due to the fact that a slight deformity is clinically symptom-free, or the symptoms are trifling. It is often only revealed in connection with an examination performed on account of symptoms from the other hip.

Coxa vara infantum is a relatively rare lesion. In Norway JOHANNING tried to estimate its incidence and came to the conclusion that this was at least one per 25,000 live births.

The frequency of coxa vara infantum is also low as compared with the frequency of other orthopaedic lesions. During the years 1944--1958 the patients with this condition treated at the Invalid Foundation numbered 115, whilst the total number of orthopaedic cases was 13,902. The former thus constituted nearly 1 per cent.

In Canada LEMESURIER found that the ratio of patients with coxa vara infantum was 1 : 13 as compared with the number of patients treated for congenital dislocation of the hip during the same period. At the Invalid Foundation the corresponding figure for the above-mentioned period was 1 : 14.

METHODS

Of the present 115 patients with coxa vara infantum I have personally examined 46 preoperatively. The data regarding the preoperative state in the remaining 69 cases have been obtained from the hospital records. Of the 102 patients followed up I have personally examined 96.

The case reports from which data regarding the preoperative state were obtained in more than 50 per cent of cases were written by many different doctors. This lessens their value. However, attention had been paid to all the most essential points. Most reports contained data on the general con-

dition, the difference in length between the extremities, Trendelenburg's sign and the mobility of the hip.

The evaluation of the general condition included observations regarding the presence of rachitic symptoms. Blood studies and roentgenological examination of the epiphyseal region of the extremities were therefore performed in some of the children, but not systematically. The length of the extremities was measured from the anterior superior spine to the medial or lateral malleolus. In 18 cases data regarding the length difference possibly present were lacking. In 5 cases nothing was mentioned concerning Trendelenburg's sign. Mobility of the hip was measured with the goniometer employed in clinical practice at our hospital. With this the angle can be measured to within 5°. Usually attention was paid to extension, flexion, abduction, adduction and rotation. In 21 cases the data regarding mobility were deficient, in 4 entirely lacking.

In the cases which I have investigated myself the preoperative examination was performed in the same way as the follow-up examination.

At the follow-up investigation I again questioned the patients in order to make the case histories complete. At this examination I paid attention to the general condition, walking capacity, Trendelenburg's sign, the difference in length between the lower extremities and the mobility of both hips.

I measured the length of the lower extremities from the anterior superior spine to the medial malleolus. Mobility of the hip was measured with the patient supine on the examination table. Both active and passive mobility were measured, but without exception they were equal. This is quite natural, since the patients were young and mobile. Extension, flexion, abduction, adduction and rotation were evaluated. Rotation was determined with the hip in 90° flexion or, if this was impossible, in maximal flexion. The measurements were made with the above-mentioned goniometer.

On roentgenological examination both hips were recorded on the same film with the patient supine on the table with the lower extremities extended together in the horizontal plane and kept in 20° inward rotation or, if this was not possible, in maximal inward rotation. The X-ray beam was directed to a point above the symphysis, and the tube was kept at a distance of 110 cm. from the patient. In the majority of cases an exposure was also made with the patient in Lauenstein's position.

Exposures were made in this way from 1946 onwards, that is, in almost all of the present cases. The same radiologist, Dr. W. Edgren, has been in charge of the Roentgenological Department of the Hospital throughout this time.

All patients were roentgenologically examined both before operation and in connection with the follow-up investigation performed by me. In addition, exposures were made during operation, which shed additional light on the operative technique and the primary result. Furthermore, roentgenological examinations were made in all cases before discharge from hospital and in connection with follow-up investigations at the outpatients' department. Thus, I have been able to study the course of development of the condition up to the time of my personal follow-up examination.

In order to form an opinion on the course of the disease in these cases from the earliest possible stage, I sent for all available case reports and roentgenograms made at other hospitals. Thus, I obtained early roentgenograms of 15 children. The oldest X-ray picture was taken ten years before the patient came to the Invalid Foundation. In 11 cases I obtained case reports from the hospitals where the patients in question had previously been treated.

One object of the roentgenological examinations was to determine the width of the neck-shaft angle both before and after operation. When measurements are made on the basis of roentgenograms, it should be borne in mind that this angle is dependent on the projection in which the exposure is made. If in the frontal view the femur is horizontally positioned, the projection of the angle in question is dependent on the version of the neck of the femur and may thus deviate from the true angle. If, when the exposure is made, the femur is rotated so that the long axis of the neck also falls in the horizontal plane, the true neck-shaft angle is measurable directly from the frontal roentgenogram. Exact measurement of the angles of the femoral neck would require a lateral exposure made in a given way, in addition to the frontal exposure. Using certain diagrams, it would then be possible to calculate the exact values from the projections of the neck-shaft angle and the version angle of the femoral neck (BILLING, MÜLLER).

In the present investigation exposures were not made with a view to obtaining accurate measurements of the angles. However, when I studied the roentgenograms I came to the conclusion that in most cases the values for the neck-shaft angle measured from the frontal views are correct, or at least nearly correct. This is accounted for by the following reasons:

1. According to STEINDLER and MÜLLER, in the coxa vara infantum deformity the anteversion angle of the femoral neck is usually smaller than normal, or the neck has undergone slight retroversion. This finding was verified in the cases operated upon by myself. When the version angle of the neck is small, the projection of the neck-shaft angle in the frontal view

differs only slightly from the true angle. A projected neck-shaft angle of 90° , for instance, does not differ at all from the true angle, irrespective of the version of the neck. A projected angle of 110° differs from the true angle by only 2° if the neck is in 20° anteversion, and by 4° if the neck is in 30° anteversion in the frontal view (MÜLLER). The greater the deviation of the angle from a right angle, and the larger the version of the neck, the more do the projected values differ from the true values.

2. As mentioned in the foregoing, in the present investigation exposures were made in the same way in almost all cases. In the frontal view the femur was positioned horizontally and, if possible, rotated so that the neck, too, occupied a horizontal position. Under these conditions the subcapital epiphyseal plate is visualized as a zone with distinct borders or, if it is fused, as a single narrow line. If, by contrast, the neck deviates from the horizontal plane, the borders of the epiphyseal plate are indistinct or it is visualized as two separate lines. According to BILLING, this is due to the fact that the epiphyseal plate is perpendicular to the long axis of the neck of the femur. When I examined my roentgenograms from this standpoint I found that in almost all cases the femoral neck had been positioned in the horizontal plane, or deviated only slightly from this plane, during the frontal exposure.

For determination of the angles I only used those roentgenograms from which the true value for the neck-shaft angle was obtainable, or in which the error was obviously negligible.

V PREOPERATIVE CLINICAL AND ROENTGENOLOGICAL INVESTIGATIONS

Clinical and roentgenological data regarding the preoperative state have been collected and are here presented with two principal ends in view:

Firstly, I wanted to disentangle certain essential points relating to the development and advance of the coxa vara infantum lesion. This could only be done on the basis of a relatively large series. The data relating to case histories tabulated in Tables 6 and 7 and the clinical and roentgenological observations presented in Tables 8, 10, 12 and 13 have been collected from the whole series, and not only from the cases followed up.

Secondly, I wanted to form an opinion on the preoperative state in the cases which were followed up. The data shown in Tables 9 and 11 relate to this shorter series and are therefore comparable with those relating to the postoperative state.

CASE HISTORIES

The relevant data are listed in Tables 6 and 7.

TABLE 6. — *Diagnosis of lesion on the basis of case history* *

Age in yrs. when lesion was observed	Soon after birth	1	2—3	4	5	6	7	8	9	Over 9	No data	Total
No. of patients	9	32	13	16	9	10	10	—	3	—	13	115

* whole series

In none of the cases where, according to the parents, the lesion had been »observed» soon after birth had a roentgenological examination been made before the child started to walk, the reason obviously being the absence of symptoms. In all these cases the »observation» only meant that the parents believed that the deformity had been present since birth.

TABLE 7. — Data regarding case histories *

	Children (56 pa- tients)	Adults (59 patients)		Total (115 pa- tients)
		No pseud- arthrosis (24 pa- tients)	Pseud- arthrosis (35 pa- tients)	
Familial occurrence	1	1	—	2
Other hip lesions (<i>e.g.</i> Legg—Calvé— Perthes, congenital dislocation of hip) in the family	5	—	—	5
Other diseases of bone (<i>e.g.</i> rickets) previously	2	—	—	2
First symptom				
limp	52	23	28	103
other (<i>e.g.</i> increased lumbar lordosis, shortening of the limb)	4	1	7	12
Accident sustained by the hip before lesion was observed	4	2	3	9
Pain in the hip				
at rest	—	1	1	2
after short walks	2	8	20	30
only after strain	15	2	12	29
No pain	39	13	2	54
Uses walking-stick	—	1	7	8
» arm-crutches	1	—	3	4
Working capacity				
hard manual labour	—	1	3	4
light manual or intellectual work	—	23	27	50
only sedentary work	—	—	5	5
Previously treated elsewhere				
conservatively (in childhood)	7	6	7	20
operatively	1	—	3	4
reduction attempted	1	—	—	1

* whole series

In 2 cases only was the abnormality familial, namely, in a father and his son (nos. 31 and 27). The former had bilateral coxa vara infantum. In 5 other cases near relatives of the patient had some lesion of the hip other than coxa vara infantum, *i.e.* Legg-Calvé-Perthes' disease in 3 and congenital dislocation of the hip in 2 cases. The expression familial occurrence is here used to mean that the lesion was diagnosed in the patient's siblings, parents or children.

Hip lesions in relatives were thus present in a total of only 7 cases, and coxa vara infantum was involved in only 2 of these. In all the cases followed up by me, I checked this point, but without being able to detect any further instances. As already mentioned in the survey of the literature, a few sporadic cases of familial occurrence of coxa vara infantum have been reported. It seems obvious that heredity is of little importance in this disease.

The accident to which the parents sometimes attributed the lesion was in all cases relatively slight, the statements »stumbled on the floor», »fell from a chair», being typical. In no instance was immediate medical aid sought for this reason.

In childhood, the relative or complete absence of pain is in clear contrast to the roentgenological changes, which are often marked. Pain in the hip was present in only 17 cases out of 56. Nearly all patients with pseudarthrosis had pain. When I questioned them closely regarding the time of onset of the pain, I found that in over fifty per cent of cases (21 out of 35) pain had been present before puberty. It may be that in these cases the lesion had been relatively severe even in childhood and consequently led to the development of pseudarthrosis at the end of the growing period. Six patients with this condition had a clear history of trauma during puberty. After the trauma a slight limp already present had become worse and the extremity had gradually become shorter. Obviously a fracture of the osteoporotic femoral neck had been sustained, or complete detachment of the fibrotic pseudarthrosis had occurred. Of the adult patients without pseudarthrosis only 4 out of 24 had had pain before puberty.

The fact that only a small number of patients used a walking-stick or crutches is striking. Even when the lesion was objectively severe and pain was present the patients walked without any aids.

The working capacity of the patients, particularly those with pseudarthrosis, was clearly affected by the lesion. Nonetheless 3 of the patients with pseudarthrosis did heavy agricultural work (digging of ditches, lumbering, etc.). In children it is difficult to evaluate working capacity. Apart from one patient who used crutches, they all moved about well and were able to go to school.

Twenty-five patients had previously been hospitalized elsewhere. Of these, 19 had been kept in traction or in plaster of Paris. In one case had only rest and medical supervision been prescribed. Two patients had been kept in bed at a tuberculosis sanatorium on suspicion of tuberculosis of the hip. In 4 cases the hip had been operated upon, but without success. One of these patients was a child who, at the age of six, had been kept in traction

at a provincial hospital. On account of the war he was subsequently evacuated to a foreign country, where subtrochanteric osteotomy was performed. The varus position did not improve, however, and pseudarthrosis developed at the site of the osteotomy. In one young patient reduction had been attempted at a provincial hospital, resulting, however, in pseudarthrosis of the neck of the femur.

CLINICAL FINDINGS

Some clinical observations are tabulated in Table 8.

TABLE 8. — *Preoperative clinical observations* *

	<i>Children</i> (56 patients 72 affected hips)	<i>Adults</i> (59 patients 82 affected hips)		<i>Total</i> (115 patients 154 affected hips)
		No pseud-arthrosis (24 patients 43 hips)	Pseud-arthrosis (35 patients 39 hips)	
<i>General condition</i>				
cleido-cranio-dysostosis	1	—	—	1
signs of rickets	—	—	—	—
obesity	2	2	—	4
poor general condition (anaemia) ..	1	—	—	1
<i>Lower extremities</i>				
crura vara	3	1	—	4
crura valga	1	2	2	5
<i>Trunk</i>				
marked lumbar lordosis	13	7	10	30
scoliosis	—	3	6	9
<i>Trendelenburg's sign</i>				
negative	9	—	—	9
slightly positive	9	4	—	13
markedly positive	53	34	40	127
no data	1	3	1	5
Contracture of hip	32	21	31	84

* whole series

In one case (no. 98) typical cleido-cranio-dysostosis was present. The patient lacked both clavicles and the rami ossis pubis. Both hips showed typical coxa vara infantum.

In 3 children slight crura et femora vara were observed. All these cases were investigated by myself. Blood studies and a comprehensive roentgenological examination of the extremities revealed no signs indicative of rickets or other disease. Four adult patients and one child (the same who had cleidocranio-dysostosis) showed a relatively marked degree of genu valgum. Trendelenburg's sign was positive in all hips which were operatively treated. In the 36 hips not operated upon it was positive in 27 and negative in 9.

The shortening of the affected extremity in the children is shown in Table 9.

TABLE 9. — *Preoperative length difference of lower limbs in children **

Patients'		Length difference of lower limbs in cm.							
age in years	no.	0	1	2	3	4	5	No data	Mean
2—4	6	—	2	2	—	—	—	2	1.5
5—7	17	1	7	5	2	—	—	2	1.5
8—10	19	2	4	6	4	—	1	2	1.9
11—12	7	—	1	—	3	1	—	2	2.8
13—16	6	—	—	1	1	3	1	—	3.7
Total	55	3	14	14	10	4	2	8	2.1

* only cases operatively treated and followed up

In respect to 8 children data regarding the length of the extremity before operation are lacking. At the follow-up examination the length difference was found to be 2—4 cm. In Table 9 I have classified the children by age groups on the principles recommended by GORF (1952) for use in studies of orthopaedic lesions in children. GORF's classification is as follows:

1. Babyhood 1— 2 years
2. Preschool age 2— 4 »
3. Early childhood 5— 7 »
4. Transitional age 7—10 »
5. Preadolescent stage 11—12 »
6. Adolescence 13—19 »

When classifying my series I have made a couple of changes in this system, aiming at a more accurate distinction of the different groups: In group 4 I have included children aged 8—10, and in the last group only those who were still growing. In my series the oldest child of growing age was 16. It appears in the table that the length deficiency of the affected extremity increases with age. The mean deficiency in the children was 2.1 cm.

In the adult patients without pseudarthrosis the length difference in the extremities varied between 3 and 7 cm in all cases but one, in which severe hypoplasia of the femur was present. In this case the length difference was 10 cm. In addition, the knee of the affected extremity showed a marked valgus deformity, due to hypoplasia of the lateral condyle of the femur. It seems obvious that in this case the defect was congenital short femur, such as has been described by GOLDING ((1938), among others. The mean length difference in the patients without pseudarthrosis was 4.8 cm.

In the adult patients with pseudarthrosis the length difference of the extremities was somewhat larger, varying between 3 and 9 cm, the mean being 5.5 cm.

In coxa vara infantum, mobility of the hip is clearly limited in both children and adults. As a rule, abduction and inward rotation show the greatest limitation, hyperextension and outward rotation being influenced to a lesser degree. Flexion and adduction are normal or only slightly limited. In order to obtain a more accurate measure of mobility I calculated Gade's mobility index (GADE 1947) for the different cases. The last to use this index in Finland was KALLIO (1958) in an investigation concerning arthroplasty of the hip. JOHANNING used it in a study of coxa vara

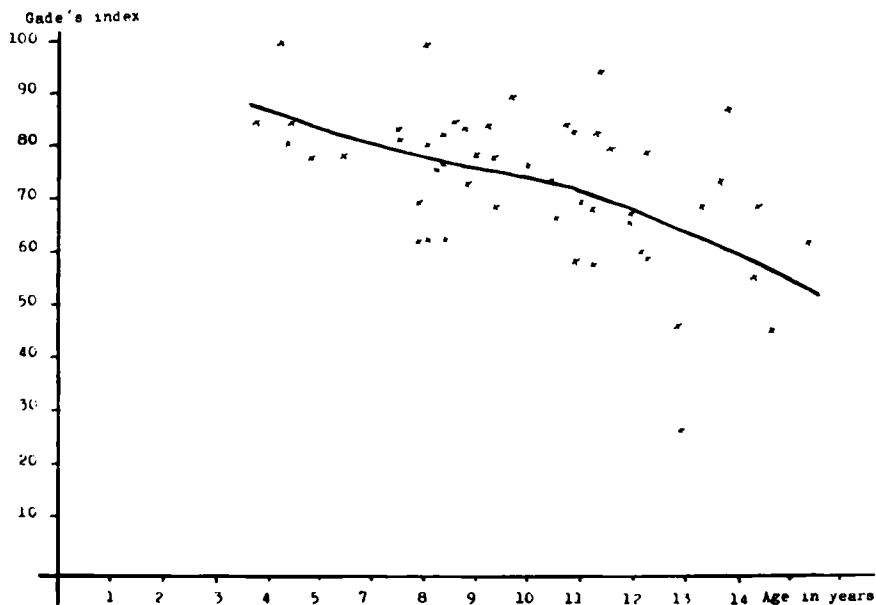


Fig. 2. — Gade's index in children before operation.

infantum. Since this index is well known, I have no reason to describe the method for its calculation here. Normally, Gade's index is about 100 in young people.

Since in over fifty per cent of cases in the present series the preoperative clinical data were obtained from various hospital records, the indices calculated may not be correct. Certain movements have not been checked in all cases. Data regarding hyperextension, for instance, are lacking in most of the case reports. The values obtained are probably somewhat lower than the true index.

Fig. 2 shows the relation between Gade's index and age. It is seen that during the growing period this index steadily decreases with age. In the children the mean index is 73, in the adult patients with pseudarthrosis 54, and in those without pseudarthrosis 48.

ROENTGENOLOGICAL FINDINGS

Every patient in the present series underwent roentgenological examination on admission to hospital. In the 115 cases, coxa vara infantum was established in 154 hips, *i.e.* in 72 hips of children and 82 of adult patients. As stated in the foregoing, the distinction between adults and children was drawn on the basis of closure of the epiphyseal lines as revealed by the roentgenograms. The division of the adults into patients with and without pseudarthrosis was also mostly made on the basis of the roentgenological findings, although the operative finding was decisive in this respect.

On examination of the roentgenograms of children I found that in the majority of cases certain roentgenological changes persisted throughout the growing period, whilst others occurred only at a given age.

In Table 10 I have tabulated certain significant observations on the roentgenological changes in the patients of growing age. The main changes were seen in the neck and head of the femur and in the acetabulum. The cases are classified in the same age groups as in the section dealing with clinical findings. The evaluation of the roentgenological findings and their gradation was based on the following principles:

The structural changes in the neck of the femur I regarded as slight when the rarefaction of the bony tissue laterally of the subcapital epiphyseal line, typical of the coxa vara infantum lesion, was only of slight degree and when this change of the tissue did not include the whole of the metaphysis of the femoral neck. Severer changes were regarded as marked.

The shortening of the neck of the femur I classified as slight when the neck was less than one-fourth shorter than that of the normal extremity. When the length difference was greater, I regarded the shortening as marked.

The head of the femur was regarded as deformed when its surface was uneven or its diameter, drawn through the epiphyseal line or perpendicularly to it, was obviously either longer or shorter than that of the other extremity or, in bilateral cases, than the normal.

The presence of decalcification was evaluated by comparing the bony tissue of the head of the femur with that of the normal extremity or that of the pelvis.

The shallowness of the acetabulum was evaluated by measuring the angle formed by its roof with the vertical plane. If this was larger than in the unaffected extremity or clearly larger than the normal, the acetabulum was regarded as shallow. The normal values are 15° in subjects aged 3—15 years, 10° or less in older subjects (MÜLLER).

Slight structural changes of the neck of the femur and a slight shortening of the latter were present in the four youngest age groups. The largest number of patients with such changes are found in the age group 5—7 years.

A vertical zone of rarefaction in the femoral neck was observed in the majority of cases in all age groups. It is possible that this finding would be still more frequent if roentgenograms had been taken with the neck of the femur in different positions of rotation.

A triangular fragment in the distal portion of the femoral neck was observable until the age of 10. In the youngest age groups this finding was commonest and the fragment most clearly discernible as a separate piece. In the older groups it was less clearly visible, and finally it was entirely fused with the neck or head of the femur.

In 4 patients over 10 years old the subcapital epiphyseal plate was closed and the neck of the femur had become ossified before the end of the growing period.

In only one child was the head of the femur entirely detached from the neck. This was due to an attempt at reduction performed at another hospital. In the whole series there is no case in which a pseudarthrosis of the femoral neck observed during the growing period could be ascribed solely to progression of the lesion, and I have found no such case in the literature, either.

Deformity of the head of the femur and decalcification were found to increase with age. As a rule, atrophy was present only in the distal portion of the femoral head. These changes were the more marked the larger the varus angle and the severer the changes in the neck of the femur.

TABLE 10. — *Roentgenological changes in children classified by age groups (72 affected hips) **

Age groups	No. of hips	CHANGES									
		In the neck of the femur						In the head of the femur		In the acetabulum	
		Structural changes		Shortening of neck		Vertical fissure	Triangular piece	Ossification completed	Marked deformity	Marked calcareous atrophy	Shallow
		slight	marked	slight	marked						
2—4 yrs.	8	1	7	1	7	8	8	—	3	3	2
5—7 "	26	6	20	6	20	20	17	—	8	11	9
8—10 "	24	1	23	1	23	16	10	—	10	12	10
11—12 "	8	1	7	1	7	5	—	2	6	4	5
13—16 "	6	—	6	—	6	4	—	2	6	4	6
Total	72	9	63	9	63	53	35	4	33	34	32

* whole series of children

TABLE 11. — *The neck-shaft angle before operation in children and adult patients without pseudarthrosis according to age groups (62 + 19 = 81 affected hips) **

Age groups by yrs.	No. of cases	Neck-shaft angle									Mean
		20—30	30—40	40—50	50—60	60—70	70—80	80—90	90—100	100—110°	
2—4	6						1	1	3	1	88°
5—7	20				1	2	8	6	2	1	76°
8—10	23				1	5	7	5	4	1	76°
11—12	7				4		1		2		67°
13—15	10			3	2	2	2	1			58°
16—19	4	1				2	1				56°
20—29	4			1	3						49°
30—46	7	1	1	1	2	2					47°
Total	81										

* only cases operatively treated and followed up

TABLE 12. — *The CE angle **

	No. of hips	CE angle			
		<15°	15—19°	20—25°	>25°
Children	72	5	16	47	4
Adults					
No pseudarthrosis	43	24	11	3	5
Pseudarthrosis	39	36	3	—	—
Total	154				

* whole series

With increasing age, the acetabulum was found to become shallower than normal. It was shallow in the majority of over 10-year-old patients. Obviously the shallowness of the acetabulum is a secondary phenomenon, due to incorrect weight-bearing.

The most typical roentgenological change in coxa vara infantum is the bending of the neck of the femur into the varus position. In many cases, although not invariably, the width of the varus angle gives a good idea of the degree of severity of the lesion. In order to evaluate the degree of the varus deformity I determined the neck-shaft angle as suggested by MÜLLER, taking as one side of the angle the axis of the femoral neck drawn from the centre of the femoral head so that the neck is bisected and as the other side the long axis of the diaphysis. The varus angles for the different age groups are shown in Table 11.

It appears from Table 11 that with increasing age a steady exacerbation of the varus deformity also occurred in adults. For determination of the angle I used only those roentgenograms in which the measurement obtained corresponded entirely or closely to the true angle, as already discussed in the part dealing with material and methods. And even if minor errors of determination are present, the decrease in width of the angle with age is so obvious, as appears from the table, that these errors are of little significance.

In order to determine the degree of dysplasia of the hip joint I measured the CE angle as suggested by WIBERG (1939). The width of this angle in the children and in the adult patients with and without pseudarthrosis appears in Table 12.

According to WIBERG, values under 20 for the CE angle are pathological in adults and show that dysplasia of the hip joint is present. Values between 20 and 25 are borderline values, and values over 25 are normal. According to SEVERIN (1943), the corresponding values are somewhat lower in children, a CE angle of 20 or more being normal in those aged 6—13 years, whilst 15—19 are borderline values and values under 15 pathological. For the age groups 14—35 years he considered WIBERG's values to be correct. Accepting these criteria, dysplasia of the hip joint was present in only a few of the children in my series, but in the majority of the adult patients.

In order to form an opinion on the course of development of the lesion during the growing period, I drew Fig. 3 to illustrate the characteristic roentgenological changes in the different age groups. The diagrams were based on the individual roentgenograms in the different age groups in my series.

It is seen that in *age group I* (2—4 years) the bony tissue shows marked rarefaction. The neck of the femur is shortened, and the triangular piece in its

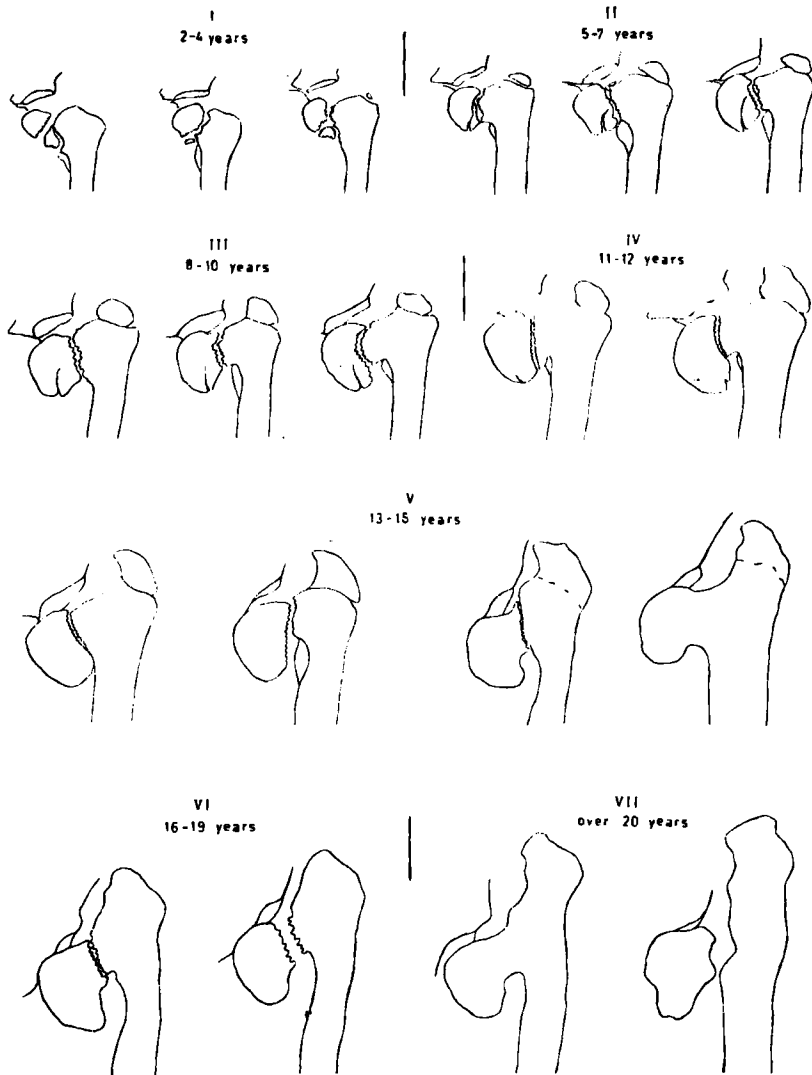


Fig. 3. — The diagrams show the roentgenological changes in different age groups. It is seen that the lesion progresses with age.

distal portion is clearly visualized as completely detached. The vertical gap and the epiphyseal line form a single zone of rarefaction running across the neck of the femur.

In *age group II* (5—7 years) the bone of the femoral neck is not so badly rarefied throughout the whole length of the latter as in the former group.

The disturbance of ossification is localized to a narrower area of the medial portion of its metaphysis. The vertical gap running across the femoral neck is separated from the epiphyseal line laterally. The triangular piece is not entirely detached, as in group I, but fused either with the head or the neck of the femur.

In *age group III* (8—10 years) the epiphyseal plate is visualized medially as a narrow line, and a vertical gap with sharper borders is clearly seen. The triangular fragment is in the process of fusing with either the head or the neck of the femur.

In *age group IV* (11—12 years) the disturbance of ossification is limited to a still narrower area in the medial portion of the metaphysis of the femoral neck. Running across the latter only one vertical zone of rarefaction is visible, the epiphyseal line is no longer clearly discernible. No triangular piece is seen.

In *age group V* (13—15 years) the disturbance of ossification is limited to a very narrow area. Only one gap with rather sharp borders runs across the neck of the femur. No epiphyseal line and no triangular fragment are visible. In certain cases this zone of rarefaction is so conspicuous that it closely resembles a pseudarthrosis, whilst in others it is in the process of disappearing as the femoral neck undergoes ossification.

In *age group VI* (16—19 years) growth is complete in the majority of cases. The neck of the femur is either ossified, or pseudarthrosis is present.

In *age group VII* (20—46 years) I have included all the remaining adult patients.

Furthermore, the figures reveal a steady increase of the varus deformity from group to group, to some extent even after the completion of growth. The acetabulum does not become shallower until the end of the growth period, the change being more conspicuous from group V onwards. After the completion of growth, a marked increase in shallowness of the acetabulum is discernible in the patients with pseudarthrosis, in particular.

Deformity of the head of the femur and decalcification also showed a definite increase towards the end of the growing period. In this respect the exacerbation of the condition after the completion of growth was particularly obvious in the patients with pseudarthrosis. In some of these cases the head of the femur had become strikingly depleted of calcium and undergone fusion with the acetabulum.

The roentgenological changes depicted in Fig. 3 were characteristic of the majority of the patients of the corresponding age groups, in particular of those who were still growing. *During the growth period the disturbance of*

ossification in the neck of the femur seems to cause similar roentgenological changes in all patients of the same age.

As is seen from Table 10, my series also comprises some cases in which the changes in the neck of the femur were slight. In these, only a slight degree of rarefaction of the bone was observable immediately laterally of the epiphyseal plate. No vertical fissure and no triangular piece were discernible. The varus deformity was slight, the neck-shaft angle being only slightly under 110° . The total number of such cases is 9, and all the patients in question belong to the four youngest age groups.

I have regarded as coxa vara infantum only cases in which the neck-shaft angle was under 110° and the neck of the femur showed the rarefied bony tissue typical of this disease.

The roentgenological changes observed in the adult patients are shown in Table 13, from which the following facts appear:

In the majority of patients with pseudarthrosis the head of the femur was entirely detached from the neck. In the remainder a transverse fissure visible in the neck was a sign of fibrotic pseudarthrosis. Furthermore, in each of these cases abnormal mobility of the neck of the femur was observed in connection with operation, which proved the presence of pseudarthrosis.

TABLE 13. — *Roentgenological changes in adults **

Age groups	No pseudarthrosis			Pseudarthrosis			Total no. of hips
	Arthrotic changes in the hip joint		No. of hips	Head of femur completely detached from neck	Transverse fissure in femoral neck = fibrotic pseudarthrosis	No. of hips	
	present	none					
14—19 yrs.	—	11	11	13	2	15	26
20—25 »	—	8	8	11	4	15	23
26—30 »	2	6	8	1	1	2	10
31—40 »	3	6	9	6	1	7	16
over 40 »	4	3	7	—	—	—	7
Total	9	34	43	31	8	39	82

* whole series of adults

Even in young patients with pseudarthrosis the head of the femur may become fused to the acetabulum. This was seen in 2 patients under 20 years old.

In the patients without pseudarthrosis, arthrotic changes of the hip joint were not observed until after the age of 26. This explains why young patients with even a high degree of coxa vara infantum often have relatively slight pain.

VI HISTOLOGICAL INVESTIGATIONS

As appeared in the survey of the literature, the histopathology of coxa vara infantum has been very little studied. In the majority of relevant papers only a few cases are described. The available investigations hitherto published are listed in Table 14.

TABLE 14. — *Earlier histological investigations on coxa vara infantum*

Investigator	Year of publication	No. of cases
A. HOFFA	1905	1
C. HELBING	1906	1
F. DELITALA	1913	1
J. S. BARR	1929	1
H. CAMITZ	1934	3
I. ZADEK	1935	1
E. BURCKHARDT	1946	4

The first histological investigations (HOFFA and HELBING) were based on resection of the whole proximal part of the femur. At that time this radical operation was performed even on small children. DELITALA and CAMITZ examined specimens obtained post mortem in one case each. BARR, ZADEK and BURCKHARDT studied small specimens taken in connection with operations. The investigations of CAMITZ and BURCKHARDT are both thorough and informative.

Since over the course of years patients with coxa vara infantum were remitted to the Invalid Foundation in considerable numbers, F. LANGENSKIÖLD decided to investigate these cases histologically, also. Specimens were therefore taken at operations.

When this material was placed at my disposal, it comprised specimens from 6 cases, all taken by F. LANGENSKIÖLD. All subsequent specimens have been taken by myself.

In connection with the operations I have taken a small specimen for histological investigation from an area of the metaphyseal portion of the femoral neck extending to the transverse zone of rarefaction. In some cases the specimen included a piece of the triangular fragment in the distal portion of the neck of the femur. In order to avoid damage to the epiphyseal plate, the operation was not extended as far as the true epiphyseal line. As far as possible I tried to take the specimens as entire pieces measuring $\frac{1}{2}$ — $1\frac{1}{2}$ cm. in diameter.

In connection with intertrochanteric osteotomy specimens were readily obtainable without extending the operation. A further reason for taking the specimens from the site described above was that the changes visible in the roentgenogram in coxa vara infantum are most pronounced precisely in the metaphyseal part of the neck of the femur, in particular in its medial portion.

Immediately after operation the specimens were fixed in a 10 per cent solution of formaldehyde. Decalcification was performed by placing them for one or two weeks in a solution consisting of two parts of 40 per cent formic acid solution and one part of 7 per cent Na-formate solution. Subsequently the specimens were dehydrated for a few days in 96 per cent alcohol and finally in absolute alcohol. They were then rinsed for one day in alcoholic ether and chloroform or, in some cases, placed in xylol, after which they were embedded in paraffin. They were sectioned at $4\ \mu$ and in the frontal plane in order to make possible comparison of the histological findings with the roentgenograms. All sections were stained with van Gieson's haematoxylin and haemalum-eosin. Some specimens were also stained with Weigerth's haematoxylin.

When I commenced this study, the importance of having a normal series for comparison became clear. At the suggestion of Professor H. TEIK I began to collect specimens from the neck and head of the femur of children of different ages, using autopsy material from the Department of Pathology, the Department of Forensic Medicine and the Children's Clinic of the University of Helsinki. Thus, I could compare the specimens obtained in cases of coxa vara with normal specimens from subjects of corresponding age.

My normal material consists of 19 specimens obtained from subjects who had died at ages of one day to 20 years. On histological examination no pathological changes were observable in these specimens. No haematological or bone diseases were revealed by either the hospital records or the autopsy findings. The specimens were fixed, decalcified, sectioned and stained in the same way as described above. This normal material shows the develop-

mental stages occurring with increasing age in the neck of the femur and the subcapital epiphyseal plate. It constitutes a basis for comparison with the specimens obtained from coxa vara patients of corresponding age.

TABLE 15. — *Normal hips and hips with coxa vara infantum investigated histologically by the author*

Age of patients in years	0—1	1	2	3	4	5	6	7	8	9	10	11	12	13	14	15	16	17	18	19	20	Total
No. of normal cases	8	2	1		1	1		1	1				1		1			1			1	19
No. of patients with coxa vara infantum				1	1	1	3	5	2	4	4	1		1	1					1		25

The whole histologically investigated material, including both the cases of coxa vara infantum and the normal cases, is given in Table 15.

NORMAL POSTNATAL DEVELOPMENT OF THE SUBCAPITAL EPIPHYSEAL PLATE AND THE NECK OF THE FEMUR

During the foetal period the whole proximal portion of the femur consists of cartilaginous tissue. At birth the border of ossification between this and the diaphysis has reached the lateral aspect of the neck of the femur. After birth, usually at the age of 2—6 months, the ossific centre of the head of the femur becomes visible in the roentgenogram (v. LANZ-WACHSMUTH). In the present series the youngest subject in whom this centre was discernible was 4 months old. Between the epiphyseal and diaphyseal ossific centres there remains a cartilaginous plate, the subcapital epiphyseal plate. The appearance of this plate changes markedly with age. According to the observations made on my own material the development of the plate is as follows:

During the first year of life the epiphyseal plate is 4—5 mm. thick. With age, a steady thinning occurs, the thickness of the plate being 2—2½ mm. at the age of 2 years, about 2 mm. at the age of 4, 1½—2 mm. at the age of 7—8, 1—1½ mm. at the age of 12 and ½—1 mm. at the age of 14. By the age of 17 the epiphyseal plate has entirely disappeared. The thinning does not occur quite evenly, thinner and thicker areas being simultaneously observable. The thinning of the epiphyseal plate is due to steady resorption of the cartilage and its replacement by bone on the metaphyseal surface. The process of ossification is not equally intensive everywhere, and this

fact is responsible for the differences in thickness observable between different areas in the plate. Although in the proliferating zone of the epiphyseal plate interstitial growth is going on, this is not sufficient to make up for the thinning due to ossification. The thinning mainly occurs at the cost of the zone of resting cartilage and the proliferating zone. The zones of maturing and calcifying cartilage also become somewhat thinner with age, but not so much as the former. The cell columns, which during the first few years of life are long, dense and very regular, become shorter, less dense and less regular towards the end of the growing period. If the epiphyseal plates of subjects aged, for instance, 2 and 14 years are compared, the



Fig. 4 a



Fig. 4 b

Fig. 4 a and b. — Normal subcapital epiphyseal plate in a 2-year-old subject. The following cartilaginous zones are discernible (according to Ham) from the epiphysis to the diaphysis (in fig. 4 a from top to bottom): 1. Zone of resting cartilage, which forms a layer adjacent to the epiphysis. Between this and the spongiosa signs of ossification are observable. 2. Proliferative zone, which is the thickest layer. In the direction of the diaphysis its cells form columns which are strikingly regular and dense. 3. Zone of maturing cartilage, the cells of which are in the stage of maturation. 4. A thin layer of calcification, in which the majority of cells are dead. At the junction between the epiphyseal plate and the metaphysis the formation of the trabeculae of the spongiosa takes place. The thickness of the epiphyseal plate is about 2—2½ mm. The lamellated structure of the spongiosa is incomplete. Haematopoiesis in the marrow cavities of the metaphysis is normal.

(32 × and 80 ×)

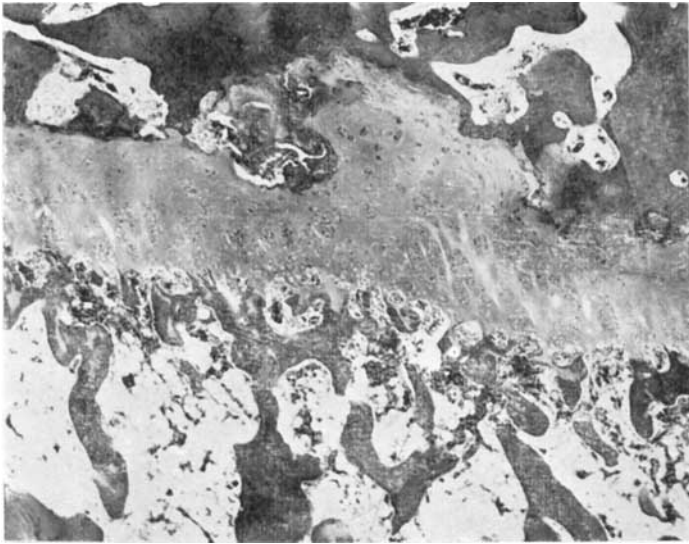

Fig. 5. — Normal subcapital epiphyseal plate in a 14-year-old subject. Thickness $\frac{1}{2}$ —1 mm. In comparison with the epiphyseal plate of a 2-year-old subject shown in Fig. 4 the following changes are seen: Thinning has not occurred evenly, the plate being thicker in some parts, thinner in others. Its epiphyseal aspect is coated with a thin layer consisting of trabeculae, the terminal plate. A zone of resting cartilage is observable only here and there. The proliferative zone has become very much thinner. The cell columns are short and few and less regular than at 2 years. The same holds good in regard to the zones of maturing and calcifying cartilage. By contrast, the formation of trabeculae is similar in the two cases. The spongiosa shows a clear trabeculated structure. Haematopoiesis is normal in the marrow cavities of the metaphysis. (32 \times)

changes occurring in the different zones are clearly discernible (see Figs. 4 and 5). The zone of trabeculated bone remains equally thick, broadly speaking, throughout the growing period.

During the first year of postnatal life the epiphyseal aspect of the epiphyseal plate shows the columnar arrangement of cells characteristic of the process of ossification, although to a lesser extent than the metaphyseal aspect. At the age of 2 years hardly any signs of ossification are discernible, and at the age of 4 years the epiphyseal plate is coated with a thin, almost uniform bony plate (the terminal plate). In later years no ossification occurs on this aspect, which is closed by the terminal plate.

When, as a result of growth, the epiphyseal plate has changed into spongy bone, the terminal plate is still distinguishable for some years, although it is no longer quite uniform (WEINMANN & SICHER). In the roentgenogram it is discernible as a «sclerotic» zone. In my own series vestiges of this zone were distinctly observable in a 17-year-old subject. The final disappearance

of the epiphyseal and terminal plates results in complete functional union of the metaphyseal and epiphyseal bone.

The changes in the spongy bone of the femoral neck are not so conspicuous as are those in the epiphyseal plate. The course is less obvious. During the first few years of postnatal life the primary spongiosa developing in the metaphysis is of the coarse fibrillar type, and it is only gradually replaced by mature lamellated bone (WEINMANN & SICHER). In the present material the main portion of the spongiosa of the femoral neck showed a clearly discernible lamellated structure in subjects aged 7—8 years.

After the first few years of postnatal life the haematopoietic bone marrow of the spongy bone is gradually replaced by adipose tissue (WEINMANN & SICHER). In my own cases haematopoiesis was very active throughout the growing period. At the age of 14 it was still vigorous in the whole area of the femoral neck, but at the age of 17 it was markedly decreased.

According to GRASHEY-BIRKNER, closure of the subcapital epiphyseal plate occurs at the age of 17—19, according to v. LANZ-WACHSMUTH at the age of 19—20. When the epiphyseal plate has become closed, the neck of the femur has attained its final length, which according to v. LANZ-WACHSMUTH is 3.5—4 cm.

THE HISTOPATHOLOGY OF COXA VARA INFANTUM

In the present series of patients with coxa vara infantum all specimens were taken from the distal portion of the femoral neck, from a site immediately laterally of the transverse zone of rarefaction (cf. Fig. 6).

Histologically the different specimens showed a striking uniformity, although the patients were of different ages and roentgenologically their lesions differed in degree of severity. All specimens exhibited the following features:

- 1) cartilaginous tissue, which in the majority of cases formed a uniform plate corresponding to the transverse zone of rarefaction visible in the roentgenogram,
- 2) metaphyseal bony tissue immediately adjacent to the cartilage and
- 3) connective tissue invading both the bone and the cartilage.

The *cartilaginous plate* discernible in most specimens consisted of cartilage of the same type as in the epiphyseal plate. It showed pathological changes in all cases. Usually it was hyaline. In some sites its structure was the same as in the normal epiphyseal plate, whilst in others the arrangement

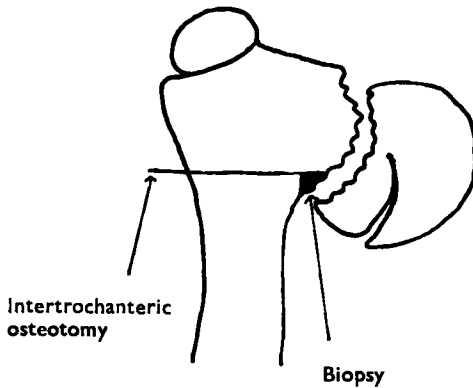


Fig. 6. — Biopsy at operation (see text on page 47).

of the cells was completely irregular. Sometimes the same specimen exhibited both areas without any cells and areas densely packed with cells. In some specimens the cartilaginous tissue formed a uniform plate, in others it contained abundant cavities, mostly filled with connective tissue, whilst in yet others the whole cartilaginous tissue was pathologically changed. The junction between cartilage and bone showed endochondral ossification, but in all specimens the process of ossification was much slighter than normal. The preparatory cell columns were short, and in some sites their arrangement was entirely irregular. In other sites preparatory cell columns were completely lacking. Another sign of the slightness of the process of ossification was that the zone of developing trabeculae was throughout thinner than normal and exhibited an irregular structure. In certain sites this zone was completely lacking, and the cartilage bordered abruptly on the bone. In the different cases these changes varied greatly in degree. In all specimens isolated islets of cartilage, as a rule with no process of ossification observable at the borders, were present deep within the area of spongy bone. Between these islets of cartilaginous tissue and the surrounding bone there was a very distinct line of demarcation. In some specimens the cartilaginous zone was to a large extent replaced by fibrillar connective tissue. Only here and there was hyaline cartilage still observable inside the area of connective tissue.

The *metaphyseal bone*, too, showed pathological changes in all cases, the main change being osteoporosis. The trabeculae were thin and irregular in shape, and exhibited an incomplete concentric structure. The marrow cavities were large and irregularly shaped. In some cases these changes were observable only in a limited area near the cartilaginous zone, whilst in

others they were extensive. Haematopoiesis in the marrow cavities was in all cases considerably weaker than the normal. In some cases extensive areas exhibited marrow cavities filled with loose connective tissue, whilst in other areas the marrow cavities were empty or contained a certain amount of adipose tissue. Usually osteoblasts were observed at the border of ossification, but their occurrence was very irregular. In some sites they were entirely lacking. As a rule, osteoclasts were present, but in moderate numbers.

Loose connective tissue, rich in cells, was found in abundance both in the marrow cavities and in the cavities in the cartilaginous zone. In certain specimens the connective tissue was strikingly fibrillar. In these, it was also very rich in cells. Connective tissue of this kind occurred in some sites in close proximity to the trabeculae, appearing like callous tissue within the area of the bone. In certain specimens callous tissue of this kind was also present within the area of the cartilage. The amount of connective tissue varied greatly in the different specimens. Here and there, particularly at the junction between bone and cartilage, the marrow cavities contained thin, dilated vessels in abundance, mostly filled with blood. The vascular walls did not exhibit any pathological changes.

In order to obtain a general view of my cases I have classified them according to the degree of severity of the changes in the different tissues. In evaluating the degree of severity I have taken into consideration both the morphological changes in the tissue and the functional changes as revealed by the histological sections. Both the morphological and functional changes have been classified into three different degrees of severity:

- Group I: slight changes
- Group II: moderate changes
- Group III: marked changes

Group I

This group includes specimens differing only slightly from the normal. The *cartilaginous plate* consisted mainly of uniform, hyaline tissue containing living cells in abundance. This tissue resembled that of the epiphyscal plate, but the arrangement of the cells differed from the normal, and the cartilaginous plate also contained necrotic areas. Everywhere at the junction between the cartilaginous plate and the bony tissue endochondral ossification was observable, although the process was weaker than normal: The preparatory cell columns were short and in the zone of developing trabeculae the number and length of the longitudinally disposed bony tra-

beculae with cartilaginous cores were clearly decreased as compared with the normal cases. The number of remnants of calcified cartilage in the metaphysis was also smaller than normal.

The changes in the *metaphyseal bone* were regarded as slight when pathological, osteoporotic bone was present only in a narrow area, 1—2 mm. broad at the outside, at the junction of bone and cartilage. The activity of the bone marrow differed from the normal in that haematopoiesis was somewhat weaker. The number of osteoblasts and osteoclasts at the junction of bone and cartilage was sometimes smaller than normal.

Loose connective tissue rich in cells was present in the cavities of the bone marrow in an area near the border of the cartilage measuring 1—2 mm. in breadth, and to some extent within the area of the cartilaginous tissue.

Group II

The following changes in the *cartilage* were considered moderate: The usual arrangement of cells was disturbed in the whole cartilaginous plate. There were numerous cavities filled with connective tissue. The cartilaginous tissue was largely fibrillar. The process of endochondral ossification was severely disturbed along the whole junction between bone and cartilage. At least fifty per cent of this junction showed very slight signs of ossification or none at all.

Osteoporotic changes in the *bone* were present in an area at least 2—5 mm. broad, extending from the junction between bone and cartilage. The activity of the bone marrow was severely disturbed, haematopoiesis being slight everywhere, or occurring only here and there. Osteoblasts and osteoclasts were found in smaller numbers than normal along the whole border of ossification, and in some sites they were completely lacking.

Loose connective tissue rich in cells was present in the bone marrow cavities in extensive areas, and in the cavities in the cartilage, too. Here and there the connective tissue was fibrillar in small areas.

Group III

In the cases included in this group the changes in the *cartilage* were as follows: The whole structure of the cartilaginous plate was disturbed, or the tissue had changed into fibrillar cartilage, or into fibrillar connective tissue. There was hardly any endochondral ossification or signs of this process were observable in a few sites only.

TABLE 16. — *Cartilage*

<i>Structural changes</i>		
I slight	II moderate	III marked
1. Cartilaginous layer uniform	Cavities in cartilaginous layer	Cartilaginous layer rarefied
2. Mainly hyaline cartilage	Fibrils or connective tissue in abundance in the cartilage	Mainly fibrocartilage or connective tissue
3. Majority of cartilaginous cells alive, numerous cells undergoing division	In cartilaginous layer areas without any cells or with dead cells without nuclei	Extensive weakly staining areas without any cells
4. Arrangement of cartilaginous cells only here and there in disorder	Extensive areas in which the arrangement typical of the cartilaginous cells is disturbed	Arrangement of cartilaginous cells mostly in complete disorder
5. No necrosis or very small necrotic areas	Necrotic areas in abundance	Extensive necrotic areas
<i>Disturbance of ossification</i>		
I slight	II moderate	III marked
1. Signs of endochondral ossification along the whole junction between bone and cartilage	Areas showing very slight signs of ossification, if any	Signs of ossification entirely lacking or observable at only a few points of the junction between bone and cartilage
2. Preparatory cell columns of cartilaginous layer only here and there shorter than normal or in disorder	Preparatory cell columns strikingly short or in disorder along at least half of the junction between bone and cartilage	Preparatory cell columns entirely lacking or everywhere in marked disorder
3. Spicules of cartilage extending into the bony tissue here and there shorter and scantier than normal	Spicules of cartilage extending into bony tissue scanty or shorter than normal along at least half of the junction between bone and cartilage	Spicules of cartilage extending into the bony tissue visible at only a few points or entirely lacking
4. Separate islets of cartilage in the bony tissue somewhat scantier than normal	Separate islets of cartilage only here and there in the bony tissue or markedly less than normal	Islets of cartilage in the bony tissue entirely lacking or discernible at only a few points

The *bone* was osteoporotic in an area more than 5 mm. broad. The bone marrow activity was very severely disturbed, there being little, if any, haematopoiesis. Osteoblasts and osteoclasts were almost entirely lacking.

TABLE 17. — *Bone*

<i>Structural changes</i>		
I slight	II moderate	III marked
1. Osteoporotic changes (bone trabeculae thin, distorted, with a deficient concentric structure, marrow cavities large, irregularly shaped) in an area not exceeding 1—2 mm. in breadth adjacent to the cartilage	Osteoporotic changes in an area 2—5 mm. in breadth adjacent to the cartilage	Osteoporotic changes in an area over 5 mm. in breadth adjacent to the cartilage
<i>Functional disturbance of the bone marrow</i>		
I slight	II moderate	III marked
1. Haematopoiesis somewhat weaker than normal	Haematopoiesis markedly weaker than normal or observable only here and there	No haematopoiesis, or weak haematopoiesis observable at a few points
2. Number of osteoblasts and osteoclasts smaller than normal at some points of the junction between bone and cartilage	Osteoblasts and osteoclasts everywhere fewer than normal, here and there entirely lacking	Osteoblasts and osteoclasts entirely lacking, or present in very small numbers here and there
3. Loose connective tissue in the marrow cavities in an area 1—2 mm. in breadth adjacent to the cartilage	Loose connective tissue in an area over 2 mm. in breadth adjacent to the cartilage. Here and there small areas of connective tissue rich in fibrils and cells (callous tissue).	Marrow cavities in an extensive area occupied by loose connective tissue or connective tissue rich in fibrils and cells (callous tissue).

Fibrillar connective tissue rich in cells (callous tissue) occupied large areas within the bone, and had replaced the cartilage to a considerable extent.

Tables 16, 17 and 18 show the tissue changes here described, classified according to degree of severity.

In Table 19 I have tabulated all the present cases of coxa vara infantum which were histologically investigated. The table shows the degree of severity of the changes observed in the different tissues in each case. The cases have been listed according to age, from the youngest to the oldest. The table

TABLE 18. — *Connective tissue*

<i>In connection with cartilage</i>		
I	II	III
small amount	moderate amount	large amount
1. Small areas in cartilaginous plate containing connective tissue	In cartilaginous plate or its cavities larger areas containing loose connective tissue or small amounts of fibrillar connective tissue	Entire cartilaginous plate or most of it changed into fibrillar connective tissue
 <i>In connection with bone</i>		
I	II	III
small amount	moderate amount	large amount
1. Near the border of ossification (in an area not exceeding 1—2 mm. in breadth) loose connective tissue, rich in cells, in the marrow cavities	Marrow cavities in an area over 1—2 mm. in breadth, containing loose connective tissue. Smaller areas at the border of ossification containing fibrillar connective tissue, rich in cells	Marrow cavities in extensive areas containing loose connective tissue and fibrillar connective tissue, rich in cells (callous tissue)

shows that the changes in the different tissues are generally slight in the younger patients and more severe in the older ones. In all the patients over 10 years of age the tissue changes mostly belonged to group III. Changes of this degree were also observed in some of the younger patients.

THE RELATION BETWEEN HISTOLOGICAL CHANGES AND AGE

Since there seemed to be a correlation between the age of the patients and the degree of severity of the histological changes, I have classified the cases into age groups in the same way as I did when discussing the clinical and roentgenological changes observed in subjects of growing age.

The histological findings in subjects aged 2--4 years

Two cases were histologically investigated (nos. 26 and 110). In case 26, the youngest patient in the series, the specimen mainly consisted of bone and connective tissue. The amount of cartilage was so small that no definite conclusions regarding its structure could be drawn. From the changes in the bone and the occurrence of connective tissue the specimen was estimated to belong to group II. In case 110, too, nearly all the tissue changes belonged to group II.

TABLE 19. — *Histological changes in different tissues classified by degree of severity (I—III)*

Case no.	Age in yrs.	Fig. no.	Cartilage changes		Bone changes		Connective tissue occurring		Number of degrees of severity per case in different age groups		
			in structure	in ossification	in structure	in bone marrow	in cartilage	in bone	I	II	III
26	3		—	—	II	II	—	II	—	4.0	0.5
110	4		II	II	II	II	II	III			
28	5		—	—	II	II	—	II			
80	6		II	II	II	II	II	II	0.8	3.7	1.1
82	6	10	I	II	I	II	I	I			
97	6		III	III	II	II	III	III			
106	7		II	II	II	II	II	II			
111	7		II	II	II	II	II	II			
89	7		I	II	I	II	I	II			
88	7	7	II	II	II	III	II	II			
76	7		III	III	III	III	II	III			
94	8	8	III	III	II	III	III	III			
99	8		I	II	II	III	I	II			
29	9		III	III	II	II	III	II			
93 right	9	11	III	III	III	III	II	II	0.3	3.0	2.7
93 left	9		II	III	III	III	II	II			
27	9		II	III	III	III	II	III			
83	10		II	II	II	II	I	II			
98 right	10		II	III	II	II	II	II			
107	10		III	II	II	III	II	II			
84	10		III	III	III	III	II	II			
98 left	11		III	III	II	II	II	II			
102	13		III	III	III	III	III	III			
85	14	9	III	III	III	III	III	III	—	1.0	5.0
81	18		III	III	III	III	III	III			

The histological findings in subjects aged 5—7 years

The cases histologically examined numbered 9 (nos. 28, 80, 82, 97, 106, 111, 89, 88 and 76).

The histological changes in this age group resembled those in the former. The changes in the structure of the cartilaginous tissue were slight in 2 cases, moderate in 4 and marked in 2. Ossification was severely disturbed in 2 cases, and moderately in the remainder. The structural changes in the bony tissue and the disturbance of bone marrow function corresponded largely to the changes observed in the cartilage. In the majority of cases the changes in

the bony tissue were moderate. The changes present were slight in 2 cases and marked in 2. From the standpoint of the occurrence of connective tissue within the areas of bone and cartilage 2 cases belonged to group III (marked changes), 6 to group II (moderate changes) and 1 to group I (slight changes).⁷

Summarizing, it may be stated that the histological changes in this age group were mostly moderate, slight and marked changes being less common.

As an example, case 88 may be described (cf. Fig. 7 a, b, c and d):

Case 88. The patient was a 7½-year-old boy, the son of a farmer. When he was 4 years old the parents had noticed that he gradually began to limp without any obvious cause. Examination revealed coxa vara infantum of the right hip. At operation a specimen was taken from the distal portion of the femoral neck, consisting of a piece of the triangular fragment of bone, a piece of the lateral branch of the epiphyseal line and some metaphyseal bony tissue. The specimen was taken as one entire piece.

Histological investigation: The sections consisted of spongy bone with a zone of cartilage, some 2 mm. thick, running tortuously through it.

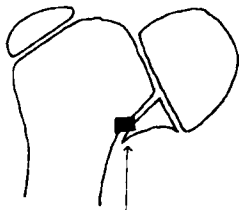


Fig. 7 a. — The diagram shows the area indicated in the microphotograph.

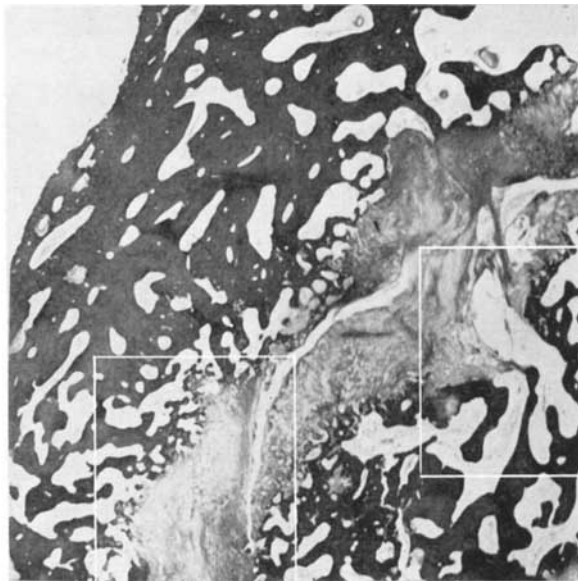

Fig. 7 b. — Case 88. Age 7 yrs. A zone of cartilaginous tissue runs across the spongiosa. To the left the metaphysis of the femoral neck is visualized, to the right the triangular fragment. Signs of ossification are visible only here and there on both sides of the cartilaginous zone, and some portions of the latter consist of fibrocartilage. The spongiosa is osteoporotic, in particular near the cartilaginous tissue and in the triangular fragment.

(12 ×)

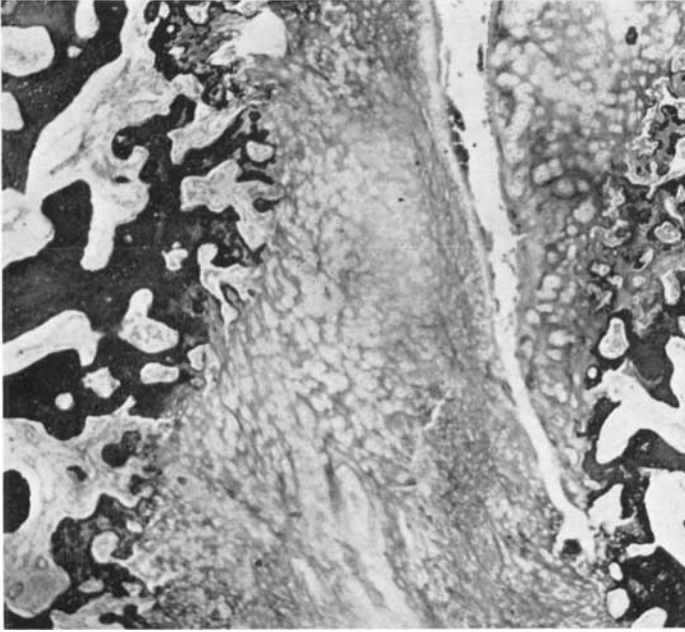
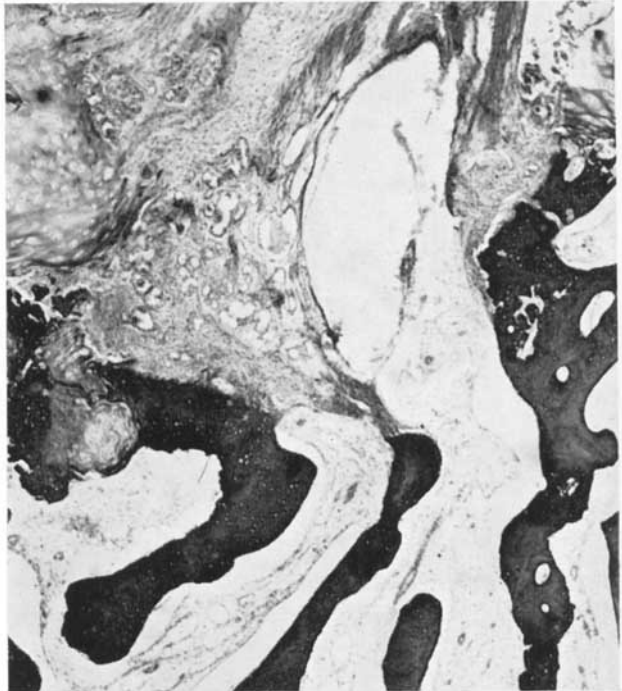


Fig. 7 c. — Magnification of the area in the lower part of Fig. 7 b marked off by a square. At the junction between the hyaline cartilage and the spongiosa the process of ossification is markedly disturbed. The cartilaginous cells are in disorder. (32 ×)

Fig. 7 d. — Magnification of the area to the right in Fig. 7 b marked off by a square. The hyaline cartilage is replaced by fibrocartilage and highly vascularized connective tissue. The trabeculae of the spongiosa are thin and their concentric structure is deficient, the marrow cavities are large and contain loose connective tissue. (32 ×)



The cartilaginous tissue contained cavities filled with loose connective tissue or blood. The cartilaginous zone consisted mainly of hyaline cartilage, but certain areas were markedly fibrillar. At the centre of the cartilaginous zone the cells were arranged in its long axis, and in the ground substance of the cartilage longitudinal bars were seen. In the immediate vicinity of the bony tissue the cells were here and there arranged in short preparatory columns, whilst in other sites their arrangement was in complete disorder. As compared with normal cases of the same age, the process of ossification was remarkably weak, inasmuch as

- 1) the preparatory cell columns were short and here and there completely lacking,
- 2) the spicules of cartilage extending into the bone were short and occurred only sparsely in some areas,
- 3) islets of cartilaginous ground substance were present only a short distance within the area of the bone.

The process of ossification seemed to be the same on either side of the cartilaginous zone.

The bone marrow cavities were large and irregular in the majority of sections. Further from the cartilaginous zone in the area of the metaphyseal bone (some 2—3 mm. from the cartilage) the cavities were smaller and the concentric structure of the trabeculae was more distinct. The bone marrow was very poor in cells. Haematopoiesis was observable only at some points. Osteoblasts and osteoclasts were present here and there in the marrow cavities, but mostly only in small numbers. The bone marrow cavity was largely occupied by loose connective tissue, containing fibroblasts in abundance and some granulocytes. In certain sites extensive areas of the bone marrow exhibited connective tissue which was markedly fibrillar and contained fibroblasts in abundance. At one point at the junction between bone and cartilage the latter was invaded by such connective tissue, forming callous tissue. This connective tissue was richly supplied with thin, dilated vessels filled with blood.

Histological findings in subjects aged 8—10 years

A total of 9 patients (10 hips) was histologically investigated (nos. 94, 99, 29, 93 right and left, 27, 83, 98, 107 and 84).

In the majority of cases the histological changes were clearly severer than in the foregoing age group. The cartilaginous changes were slight in only one case, moderate in 4 cases and severe in 5. The disturbance of endochondral ossification was considerable, being moderate in only 3 cases and marked in the remainder. The changes in the structure of the bone were moderate in 6 cases and marked in 4. The functional disturbance of the bone marrow was also conspicuous, being moderate in 3 cases and marked in 7. The amount of connective tissue within the areas of either the cartilaginous tissue or the bone was moderate in 7 cases and considerable in 3.

The histological findings in case 94 may be described as an example (cf. Fig. 8 a, b and c):

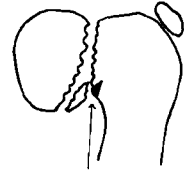
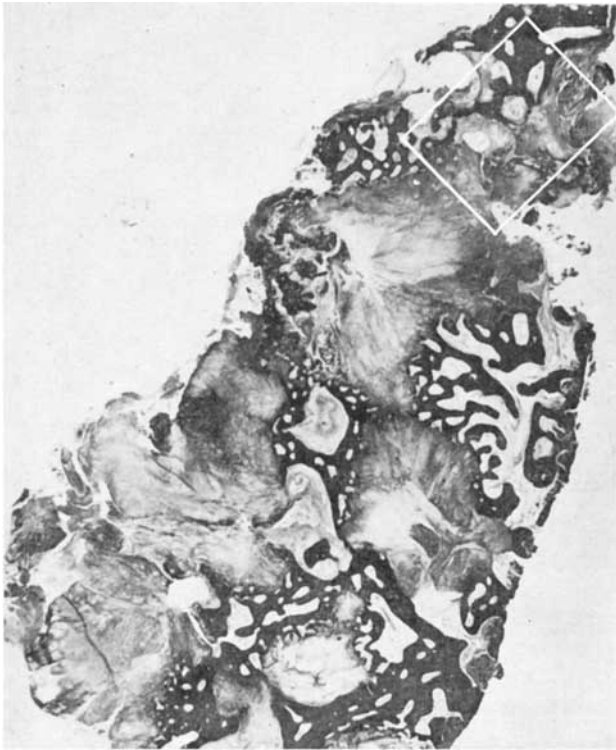

Fig. 8 a. — The diagram shows the area indicated in the microphotograph.

Fig. 8 b. — Case 94. Age 8 years. Cartilaginous tissue visible to the left, metaphyseal spongiosa to the right. The cartilage forms large islets in the middle of the bony tissue. Signs of ossification are slight and in many sites entirely lacking, the cartilage forming a sharp border with the bony tissue. The spongiosa is osteoporotic; the marrow cavities are large and contain loose connective tissue. (12 ×)

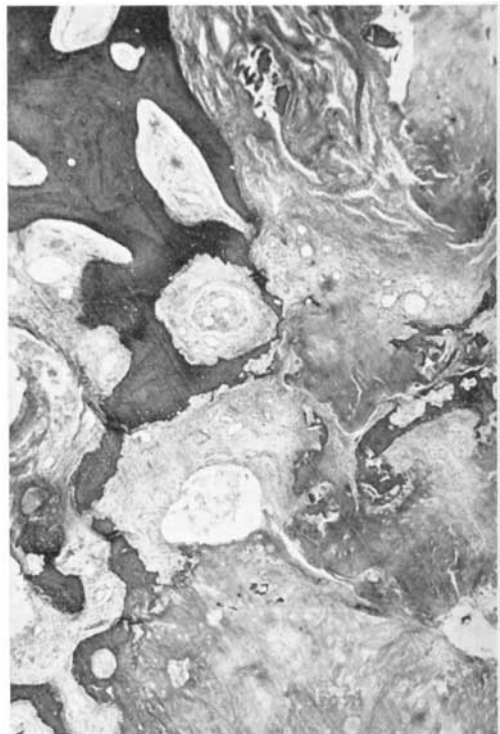


Fig. 8 c. — Magnification of the area in the upper portion of Fig. 8 b marked off by a square. Both the cartilage and the bone are replaced by connective tissue acting as callus. The connective tissue is in some sites fibrillar, in others highly vascularized. (32 ×)

Case 94. The patient was an 8-year-old boy, the son of a farmer. He had had a limp since he began to walk at the age of about one year, the right hip being affected. Roentgenological examination revealed a high degree of coxa vara infantum. There was a broad transverse zone of rarefaction in the femoral neck, which was considerably shorter than normal. At operation a piece of bone, extending medially to the zone of rarefaction, was removed from the neck of the femur.

Histological investigation: The sections exhibited hyaline cartilage in abundance, forming islets of varying size separated by spongy bone and connective tissue. Here and there in the cartilaginous tissue there were cavities containing some loose connective tissue and blood. Most of the cartilaginous tissue stained well, but there were also areas which were weakly stained. In some sites the cartilaginous cells were arranged in long columns. At certain points at the junction between bone and cartilage endochondral ossification was observable, but on the whole the process of ossification was very weak, the spicules of cartilage extending into the bony tissue being short and present only in a few sites. At some points the junction between bone and cartilage was very distinct, no signs of growth being discernible.

The structure of the bone showed a wide variation. The trabeculae lacked a concentric structure almost completely, and the marrow cavities were usually large and very irregular in shape. In general, haematopoiesis in the cavities was slight, and they were largely filled with loose connective tissue rich in cells. As a rule, osteoblasts and osteoclasts occurred in very small numbers.

Fibrillar connective tissue rich in cells was present here and there, in certain sites invading both the cartilaginous tissue and the bone. In these sites the cartilage was very poor in cells, and it seems obvious that a change of the cartilaginous tissue into connective tissue had occurred. Certain areas of the connective tissue contained thin vessels in abundance, sometimes filled with blood. At some sites the connective tissue seemed to invade the bone. Evidently this connective tissue was callous.

The patient was in this case an 8-year-old boy, in whom a lesion of the right hip had been observed since infancy. The roentgenogram revealed a marked degree of coxa vara infantum. Histologically, considerable changes in the cartilage and severe disturbance of endochondral ossification were established. The changes in the bony tissue were also marked. Particularly striking features were the inactivity of the bone marrow and the large amount of connective tissue within the areas of both the bone and the cartilage, especially the invasion of these tissues by callus.

Summarizing the findings in this age group it may be stated that moderate and marked tissue changes occurred in equal proportions, broadly speaking.

Histological findings in patients aged 11—15 years

Three cases were histologically investigated (nos. 98, 102 and 85).

All these cases exhibited changes of the third degree in the cartilaginous tissue. The changes in the bony tissue and the occurrence of connective tissue were marked in two cases and moderate in one. Summarizing, it may be stated that most of the tissue changes observed were marked. Moderate changes were infrequent, and slight changes were not seen at all.

As an instance case 85 may be described (cf. Fig. 9 a, b and c).

Case 85. The patient was a 14-year-old girl, the daughter of a farmer. She had exhibited a limp since she began to walk, the right hip being affected. Gradually the limp increased, and for the last two or three years preceding examination she had experienced pain in the hip in connection with strain. A high degree of coxa vara infantum was established in the right hip, the angle between the femoral neck and the diaphysis being 45° . The roentgenogram revealed pseudarthrosis of the neck of the femur. The epiphyseal lines of the lower extremities and the pelvis were fused. At operation, abnormal mobility was observed at the level of the transverse fissure, a sign of pseudarthrosis of the femoral neck. A specimen was taken from the site shown in Fig. 9 a, including a piece of the distal portion of the neck of the femur extending to the fissure.

Histological investigation: The sections contained spongy bone, at one aspect bordered by a layer of cartilage and connective tissue, about 1 mm. thick. This layer consisted mainly of fibrillar connective tissue rich in cells, but here and there it exhibited hyaline cartilage poor in cells, consisting chiefly of cartilaginous ground substance. Fibrillar cartilage with a relatively large number of nucleated cartilaginous cells was observable only at one point. This layer was coated with fibrillar perichondrium, poor in cells. Everywhere in it connective tissue had invaded the cartilaginous tissue, dividing the latter into islets of varying size. The connective tissue was fibrillar and rich in cells (mainly fibroblasts, and to some extent granulocytes, histiocytes and endothelial cells). At the border of the bony tissue this connective tissue was richly supplied with vessels filled with blood. No signs of growth were discernible in the cartilaginous tissue. The latter nowhere extended into the bone, and consequently no signs of endochondral growth were observable.

The junction between the bone and this zone of connective and cartilaginous tissue was irregular owing to the fact that connective tissue everywhere invaded the marrow cavities. Here and there connective tissue also seemed to have invaded the trabeculae, and in these sites the junction between bone and connective tissue was indistinct. At one point small, isolated islets of bone were present within the connective tissue. Obviously the latter acted as a callous substitute for the bony tissue. Here and there osteoclasts were also observable in this site.

The bony tissue consisted of spongy bone. In the immediate vicinity of the zone of cartilage and connective tissue the trabeculae were misshapen. Only at a distance of some 5—6 mm. from this zone was the concentric structure of the trabeculae around the Haversian canals more distinct. Near the connective tissue the marrow cavities were wide and irregularly shaped.

In the bone marrow immediately adjacent to the zone of cartilage and connective tissue the marrow cavities were filled with fibrillar connective tissue rich in cells. With increasing distance from this border, the connective tissue became poorer in fibrils and looser. By contrast, the number of cells in the connective tissue was everywhere the same, broadly speaking. Haematopoiesis was observable in the marrow cavities in only one site, otherwise the bone marrow was completely inactive. Here and there the walls of the marrow cavities exhibited osteoblasts in abundance, and osteoclasts were also observable in some cavities.

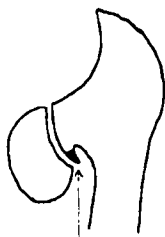


Fig. 9 a. — The diagram shows the area indicated in the microphotograph.

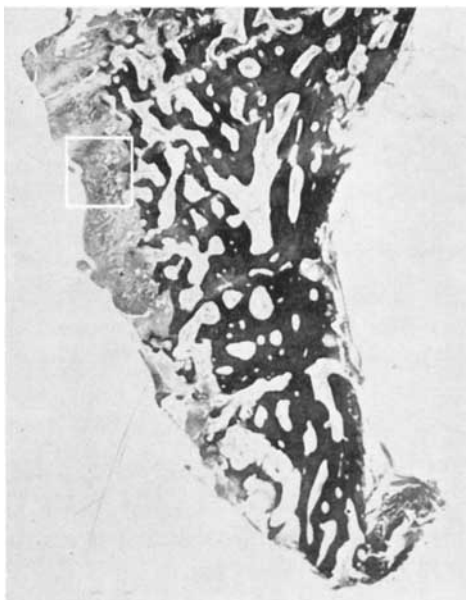

Fig. 9 b. — Case 85. Age 14 years. To the left, a uniform layer of fibrocartilage. To the right, spongy bone, which is markedly osteoporotic. (12 ×)

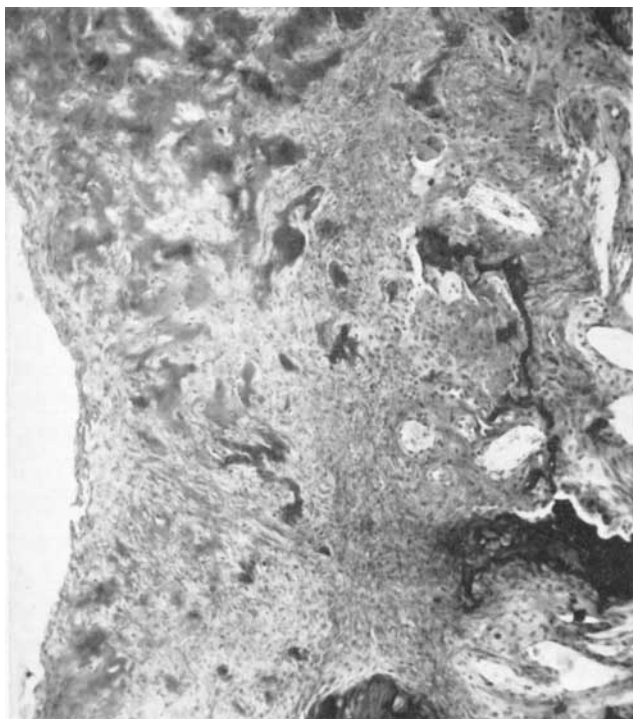


Fig. 9 c. — Magnification of the area in the middle of Fig. 9 b marked off by a square. Both the bone and the cartilage are replaced by fibrillar connective tissue rich in cells. Cartilaginous cells are lacking; only cartilaginous stroma remains as scattered islets. (80 ×)

The histological, clinical and roentgenological findings show a good correspondence. The patient was a girl whose longitudinal growth had just been completed. In the hip showing coxa vara infantum a clinically and roentgenologically observable pseudarthrosis had developed. On histological investigation it was established that the cartilaginous tissue had disappeared to a great extent and been replaced by fibrillar connective tissue rich in cells. Signs of ossification were no longer observable. In the immediate vicinity of this connective tissue resorption of the bone was discernible, the latter being invaded by the connective tissue. This phenomenon is obviously a sign of progressive pseudarthrosis.

In addition, a histological specimen was taken from one *18-year-old patient* (case 81). All tissue changes were marked. Clinically and roentgenologically it was established that complete pseudarthrosis had developed.

COMMENTS ON THE HISTOLOGICAL FINDINGS

As appears from the foregoing, the most striking changes in coxa vara infantum are those occurring in the cartilaginous tissue. The transverse zone of rarefaction in the neck of the femur, visible in the roentgenogram, which in most cases is situated laterally of the epiphyseal line proper, consists of cartilage of the same kind as that composing the epiphyseal plate. CAMITZ, whose investigations were based on specimens consisting of the whole upper portion of the femur, established that this transverse zone in the femoral neck is a true epiphyseal plate. In this zone of cartilaginous tissue great structural changes were, however, observable in all cases in the present series. The process of endochondral ossification at the junction between this cartilage and the metaphyseal bone was considerably disturbed. The interference with ossification, which in some sites was partial, in others complete, was observed in all cases, being thus a pathognomonic phenomenon. The majority of writers who have performed histological investigations have drawn attention to this disturbance (HOFFA, HELBING, CAMITZ, BURCKHARDT).

The changes in the metaphyseal bony tissue were also considerable and similar in all cases. They were osteoporotic, and most marked in the immediate vicinity of the border of the cartilage, whilst in the distal direction they gradually became less conspicuous. Attention has previously been drawn to this change in the metaphyseal bony tissue by BARR, who described it as atrophy of the bone. It was also observed by BURCKHARDT. Bone marrow activity was also severely disturbed in all cases. In almost fifty per cent of cases (12) the disturbance was found to be marked. This osteoporosis of the metaphyseal bony tissue and the inactivity of the bone marrow were very striking and also seemed to be of almost pathognomonic significance.

Here and there the bone marrow was richly supplied with thin, dilated vessels, filled with blood. Attention has been drawn to this phenomenon by HOFFA, HELBING, CAMITZ, BURCKHARDT and others. The sites showing callous tissue were, in particular, highly vascularized.

The amount of connective tissue within the areas of the bony or cartilaginous tissue was very different in the different cases. As a rule, it was the more abundant the more marked the changes in the other tissues. Connective tissue replaced other destroyed tissues.

On the whole, the histological picture in coxa vara infantum was found to be very complex: On the one hand, formation of bone occurred by endochondral ossification, on the other hand bone and cartilage were resorbed and replaced by connective tissue.

When the histological picture in coxa vara infantum is compared with that of certain commoner diseases, the following points emerge: None of the changes typical of rickets are observable, nor the bone necrosis typical of Legg-Calvé-Perthes' disease (HAYTHORN, JONSÄTER, LUCK). Changes due to inflammation are not visible, either. By contrast, the histological features of coxa vara infantum are seen to resemble those described in cases of infantile tibia vara (A. LANGENSKIÖLD). The changes in the cartilaginous tissue, for instance the simultaneous occurrence of areas with no cells and areas rich in cells, the irregular occurrence of endochondral ossification and the presence of islets of cartilaginous tissue in the metaphyseal bone, are all features which the two diseases have in common. Abundant vascularization in certain sites is also seen in both. By contrast, the changes of the metaphyseal bone seem to be much greater in coxa vara infantum.

COMPARISON OF THE CLINICAL, ROENTGENOLOGICAL AND HISTOLOGICAL PICTURES

As appeared in the description of the different groups, the histological changes were usually slighter in the younger patients. With increasing age, particularly towards the end of the growing period, the changes were found to be severer. This becomes clear when a comparison is made between the clinical and roentgenological pictures on the one hand and the histological changes on the other.

Clinically and roentgenologically cases 82, 89 and 99 showed slight changes. In all, symptoms had appeared relatively late. Patient no. 82, who was 6 years old when operated upon, had begun to limp one year before. The

limp and the limitation of movement in the hip were very slight. Patient no. 89, who was 7 years old, began to show a limp when she was 4 years old. In this case, too, the lesion of the hip was slight both clinically and roentgenologically. Patient no. 99, aged 8 years, had shown a limp since she was 4 years old, and she, too, had a relatively slight lesion. The histological changes in these cases, especially the structural changes of the cartilaginous tissue and bone, were slight (cf. Table 19).

In case 82, both the histological investigation and the roentgenogram showed that the lesion was relatively mild (Fig. 10 a and b).

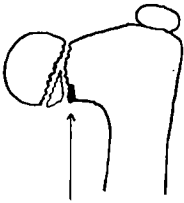


Fig. 10 a. — The diagram shows the area indicated in the microphotograph.

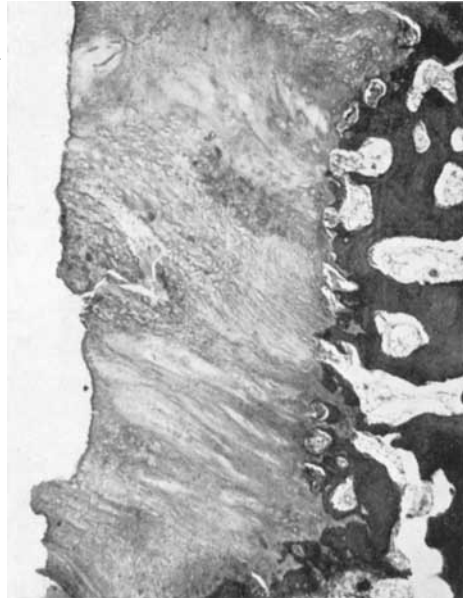

Fig. 10 b. — Case 82. Age 6 years. The cartilaginous tissue forms a uniform layer consisting of hyaline cartilage. In some sites the cell arrangement is in disorder, in other sites preparatory cell columns are seen. Signs of endochondral ossification are observable at the junction between bone and cartilage, but the process is weaker than normal. The spongiosa is relatively firm, although the marrow cavities are larger than the normal. The structural changes of both the bone and the cartilage are classified as slight (group I).
(12 ×)

As instances of clinically and roentgenologically severe cases nos. 93 and 102 may be taken. Patient no. 93 was 9 years old on presentation, and he had had a limp owing to bilateral affection of both hips since he began to walk. The clinical and roentgenological signs showed that the lesion was severe, and the histological changes were also marked (Figs. 11 a, b, c, d).

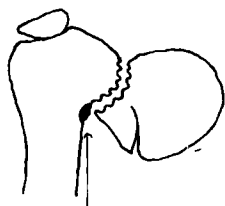


Fig. 11 a. — The diagram shows an area seen in the microphotograph.

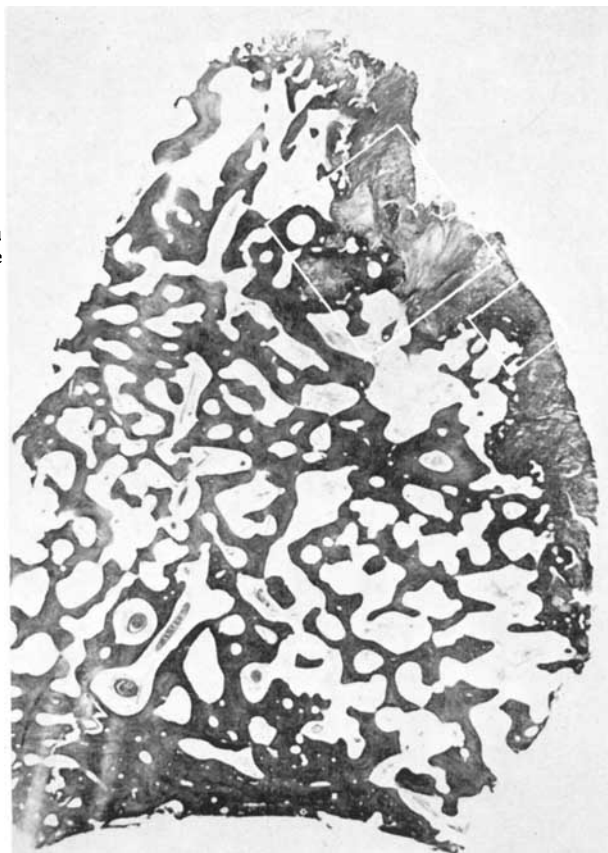


Fig. 11 b. — Case 93 (right hip). Age 9 years. To the right the cartilage forms a dispersed, tortuous layer at the border of the bony tissue. Scattered islets of cartilage are seen in the spongy bone. Most of the spongiosa is markedly osteoporotic. The trabeculae are thin and weak, the marrow cavities large and irregular. The marrow cavities are empty or contain loose connective tissue. The changes of both the cartilage and the bone are classified as marked (group III). (12 ×)

Patient no. 102 was 13 years old when medical aid was sought. Both clinically and roentgenologically the lesion was found to be severe, and the histological changes, too, were marked.

A decided correlation between the clinical and roentgenological findings and the histological finding was not observable in every case. In case 107, for instance, the lesion was clinically and roentgenologically only moderately severe, but the histological changes were marked.

The degree of severity does not depend on age alone. Patients nos. 97 and

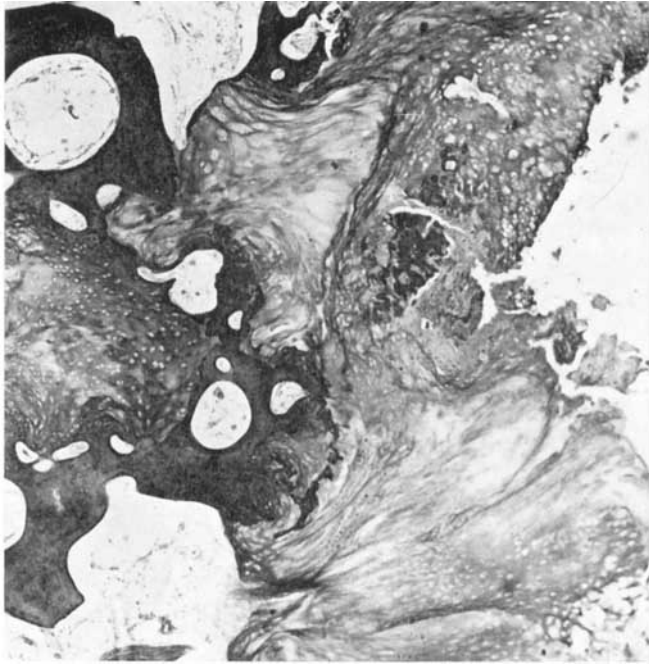


Fig. 11 c. — Magnification of the area in the upper portion of Fig. 11 b marked off by a square. The cartilaginous tissue is scattered, the cell arrangement is in complete disorder; in some sites the cells are densely packed, in others cells are entirely lacking. No signs of ossification are discernible, and the border between the cartilage and the bone is sharp. (32 ×).

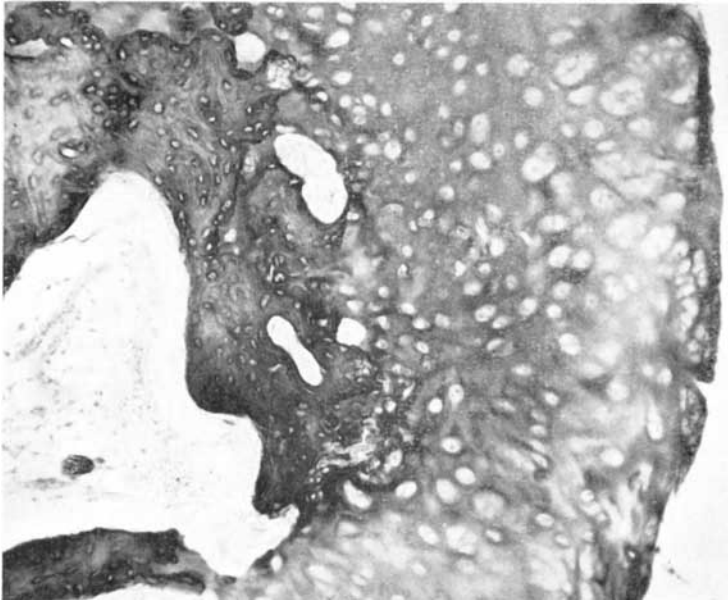

Fig. 11 d. — Magnification of the area in the lower portion of Fig. 11 b marked off by a square. The cartilaginous tissue consists of hyaline cartilage, the cell arrangement being disturbed. Weak signs of ossification at the junction between bone and cartilage. (80 ×).

76, for instance, were among the youngest in the series, being 6 and 7 years old, respectively. Nonetheless the condition was severe both clinically and roentgenologically, and the histological changes, too, were marked.

In general, a correlation can be established between the clinical and roentgenological changes, on the one hand, and the histological changes on the other. This holds good in particular when the clinical and roentgenological degree of severity of the condition was either slight or severe. Then the histological changes were correspondingly either slight or marked. By contrast, in the moderately severe cases the histological changes were sometimes found to deviate in regard to degree of severity. This is obviously due to the fact that the histological investigation was made on a small specimen, and tissue changes are not everywhere the same.

VII ETIOLOGY AND PATHOGENESIS

Of all the questions relating to coxa vara infantum, the etiology has been the most debated. As appeared in the survey of the literature, a large number of different theories have been suggested, but as the lesion is uncommon, the series published have all been relatively short. The clarification of this point has also been delayed owing to the fact that by the time clinical symptoms appear, the changes observable roentgenologically, for instance, are already advanced.

In what follows, it is my intention to compare the observations made on my own series with previous views concerning the etiology.

Many writers have regarded coxa vara infantum and congenital short femur as one and the same congenital malformation. According to this view, coxa vara infantum is only an extremely mild form of congenital short femur. Patients with coxa vara infantum, however, do not show the marked changes typical of the latter condition. Mild cases of congenital short femur, which could be considered as borderline cases between these two conditions, are extremely rare (EXNER).

At the Orthopaedic Hospital of the Invalid Foundation only 2 cases of congenital short femur have been treated. In the first patient, a 7-year-old boy, the head of the femur was a rudimentary remnant in the acetabulum. The second patient, an adult woman, whom I have mentioned on page 34, possibly had the same lesion, although in a much milder form. Since there are no other cases at my disposal, I cannot commit myself in regard to the question of the relationship between this condition and coxa vara infantum.

That theory of a congenital etiology according to which genetic factors are the cause of the disease has found many adherents. The most important argument in favour of this view is that familial occurrence has sometimes been observed. From this standpoint the reported cases of coxa vara infantum in identical twins are particularly significant. They are so few, however, that they do not constitute convincing evidence in favour of the view that coxa vara infantum is invariably a congenital anomaly.

Cleido-cranio-dysostosis may be accompanied by typical coxa vara infantum (LINDEMANN, WEIL). It may, therefore, be concluded that coxa vara infantum is sometimes one symptom of a disease due to a general disturbance of epiphyseal ossification.

Some adherents to the view of a congenital etiology ascribe the lesion to intra-uterine pressure or a disturbance of embryonic circulation. These theories can be neither confirmed nor refuted (WALTER).

As regards my own series it can be stated that the obvious familial occurrence in 2 cases (nos. 27 and 31) and the presence of cleido-cranio-dysostosis and bilateral typical coxa vara infantum in one case (no. 98) constitute evidence in favour of a congenital etiology. By contrast, the data concerning the appearance of symptoms soon after birth are not convincing, since no roentgenological or other objective examination was done in any case when the child was newborn.

The view that coxa vara infantum is a kind of juvenile osteochondrosis resembling Legg-Calvé-Perthes' disease has been advocated by many writers. This conclusion has been drawn from histological investigations, in particular (CAMITZ, BURCKHARDT). However, the examination of the present material does not confirm this theory. In my specimens no necrosis of the bony tissue, which is typical of Legg-Calvé-Perthes' disease, was observable.

A number of investigators have attributed coxa vara infantum to static-mechanical factors and used the denomination weight-bearing deformity (WALTER, PAUWELS, MAGNUSSON). No lesion will develop, however, unless there is a primary disturbance in the metaphyseal portion of the neck of the femur, which PAUWELS, among others, considered to be some condition resembling Legg-Calvé-Perthes' disease.

NAGURA's and BURCKHARDT's respective theories of a mechanico-traumatic etiology were based on animal experiments. The validity of these views has not been proved in any human series. Both previous series and my own include cases in which the onset of the disease was related to a slight trauma, but convincing evidence of a causal relationship is lacking.

At the Invalid Foundation, A. LANGENSKIÖLD & SARPIO have performed animal experiments in order to elucidate the pathogenesis of coxa vara infantum. This investigation has not yet been published, but I have been authorized to make a preliminary report in this connection, since it seems to shed additional light on the pathogenesis of coxa vara infantum.

Report of the experiment: In a 9-day-old rabbit a thin plastic plate was inserted into the medial part of the epiphyseal plate vertically to the long axis of the neck of the femur. The foreign body replaced the medial half

of the zone of cartilage columns of the epiphyseal plate which was partly excised. Roentgenograms of both hips were taken immediately before operation and postoperatively at one-week intervals. After a month, coxa vara was observed in the treated hip, and a triangular piece of bone was detected in the distal portion of the femoral neck (see Figs. 12 a b, and c).

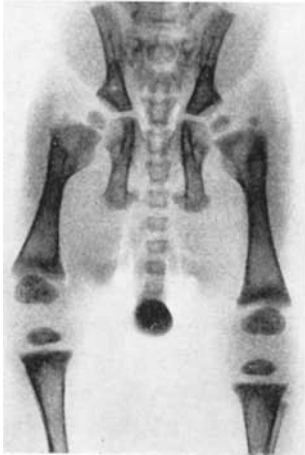

Fig. 12 a.

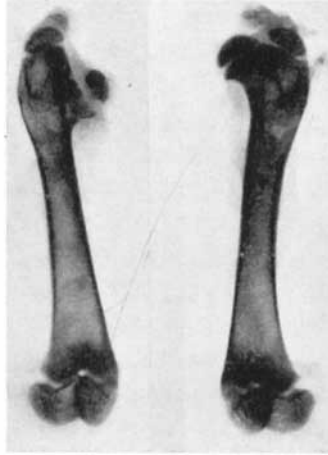

Fig. 12 b.

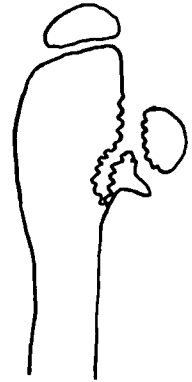


Fig 12 c.

Fig. 12. — Animal experiment by A. LANGENSKIÖLD & SARPIO. a. 9-day-old rabbit immediately before experiment. The hips are normal, b. One month after operation on the right hip coxa vara has developed in the latter. A triangular piece is seen in the distal portion of the neck of the femur. (2 ×). c. Configuration of the affected hip. (Compare with fig. 16 a and 3 I. Cf. text on page 69).

From this result A. LANGENSKIÖLD & SARPIO conclude that a condition closely resembling coxa vara infantum can be produced in rabbits by placing a mechanical obstacle to ossification across the metaphyseal portion of the neck of the femur.

My own impression of the etiology of coxa vara infantum is as follows:

The present histological investigations did not reveal any specific cause of the lesion. In the metaphyseal portion of the neck of the femur no changes typical of rickets, Legg-Calvé-Perthes' disease or any inflammatory disease were observable. By contrast, the histological investigations showed that in the pathogenesis of coxa vara infantum an important part is played by a disturbance of the process of ossification in the medial portion of the neck of the femur. This disturbed ossification results in delayed growth of this part of the femoral neck and in irregularity of the bony structure. In addition,

there are static-mechanical factors to be taken into account, *i.e.* the influence of weight-bearing on this weakened metaphyseal portion of the femoral neck, which finally elicits the typical disease.

There are various causes possibly responsible for the disturbance of endochondral ossification. There certainly exist congenital genetic factors. This is proved by the cases in which a familial occurrence has been reported. The presence of typical coxa vara infantum in cleido-cranio-dysostosis represents another manifestation of these factors. Cases of congenital coxa vara infantum and cases in which symptoms appear at a more advanced age exhibit exactly identical clinical and roentgenological pictures. In my own series and in those of many previous writers (*e. g.* ZIMMERMANN, BADE) the clearly congenital cases are relatively few. In the majority of cases the onset of the disease occurred later. The explanation of the results obtained in animal experiments seems to be that endochondral ossification in the neck of the femur has been locally disturbed by some noxious influence.

The triangular fragment in the distal portion of the neck of the femur has generally been regarded as pathognomonic of coxa vara infantum. Its occurrence is frequent in many lesions of this kind, however, which have in common a disturbance of endochondral ossification and deformity due to weight-bearing. Such a triangular fragment is observable in both tibia vara

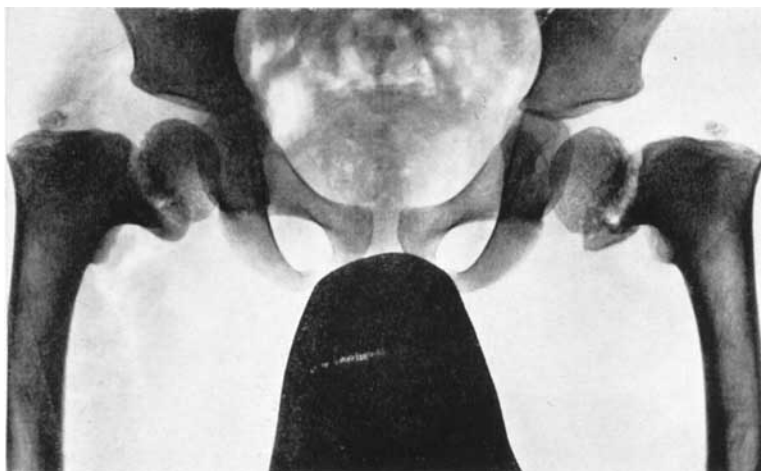


Fig. 13. — Bilateral rachitic coxa vara. A 7-year-old boy with marked varus deformity of both femoral necks. The subcapital epiphyseal plate is almost vertical and broad. In the distal portion of the femoral neck of the left hip a triangular fragment is observable. Marked rachitic changes of bone are present, both tibiae and femora, for instance, showing a marked varus deformity.

(A. LANGENSKIÖLD 1952) and in rachitic coxa vara (KARFIOL, BRAILSFORD, MASSE) (see Fig. 13). Thus, the triangular fragment is not pathognomonic only of coxa vara infantum.

Conclusions

The pathogenesis of coxa vara infantum does not seem to be uniform or invariably due to the same etiological factors. Although different cases may exhibit the same clinical picture, the etiology may be different. Some cases are congenital, and obviously caused by genetic factors. In the majority of cases the etiology is not yet understood. It seems probable that during infancy or early childhood the process of ossification in the neck of the femur is interfered with by some noxious factor, possibly a trauma. The disturbance of ossification in the medial portion of the femoral neck leads to delayed growth in this part and to weakness of the metaphysis. Weight-bearing places a stress on the injured growth region of the neck of the femur. This leads to the deformity typical of coxa vara infantum.

Previously coxa vara congenita was the name mostly used for this condition, but since the last world war the name coxa vara infantum has been more generally adopted in the literature. It was used as early as 1907 by ELMSLIE. Personally I prefer this denomination for the reason that it corresponds better with my views regarding the heterogeneous etiology of the disease.

VIII TREATMENT AND ITS RESULTS

At the Invalid Foundation, the goal of the treatment in the case of children has been to arrest the disease process and correct the malposition that has developed, and simultaneously to preserve the functional capacity of the subcapital epiphyseal plate. Conservative treatment, as for instance traction, rest in bed, etc., has not been used. In adults, in whom the epiphyseal lines of the extremities are already closed, the condition of the hip is final. In these cases we have aimed at correcting the malposition and simultaneously at preserving and, if possible, improving the mobility of the hip.

INDICATIONS FOR OPERATION

The indications for operation have depended on the stage at which the patients have come under treatment.

In *children*, surgery has been regarded as indicated when the roentgenogram showed a coxa vara deformity with a neck-shaft angle of under 110° and obvious changes in the bony tissue of the neck of the femur. Trendelenburg's sign was positive in all these cases. No age limit has been set, and all severe cases have been operatively treated. In mild cases with a neck-shaft angle of over 100° and slight changes in the neck of the femur an expectant attitude has been maintained. These cases have been followed up at regular intervals, and surgical intervention has been resorted to only if an exacerbation has taken place.

In *adult patients without pseudarthrosis* surgery has been regarded as indicated if the neck-shaft angle was under 100° . The cases selected for operation were all ones in which the function of the hip was markedly impaired, Trendelenburg's sign was positive and mobility of the hip was markedly limited. No age limit has been set. The oldest patient operatively treated was 46. Where arthrosis was observed in the hip joint, no attempt at surgical correction of the varus position was made. In these cases the therapy consisted in a palliative operation or symptomatic treatment.

Adult patients with pseudarthrosis of the neck of the femur always constitute the most severely disabled group. As F. LANGENSKIÖLD pointed out in a paper published in 1949 in the *Acta Chirurgica Scandinavica*, they present a special therapeutic problem, which has attracted very little attention in the literature. The majority of the patients with pseudarthrosis which were operated upon at the Invalid Foundation were young (mostly under or just over 20 years old). As a rule, mobility of the hip was relatively good. For this reason the goal of the treatment was to preserve mobility of the hip and simultaneously to improve its weight-bearing capacity. Arthrodesis was not deliberately done in any case.

In evaluating the indications for surgery in patients with pseudarthrosis both the patient's age and the roentgenological state were taken into account. No operation was meditated if the patient was much over 30 years old. The oldest patient operated upon was 34. Furthermore, no operation was attempted if the roentgenogram showed that the head of the femur was markedly atrophic or fused to the acetabulum. In dubious cases roentgenograms were taken with the extremity in different positions in order to find out whether the head of the femur moved in the acetabulum. In cases in which the patient was much over 30 years old or the head of the femur was no longer viable, only symptomatic treatment was given.

OPERATIVE METHODS

I. *Children*. — During the years 1945—1949 a total of 14 children with coxa vara infantum were treated at the Invalid Foundation. In all these cases *sphaeric intertrochanteric osteotomy* was performed. The osteotomy did not reach the neck of the femur, but remained distal to it. The extremity was immobilized in wide abduction in plaster of Paris. The width of abduction was dependent on the degree of the varus position. No internal fixation was used. The plaster was maintained for 6—8 weeks. Since the results were unsatisfactory, Professor F. LANGENSKIÖLD developed a new operative technique, which has been employed at the Invalid Foundation since 1950 in most cases of coxa vara infantum in children. For this operation I use the denomination *F. Langenskiöld's osteotomy*. It has been performed on 43 hips. The operative technique is as follows:

The operation is performed under ether anaesthesia. As a rule, antishock treatment is given in the form of an intravenous drip. The antero-lateral approach is used, the skin incision beginning at the ventral iliac spine, then

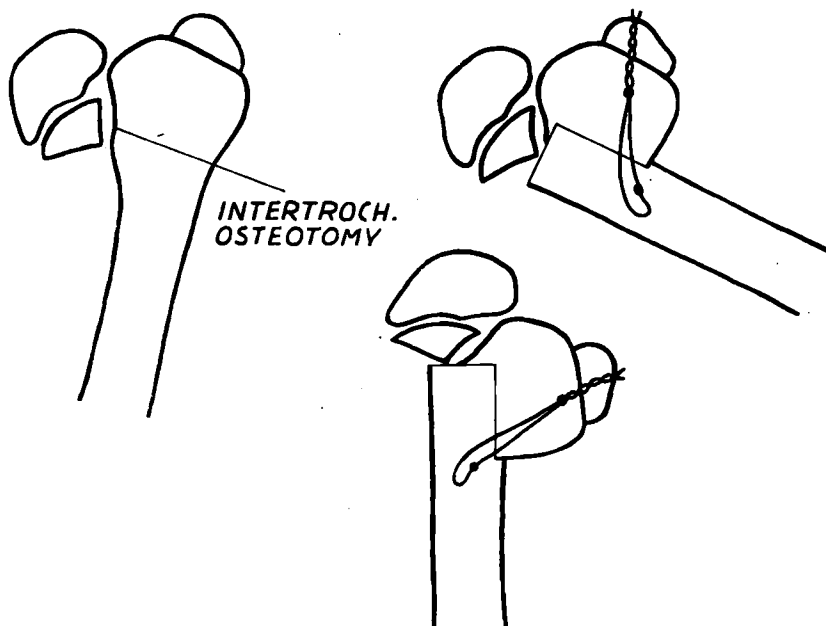


Fig. 14. — F. Langenskiöld's intertrochanteric osteotomy.

running in the distal direction to the border between the upper and middle thirds of the femur and finally curving dorsally. The fascia lata is divided. Between the tensor fasciae latae and the sartorius, the anterior lateral surface of the femur is reached in the intertrochanteric region and exposed subperiostally. Intertrochanteric osteotomy is performed in the way shown in Fig. 14 and Fig. 15 a and b. The osteotomy reaches the vertical gap in the lateral part of the femoral neck, injury to the more medial epiphyseal plate being avoided. Subsequently the lateral surface of the femur is freshened, and the diaphysis is adjusted against the neck of the femur by abduction of the extremity. The greater trochanter is fixed by a wire to the diaphysis and the abduction of the limb is reduced. The head of the femur has then rotated into its normal position. The position is checked roentgenologically.

In some cases in which there was a considerable degree of varus deformity and very little remained of the neck of the femur, the tendon of the iliopsoas presented an unyielding obstacle. Then the lesser trochanter and the tendon of the iliopsoas were detached and refixed subperiostally to the anterior surface of the femur. If the adductor muscles constituted a firm obstacle on abduction of the limb, tenotomy of the surface muscles was performed

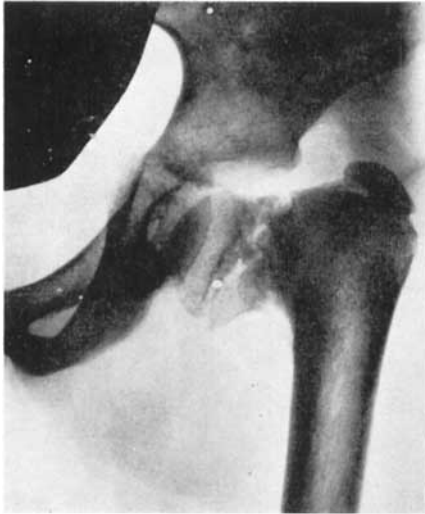

Fig. 15 a.

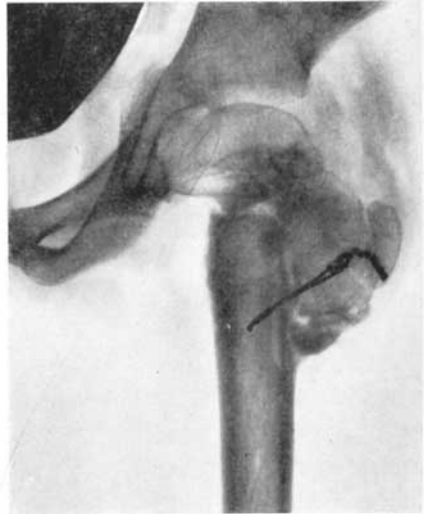

Fig. 15 b.

Fig. 15. — Case 99. a. An 8-year-old girl with typical coxa vara infantum of the left hip. b. Picture taken immediately after the performance of F. Langenskiöld's intertrochanteric osteotomy.

through a small separate incision. After closure of the wound the extremity was immobilized in plaster of Paris in about 20° abduction.

Postoperative treatment. — The plaster was maintained for 6–8 weeks, after which the position and the callus formation were checked roentgenologically. In some cases immobilization had to be continued for another two or three weeks owing to unsatisfactory ossification. In the majority of cases prophylactic penicillin treatment was given for 5–6 days. After removal of the plaster the patient was allowed actively to move the extremity, and after one or two weeks, depending on the position of the hip and the callus formation, to walk. In uncomplicated cases the patients were usually discharged from hospital some 8–10 weeks after operation. The average period of hospitalization was 89 days.

On three hips only *epiphyseodesis of the greater trochanter* was performed. In all these cases the coxa vara deformity was slight (90° – 100°), and there were slight changes in the neck of the femur. The purpose of this operative method is to correct the coxa vara position in such a way that the neck of the femur grows by the activity of the subcapital epiphyseal plate, whilst the growth of the greater trochanter is simultaneously arrested.

II. *Adult patients without pseudarthrosis.* — Four hips belonging to this

group were operated upon at the Invalid Foundation during the years 1945—1948. In these cases *sphaeric intertrochanteric osteotomy* was performed, and subsequently the extremity was immobilized in wide abduction for 6—8 weeks. Internal fixation was not practiced. Since the results with this method were poor, just as they were in the case of children, Professor F. LANGENSKIÖLD abandoned it and introduced the technique described in the foregoing. By this method 9 adult hips with coxa vara infantum have been treated.

From the year 1956 onwards, 4 adult coxa vara infantum hips have been operated upon by a technique including *internal fixation with a McLaughlin nail*. Intertrochanteric osteotomy was performed. In the first of these cases the extremity was, in addition, immobilized in plaster, whilst in the remainder internal fixation was regarded as sufficient. In these, the patients were allowed to move the limb actively immediately after operation, and after about 6—8 weeks to walk.

In one very severe case Judet's arthroplasty was performed.

In one case, in which painful arthrosis deformans had developed in the hip, *McMurray's intertrochanteric osteotomy* was performed. The purpose of this measure was only to relieve the pain. No attempt was made to correct the coxa vara position.

III. *Adult patients with pseudarthrosis*. During the years 1945—1947 *McMurray's intertrochanteric osteotomy* (McMURRAY 1938) was performed at the Invalid Foundation in 6 cases. In no case was the result satisfactory. Hence, Professor F. LANGENSKIÖLD abandoned this method and adopted *Brackett's technique* instead. BRACKETT (1917) used the method in question in old ununited fractures of the neck of the femur. Since 1947, this operation has been performed at the Invalid Foundation in all cases of coxa vara infantum with pseudarthrosis of the neck of the femur.

This operation was performed as follows: Just as in the operation on children's hips, a fronto-lateral incision was made, through which the pseudarthrosis was reached. The femur was divided at the level of the false joint. Subsequently the end of the diaphysis was adjusted by strong abduction and traction of the extremity into a hole drilled in the head of the femur. The diaphysis was inserted as deep into the head of the femur as was possible without breaking the joint surface of the head. By reducing the traction and abduction, the head of the femur was then made to turn into its normal position in the acetabulum. The greater trochanter was fixed by either a screw or a wire to the upper lateral surface of the femur, which was freshened. The extremity was immobilized in plaster for 6—8 weeks. Subsequently

active mobilization of the extremity was commenced, and depending on the degree of consolidation established roentgenologically, walking was allowed one or two months after removal of the plaster.

Since this method of operation presented many technical difficulties, certain changes of the original technique have been introduced during the course of years.

In the first operations the hole in the head of the femur was made with a chisel. In one case this resulted in breaking in two of the head, which then had to be removed entirely. The operation was finished by *Whitman's reconstruction*. Subsequently a drill has been used instead, and no complications of this kind have occurred.

In the beginning, the osteotomy was obviously made too far proximally, and it was therefore difficult to adjust the diaphysis of the femur into the head of the femur. Latterly, the osteotomy has been made at the level of the middle portion of the head. If it is made at the site of the lesser trochanter, this is detached and fixed to the anterior surface of the femur together with the tendon of the iliopsoas.

If necessary, the tension of the abductor muscles is relieved by tenotomy performed through a separate incision.

In the first operations the extremity was immobilized in maximal abduction. In 3 cases muscle tension obviously caused necrosis of the atrophic head of the femur. In order to avoid this, endeavours have been made to adjust the end of the femur into the head of the latter so firmly that turning of the head has been accomplished by reducing the abduction of the extremity.

COMPLICATIONS

No deaths occurred in the present series.

In two cases wound infection developed, which prolonged hospitalization. In one of these cases it was necessary to remove the metal wire used in osteosynthesis. Nonetheless satisfactory consolidation was obtained after osteotomy, and the end result was good in both cases.

In 3 adult patients thrombosis of the lower extremity was observed post-operatively. It was relieved by heparin treatment.

In connection with re-osteotomy on the hip of a child the deep femoral artery was injured, and this gradually resulted in the development of a pulsating haematoma at the proximal portion of the median region of the thigh. Two months after operation the haematoma had to be evacuated and

the deep femoral artery was ligated. The subsequent recovery was uneventful, the osteotomy surfaces had become united prior to this operation.

After removal of the plaster an abduction contracture of about 10° — 30° was observed in 10 patients, 3 of whom were children. In 4 of these cases, in which the contracture had developed after Brackett's operation, it was released by manual redression performed under ether anaesthesia. In 3 cases adduction was hindered by the proximal-medial edge of the diaphysis of the femur, which touched the lower edge of the acetabulum. A piece of bone was removed from this edge of the femur, after which adduction could be accomplished. In 3 hips of children the situation gradually improved within a month's time without any special measure.

RESULTS OF TREATMENT

The evaluation of the results of treatment is difficult for many reasons. From the standpoint of the age of the patients the series is heterogeneous. The age varied between 3 and 46 years. The character of the lesion varied from slight changes to complete pseudarthrosis of the neck of the femur. The results of treatment are essentially dependent on these factors. In patients of growing age, complete or nearly complete healing of the lesion may be attained by operation. In adults, a skeletal deformity cannot be corrected with equal success. Although the varus position is corrected, a deformed femoral head and acetabulum have no longer the same possibility of resuming a normal shape as they have in children.

The follow-up period was in all cases at least one year. In growing children this is not enough. When a lesion is involved in which growth plays an important part, the final results of treatment cannot be confidently evaluated until growth is complete. In operations on the hip joint, an observation time of one year is too short for reliable evaluation of the end result even in adult cases.

In connection with the follow-up investigation, the *questions listed in Table 20 were asked.*

For the evaluation of the results in children these data are of minor significance. The preoperative subjective symptoms were mostly slight, and so also were the postoperative complaints. The belief that the condition of the hip had improved was in the majority of cases based on the fact that the patient had ceased to limp. Since it is difficult to evaluate working capacity in children, this point was left blank.

TABLE 20. — *Data obtained at follow-up investigation*

	Children (62 cases)	Adults (52 cases)	
		No pseud- arthrosis (19 cases)	Pseudarthrosis (33 cases)
Hip			
— improved	56	13	25
— remained the same	4	3	4
— become worse	2	3	4
Pain in the hip			
— none at all	52	16	22
— less than before	4	—	7
— the same	4	2	1
— worse	2	1	3
Use of aids			
— uses none	61	17	28
— uses a walking-stick	—	1	4
— uses arm-crutches	—	—	—
— uses orthopaedic shoe	1	1	1
Working capacity			
— improved	—	5	7
— same as before	—	11	22
— decreased	—	3	4

In regard to adults, on the other hand, the replies to the questions asked are of essential significance from the standpoint of evaluation of the results. In the majority of the present cases the preoperative symptoms were considerable. The improvement achieved by operation was obvious. By contrast, it is not so obvious that the patients' working capacity had improved.

In connection with the *clinical examination* attention was paid to the following points: stability and mobility of the hip, the presence of contracture of the hip, and difference in the length of the lower extremities.

Stability of the hip was evaluated in terms of Trendelenburg's sign. The relevant data are shown in Table 21. The table shows that in 5 cases there are no preoperative data. In these Trendelenburg's sign has probably been positive, owing to the marked severity of the coxa vara deformity. Trendelenburg's sign, which was one of the indications for operation when positive, had become negative in 96 out of 114 cases.

TABLE 21. — Trendelenburg's sign before operation and at follow-up investigation

	Children (62 hips)					Adults (52 hips)							Total		
	Trendelenburg's sign					No pseudarthrosis (19 hips)				Pseudarthrosis (33 hips)					
	+	+	-	-	no data	+	+	-	-	no data	+	+		-	-
preoperat.	59	2	—	1		16	—	—	3		32	—	—	1	114
postoperat.		5	57			4	—	15	—		6	3	24	—	114

Mobility of the hip was evaluated by means of Gade's index. The pre- and postoperative values are shown in Table 22, in which the following observations can be made:

TABLE 22. — Gade's mobility index before operation and at follow-up investigation

	No. of hips	No data	Gade's index										Mean	
			0-9	10-19	20-29	30-39	40-49	50-59	60-69	70-79	80-89	90-100		
<i>Children:</i>	preoperat.	62	10	—	—	1	—	2	4	10	15	16	4	72
	post »	62	—	—	1	1	1	—	4	3	22	19	11	77
<i>Adults:</i>	preoperat.	19	4	—	—	2	—	2	4	2	3	1	1	57
	No pseudarthrosis post »	19	—	1	—	3	1	2	—	4	6	2	—	59
<i>Pseudarthrosis</i>	preoperat.	33	4	—	1	2	1	1	9	8	5	2	—	59
	post »	33	—	5	1	2	3	6	5	8	3	—	—	45

In children and adult patients without pseudarthrosis Gade's index had mostly risen somewhat after operation. By contrast, in the patients with pseudarthrosis it had dropped. The changes were in no case great, however. As a rule, the limited abduction and rotation movements were improved by surgery, whilst flexion and adduction, which were usually good prior to operation, were somewhat limited postoperatively. The stability of the hip attained in the patients with pseudarthrosis mostly caused limitation of movement.

Contracture of the hip was observed in 6 children and 14 adult patients with, and 7 without, psudarthrosis. The corresponding preoperative state was present in 72 hips. Thus, the improvement due to operation is obvious.

The *shortening of the extremity* is of fundamental significance in the evaluation of the results of treatment. The length differences between the extremities pre- and postoperatively appear in Table 23, which reveals the following:

TABLE 23. — *Length difference of lower limbs before operation and at follow-up investigation*

	No. of patients	No data	Length difference of lower limbs in cm.								
			0	1	2	3	4	5	6—8	9—10	Mean
<i>Children</i>											
preoperat.	55	8	3	14	14	10	4	2	—	—	2.1
post »	55	—	13	13	11	8	1	6	2	1	2.1
<i>Adults</i>											
No pseudarthrosis											
preoperat.	15	2	2	—	—	2	—	5	2	2	4.8
post »	15	—	3	—	3	1	1	4	2	1	3.7
Pseudarthrosis											
preoperat.	32	6	2	—	1	4	6	3	9	1	4.7
post »	32	—	3	—	4	5	4	8	8	—	4.1

In the children the length difference was reduced by operation in a large number of cases, and entirely eliminated in some. In certain cases where less satisfactory results were obtained, the length difference increased. In the two adult groups the length difference was reduced in the majority of cases.

Certain *roentgenological findings* made in connection with the follow-up investigation are listed in Table 24. It is seen that in the children an improvement of the rarefied bony tissue in the neck of the femur was observed in all cases. As a rule, healing occurred during hospitalization simultaneously with union after the osteotomy. In those cases where this did not occur, the varus position recurred and reoperation had to be performed, which led to strengthening of the femoral neck.

Growth of the neck of the femur will only continue after operation if the subcapital epiphyseal plate remains open. Of the 41 hips belonging to patients who at follow-up investigation were found to be of growing age, 17 showed an open epiphyseal line. Normally, the line in question forms an angle of 16° with the horizontal (v. LANZ-WACHSMUTH). The wider this angle, the greater is the risk of recurrence of the coxa vara deformity when the hip joint is subjected to weight-bearing.

TABLE 24. — *Roentgenological findings made at follow-up investigation*

Roentgenological findings	Children (62 hips)	Adults (52 hips)	
		No pseud- arthrosis (19 hips)	Pseudarthrosis (33 hips)
<i>Children</i>			
1. Healing of the disturbance of ossification in the femoral neck	62		
2. Epiphyseal lines fused (longitudinal growth completed)	21		
3. Epiphyseal lines open (longitudinal growth still proceeding)	41		
a) subcapital epiphyseal line alone fused	24		
b) subcapital epiphyseal line open	17		
— its angle with horizontal plane under 30°	15		
— its angle with horizontal plane 30°—45°	2		
<i>Patients with pseudarthrosis</i>			
4. Bony union attained			26
5. Persistent pseudarthrosis			6
<i>All patients</i>			
6. Bony union attained after osteotomy	62	19	33
7. Position of apex of greater trochanter			
— at normal level	35	9	7
— at level of upper edge of acetabulum	10	6	16
— above upper edge of acetabulum	17	4	10
8. Femoral neck			
— normal in length	5	1	—
— short or absent	57	18	33
9. Head of the femur			
— normal in shape or slightly deformed	56	11	10
— markedly deformed	6	5	19
— osseous ankylosis of the hip	—	—	2
— dislocation of the head of the femur	—	—	1
— arthroplasty of the hip performed (JUDET, SMITH-PETERSEN, WHITMAN)	—	3	1
10. Arthrosis deformans of the hip	—	3	7

Fusion of the subcapital epiphyseal plate after surgery may be due to various causes, the main cause obviously being the disease itself. The severer the condition, the more frequent was this outcome. In part, the operation itself and the subsequent immobilization in plaster, particularly if the extremity was positioned in wide abduction, were responsible. This becomes evident if the results obtained with different operative techniques are compared. In 7 of the 41 cases mentioned above the intertrochanteric osteotomy initially used was performed, and in 31 Langenskiöld's osteotomy. In the former group, in which the extremity was immobilized in wide abduction, the subcapital epiphyseal plate remained open in only one case against 16 in the latter group.

I have also tried to find out whether the taking of a specimen in connection with operation played any part in the fusion of the subcapital epiphyseal plate. In the above-mentioned group of 41 hips, a specimen was taken from 22, *i.e.* in somewhat more than half the number of cases. Of the 17 cases in which the epiphyseal line in question remained open, only 7, *i.e.* less than fifty per cent, belonged to the group from which specimens were taken. Although I endeavoured not to injure the epiphyseal plate proper, it is possible that in some cases the taking of a specimen played some part in provoking the fusion of the epiphyseal plate.

In the cases with pseudarthrosis the most important goal of treatment, *i.e.* the elimination of the false joint, was attained in 26 cases out of 33.

Normally, the apex of the greater trochanter is situated at the level of the centre of the femoral head (v. LANZ-WACHSMUTH). If it rises considerably higher, weakness of the gluteal muscles and a positive Trendelenburg's sign result. Marked elevation of the apex of the greater trochanter also causes limitation of the hip movements, of abduction in particular. In more than half the number of children (35 out of 62) and in somewhat less than one-third of the adult patients (16 out of 52) the follow-up examination showed that the apex of the greater trochanter was at the normal level.

Apart from elevation of the greater trochanter, shortening of the neck of the femur may cause weakness of the gluteal muscles and a positive Trendelenburg's sign. It is striking that on follow-up examination the neck of the femur was found to be of normal length in only a few cases. The reason for this is obviously that the subcapital epiphyseal plate was so badly damaged that the process of ossification could no longer return to normal.

In a large number of cases, despite the above-mentioned pathological roentgenological findings, the function of the hip was good and Trendelenburg's sign negative (cf. Table 21).

In most cases of the children the shape of the femoral head was much improved after operation. Not in one case was the head of the femur normal before operation and in 33 cases it was markedly deformed. But, on the contrary, in adults the shape of the femoral head was not much improved. In most cases with poor result there has developed a marked deformity.

Arthrosis deformans of the hip joint was observed in 10 adults. All these patients were operated upon during the early years, and the time of observation is therefore longest in these cases. Hence, it seems probable that an increase in the number of arthrosis deformans cases is to be expected in my series with the passage of time.

The most striking postoperative change observable roentgenologically is the improvement of the coxa vara deformity. The neck-shaft angles noted at follow-up investigation are classified in Table 25, 90° and 110° being

TABLE 25. — Neck-shaft angle at follow-up investigation in operatively treated cases

	No. of hips	Neck-shaft angle		
		<90°	90—110°	>110°
Children	62	1	9	52
Adults (No pseudarthrosis)	17*	1	3	13
Total	79	2	12	65

* Two cases have been omitted in which the neck-shaft angle could not be measured because Judet's arthroplasty had been performed.

used as borderline values. The same borderline values are used by MAGNUSON. I did not measure the angle more accurately in the roentgenograms, since the version of the neck of the femur was not exactly determined when the exposures were made. On the basis of the pictures taken in connection with the follow-up investigation it is possible to say with certainty only whether the angle is 90°, or wider or narrower than this. When the angle deviates from 90°, it is possible that the value obtained is greater than the true angle in a larger number of cases than appears in the table. This chance is fairly slight, however, as I have already emphasized in the part entitled Material and Methods.

In any case it is seen in Table 25 that in a total of 79 hips of children and adult patients without pseudarthrosis the neck-shaft angle was corrected so much that it remained under 90° in only 2. Furthermore, with a high degree of certainty it may be claimed that it was between 90° and 110° in only 12, and over 110° in the remainder.

TABLE 26. — *Change in CE angle after operation*

		No. of hips	CE angle			
			<15°	15°—19°	20°—25°	>25°
<i>Children:</i>	preoperat.	62	5	16	39	2
	post *	62	3	13	21	25
<i>Adults:</i>	preoperat.	17	13	2	1	1
	No pseudarthrosis post *	17*	3	3	8	3
Pseudarthrosis	preoperat.	33	30	3	—	—
	post *	33	11	9	10	3

* In two omitted cases Judet's arthroplasty was done. Measurement of the CE angle in the postoperative roentgenograms was not possible.

TABLE 27. — *Evaluation*

	Result groups	History	Clinical investigation			
		Patient's impression of result	Trendelenburg's sign	Gade's index	Contracture of hip	Shortening of extremity
<i>Children</i>	Good	no pain	—	>70	—	0—3 cm
	Fair	—	+—	50—70	slight	4—6 "
	Poor	pain	+	<50	severe	over 6 "
<i>Adults</i> No pseudarthrosis	Good	result good	—	the same or better	—	not increased
	Fair	hip improved	+—	worse	slight	increased 0—2 cm
	Poor	unsatisfactory	+	worse	severe	increased over 2 cm
Pseudarthrosis	Good	result good	+—	the same or better	—	not increased
	Fair	hip improved	+—	worse	slight	increased 0—3 cm
	Poor	unsatisfactory	+	worse	severe	increased over 3 cm

The correction of the varus angle accomplished in the majority of cases explains that Trendelenburg's sign mostly became negative. Thus, it appears that of the factors influencing stability of the hip, the neck-shaft angle is of greater significance than the position of the apex of the greater trochanter, for instance.

The results of determination of Wiberg's CE angle are listed in Table 26. It is seen that in both adults and children the CE angle showed considerable improvement after operation. When the static conditions in the hip joint become normal as a result of operation, both the head of the femur and the acetabulum are normalized to such a degree that no dysplasia is observable any longer. In regard to the adult patients this was apparently possible only for the reason that the majority of them were young. The mean age of the patients with pseudarthrosis was 23 years, and the mean age of

of the results of treatment

Roentgenological investigation						
Uses walking-stick or crutches	Neck-shaft angle	Bony union attained	Position of apex of greater trochanter	Angle of sub-capital epiphyseal plate with horizontal plane	CE-angle	Shape of femoral head, arthrosis deformans of the hip
—	>110°	+	normal or at upper margin of acetabulum	0—30°	>20°	good
—	90°—110°	+	slightly above acetabulum	30—45°	<20°	slight changes
+	<90°	—	very high	over 45°	<20°	marked changes
—	>110°	+	normal or slightly elevated		>20°	slight changes, no arthrosis
—	90°—110°	+	slightly above acetabulum		<20°	no arthrosis
+	<90°	—	very high		<20°	marked changes, arthrosis deformans
—		+	normal or slightly elevated		>20°	slight changes, no arthrosis
—		+	slightly above acetabulum		<20°	no arthrosis
+		—	very high		<20°	marked changes, arthrosis deformans

those without pseudarthrosis was 24 years. The low preoperative CE values are in part due to the fact that the head of the femur was turned somewhat outwards in the acetabulum. After operation the femoral head is pressed deeper into the acetabulum.

According to WIBERG, it is to be expected that arthrotic changes will develop with increasing age in those patients whose CE values are under 20°.

The criteria for evaluation of the results appear in Table 27. As is seen in the table, the evaluation of the results in children is based on the clinical and roentgenological state as observed at follow-up investigation, *i.e.* the *absolute result*. In regard to the adult patients, on the other hand, in some aspects the *relative result* has been taken into account, *i.e.* the change in the condition of the hip achieved by operation. In adults, it is easier to make such a comparison than it is in children, because in the latter growth may cause an essential change in the result.

TABLE 28. — Results of treatment in 114 hips operatively treated and followed up

	Children (62 hips)	Adults (52 hips)	
		No pseudarthrosis (19 hips)	Pseudarthrosis (33 hips)
Good	42	10	10
Fair	14	3	11
Poor	6	6	12

Table 28 shows the results as evaluated on these principles. When the cases are classified into different groups according to the results obtained, the following conclusions can be drawn:

In regard to the *children*, roentgenological examination yields a reliable picture of the results of treatment and of the changes due to growth which are to be anticipated. Forty-two cases are included in the group of good results. An example is afforded by case 39, shown in Fig. 16 a, b and c.

In 5 of the 14 cases belonging to the group with fair results, the neck-shaft angle was between 90° and 110°, in 4 the length difference of the lower extremities was 5—6 cm., and in 7 the position of the greater trochanter was markedly elevated, which caused impairment of the function of the hip. This group is represented by case 26, shown in Fig. 17 a, b, c and d.

In all of the 6 cases in which the results were poor, the main cause of this unsatisfactory outcome was partial necrosis of the head of the femur. Furthermore, in 4 of these cases the function of the hip was poor.

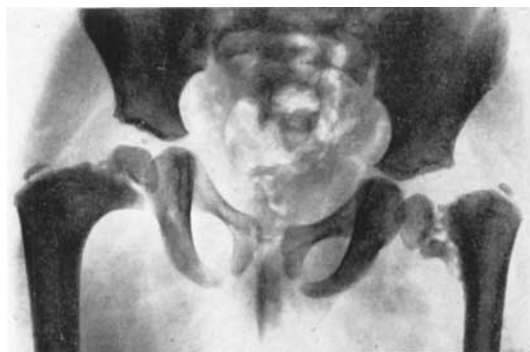


Fig. 16 a.

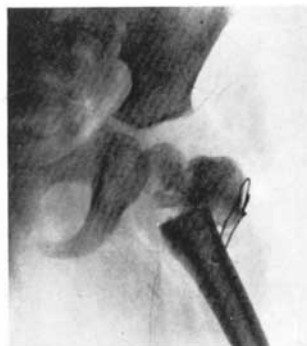

Fig. 16 b.

Fig. 16 a. — Case 39. A girl aged 4 years and 5 months. Relatively marked coxa vara infantum of the left hip. In the right hip a slight varus deformity and slight changes in the metaphyseal part of the femoral neck.

Fig. 16 b. — Case 39. F. Langenskiöld's intertrochanteric osteotomy was performed on the left hip. The picture was taken during operation.

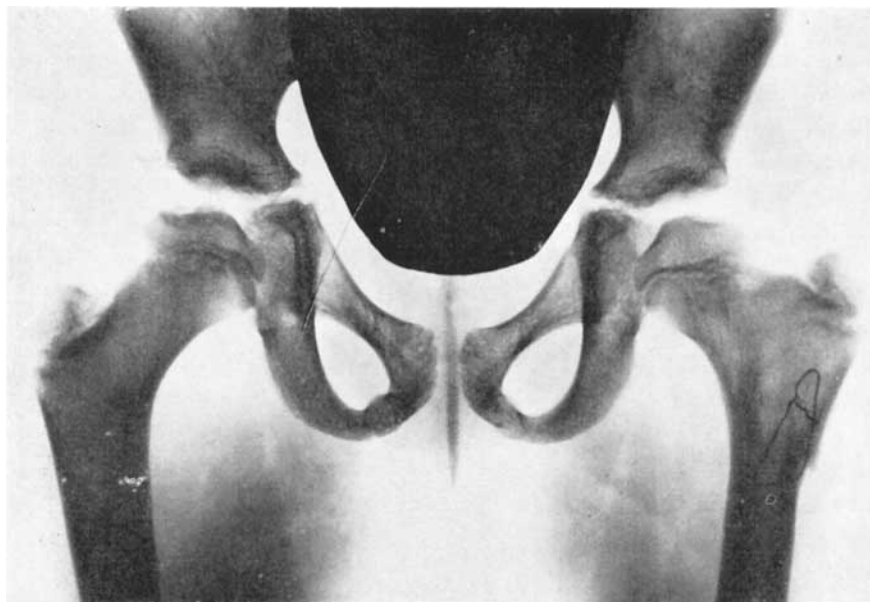

Fig. 16 c. — Case 39. The lesion of the left hip has completely healed 6½ years after operation. The neck-shaft angle is normal. The subcapital epiphyseal plate is open and almost horizontal. The length of the femoral neck is almost normal. The right hip has healed completely without any treatment. Both hips are functionally entirely normal.

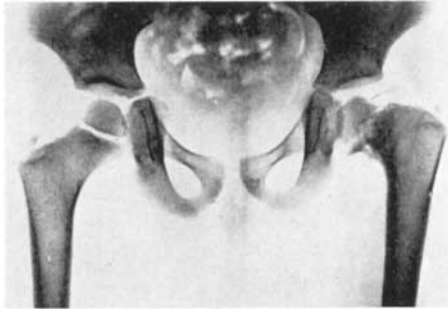

Fig. 17 a. — Case 26. A boy aged 3 years and 9 months. Coxa vara infantum to the left. The neck of the femur is short, with a rarefied structure. Across the femoral neck runs a vertical, broad fissure, which is not distinguishable from the epiphyseal line.

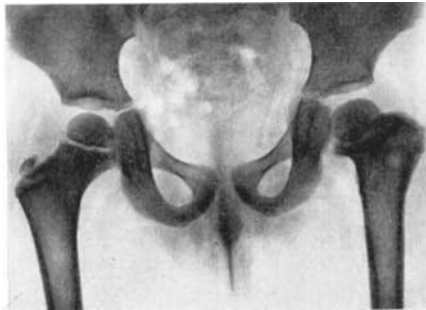

Fig. 17 b. — Case 26. Intertrochanteric osteotomy was performed on the left hip. The picture was taken 2 months after operation. The varus position has been corrected. The subcapital epiphyseal line is thin.

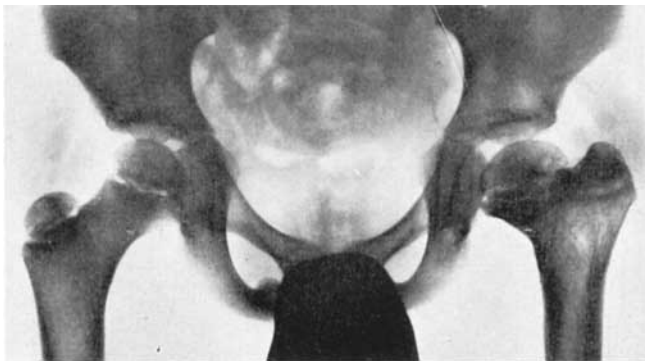


Fig. 17 c. — Case 26. The picture was taken 2 years after operation. The neck-shaft angle is normal. The subcapital epiphyseal line is very thin, almost fused, and the femoral neck is short. The greater trochanter has grown somewhat higher than normal. The function of the hip is good.

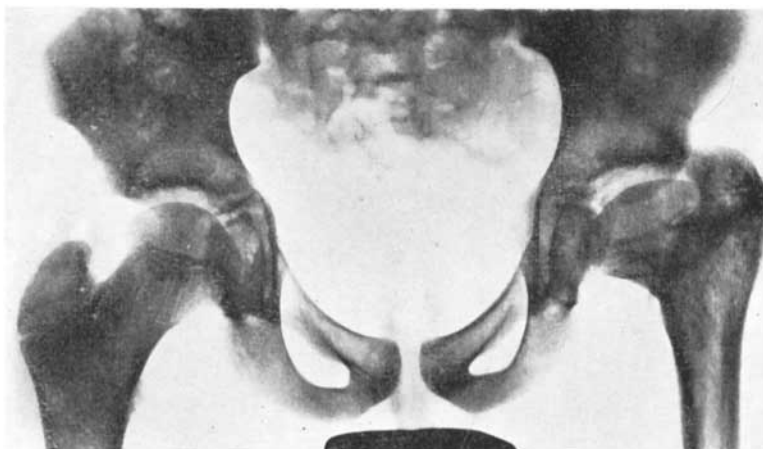

Fig. 17 d. — Case 26. Eight years after operation. The neck-shaft angle is normal. The subcapital epiphyseal plate is fused. The femoral neck has remained very short. The greater trochanter has grown markedly higher than normal. At clinical investigation Trendelenburg's sign was found to be slightly positive, and abduction and rotation of the hip were restricted. The initially good operative result has been impaired owing to the growth of the greater trochanter.

In regard to the *adult patients without pseudarthrosis*, just as in regard to the children, a good roentgenological result invariably meant a good clinical result as well. When the varus position had been corrected, the hip became stable and Trendelenburg's sign became negative. In all the 10 cases in the group with good results the correction of the varus angle was complete, and mobility of the hip had improved in all but 2. Gade's index was 65, at least, in all these cases. Fig. 18 a and b (case 95) represents an example.

In the 3 cases with fair results complete correction of the varus angle was not attained.

The cause of the outcome in the group with poor results (6 cases) was in 3 cases arthrosis deformans of the hip and in one case persistence of the varus deformity. In 2 cases function of the hip was poor.

In regard to the *patients with pseudarthrosis*, too, a good roentgenological result in all cases coincided with a good clinical result. In all the 10 cases included in the group with good results, union of the pseudarthrosis was attained by operation. Furthermore, the hip joint remained mobile, painless and fully capable of weight-bearing. Fig. 19 a, b and c shows a case belonging to this group (no. 70).

Union of the false joint was also attained in all cases included in the group with fair results. In 9 cases the head of the femur was misshapen and mobility

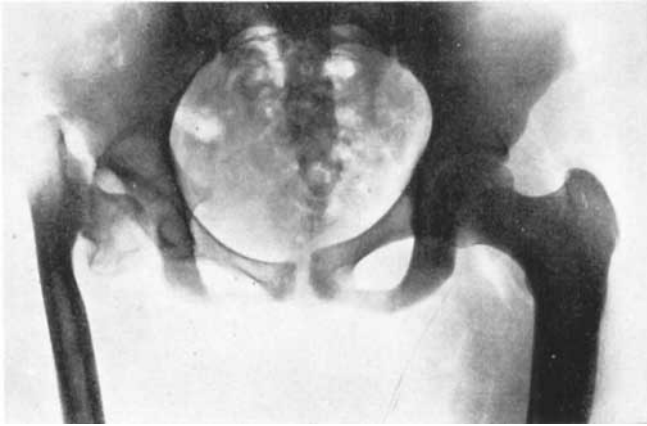


Fig. 18 a. — Case 95. A 16-year-old girl with marked coxa vara infantum to the right. Longitudinal growth has ceased. The neck-shaft angle is 40° , the head of the femur somewhat deformed, and calcaneous atrophy is present. Trendelenburg's sign is decidedly positive. The patient has a marked limp, and mobility of the hip is greatly restricted.

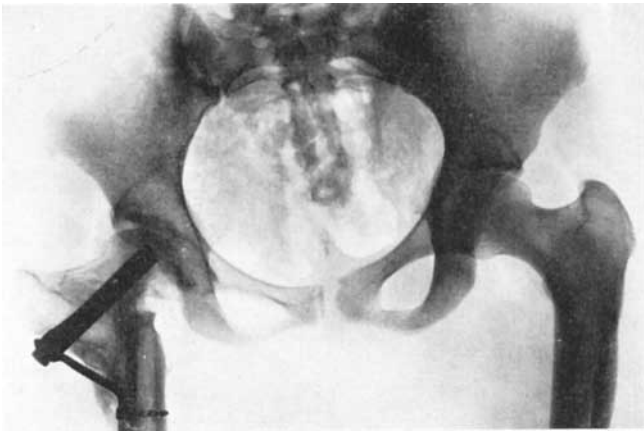


Fig. 18 b. — Case 95. Intertrochanteric osteotomy was performed using fixation with a McLaughlin nail. The picture was taken two years after operation. The varus position of the femoral neck has been completely corrected. The shape of the femoral head and its calcification have improved. Trendelenburg's sign is negative, the patient has no limp, and the mobility of the hip is almost normal.

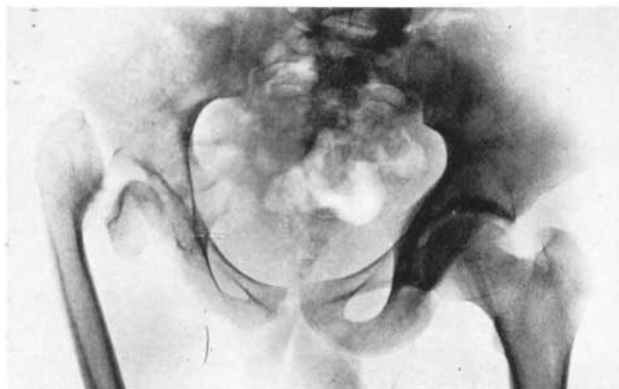


Fig. 19 a. — Case 70. An 18-year-old boy, the son of a farmer. Pseudarthrosis of the femoral neck has developed from coxa vara infantum of the right hip. The head of the femur is completely detached from the neck, but despite considerable decalcification its surface is smooth and its shape is normal. Clinical investigation showed that Trendelenburg's sign was decidedly positive, the patient had a bad limp and mobility of the hip was greatly restricted. Gade's index was 50. Owing to pain in the hip the patient was only able to do light work on the farm.

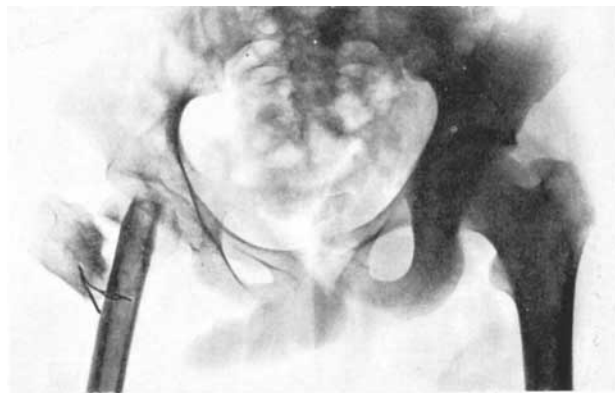


Fig. 19 b. — Case 70. Brackett's operation was performed. The picture was taken during operation.

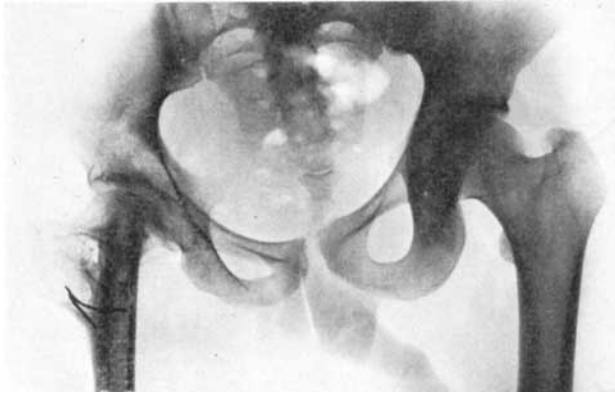


Fig. 19 c. — Case 70. The picture was taken 3 ½ years after operation. The diaphysis of the femur has united with the femoral head and the greater trochanter with the diaphysis. The calcification of the femoral head shows considerable improvement, the surface is even and the shape is good, Trendelenburg's sign is negative, mobility of the hip has improved and Gade's index is 60. The patient works as a farmer and is capable of doing all kinds of heavy work. The hip is painless.

of the hip was impaired. No definite arthrotic changes were observed, however, and Trendelenburg's sign had become negative. In 2 cases the operation led to bony ankylosis of the hip joint. Both these patients were young, 20 and 22 years old, respectively. In spite of this outcome, the postoperative clinical condition obviously represented an improvement. Since in both cases the hip was entirely stable and painless, and the patients themselves were satisfied with the result, I have regarded it as more reasonable to include them in the group with fair results than in the group with poor results.

In the group with poor results (12 cases), the failure was in 6 cases due to non-union of the false joint. In the remaining 6 cases union was attained, but function of the hip was nonetheless poor. Five of these cases exhibited extensive arthrotic changes or partial necrosis of the head of the femur. In one case the head of the femur had slipped out of the acetabulum.

In order to form an opinion on the influence of different factors on the results of treatment, I have analysed the series from the standpoint of the patients' ages at the time of operation, the different operative techniques used and, in children, the postoperative effect of growth on the condition of the hip.

The *influence of age on the result of treatment* in children and adult patients appears in Table 29. It is seen that the earlier the operation was performed, the larger was the number of good results in relation to the number of opera-

TABLE 29. — Results of treatment in different age groups

Age groups	Children				Adults							
					No pseudarthrosis				Pseudarthrosis			
	Good	Fair	Poor	No. of hips	Good	Fair	Poor	No. of hips	Good	Fair	Poor	No. of hips
2—4 years	5	1	—	6								
5—7 »	18	1	1	20								
8—10 »	15	6	2	23								
11—12 »	3	2	2	7								
13—15 »	1	3	1	5	5	—	—	5	2	1	1	4
16—19 »	—	1	—	1	3	—	—	3	3	3	2	8
20—25 »					1	—	2	3	4	4	7	15
26—29 »					—	1	—	1	—	2	—	2
30—46 »					1	2	4	7	1	1	2	4
Total	42	14	6	62	10	3	6	19	10	11	12	33

tively treated cases. It is striking that in both the patients with pseudarthrosis and in those without this condition one good result was obtained in the oldest group, *i.e.* those over 30 years. As a rule, the results were poor, however, in these completely neglected cases.

The results obtained by different operative methods are shown in Tables 30, 31 and 32.

It appears from Table 30 that in *children* relatively the largest number of poor results were obtained by sphaeric intertrochanteric osteotomy, where no internal fixation was used. The cause of the poor result was in all cases partial necrosis of the head of the femur, which was obviously due to the wide abduction in which the extremity was immobilized in order to attain sufficient correction of the varus position. The best results were obtained by F. Langenskiöld's intertrochanteric osteotomy.

TABLE 30. — Results obtained by different operative techniques in children

	Intertroch. osteotomy (no internal fixation)	Langenskiöld's osteotomy	Epiphyseode- sis of greater trochanter	Brackett's operation	Reoper- ated	No. of hips
Good	3	30	2	—	7	42
Fair	6	3	1	—	4	14
Poor	3	1	—	1	1	6
Total	12	34	3	1	12	62

Epiphyseodesis of the greater trochanter was done in 3 mild cases. In 2 of these the improvement has been obvious, whilst in the third case there has so far been no appreciable effect. Since this method of treatment is based on the idea that growth of the neck of the femur will gradually correct the varus position, the follow-up period is as yet too short in all these cases, *i.e.* only a little more than two years. However, the fact that in 2 cases obvious improvement has been attained in such a short time seems to indicate that in mild cases of coxa vara infantum in children good results may be obtained by this small operation. The course of healing in one of these cases (no. 78) is shown in Figs. 20 a, b and c.

The idea of introducing this operation was conceived by A. LANGENSKIÖLD and based on observations made in connection with the operative treatment of congenital dislocation of the hip in children at the Orthopaedic Hospital of the Invalid Foundation. Previously, a piece of bone and cartilage was transferred in these dislocation cases from the region of the greater trochanter to the roof of the acetabulum. After the elapse of a few years it was found on follow-up investigation that typical coxa valga had developed in some cases (LAURENT 1959, Fig. 21 a and b).

Brackett's operation was performed on a child in whom pseudarthrosis of the neck of the femur had developed as a result of an attempt, made at another hospital, to correct the deformity by manual redression. The result was poor owing to the fact that partial necrosis of the head of the femur ensued.

The large number of reoperations (12) is striking. Reoperation had to be performed in 9 cases treated by F. Langenskiöld's intertrochanteric osteotomy and in 3 cases in which sphaeric intertrochanteric osteotomy without internal fixation was done. In all these cases Langenskiöld's osteotomy was performed. In every case, reoperation was necessitated by recurrence of the varus position. As a rule, the mechanism was that after the primary operation, in many cases when the extremity was still in plaster, muscle tension brought about bending of the proximal portion so that the diaphysis slipped upwards. The fixation of the bony surfaces by a wire, the technique employed in Langenskiöld's operation, is obviously inadequate, since recurrence of the varus position was so frequent.

The results in the *adult patients without pseudarthrosis* obtained by different operative methods appear in Table 31. Intertrochanteric osteotomy without internal fixation was done in 4 cases, but on account of the unsatisfactory result reoperation was later necessary in 2 cases. Langenskiöld's osteotomy was performed in 9 cases, likewise followed by reoperation in 3 cases. The

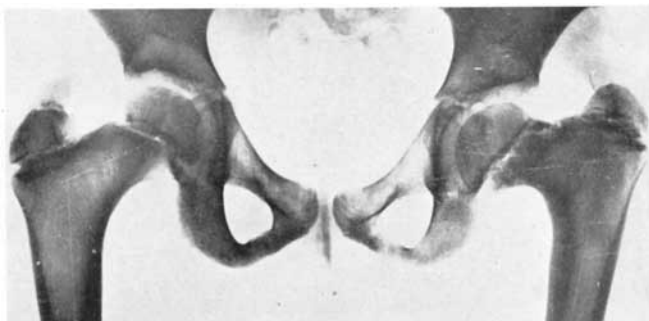


Fig. 20 a. — Case 78. A 7-year-old girl with slight coxa vara infantum of the left hip. The neck-shaft angle is 90° , the bony tissue in the metaphyseal part of the femoral neck is rarefied in a narrow area. No vertical fissure or triangular fragment are observable. The clinical symptoms are slight, Trendelenburg's sign is \pm , the limp is slight. Owing to the slight degree of the lesion it was decided not to operate, but to keep the case under observation.

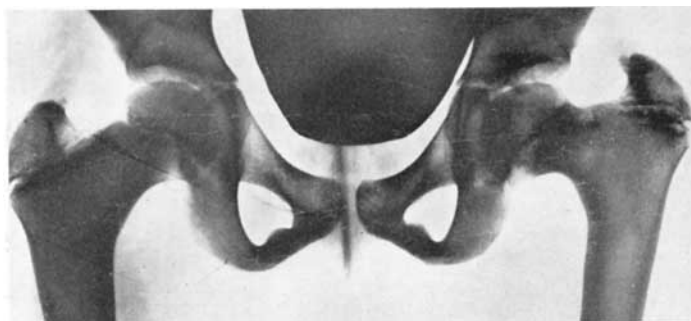


Fig. 20 b. — Case 78. The picture was taken 3 years later than Fig. 20 a. The patient had been kept under observation during this time. The condition is somewhat impaired: The greater trochanter has grown somewhat higher, the neck-shaft angle is still 90° , the bony tissue in the lateral aspect of the subcapital epiphyseal plate is still rarefied. The limp is more conspicuous and Trendelenburg's sign is now clearly positive. *Epiphyseodesis of the greater trochanter was performed.* Since the lesion was relatively slight, osteotomy to correct the varus position was regarded as too radical a measure.

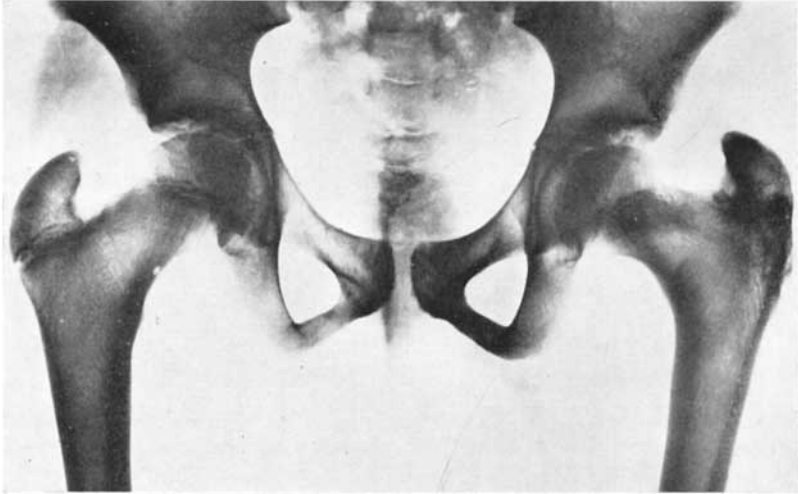


Fig. 20 c. — Case 78. The picture was taken 2 years and 3 months after the performance of epiphyseodesis of the greater trochanter. The neck-shaft angle is now 110° . The apex of the greater trochanter is still situated somewhat higher than normal, but its epiphyseal line has fused. The subcapital epiphyseal line is open, although it is narrower than on the right side. The bony tissue of the metaphyseal portion is no longer rarefied. The femoral neck has grown in length. The patient has no limp. Trendelenburg's sign is negative.

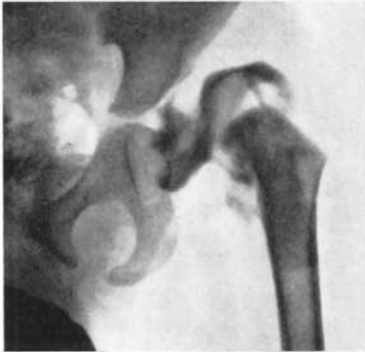

Fig. 21 a.

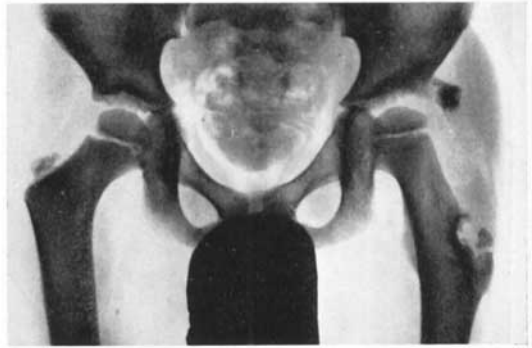

Fig. 21 b.

Fig. 21 a. — A boy aged 1 year and 8 months. He had congenital dislocation of the left hip, as revealed by the arthrogram. Operative reduction was performed, and the roof of the acetabulum was reinforced by a transplant from the greater trochanter.

Fig. 21 b. — The same case as in Fig. 21 a. This picture was taken $4\frac{1}{2}$ years after operation. A striking degree of coxa valga has developed in the left hip. (cf. text on page 96).

TABLE 31. — Results obtained by different operative techniques in patients without pseudarthrosis

	Intertroch. osteotomy (no internal fixation)	Langenskiöld's osteotomy	Intertroch. osteotomy (fixation with McLaughlin nail)	Judet's arthroplasty	McMurray's intertroch. osteotomy	Re-operated	No. of hips
Good	1	3	4	—	—	2	10
Fair	—	2	—	—	1	—	3
Poor	1	1	—	1	—	3	6
Total	2	6	4	1	1	5	19

cause of the unsatisfactory results obtained by these two operations was either the development of severe arthrosis deformans of the hip or persistence of the varus position. The immobilization of the extremity in wide abduction after sphaeric intertrochanteric osteotomy apparently caused necrosis of the head of the femur. The poor results of F. Langenskiöld's osteotomy are in part attributable to the protracted immobilization in plaster, in part to the advanced age of the patients, who were all over 30 years old.

The best results were obtained by intertrochanteric osteotomy where internal fixation with a McLaughlin nail was used. The result was good in all the 4 cases treated by this technique, the most significant factor obviously being that no immobilization in plaster was required thanks to the good internal fixation. The extremity was immobilized in plaster only in the first of the cases treated by this method. Since the patients were allowed active mobilization of the extremity immediately after operation, the drawbacks of protracted plaster immobilization have been eliminated (cf. Fig. 18 a, b).

In one case (a 40-year-old man) Judet's arthroplasty was done. The hip joint functioned well for five years, but then the acrylic prosthesis showed signs of giving way, which led to a rather unsatisfactory result.

McMurray's intertrochanteric osteotomy without correction of the varus position was performed in a case with painful arthrotic changes. Some improvement was attained.

As reoperation Langenskiöld's osteotomy was done in 3 and arthroplasty of the hip in 2 cases. After the former the result was good in 2 cases and poor in one. The arthroplastic operations, Judet's and Smith-Petersen's, gave poor results owing to a very severe coxa vara deformity and a shallow acetabulum in both cases.

The results obtained by different operative methods in *adult patients with pseudarthrosis* appear in Table 32. It is seen that the poorest results were

TABLE 32. — Results obtained by different operative techniques in patients with pseudarthrosis

	McMurray's intertroch. osteotomy	Brackett's operation	Whitman's reconstruction	Reoperated	No. of hips
Good	—	10	—	—	10
Fair	—	8	1	2	11
Poor	4	6	—	2	12
Total	4	24	1	4	33

obtained with McMurray's osteotomy. It was done as a primary operation in 6 cases, not one case having a good or even fair result. Union of the false joint was not attained in any case, either.

The best results were obtained with Brackett's operation. It was performed as the primary operation in 26 cases and in 23 of these union of the false joint was attained (cf. Fig. 19 a, b and c).

In one case in which Brackett's operation was attempted, the operation was finished up as Whitman's reconstruction for the reason that the head of the femur broke in two. After a follow-up time of 8½ years the result was found to be clinically fair. The patient was satisfied, since the hip was painless and completely capable of weight-bearing. It was rather stiff, however, Gade's index being 44.

Re-operation was performed on 4 hips, in 2 cases after McMurray's and in 2 after Brackett's operation. In 2 cases the reason was non-union of the false joint. Consolidation of the pseudarthrosis and a fair result were attained with Brackett's operation in both of them. In 2 cases the primary operation led to painful arthrosis deformans of the hip. McMurray's intertrochanteric osteotomy and denervation of the hip joint were performed. There has been some improvement, but owing to arthrosis the final result is poor.

The results in children were influenced not only by the above-mentioned factors, but frequently also by *postoperative growth*. As emphasized in the foregoing, the upward growth of the greater trochanter affected the result of treatment in certain cases. In 7 cases out of those 14 in which the result was evaluated as fair, this growth was responsible for the fact that the primary operative result was gradually impaired. This course of events is exemplified by case 26, shown in Figs. 17 a, b, c and d.

In order to eliminate the risk of such an unsatisfactory outcome due to growth in a wrong direction, epiphyseodesis of the greater trochanter was performed in a total of 5 cases during the years 1958—1959. In these, the

varus position had been corrected by the primary operation, but the subcapital epiphyseal plate had become closed and the greater trochanter had grown somewhat higher than normal. Since all these patients were still of growing age, being between 7 and 13 years old, epiphyseodesis of the greater trochanter was performed. No untoward effects have appeared, but the results of this operation cannot yet be evaluated owing to the short time of observation.

The upward growth of the greater trochanter resulting from closure of the subcapital epiphyseal plate cannot be ascribed to the operation alone. The subcapital epiphyseal plate may become fused even without surgical intervention, as appears in Table 10, which includes 4 such patients of growing age. It is precisely owing to premature fusion of the subcapital epiphyseal plate that the proximal portion of the femur develops the shape which is typical of coxa vara (cf. Fig. 22).

In connection with the follow-up investigations, I observed that in children in all cases with a poor result (totalling 6), the cause of the failure was partial necrosis of the head of the femur. In two cases this was observed soon after operation, when the patient was still in hospital. Obviously this development was an immediate result of operation and immobilization in plaster. In the remaining 4 cases the patients could be followed up only for some 3 months after operation. At this time bony union of the osteotomy had occurred and the position of the hip was satisfactory. After about half a year limping began again, however, but the patients did not come to hospital until summoned several years later. Then it was found in all these cases

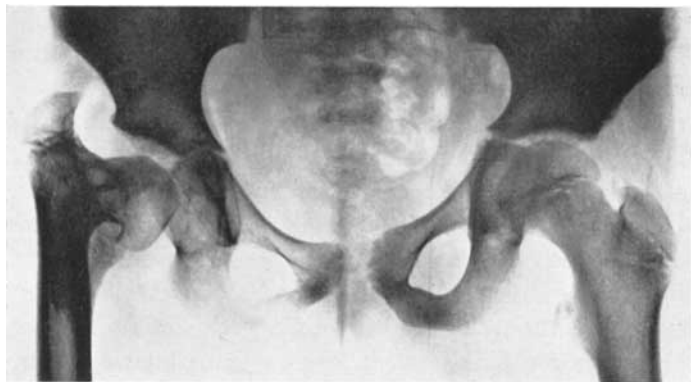


Fig. 22. — Case 115. A 12-year-old girl, who had not received any treatment. Typical coxa vara infantum to the right. The subcapital epiphyseal plate is fused, the epiphyseal plate of the greater trochanter is open.

TABLE 33. — *Results of treatment in coxa vara infantum*

Author	No. of operated cases	No. of cases with good result	Remarks
G. DUNCAN 1938	23	18	Age of patients: 1—15 yrs. All operated by subtroch. osteotomy.
TH. HORWITZ 1948	17	3	Age of patients: 3 ½—15 yrs. Various operations performed.
F. W. HARK 1950	17	11	12 early cases by subtroch. osteotomy, 5 advanced cases (pseudarthrosis) treated by Whitman's reconstruction.
K. JOHANNING 1952	30	19	Age of patients: 3—47 yrs. (4 over 15 yrs.) All treated by subtroch. osteotomy.
K. MAGNUSSON 1954	47	24	Age of patients: 3—30 yrs. (9 over 15 yrs.). All treated by subtroch. osteotomy.
Present series	114	62	Age of patients: 3—46 yrs. (52 adults, 62 children). Various operations performed.

that the head of the femur was exceedingly deformed, obviously as a result of partial necrosis.

Necrosis of the proximal portion of the head of the femur, although slight, was also observed many months after operation in 2 other children's hips. In one case recovery was achieved by applying a Thomas's splint for half a year. In the other case the head of the femur gradually healed with bed rest at home for about 3 months.

The last-mentioned 2 cases seem to afford a clue to the poor result in the 4 described above. In the latter, the head of the femur, which was atrophic after operation, had been persistently subjected to the strain of weight-bearing. If careful follow-up examinations had been made at regular intervals, incipient flattening of the head would have been noticed at an early stage, and by rest or the use of a Thomas's splint it might have been possible to prevent impairment of the condition.

It is difficult to compare the present results of treatment with those of other writers, since the series reported differ considerably from each other in regard to indications for operation, operative methods and evaluation of the results. Only a few authors have distinguished between adults and children or between the different types of the lesion, and others have made a distinction between children and adults according to a certain age limit

instead of drawing the line at the time of completion of growth, as was done in my series. In order to facilitate comparison I have made a table (Table 33) including only good results. It appears from this that my results show a good correspondence with these reported by others.

UNTREATED CASES

The present series includes 9 untreated patients. In addition, one side was not treated in 19 patients with bilateral coxa vara infantum.

The reason why the above-mentioned 9 patients were discharged untreated was in all cases the severity of the lesion. They were all adults who had either pseudarthrosis of the femoral neck or marked arthrotic changes of the hip. In 8 cases the lesion was bilateral. The majority of these patients had moreover reached a relatively advanced age, their average age being 34 years. Attempts were made to improve their situation by social readjustments.

In the 19 cases mentioned above one side was operated upon whilst the other side remained untreated. Nine of these patients were children who had a very slight degree of coxa vara infantum in the untreated hip, visible only in the roentgenogram. Since clinically the hip was symptom-free, an expectant attitude was adopted. In 4 of these cases it was found at follow-up examination that complete healing had taken place. In the remaining 5 cases the lesion was either improved or unchanged. No exacerbation was observed in any of these cases.

In 4 of the 10 cases of bilateral coxa vara infantum in adults, the lesion was so slight on one side and the clinical symptoms so mild that no operation was meditated. By contrast, 6 patients had a severe lesion in both hips. In all of these cases a painful pseudarthrosis of the femoral neck was present on one side. This was operatively treated, but the result was satisfactory in only 2 cases. The contralateral hip was not operated upon, the reason being in part the failure of the operation performed, in part the fact that the untreated side gave less trouble and the patient was satisfied with the result already obtained by the treatment of the severer lesion.

IX DISCUSSION

Etiology and Pathogenesis. The vertical gap in the femoral neck visible in roentgenograms of children has been given a variety of names, *e.g.* »zone of rarefaction», »Zerstörungszone», »Trümmerzone», »Erweichungszone», »Umbauzone», »vertical fissure», »insufficiency fracture», according to the view held by the writer regarding the etiology of the lesion.

One of the most common views is that coxa vara infantum is a weight-bearing deformity and that the gap in question is an »insufficiency fracture», which at a later stage may lead to real pseudarthrosis. The fracture is thought to develop only when a sufficient degree of varus position has been reached (MAGNUSSON). But according to my view, the coxa vara deformity -- bending of the neck of the femur -- is a secondary phenomenon, since it does not invariably develop even if considerable changes are observable (cf. Fig. 23). This seems to indicate that the cause of the coxa vara infantum deformity is a disturbance in the ossification of the subcapital epiphyseal plate, which manifests itself in the formation of a partially double or λ -shaped epiphyseal plate and in delayed ossification of the medial portion of the neck of the femur. Owing to the consequent weakness, the neck of the femur secondarily begins to yield to the strain of weight-bearing, which is an additional factor provoking the varus deformity.

This view is corroborated by the histological investigations which I have performed. The specimens taken extended as far as to include the vertical gap. Histologically the latter was found to be an abnormal epiphyseal plate. The primary cause of the disturbance of ossification was not revealed by the histological investigations, however.

As already emphasized in the part entitled Physiology, Mechanics and Statics of the Hip Joint, page 18, the shape of the proximal portion of the femur is essentially dependent on the process of ossification in the epiphyseal plates of the head of the femur and the greater trochanter. A coxa vara deformity develops when the activity of the subcapital epiphyseal plate is disturbed or prematurely comes to a standstill (cf. Fig. 22). A coxa valga

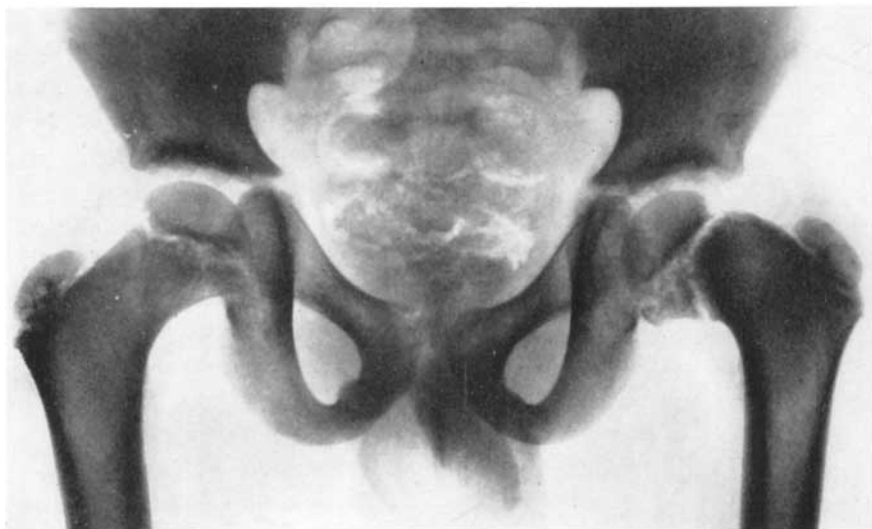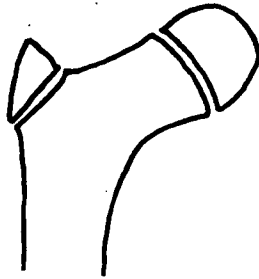


Fig. 23. — Case 66. An 8-year-old boy with coxa vara infantum of the left hip. The subcapital epiphyseal plate is divided into two in its distal portion, and the bony tissue of the triangular portion between them is rarefied. The femoral neck is shorter than normal. Notwithstanding the great structural changes in the femoral neck the varus deformity is slight, the neck-shaft angle being 110° .

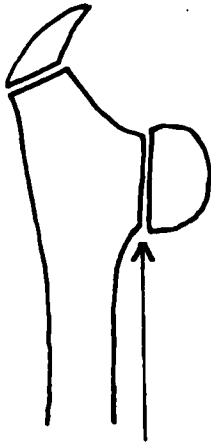
deformity, on the other hand, develops when the activity of the epiphyseal plate of the greater trochanter is disturbed or prematurely ceases (cf. Figs. 21 a and b).

In Fig. 24 I have tried to demonstrate diagrammatically the essential part played by growth in the development of coxa vara and coxa valga. *These deformities result from a disturbance of growth in the epiphyseal plates of the proximal portion of the femur.*


Clinical and roentgenological features. It would not be in accordance with our principles at the Invalid Foundation to follow a case of coxa vara infantum from early childhood to adulthood without attempting to cure the lesion. By classifying the patients according to age, however, it is possible to form a general opinion on the course of development of the lesion. It appears from the roentgenograms of children of different ages that changes are present not only in the neck of the femur, but in the whole of the proximal portion of the femur and in the pelvis, too (LINDEMANN). My material shows that dysplasia of the hip joint develops with increasing age and with increasing degree of severity of the lesion. When the deformity is corrected by surgery, the changes in question improve to a considerable extent, however, sometimes



Normal configuration of the proximal portion of the femur in children



Disturbance of ossification in the subcapital epiphyseal plate → coxa vara.



Disturbance of ossification in the epiphyseal plate of the greater trochanter → coxa valga.

Fig. 24. — The diagrams show the development of coxa vara and coxa valga as the result of disturbances of ossification of the epiphyseal plates. If the ossification of the subcapital epiphyseal plate is disturbed coxa vara develops. If, on the contrary, the ossification of the epiphyseal plate of the greater trochanter is disturbed coxa valga is resulting.

even completely. The earlier the lesion is treated, the more complete is the correction of the dysplasia. Simultaneously the changes in the proximal portion of the femur and in the pelvis are normalized. This constitutes strong evidence in favour of the belief that these changes are secondary.

As a rule, the disturbance of ossification of the epiphyseal plate is considerable and in the majority of cases remains a significant factor until the completion of growth. It manifests itself either in fusion of the subcapital epiphyseal plate after operation, or as a narrowing of this plate in comparison

with the corresponding plate in the normal extremity. In the majority of cases it was found at follow-up investigation that the neck of the femur was shorter than normal. Nonetheless, a complete return to normal may be attained by surgery, if the operation is done at a sufficiently early stage (cf. Fig. 16 a, b and c). Complete healing without any treatment has also been reported (JERRE, LINDEMANN).

A steady impairment of the lesion after the completion of growth is due to erroneously applied weight-bearing. The varus deformity increases, and so does the dysplasia of the joint. In patients with pseudarthrosis the head of the femur, which does not participate in weight-bearing, becomes atrophied and sometimes fused with the acetabulum. The neck of the femur, which is not utilized, is resorbed.

Treatment. As mentioned in the survey of the literature, in the treatment of coxa vara infantum it is imperative to pay attention to the circulation and static-mechanical conditions of the hip joint. Since it has been shown that during almost the whole of the growing period the head of the femur is supplied solely by the vessels of the capsule, the circulation of the femoral head is liable to become injured. Operations involving the neck of the femur or plaster immobilization in wide abduction may damage the vessels of the capsule. Some of the poor results in my series seem to be explicable on this basis. As previously emphasized, another possible cause of failure is the strong pressure exerted by the adductor muscles. In the conservative treatment of congenital dislocation of the hip in children these facts have been taken into account (HILGENREINER, NAGURA, LAURENT).

Since in adult life the vessels running through the ligamentum teres play an important part in the circulation of the head of the femur, the latter may remain viable even in patients with pseudarthrosis of the femoral neck thanks to this circulation. The good results obtained with Brackett's operation constitute evidence of this.

Under normal conditions the head of the femur is subjected to a considerable amount of weight-bearing owing to the fact that when the pelvitrochanteric muscles are stretched on walking, the pressure on the femoral head is greatly increased. In coxa vara this pressure is markedly reduced since muscle tension is smaller (PAUWELS, MÜLLER). When the statics of the femur are normalized after operation, the pressure on the head of the femur is greatly increased owing to the increased muscle tension. In my opinion this explains why necrosis of the proximal portion of the head of the femur is sometimes observed a few months after operation, when the patient has begun to walk. In these cases it seems probable that the head of the femur

was poorly calcified, as is often seen in coxa vara infantum in children, and therefore could not withstand the greatly increased strain of weight-bearing.

According to the literature, conservative treatment during childhood is completely unsuccessful (BADE, NILSONNE, LEMESURIER). In my series conservative treatment (rest in bed, traction) was attempted in 20 children before the patient came to the Invalid Foundation, but without any result whatsoever. Nonetheless, in mild cases there may be reason for assuming an expectant attitude and keeping a watch on the development of the lesion (JOHANNING). This was also seen in my series, inasmuch as out of 9 patients with mild coxa vara infantum in childhood 4 recovered completely without any treatment.

The intertrochanteric osteotomy introduced by F. LANGENSKIÖLD in the treatment of coxa vara infantum in children resembles PAUWELS' intertrochanteric osteotomy, *i.e.* the Y-osteotomy. PAUWELS stated that intertrochanteric osteotomy is theoretically preferable to subtrochanteric osteotomy for the reason that the former corrects the varus deformity as near the affected area as is possible. Thus, the deformity has a better chance of being corrected. The disadvantage of Langenskiöld's osteotomy as compared with subtrochanteric osteotomy is that it is a more extensive and more difficult operation. Furthermore, the rate of recurrence has been relatively high. This appears to be attributable to the fixation with wire, however, which is obviously inadequate.

Subtrochanteric osteotomy has not been performed at the Invalid Foundation. DUNCAN, who operated upon 23 hips by this technique, regards it as a conservative method of treatment because it is so simple. However, in JOHANNING'S series (30 hips treated by subtrochanteric osteotomy) the main factors impairing his otherwise good results were insufficient correction of the deformity and inadequate internal fixation.

Those numerous operative methods which involve drilling of the neck of the femur or the application of a bone transplant through the latter (ZADEK, LEMESURIER, HORWITZ) must be condemned on theoretical grounds for the reason that they aim at fusion of the subcapital epiphyseal plate. In patients of growing age it is necessary for a good result that this epiphyseal line should remain open.

DUNCAN'S view that surgery may be postponed till the age of 6—8 years, since at this age the lesion is not yet severe, is not corroborated by the present investigation. Table 29 shows that the younger the patient at the time of operation, the better are the results. This is in agreement with JOHANNING'S and MAGNUSSON'S findings.

An important conclusion to be drawn from the present results is that in the treatment of children, postoperative follow-up investigations at regular intervals are essential. The growth of the greater trochanter may change the result entirely. Similarly, partial necrosis of the head of the femur, sometimes observed as a late complication, may impair an initially good result. If measures are taken in time, it is possible to avoid this regrettable turn of events.

Postoperative growth is not an altogether negative factor. Epiphyseodesis of the greater trochanter, which is sometimes performed on children in mild cases of coxa vara infantum, is based on the principle that the growth of the subcapital epiphyseal plate will tend to correct the varus position, when growth of the greater trochanter is arrested. As early as the 1920's, BRANDES elaborated an operative technique based on the same principle. He performed resection of the greater trochanter in order to eliminate the traction of the pelvitrochanteric muscles. Thus, the growth of the subcapital epiphyseal plate can exert a correcting influence on the varus position. Both these operative methods are based on the same biological phenomenon, namely, growth of the epiphyseal plate.

The treatment of adults is a difficult problem. These cases are neglected, but fortunately they have become increasingly rare. The more often coxa vara infantum is treated in childhood, the less frequently is the lesion observed in adults. This is clearly discernible in the composition of the number of patients with coxa vara infantum annually admitted to the Invalid Foundation. The ratio adults to children has steadily decreased.

It is difficult to compare the present results of treatment of patients with pseudarthrosis with the data found in the literature for the reason that the reports are based on so few cases. Under certain conditions Brackett's operation, which was used in this series, yields a good result. For this to be so, it is essential that the head of the femur should be viable, which implies that the upper age limit of the patients must be comparatively low. From roentgenograms it is difficult to judge with confidence whether the head of the femur is still viable. Obviously this has been an important cause of the failures. The patient's age alone is not a decisive factor. My series includes a 31-year-old patient who was operated upon with a good result, which shows that the head of the femur may remain viable until this age. In order to attain good results it is necessary not only to determine the correct indications for operation, but also to use the right operative technique. This is borne home by the experiences made at this hospital during the first few years covered by the present investigation, discussed by F. LANGENSKIÖLD in a relevant paper.

The treatment of adult patients without pseudarthrosis presents the same difficulties as the treatment of those with this lesion. In regard to indications for operation, the patient's age and the presence of arthrotic changes in the hip joint are obviously more significant factors than the extent of the varus deformity. In a condition showing such wide variation as does coxa vara infantum, it is difficult to establish any universally applicable indications for operation. In my opinion, good results depend to an equal degree on the choice of the right operative technique as in regard to patients with pseudarthrosis. The technique employed latterly in the present series, namely, fixation with a McLaughlin nail, which makes immobilization in plaster unnecessary, seems to be the best operative method. Probably it will be possible with this method to widen the indications for operation in regard to age, at least.

X SUMMARY

The investigation is based on a series of patients with coxa vara infantum treated at the Orthopaedic Hospital of the Invalid Foundation, Helsinki, during the years 1944—1958. The total number of patients is 115, the number of pathological hips 154. The patients operatively treated and followed up numbered 102, the hips operated upon and followed up 114. Of these, 62 were children's hips, whilst 52 hips belonged to adult patients. The follow-up period varied from 1—13½ years, the average being 5 years and 8 months. In connection with operation a specimen for histological investigation was taken from the metaphyseal portion of the neck of the femur of 25 children's hips. The age of these patients varied from 3—18 years. For the sake of comparison and in order to shed light on the normal histological development of the subcapital epiphyseal plate and the metaphysis of the neck of the femur, specimens were taken post mortem from 19 subjects aged 1 day to 20 years.

The present series is uniform in the sense that all patients were treated at the same hospital and on the same principles.

Clinical and roentgenological features. — The series is divided into children and adults, and the latter into patients without pseudarthrosis and patients with this condition. The case histories afford corroboration of the view that in the majority of cases no symptoms appear until after the first year of life, or when the patient has begun to walk. In the whole series the lesion can confidently be considered as congenital in only 2 cases, namely, in one case of cleido-cranio-dysostosis and in one of congenital short femur. Only 2 instances of familial occurrence were observed. In the majority of cases no other bone diseases could be detected.

Development of the lesion during the period of growth. — In a series of diagrams illustrating the roentgenological changes observed I have tried to depict the development of the lesion from its earliest stage throughout the whole of the growing period such as it obviously would be in untreated cases

(Fig. 3, page 39). During the growth period the disturbance of ossification in the neck of the femur seems to cause similar roentgenological changes in patients of the same age. This shows that the process of growth plays an essential part in the development of coxa vara infantum.

Histological changes. — Specimens were taken from the medial metaphyseal portion distally of the subcapital epiphyseal plate from sites determined on the basis of roentgenograms (cf. Fig. 6, page 48). Frontal sections were made in order to obtain some idea of the course of ossification and to compare the histological findings with the X-ray pictures.

The histological investigations showed, among other things, that the zone of rarefaction running across the neck of the femur in the roentgenograms consisted of cartilage resembling that of the epiphyseal plate, but mostly with a markedly disturbed cell arrangement. The process of ossification was severely disturbed and as a rule weak. The metaphyseal bone was atrophic and sometimes contained large islets of cartilage. Here and there large amounts of connective tissue were seen within the areas of both the cartilaginous tissue and the bony tissue. In the bone marrow haematopoiesis was scanty (cf. Figs. 7, 8, 9, 10 and 11). For the sake of obtaining a comprehensive view, the histopathological changes were classified according to degree of severity. In cases where the lesion was clinically and roentgenologically severe, the histological changes were usually marked, and vice versa. Since the lesion as a rule progresses with increasing age, the histological changes were in general more marked in the older children than in the younger ones.

The histopathological findings alone do not afford a satisfactory explanation of the etiology of coxa vara infantum. The changes are largely the same as in tibia vara (osteochondrosis deformans tibiae), and the view that these conditions have a similar etiology is thus corroborated.

The histological findings in the normal material showed that throughout the period of growth the structure of the subcapital epiphyseal plate and the metaphyseal bony tissue as well as the process of ossification taking place at their junction remain quite regular. With increasing age, the epiphyseal plate becomes thinner as a result of the progress of ossification, and finally, at the end of the growing period, it disappears.

Etiology and pathogenesis. — My impression of the etiology of coxa vara infantum is that the cause of the lesion is a disturbance of the process of ossification and growth originating in the medial portion of the subcapital epiphyseal plate. This leads to delayed ossification, the occurrence of cartilage left behind within the area of the bone and weakness of the metaphyseal bone of the neck. When the child begins to walk, static factors increase the strain

to which the neck of the femur is subjected. As the latter is weaker than normal, coxa vara infantum results. The primary cause of the cartilaginous changes and the disturbance of ossification is not yet understood. It is possible that a variety of causes are responsible.

Treatment and the results of treatment. — In regard to children with a slight deformity an expectant attitude is justified, since the lesion may heal without any treatment. Conservative measures are of no avail. Surgery is the only form of treatment yielding successful results.

The evaluation of the present results of treatment was based on follow-up investigations.

Trendelenburg's sign, which before operation was positive in all cases, was found to be negative at follow-up examination in 96 cases out of 114. As a rule, mobility of the hip had improved in the children and the adult patients without pseudarthrosis, whilst it was somewhat impaired in the patients with pseudarthrosis. Gade's mobility index was used as a measure.

The most conspicuous roentgenological change was the correction of the varus angle. In a total of 79 hips, it was found at follow-up investigation that the neck-shaft angle was over 110° in 65 cases, from 90° — 110° in 12 cases and under 90° in only 2 cases. In the patients with pseudarthrosis bony union of the false joint was attained in 26 cases out of 33.

On final evaluation of the results of treatment it was established that a good result had been attained in 42 out of 62 children's hips treated by surgery. In a total of 19 adult hips without pseudarthrosis the result was good in 10, and in the group of adult hips with pseudarthrosis the result was good in 10 out of 33. In all 6 cases of children's hips showing a poor result the cause of the failure was partial necrosis of the head of the femur. In adults the commonest cause was the gradual development of arthrosis deformans of the hip.

The results of treatment were significantly influenced by age and by the operative method employed. The earlier the surgical intervention, the larger was the ratio of good results in each age group. In children the best results were obtained by F. Langenskiöld's intertrochanteric osteotomy (cf. Fig. 14 and 15 a and b). Epiphyseodesis of the greater trochanter, which was done in the case of 3 children's hips with slight changes, yielded a good result in 2 cases (cf. Figs. 20 a, b and c). In adult patients without pseudarthrosis fixation with a McLaughlin nail in connection with intertrochanteric osteotomy proved to be the most satisfactory method (cf. Figs. 18 a and b). In patients with pseudarthrosis the best results were obtained with Brackett's operation (cf. Figs. 19 a, b and c).

The lesion should be corrected as early as possible, since the operative results in children are so greatly superior to the results in adult patients. In children it is sometimes possible to obtain an almost normal hip joint (cf. Figs. 16 a, b and c). After operation children must be followed up for a sufficiently long period, even to the completion of growth, in order that steps may be taken in time to prevent a possible exacerbation due to growth.

In adults the possibilities for radical surgery are restricted by severe deformity of the hip joint and, in patients with pseudarthrosis, by unviability of the head of the femur. The results may be bettered by improvement of the operative technique, as was seen in the cases without pseudarthrosis in which fixation with a McLaughlin nail was used. In advanced cases of long standing, relief can be brought by palliative treatment such as operations relieving the pain (denervation of the hip joint or intertrochanteric osteotomy without correction of the position).

XI REFERENCES

- ALMOND, H. G.: Familial Infantile Coxa Vara. — *J. Bone & Joint Surg.* 1956:38 B:539.
- ARMSTRONG, J. R.: A Case of Infantile Coxa Vara with Notes on the Aetiology. — *Lancet* 1935:1:1498.
- BABB, F. S., GHORMLEY, R. K. and CHATTERTON, C. C.: Congenital Coxa Vara. — *J. Bone & Joint Surg.* 1949:31 A:115.
- BADE, A.: Zur Abgrenzung der verschiedenen Formen von Coxa vara. — *Z. f. orthop. Chir.* 1933:59:53.
- BARR, J. S.: Congenital Coxa Vara. — *Arch. Surg.* 1929:18:1909.
- BARRINGTON-WARD, L. E.: Double Coxa Vara with Other Deformities Occurring in Brother and Sister. — *Lancet* 1912:1:157.
- BERNBECK, R.: *Kinderorthopädie.* — Georg Thieme, Stuttgart, 1954.
- BILLING, L.: Roentgen Examination of the Proximal Femur End in Children and Adolescents. — *Acta Radiol.* 1954: suppl. 110.
- BLOUNT, W. P.: Blade-Plate Internal Fixation for High Femoral Osteotomies. — *J. Bone & Joint Surg.* 1943:25:319.
- BLOUNT, W. P.: *Fractures in Children.* — Williams et Wilkins Company, Baltimore, 1954.
- BRACKETT, E. G., and NEW, M. S.: Treatment of Old Ununited Fracture of the Neck of the Femur by Transplantation of the Head of the Femur to the Trochanter. — *Boston Med. & Surg. J.* 1917:177:351.
- BBALLSFORD, J. F.: *The Radiology of Bones and Joints.* — J. et A. Churchill, London, 1953.
- BRANDES, M.: Zur Behandlung der Coxa vara. — *Z. f. orthop. Chir.* 1924:44:266.
- BRANDES, M.: Behandlung der Coxa vara mit Resektion des Trochanter major. — *Verh. dtsch. orthop. Ges.* 1929:24:80.
- BRANDES, M.: Zur Behandlung der Coxa vara. — *Arch. f. orthop. Chir.* 1930:28:179.
- BURCKHARDT, E.: Zur Klinik und pathologischen Anatomie der Coxa vara infantum. — *Helv. chir. acta* 1946:13:28.
- BURCKHARDT, E.: Zur Histologie der Coxa vara infantum. — *Helv. chir. acta* 1946:13:123.
- BURCKHARDT, E.: Perthes, Osteochondritis dissecans und Coxa vara infantum im Tierexperiment. — *Helv. chir. acta* 1948:15:3.
- BÖHM, M.: Ueber die Ursache und das Wesen der idiopathischen Deformitäten des jugendlichen Alters. — *Z. f. orthop. Chir.* 1908:20:535.
- CAMITZ, H.: Etude comparee sur la coxa vara dite congenitale et l'osteochondrite coxale juvenile (coxa plana). — *Acta chir. Scandinav.* 1934:73:521.

- COMPERE, E. L., GARRISON, M., and FAHEY, J. J.: Deformities of the Femur Resulting from Arrestment of Growth of the Capital and Greater Trochanteric Epiphyses. — *J. Bone & Joint Surg* 1940:22:909.
- DELITALA, F.: Coxa vara congenita. — *Arch. di ortop.* 1913:30:382. Zit. by NILSSON and ZADEK.
- DREHMANN, G.: Zur Frage der angeborenen Coxa vara. — *Berl. klin. Wschr.* 1910:47:1752.
- DREHMANN, G.: Die Coxa vara. — *Erg. Chir. u. Orthop.* 1911:2:452.
- DUNCAN, G. A.: Congenital and Developmental Coxa Vara. — *Surg.* 1938:3:741.
- ELMSLIE, R. C.: Injury and Deformity of the Epiphysis of the Head of the Femur: Coxa Vara. — *Lancet* 1907:1:410.
- ERLACHER, PH.: Die Dysplasie als Krankheitsursache. — *Z. f. Orthop.* 1950:79:269.
- EXNER, G.: Vergleichende Untersuchungen über das Verhalten des proximalen Femurendes bei angeborenem Femurdefekt und Coxa vara congenita. — *Z. f. Orthop.* 1950:79:624.
- FAIRBANK, H. A. T.: An Unusual Case of Congenital Coxa Vara. — *Proc. Roy. Soc. Med.* 1927:20:237.
- FAIRBANK, H. A. T.: Infantile or Cervical Coxa Vara. — *The Robert Jones Birthday Volume. A Collection of Surgical Essays.* Oxford University Press, London, 1928:225.
- FIORANI, G.: Sopra una forma speciale di zoppicamento. — *Gazz. d.osp.* 1881:2:717. *Ref. Zbl. f. Chir.* 1882:9.
- FRANCKE, F.: Zur Kasuistik der angeborenen Coxa vara. — *Z. f. orthop. Chir.* 1906:15:288.
- FROELICH: Beitrag zur Aetiologie der nichtsymptomatischen Coxa vara. — *Z. F. orthop. Chir.* 1904:12:80.
- V. FRISCH, O.: Ein Fall von Coxa vara. — *Wien. klin. Wschr.* 1908:21:1358.
- GADE, H. G.: A Contribution to the Surgical Treatment of Osteoarthritis of the Hip Joint. A Clinical Study. — *Acta chir. Scandinav.* 1947:95: suppl. 120.
- GOFF, C. W.: Orthopaedic Examination of the Growing Child. — *Am. Acad. Orthop. Surgeons Instr. Course Lectures* 1952:9:73.
- GOLDING, F. C.: Congenital Coxa Vara and the Short Femur. — *Proc. Roy. Soc. Med.* 1938:32:641.
- GOLDING, F. C.: Congenital Coxa Vara. — *J. Bone & Joint Surg.* 1948:30 B:161.
- GRASHEY, R., and BIRKNER, R.: Atlas typischer Röntgenbilder vom normalen Menschen. — Urban & Schwarzenberg, München, 1953.
- GUILLEMIN, A.: Quelques observations de la coxa vara essentielle et d'osteochondrite. — *Revue d'Orthop.* 1924:11:51. *Ref. Zent. Org. Ges. Chir.* 1924:26:437.
- GÜTIG, C., and HERZOG, A.: Der Beginn der sogenannten »Coxa vara congenita«. Aseptische Schenkelhalsnekrose. — *Beitr. z. klin. Chir.* 1932:156:551.
- HAM, A. W.: *Histology.* — Pitman Medical, London, 1957.
- HARK, F. W.: Congenital Coxa Vara. — *Am. J. Surg.* 1950:80:305.
- HAYTHORN, S. R.: Pathological Changes Found in Material Removed at Operation in Legg-Calve-Perthes Disease. — *J. Bone & Joint Surg.* 1949:31 A:599.
- HELBING, C.: Die Coxa vara. — *Z.f. orthop. Chir.* 1906:15:502.
- HILGENREINER, H.: Zur Genese der Coxa vara. — *Med. Klin.* 1931:5:159, 6: 200 and 29: 1072.

- HILGENREINER, H.: Weiterer Beitrag zur Lehre und Behandlung der angeborenen Hüftverrenkung. Fort mit dem Gipsverband. — *Z. f. Orthop.* 1940:70:212.
- HOFFA, A.: Die angeborene Coxa vara. — *Deutsch. med. Wschr.* 1905:31:1257.
- HOFMEISTER, F.: Coxa vara. Eine typische Form der Schenkelhalsverbiegung. — *Beitr. z. klin. Chir.* 1894:12:245.
- HOHMANN, G.: Beitrag zur Pathologie und Therapie der Coxa vara. — *Münch. med. Wschr.* 1910:23:1219.
- HORWITZ, T.: The Treatment of Congenital or Developmental Coxa Vara. — *Surg., Gynec. & Obst.* 1948:87:71.
- INMAN, V. T., Functional Aspects of the Abductor Muscles of the Hip. — *J. Bone & Joint Surg.* 1947:29:607.
- JANEK, J.: Operative Behandlung der Coxa vara infantilis. — *Zbl. f. Chir.* 1937:5:277.
- JERRE, T.: Spontaneous Recovery in Coxa Vara Infantum. — *Acta orthop. Scandinav.* 1955:25:149.
- JOACHIMSTHAL, G.: Ein Fall von congenitalem Herzfehler combiniert mit angeborenem Oberschenkeldefect. — *Berl. klin. Wschr.* 1900:37:172.
- JOACHIMSTHAL, G.: Die Aetiologie der Schenkelhalsverbiegungen. — *Z.f. orthop. Chir.* 1904:12:52.
- JOHANNING, K.: Coxa Vara Infantum I. — *Acta orthop. Scandinav.* 1951:21:273.
- JOHANNING, K.: Coxa Vara Infantum II. — *Acta orthop. Scandinav.* 1952:22:100.
- JONSÄTER, S.: Coxa Plana. A Histo-Pathologic and Arthrographic Study. — *Acta orthop. Scandinav.* 1953: suppl. 12.
- KALLIO, E.: Skin Arthroplasty of the Hip Joint and Corresponding Alloplastic Methods in the Light of a Clinical Study. — *Acta orthop. Scandinav.* 1958: suppl. 30.
- KARFIOL, G.: Über den Verlauf der Epiphysenlinie bei der Coxa vara. — *Fortschr. a.d. Geb. d. Röntgenstrahlen* 1929:39:326.
- KEETLEY, C. B.: Coxa Vara. — *Lancet* 1900:1:1115.
- KRASKE, P.: Über die operative Behandlung der statischen Schenkelhalsverbiegung. — *Zbl. f. Chir.* 1896:6:121.
- KREDEL, L.: Coxa vara congenita. — *Zbl. f. Chir.* 1896:42:969.
- KREUZ, L.: Kritische Betrachtungen zur Morphologie der angeborenen Coxa vara. — *Arch. f. orthop. Chir.* 1930:28:106.
- LANGE, M.: Die verschiedenen Formen und die Behandlung der Coxa vara. — *Zbl. f. Chir.* 1937:32:1898.
- LANGE, M.: Orthopädisch-Chirurgische Operationslehre. — J.F. Bergmann, München, 1951.
- LANGENSKIÖLD, A.: Tibia Vara. (Osteochondrosis Deformans Tibiae). — *Acta chir. Scandinav.* 1952:103:1.
- LANGENSKIÖLD, A., and SARPIO, O.: Personal Communication.
- LANGENSKIÖLD, F.: On pseudarthrosis of the Femoral Neck in Congenital Coxa Vara. — *Acta chir. Scandinav.* 1949:98:568.
- LANZ, T. v., and WACHSMUTH, W.: Praktische Anatomie. — J. Springer, Berlin, 1938.
- LAUENSTEIN, C.: Bemerkungen zu dem Neigungswinkel des Schenkelhalses. — *Arch. f. klin. Chir.* 1890:40:244.
- LAURENT, L. E., Congenital Dislocation of the Hip. — *Acta chir. Scandinav.* 1953: suppl. 179.

- LAURENT, L. E.: Growth Disturbances of the Proximal End of the Femur in the Light of Animal Experiments. — *Acta orthop. Scandinav.* 1959:28:255.
- LE DAMANY, P.: Die angeborene Hüftgelenksverrenkung. — *Z. f. orthop. Chir.* 1908:21:129.
- LE MESURIER, A. B.: Developmental Coxa Vara. — *J. Bone & Joint Surg.* 1948:30 B:595.
- LIAN, C.: Congenital Coxa Vara and Perthes' Disease. — *Acta orthop. Scandinav.* 1950:19:527.
- LINDEMANN, K.: Das erbliche Vorkommen der angeborenen Coxa vara. — *Z. f. Orthop.* 1941:72:326.
- LINDEMANN, K.: Zur Morphologie der Coxa vara congenita. — *Z. f. Orthop.* 1949:78:47.
- LUCK, J. V.: Bone and Joint Diseases. — Ch. C. Thomas, Springfield, Ill., 1950.
- MAGNUSSON, R.: Coxa Vara Infantum. — *Acta orthop. Scandinav.* 1954:23:284.
- MARTIN, H.: Coxa vara congenita bei eineiigen Zwillingen. — *Arch. f. orthop. Chir.* 1943:42:230.
- MASSE, P.: Coxa vara rachitiques et coxa vara congenitales. — *Rev. chir. orthop.* 1956:42:362.
- MAU, H.: Wesen und Bedeutung der Enchondralen Dysostosen. — Georg Thieme, Stuttgart, 1958.
- MAU, H.: Die Trochanterresektion als physiologische Behandlung der Coxa vara. — *Z. f. Orthop.* 1955:85:48.
- MAYER, E.: Ein Fall von schwerer doppelseitiger Coxa vara congenita. — *Z. f. orthop. Chir.* 1910:25:323.
- McMURRAY, T. P.: Fracture of the Neck of the Femur Treated by Oblique Osteotomy. — *Brit. M. J.* 1938:1:330.
- MÜLLER, E.: Ueber die Verbiegung des Schenkelhalses im Wachstumsalter. Ein neues Krankheitsbild. — *Beitr. z. klin. Chir.* 1888:4:137.
- MÜLLER, M. E.: Die Hüftnahen Femurosteotomien. — Georg Thieme, Stuttgart, 1957.
- NAGURA, S.: Über die Entstehung und das Wesen der Femurkopfdeformation nach Einrenkung von angeborener Hüftverrenkung. — *Z. f. Orthop.* 1938:68:187.
- NAGURA, S.: Zur Ätiologie der Coxa vara, zugleich Beitrag zur Kenntnis der Transformation der Knochen. — *Arch. f. klin. Chir.* 1940:199:533.
- NAGURA, S.: Perthesche Krankheit und Coxa vara. — *Arch. f. klin. Chir.* 1940:199:613.
- NAGURA, S., and KOSUGE, S.: Die Pathogenese und das Wesen der Perthes'schen Krankheit. — *Arch. f. klin. Chir.* 1938:191:347.
- NILSSONNE, H.: Beitrag zur Kenntnis der kongenitalen Form der Coxa vara. — *Acta Radiol.* 1924:3:383.
- NILSSONNE, H.: On Congenital Coxa Vara. — *Acta chir. Scandinav.* 1929:64:217.
- NOBLE, T. P., and HAUSER, E. D. W.: Coxa Vara. — *Arch. Surg.* 1926:12:501.
- PAUWELS, F.: Zur Therapie der kindlichen Coxa vara. — *Verh. dtsh. orthop. Ges.* 1936:30:372.
- PAUWELS, F.: Des affections de la hanche d'origine mecanique et de leur traitement par l'osteotomie d'adduction. — *Rev. chir. orthop.* 1951:37:22.
- PEABODY, W.: Subtrochanteric Osteotomy in Coxa Vara. — *Arch. Surg.* 1943:46:743.

- PITZEN, P.: Die Behandlung der Coxa vara. — Verh. dtsh. orthop. Ges. 1929:24:39.
- PITZEN, P.: Die operative Umformung des koxalen Femurendes bei der Coxa vara congenita mit einer Pseudarthrose. — Z.f. Orthop. 1950:79:386.
- PLATOU, E.: Subtrochanteric Osteotomy in Relatively Old Congenital Luxation of the Hip, Arthritis Deformans and Coxa Vara. — Acta orthop. Scandinav. 1938:9:132.
- POUZET, F.: Le traitement de la coxa vara congenitale. — Presse Méd. 1938:55:1095.
- REINER, M.: Ueber den congenitalen Femurdefect. — Z. f. orthop. Chir. 1901:9:544.
- REINER, M.: Ueber die Beziehungen von congenitaler Coxa vara und congenitalem Femurdefect. — Berl. klin. Wschr. 1903:27:614.
- RICHTER, W.: Ein Beitrag zur Behandlung der Coxa vara durch Abmeisselung des Trochanter major. — Zbl. f. Chir. 1937:23:1347.
- SCHANZ, A.: Zur Behandlung der Coxa vara. — Münch. med. Wschr. 1923:40:1247.
- SCHANZ, A.: Zur Behandlung der angeborenen Coxa vara. — Z. f. orthop. Chir. 1924:44:261.
- SCHMIDT, A.: Zur Ätiologie der Coxa vara und der Pertheschen Krankheit. Z. f. orthop. Chir. 1927:48:229.
- SCHULTZ, J.: Zur Kasuistik der Verbiegungen des Schenkelhalses. — Z. f. orthop. Chir. 1892:1:55.
- SCHWARZ, E.: Über die Coxa vara congenita. — Beitr. z. klin. Chir. 1913:87:685.
- SCOTT, J. S.: Displacement of the Upper Epiphysis of Femur. In PLATT, H.: Modern Trends in Orthopaedics. — Butterworth, London, 1956.
- SEVERIN, E.: Späteresultate unblutiger Behandlung von Luxatio coxae congenita. — Z. f. Orthop. 1943:74:52.
- SIMONS, B.: Die sogenannte Coxa vara congenita. Beitr. z. klin. Chir. 1935:161:205.
- STAUSS, A.: Die Ätiologie der Hüftgelenkdeformitäten. — Z. f. Orthop. 1938:68:Beilageheft.
- STEINDLER, A.: Kinesiology of the Human Body Under Normal and Pathological Conditions. — Ch. C. Thomas, Springfield, Ill., 1955.
- TRUETA, J.: The Normal Vascular Anatomy of the Human Femoral Head During Growth. — J. Bone & Joint Surg. 1957:39:B:358.
- TRUETA, J., and HARRISON, M. H. M.: The Normal Vascular Anatomy of the Femoral Head in Adult Man. — J. Bone & Joint Surg. 1953:35B:442.
- TUCKER, F. R.: Arterial Supply to the Femoral Head and Its Clinical Importance. — J. Bone & Joint Surg. 1949:31 B:82.
- WALTER, H.: Die Pathologie und Klinik der Coxa vara. — Verh. dtsh. orthop. Ges. 1929:24:8.
- WALTER, H.: Zur Genese der Coxa vara. — Med. Klin. 1931:29:1071.
- WALTER, H.: Sogenannte angeborene Coxa vara durch Umlagerung der Pseudarthrosenzone geheilt. — Zbl. f. Chir. 1933:40:2359.
- WEIL, S.: Die Dysostosis cleido-cranialis. In HOHMANN, G. et al.: Handbuch der Orthopädie, Bd. I. — Georg Thieme, Stuttgart, 1957.
- WEINMANN, J. P., and SICHER, H.: Bone and Bones. Fundamentals of Bone Biology. — H. Kimpton, London, 1955.
- WHITMAN, R.: Further Observations on Coxa Vara with Particular Reference to its Aetiology and Treatment. — New York Med. J. 1899:69:73.

- WIBERG, G.: Studies on Dysplastic Acetabula and Congenital Subluxation of the Hip Joint. — Acta chir. Scandinav. 1939:83:suppl. 58.
- WOLCOTT, W. E.: The Evaluation of the Circulation in the Developing Femoral Head and Neck. — Surg., Gynec. & Obst. 1943:77:61.
- ZADEK, I.: Congenital Coxa vara. — Arch. Surg. 1935:30:62.
- ZAREMBA, J.: Congenital Coxa Vara. Report of a Case. — J. Bone & Joint Surg. 1935:17:450.
- ZIMMERMANN, M.: Untersuchungen über Krankheitsbild und Aetiologie der »sogenannten Coxa vara congenita« oder »Coxa vara infantum«. — Z. f. Orthop. 1938:68:389.