

A TEST FOR RUPTURE OF THE TENDO ACHILLIS

BH

T. CAMPBELL THOMPSON

To have the opportunity to describe this test in a special issue of the *Acta Orthopaedica Scandinavica* is indeed a pleasure as many of the best studies concerning the tendo achillis and its injuries have been done in Sweden (1, 2, 3, 4, 9, 12, 16).

On November 4, 1955, it was first noticed by the author that squeezing the calf of a normal leg produced strong plantar flexion of the foot, while squeezing the calf of a leg with a ruptured heel cord produced no motion in the foot. This observation has now been confirmed in twenty-one such patients. A diligent search of the literature at that time disclosed no references to such a finding. This test has been used in all such patients seen since that time by us and has been demonstrated frequently to visitors at the Hospital for Special Surgery. A number of reports describing it and attesting its value have appeared in the literature since then (10, 11, 15, 16, 18, 19).

It was found by anatomical dissections that the plantar flexion of the foot depends upon an intact soleus muscle attached to an intact tendon of achilles. It is not a reflex and the plantar flexion of the foot results from simple shortening of the muscle as it is compressed. This test is very useful in convincing the patient, his family, the family doctor and sometimes even the surgeon that the rupture is complete and should be repaired. The squeeze test can be done with the patient prone with his feet hanging over the end of a table or kneeling upon a stool or chair.

This method of squeezing a muscle to produce motion in a more distal structure can be used in other parts of the body to demonstrate an intact tendon. Squeezing the forearm muscles with arm dependent and the hand relaxed will produce motion in the thumb and fingers.

Dr. John H. Doherty of our Staff, kindly reviewed fortyseven cases of

FIG. 1A

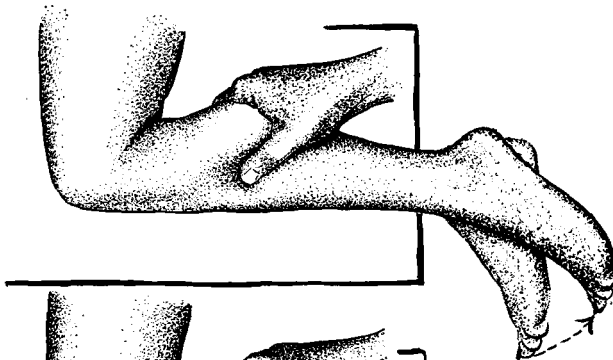


Fig. 1 a.
Squeezing calf produces plantar flexion of foot when heel cord is intact.

FIG. 1B

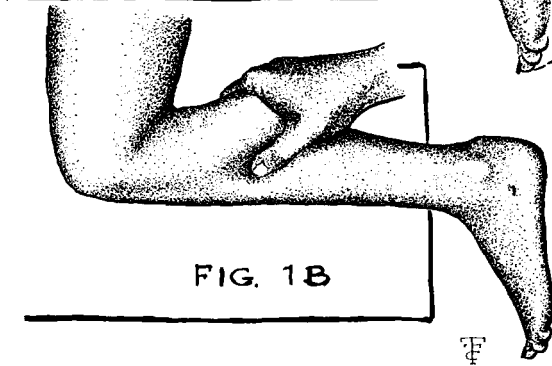


Fig. 1 b.
Squeezing calf produces no motion of foot in injured leg.

rupture of the tendon of achilles seen at three New York Hospitals and in twenty-two the diagnosis was not made by the first examining doctor. Other authors have reported that the diagnosis of rupture of the tendo achillis is frequently missed because the patient can actively dorsiflex and plantar flex the foot.

There are many interesting facts about these forty-seven patients with ruptured heel cords which could be reported.

Numerous methods of repair recommended by various authors have been reviewed (5, 6, 7, 8, 12, 14, 20, 21).

The Bunnell pullout wire that is tied outside of a cast which holds the foot in equinus until healing is complete is in our opinion the best method of holding the tendon ends together while healing takes place.

Because early repair is fairly simple and late repair very difficult it is hoped that the use of this simple test will be helpful in making a prompt diagnosis and instituting early surgical treatment.

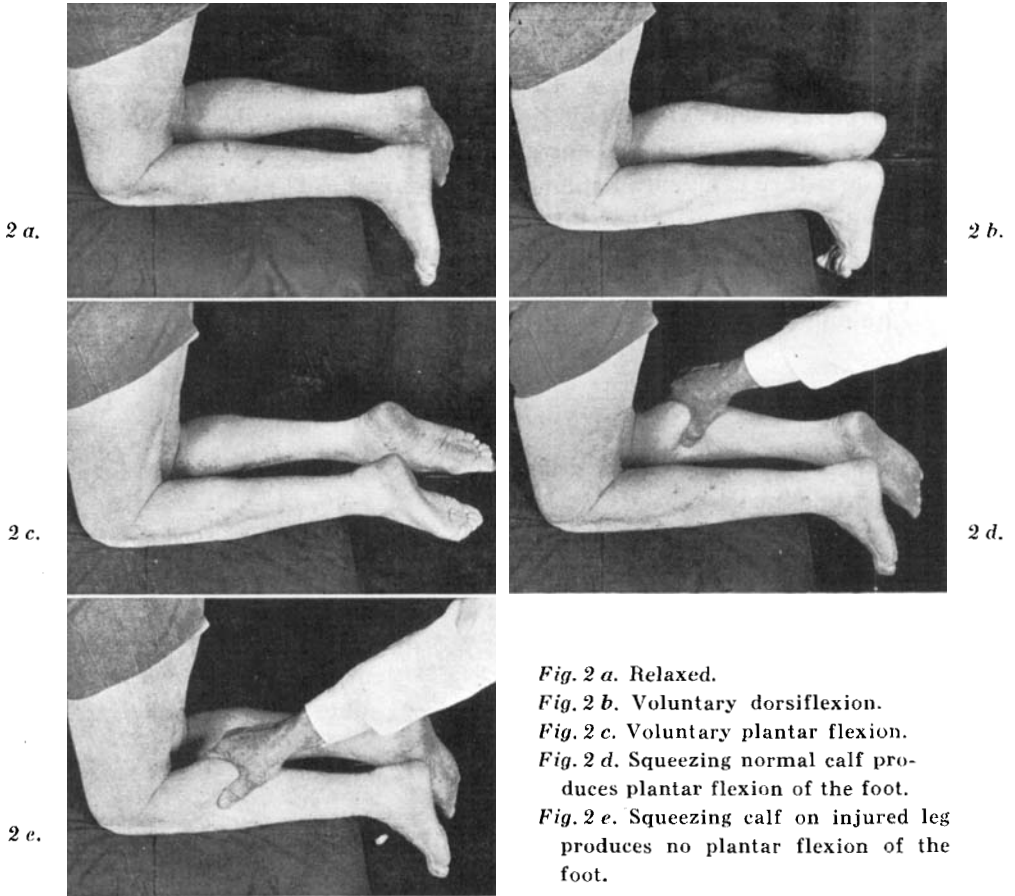


Fig. 2 a. Relaxed.

Fig. 2 b. Voluntary dorsiflexion.

Fig. 2 c. Voluntary plantar flexion.

Fig. 2 d. Squeezing normal calf produces plantar flexion of the foot.

Fig. 2 e. Squeezing calf on injured leg produces no plantar flexion of the foot.

Fig. 2.

Photos of a typical case of ruptured tendo achillis.

SUMMARY

1. A test for rupture of the tendo achillis is described.
2. The diagnosis of this injury is frequently missed or delayed.
3. Early repair of such a rupture is much more satisfactory than late repair.
4. For these reasons this test should be employed not only to confirm the diagnosis but also to convince the patient that surgical repair is indicated.

RESUME

1. Description d'un procédé permettant de déceler une rupture du tendon d'Achille.
2. Il s'avère souvent difficile de poser le diagnostic de cette lésion. Dans tous les cas il est souvent posé avec retard.
3. Une suture rapide du tendon donne des résultats plus satisfaisants qu'une suture effectuée tardivement.
4. Il convient pour ces raisons d'appliquer ce procédé, non seulement pour confirmer le diagnostic, mais aussi pour convaincre le malade qu'une intervention chirurgicale est indiquée.

ZUSAMMENFASSUNG

1. Eine Probe zur Sicherung der Diagnose der Achillessehnenruptur wird beschrieben.
2. Diese Verletzung wird häufig übersehen oder verspätet erkannt.
3. Frühzeitige Wiederherstellung einer solchen Zerreiung ist viel zufriedenstellender als späte Reparatur.
4. Aus diesen Grnden sollte die Probe nicht nur um die Diagnose zu besttigen, sondern auch um den Patienten von der Notwendigkeit eines chirurgischen Eingriffes zu berzeugen, ausgefhrt werden.

REFERENCES

1. Arner, O., Lindholm, A. & Orell, S. A.: Histologic changes in subcutaneous rupture of the achilles tendon; a study of 74 cases. *Acta chir. scand.*, 116: 484-490, 1959.
2. Arner, O., Lindholm, A. & Lindvall, N.: Roentgen changes in subcutaneous rupture of achilles tendon. *Acta chir. scand.*, 116: 496-500, 1959.
3. Arner, O.: Subcutaneous rupture of the achilles tendon; a study of 92 cases. *Acta chir. scand. Suppl.* 239: 1-51, 1959.
4. Arner, O.: Subcutaneous rupture of the achilles tendon. A new roentgen diagnostic method. *Acta chir. scand.*, 199: 523-525, 1960.
5. Bancroft, F. W. & Marble, H. C.: *Treatment of the Musculo-Skeletal System*, 2nd ed., vol. 11. Phila., J. B. Lippincott, 1951.
6. Bate, T. H.: Subcutaneous rupture of the achilles tendon. *Arch. Surg.*, 62: 14-22, 1951.
7. Bosworth, D.: Repair of rupture and defects of the tendo achilles. *J. Bone & Joint Surg.*, 38 A: 111-114, 1956.
8. Bunnell, S.: Discussion of paper by H. L. McLaughlin.
9. Christensen, I.: Rupture of the tendo achilles; analysis of 54 cases. *Acta chir. scand.*, 106: 50-60, 1953.

10. *Hiertonn, T.*: A simple method of diagnosing rupture of the achilles tendon. Svensk Kirurgisk Förenings förhandl., 17: 50-51, 1959.
11. *Hiertonn, T.*: A simple method of diagnosing rupture of the achilles tendon. Nordisk Medicin, 63: 671-672, 1960.
12. *Lawrence, G. H., Cave, E. F. & O'Conner, H.*: Injury of the achilles tendon; experience at Massachusetts General Hospital. Am. J. Surg., 89: 795-800, 1955.
13. *Lindholm, A.*: A new method of operation in subcutaneous rupture of the achilles tendon. Acta chir. scand., 117: 261-270, 1959.
14. *McLaughlin, H. L.*: Repair of major tendon ruptures by buried removable sutures. Am. J. Surg., 74: 758, 1947.
15. *Quigley, T. B. & Banks, H.*: Progress in the treatment of fractures and dislocations. W. B. Saunders, Phila., p. 66, 1960.
16. *Scott, J. H. S.*: Pitfalls in the management of sport injuries. Practitioner (London), 185: 770-779, 1960.
17. *Silfvorskiöld, N.*: Über die subcutane totale Achillessehnenruptur und deren Behandlung. Acta chir. scand., 84: 393, 1941.
18. *Simmonds, F. A.*: The diagnosis of the ruptured achilles tendon. Practitioner (London), 179: 56-58, 1957.
19. *Thompson, T. C. & Doherty, J. H.*: Spontaneous rupture of tendon of achilles: a new diagnostic test. J. Trauma, 2: 126-129, 1962.
20. *Tobin, W. J.*: Repair of neglected ruptured and severed achilles tendon. American Surgeon, 19: 514-522, 1953.
21. *Zadek, I.*: Repair of old ruptured tendo achilles by means of fascia lata. J. Bone & Joint Surg., 22: 1070, 1940.