

From Institute of Experimental Research in Surgery, University of Copenhagen,
(Head: H. H. Wandall) and
The Orthopedic Hospital, Department I., Copenhagen, (Head: A. Bertelsen)
with support from Fondet til Videnskabens Fremme.

THE VASCULAR SUPPLY TO
THE FEMORAL HEAD FOLLOWING DISLOCATION
OF THE HIP JOINT

An Experimental Study in New-Born Rabbits

By

H. BOHR, K. BAADSGAARD and PH. SAGER

In congenital dislocation of the hip joint, disturbances in the development of the femoral head can be observed. Retarded appearance of the ossification centre or condensation and fragmentation is seen with varying frequency according to the age and the method of treatment (*Esteve 1960* and *Wilkinson & Carter 1960*). Little is known about the origin of these changes, but the resemblance with the disturbances in Legg-Calvé-Perthes' disease has been pointed out (*Massie 1951* and *Meyer 1963*). It is generally agreed, that the changes in Legg-Calvé-Perthes' disease are due to disturbances in the vascular supply to the femoral head producing ischemic necrosis (*Jonsäter 1953*). Changes in the femoral head of dogs similar to those of Legg-Calvé-Perthes' disease have been described by *Moltzen-Nielsen (1938)*. Angiographic investigation of such cases has shown that devascularization is present corresponding to the lesion and that hyperemia has developed in the surrounding tissue (*Hulth 1962*).

The present investigation has been carried out to study the effects of a disturbance of the vascular supply to the femoral head produced by traumatic dislocation of the hip joint in new born rabbits.

METHODS

In two days old rabbits a dislocation of the right hip joint was produced by a constant pressure in an upward direction on the adducted femur. A small click was

heard as the femoral head slipped over the rim of the acetabulum, and the greater trochanter could be felt projecting outwards. The animals showed only little reaction to this manipulation, and seemed to be able to move about without pain. No deaths occurred. In each animal the left hip served as control.

X-ray examinations were performed with regular intervals to observe the changes which developed.

20 animals were included in the experiment, and as seen in the table, 19 were sacrificed from 2 days to 7 weeks and one animal 17 weeks after the dislocation was performed. In intraperitoneal Nembutal anaesthesia the heparinized animals were bled from the inferior vena cava. A cannula was placed in the aorta and the vascular system perfused with saline of body temperature to wash out the blood. Perfusion was continued with a 2 per cent solution of Berline Blue in saline, in an amount of 100-300 ml according to the size of the animal. This was followed by perfusion of a 25 per cent mixture of Micropaque in saline with 2 per cent Berline Blue. The colouring of the skin and the membranes was noted and venous return of the perfused solution was observed during the perfusion, which was continued for an hour at a pressure of 100 mm Hg.

After fixation in 4 per cent formaline the animals were dissected and the pelvis with attached femora removed for X-ray examination and decalcification in formic acid.

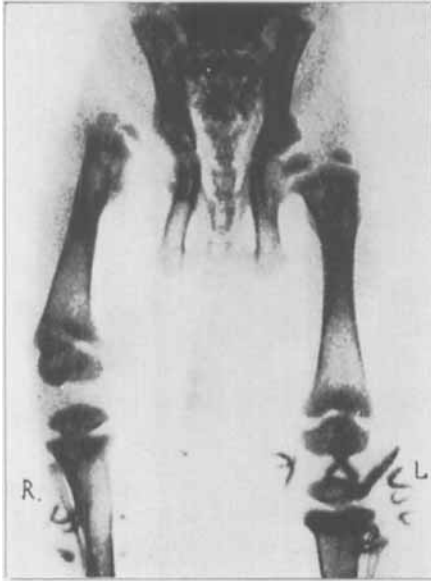Angiographic examination of the femur and acetabulum was performed with soft X-rays from a Machlett A.E.G. X-ray tube, regenerated at 25 kV max. and 20 mA. Exposures were made on Kodaline film at a distance of 50 cm from the focus.

The specimens were then embedded in paraffin and cut on a microtome into sections alternating 200 μ and 7 μ in thickness. The thin sections were prepared for ordinary histological investigation after staining with Haematoxylin-Eosin, while the thick sections were treated according to the method of Spalteholz to observe the course of the vessels.

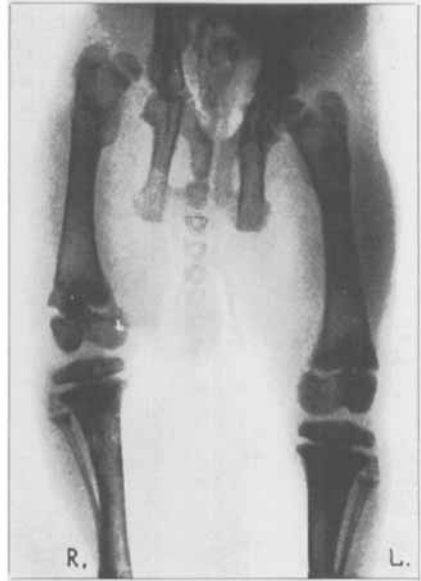RESULTS

Repeated X-ray examinations of the living animals showed dislocation of the hip joint with lateral and posterior displacement of the femoral head persisting throughout the time of observation (Figs. 1 and 2). In 3 of the animals epiphysiolysis of the femoral head and in 2 animals a fracture of the femoral shaft resulted from the manipulation. These animals are included in the total material, and the sequels of epiphysiolysis will be described separately.

The dissection disclosed that disruption of the ligamentum teres occurred in every case of dislocation in the hip joint. In those animals which were sacrificed during the first two weeks it could be seen that the femoral head was displaced through the capsule. 2 to 3 weeks after the dislocation the original capsule could no longer be identified and a regular false joint with cartilage and fibrous capsule had developed above and behind the acetabulum (Fig. 3). Dysplastic changes of the

*Fig. 1.*

Radiograph 11th day. Animal 11.
Right hip dislocated. Dysplastic changes
of the acetabulum and the femoral head.

*Fig. 2.*

Radiograph 29th day. Animal 18.
Persistent dislocation. A new acetabu-
lum has been formed.
Varus position of the femoral head.

acetabulum were present from the 3rd day and gradually increased. The head of the femur showed anteversion and varus position from the 7th day of dislocation and throughout the following period. In the youngest animals the epiphysis was reduced in size compared with the normal side, but this difference later decreased. A slight shortening of the femoral shaft could be measured in most cases, but not exceeding a few per cent. The neck of the femur seemed shorter and somewhat broader than the normal.

X-ray examination of the removed specimens shows, that the ossification centre of the femoral head normally appears during the first few days of life. Compared to this the side of the lesion will show delayed appearance and during the first 3 weeks retarded growth of the centre, which often displays irregular outline and condensation (Fig. 4). Although these changes later disappear, the femoral head often remains somewhat flattened and broad.

Angiographic studies and Spalteholz preparations of the decalcified specimens show that the normal blood supply to the femoral head

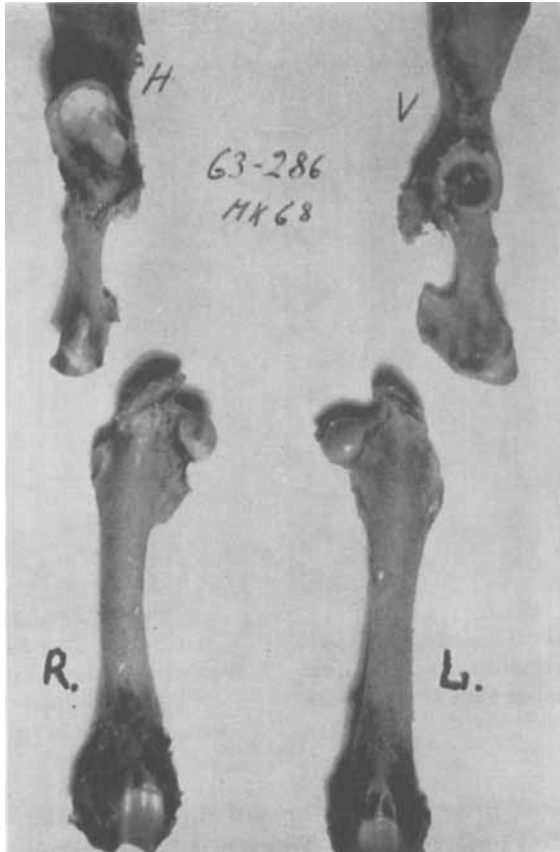


Fig. 3.

Dissection specimens 7th week. Animal 19.

Varus position, anteversion and some malformation on the right femoral head.
New acetabulum formed.

comes from vessels in the ligamentum teres and on the postero-medial side of the femoral neck.

As a result of dislocation the femoral head is almost completely avascular during the first week (Fig. 5). From the second week revascularization takes place through vessels from the trochanteric region and by vessels perforating the epiphysial plate from the metaphysial side (Figs. 6 and 7). Such perforating vessels were never seen in the normal hip; detailed description appears below under the histological examination. During the following 2–3 weeks hypervascularization is observed in the femoral head. This hyperemia gradually

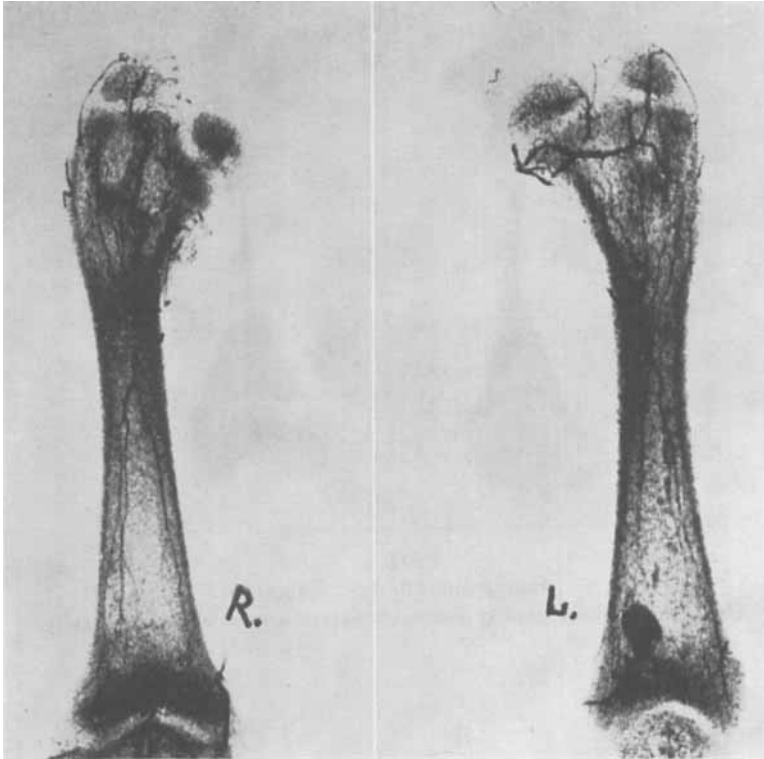

Fig. 4.

Radiograph 14th day. Animal 11.

Varus position of the right femoral head.

Smaller, irregular and condensed centre of ossification.

diminishes and the perforations of the epiphysial plate cannot be demonstrated from the 4th week following the dislocation, although the vessels still show a somewhat abnormal and irregular distribution.

The examination of the histological slides shows but few functioning vessels in the head of the femur during the first week after dislocation of the hip. The joint cartilage appears normal, while the central part of the epiphysis shows undefined structure with pycnotic remains of cell nuclears from necrotic marrow and thrombosed vessels. Around this centre, especially along a line from the previous attachment of the ligamentum teres towards the epiphysial plate, the cartilage appears partly necrotic with pycnotic cell nuclears and less stained intercellular substance. This is true also of that part of the epiphysial plate, which is in contact with the degenerated cartilage. From the corre-

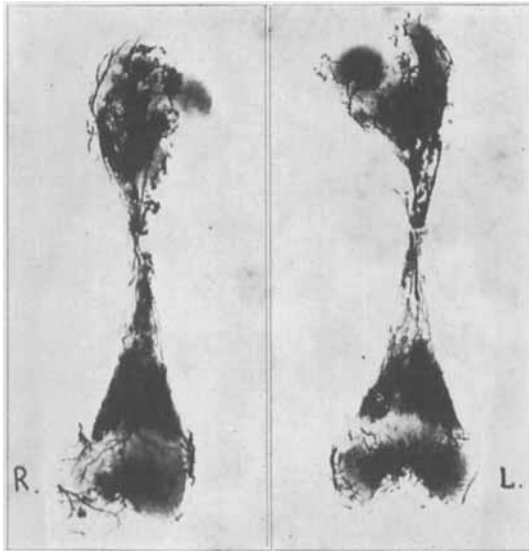


Fig. 5.

Angiograph 7th day. Animal 6.

The right femoral head is avascular except a smaller part laterally.

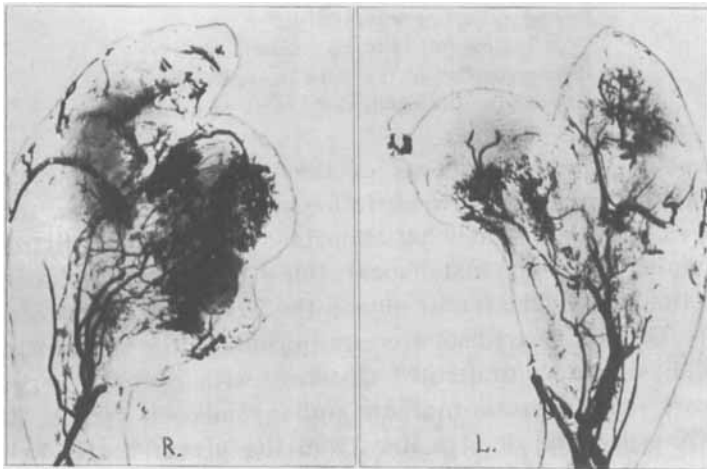

Fig. 6.

Angiograph 3rd week. Animal 15.

Hypervascularization of the right femoral head.

Abnormal vascular pattern.

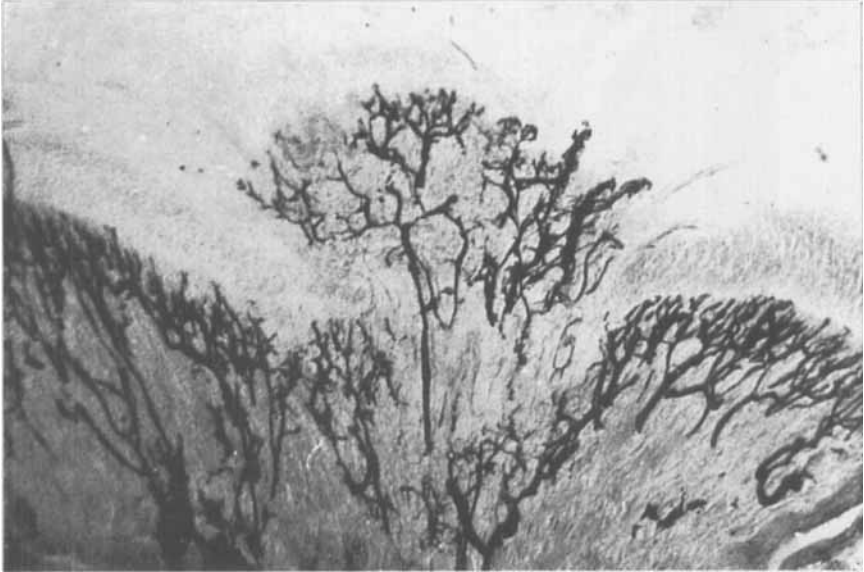


Fig. 7.

Spalteholz preparation 16th day. Animal 12. Right femoral head.
Vessels perforating central part of the epiphysial plate.

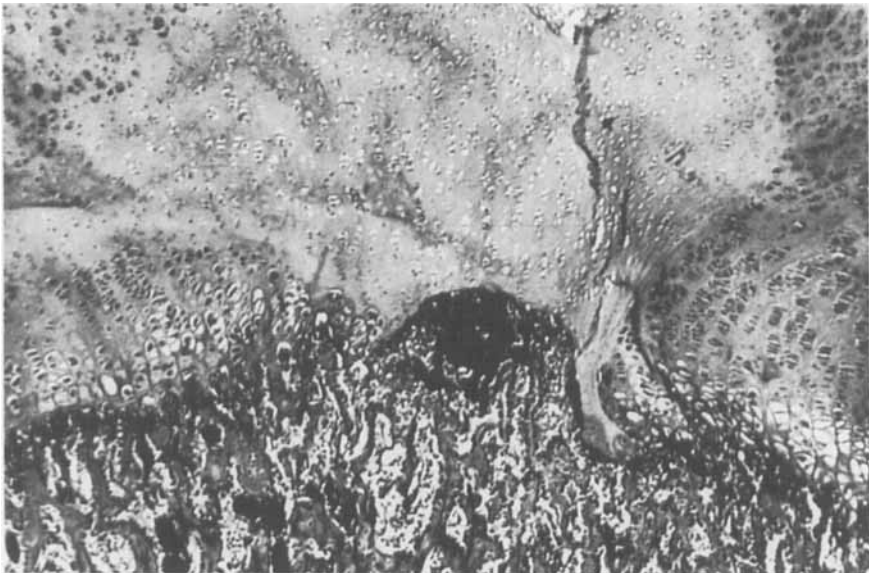

Fig. 8.

Histological section 7th day. Animal 6. Right femoral head.
Necrotic changes in the central part of the femoral head and epiphysial plate.
Vessels penetrating from the metaphysis.

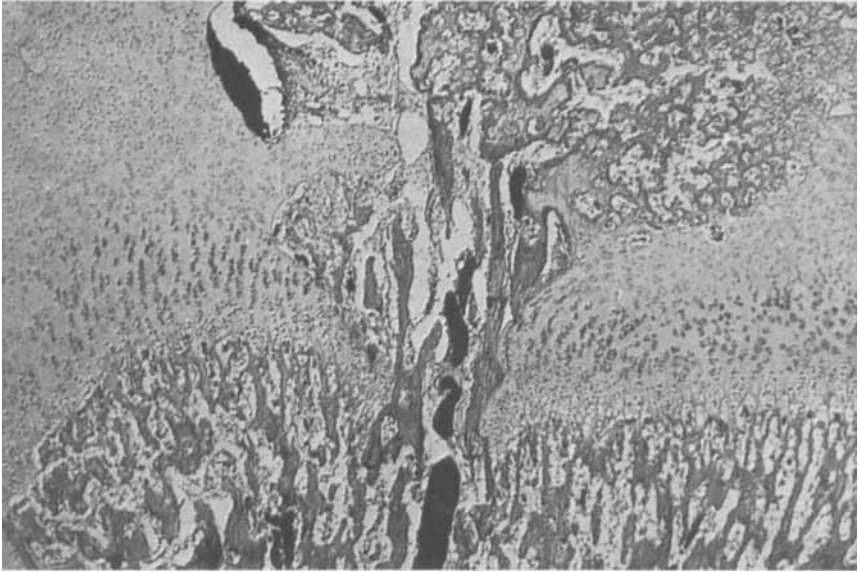

Fig. 9.

Histological section 14th day. Animal 10. Right femoral head.
Central perforation of the epiphysial plate by vessels and formation of bone bridge.

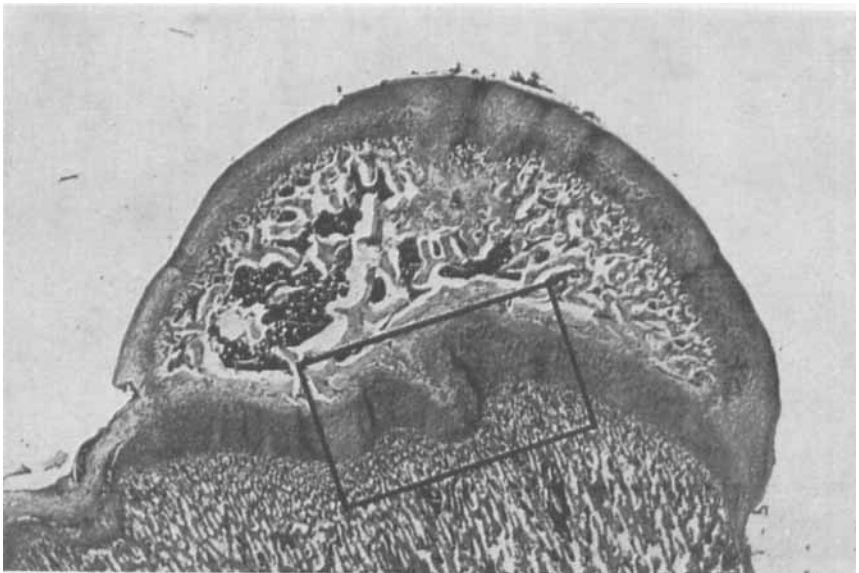


Fig. 10.

Histological section 4th week. Animal 16. Right femoral head.

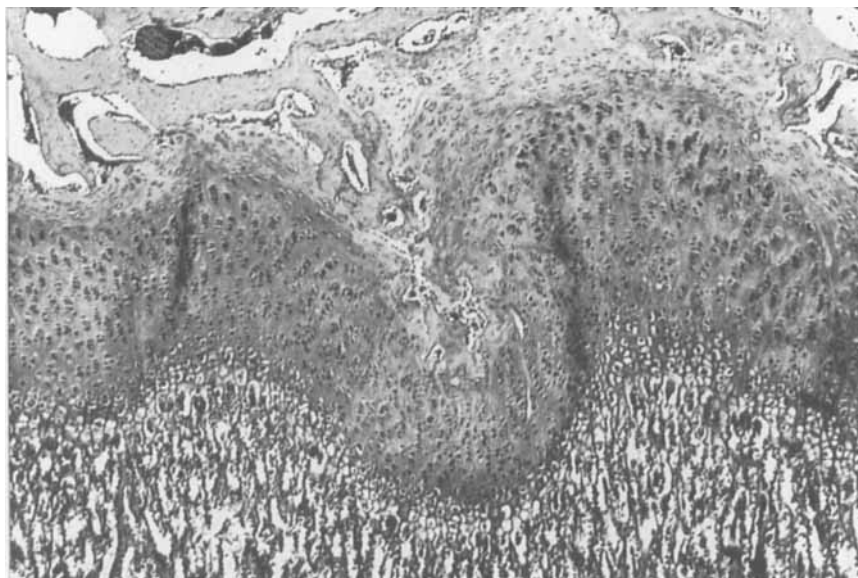


Fig. 11.

Detail from Fig. 10.

Continuity of the epiphysial plate has been re-established.
Large bony projection from the epiphysis.

sponding metaphysial part dilated vessels are seen penetrating towards the epiphysis (Fig. 8).

During the following weeks these vessels perforate the epiphysial plate and along with vessels and invading connective tissue ossification takes place, establishing a bone bridge between the metaphysis and the ossification centre of the epiphysis (Fig. 9). Regeneration of the cartilage cells in the epiphysis and the epiphysial plate takes place with the appearance of normal cell proliferation. During the following weeks the bone bridges between the metaphysis and epiphysis are gradually disconnected at the metaphysial end, and about the 4th week after dislocation of the hip the continuity of the epiphysial plate is reestablished, leaving irregularities corresponding to the remaining bone projections from the epiphysis (Figs. 10 and 11).

As previously mentioned epiphysiolysis occurred instead of dislocation in 3 animals. In these cases the vascular supply to the femoral head seems undisturbed and the histological sections show that disruption has occurred through the metaphysial side of the epiphysial plate. During the observation time the epiphysial plate increases in

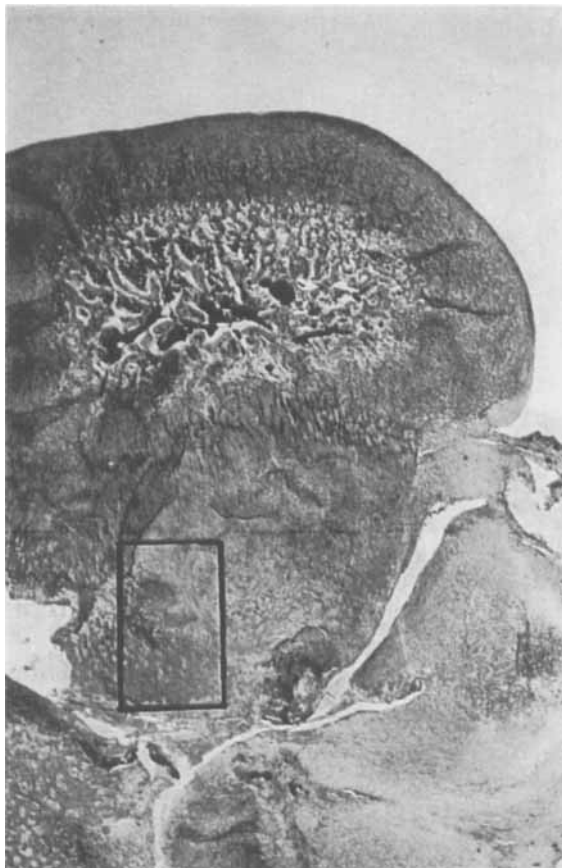


Fig. 12.

Histological section 11th day. Animal 7. Right femoral head.
Epiphysiolysis. Normal centre of ossification.

thickness with elongation of the columns of cartilage cells and no ossification develops here (Figs. 12 and 13).

DISCUSSION

It was shown by *Langenskjöld, Sarpio & Michelsson* (1962) that the characteristic deformities in the acetabulum and the femoral head following congenital dislocation in man can be produced by traumatic dislocations of the hip joint in new born rabbits. In the present investigation similar dysplastic changes have been demonstrated. Our examinations have furthermore shown development of ischemic ne-

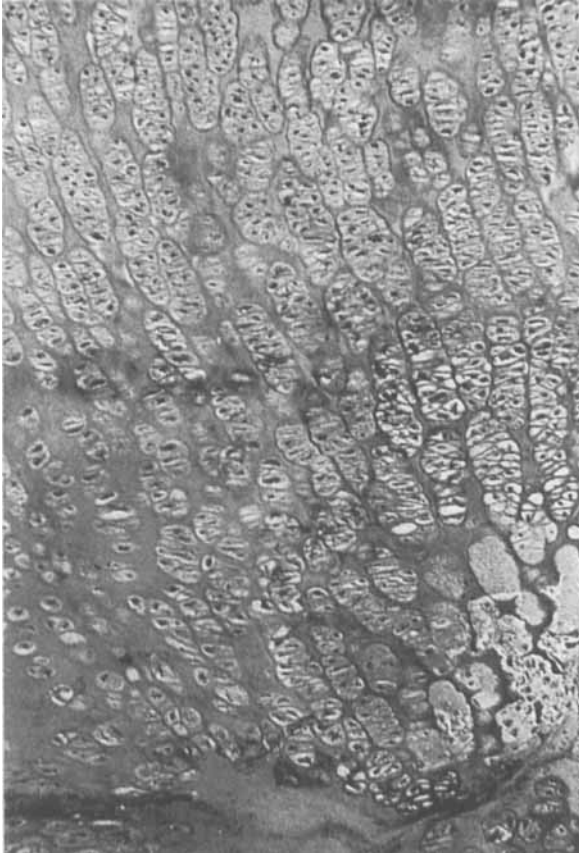


Fig. 13.

Detail from Fig. 12.

Greatly broadened epiphyseal plate without endochondral ossification.

crisis in the ossification centre and degeneration of cartilage cells in the epiphysis with perforation of the epiphyseal plate by vessels from the metaphysis. Such perforations have previously been described, among others by *Trueta & Amato* (1960), who through surgical interventions on 6 weeks old rabbits produced devascularization of the proximal tibia epiphysis. While these authors observed the development of permanent epiphysiodesis in the area of intervention, the bone bridges in our cases were only transitory, with later reestablishment of the continuity of the epiphyseal plate. Although this discrepancy may be due to the difference in degree of the intervention, it is in our opinion more likely due to a different reaction in the younger animals.

Our cases of epiphysiolysis showed no interference with the vascular supply to the epiphysis and resulted in a broadening of the epiphysial plate. This can be compared with the similar disturbances described by *Trueta & Amato* (1960) following interference with the vascular supply on the metaphysial side of the epiphysial plate.

Results of surgical interventions in the vascular supply to the femoral head of rabbits have been described by different authors. Thus *Lemoine* (1957) in examinations of 2-7 weeks old animals observed fragmentation and flattening of the femoral head after ligation of the ligamentum teres or disruption of the posterior-inferior vessel to the epiphysis. *Rokkanen* (1962) has shown that similar disturbances of the vascular supply to the femoral head of adult rabbits interfere but little with the development of bone and cartilage. In cases of permanent dislocations, however, necrosis of the bone was often observed.

The results of the quoted works and those of our observations may contribute to the understanding of the dysplastic changes of the femoral head in various age groups, including Legg-Calvé-Perthes' disease. Further investigations along these lines are needed and have been planned.

SUMMARY

Following traumatic dislocation of the hip joint in 20 new-born rabbits, characteristic changes could be seen with anteversion and varus position of the femoral head as well as dysplastic deformations of the acetabulum. The animals were sacrificed 2 days to 7 weeks after the dislocation. Injection studies revealed an almost complete devascularization of the displaced femoral head within the first week. This was followed by revascularization with an intermediate phase of hyperemia of the femoral head. On sections through the femoral head histological examination as well as preparations with Spalteholz technic showed ischemic necrosis of the ossification centre and degenerative changes in the cartilage of the epiphysis and the epiphysial plate. From the first week after dislocation vessels were observed perforating the epiphysial plate from the metaphysis, resulting in the formation of bone bridges between the metaphysis and the epiphysis. These perforations were transitory and from the 4th week they could only be traced as irregularities in the epiphysial plate.

The significance of these findings is discussed in relation to the changes observed in congenital dislocation of the hip as well as in Legg-Calvé-Perthes' disease.

RESUME

A la suite d'une dislocation traumatique de la hanche chez 20 lapins nouveau-nés, des changements caractéristiques ont été constatés: antéversion et position varus de la tête fémorale, aussi bien que déformation dysplastique de la cavité cotyloïde.

Les animaux ont été sacrifiés entre 2 jours et 7 semaines après la dislocation.

Une étude au moyen d'injections a révélé une dévascularisation presque complète de la tête fémorale déplacée, dans le courant de la première semaine. Il s'est produit ensuite une revascularisation avec une phase intermédiaire d'hyperhémie de la tête fémorale. En sectionnant la tête fémorale, l'examen histologique comme les préparations selon la technique de Spalteholz ont montré une nécrose ischémique du centre d'ossification et des modifications dégénératives du cartilage de l'épiphyse et de la plaque épiphysaire. Déjà la première semaine après la dislocation, on a observé des vaisseaux perforant la plaque épiphysaire en partant de la métaphyse, résultant dans la formation d'un osseux entre la métaphyse et l'épiphyse. Ces perforations étaient transitoires et à partir de la 4ème semaine, elles ne pouvaient être discernées que comme des irrégularités de la plaque épiphysaire.

La signification de ces trouvailles est discuté en relation avec les modifications observées dans la dislocation congénitale de la hanche, aussi bien que dans la maladie de Legg-Calvé-Perthe.

ZUSAMMENFASSUNG

Nach traumatischer Luxation des Hüftgelenkes bei 20 neugeborenen Kaninchen konnten charakteristische Veränderungen wie Anterverion und Varusposition des Femurkopfes als auch dysplastische Verbildungen des Acetabulum beobachtet werden.

Die Tiere wurden 2 Tage bis 7 Wochen nach der Luxation getötet.

Untersuchungen mittels Injektion zeigten einen beinahe vollständigen Gefäßverlust des luxierten Femurkopfes innerhalb der ersten Woche. Dies war von einer Revaskularisierung mit einer dazwischenliegenden Phase von Hyperämie des Femurkopfes gefolgt. Die histologische Untersuchung von Scheibenschnitten des Femurkopfes, sowie auch Präparate mit der Spalteholz-Technik, zeigte ischämische Nekrose des Ossifikationszentrums und degenerative Veränderungen des Epiphysenknorpels und der Epiphysenplatte. Von der ersten Woche nach der Luxation wurden Gefäße beobachtet, die die Epiphysenplatte

von der Metaphyse her durchbrachen und die Bildung von Knochenbrücken zwischen der Metaphyse und der Epiphyse zum Ergebnis hatten. Diese Durchbrüche waren vorübergehend und von der vierten Woche an konnten sie nur als Unregelmässigkeiten in der Epiphysenplatte nachgewiesen werden.

Die Bedeutung dieser Befunde wird unter Bezugnahme auf die Veränderungen, die bei angeborener Hüftverrenkung und bei der Legg-Calvé-Perthes Erkrankung beobachtet werden, besprochen.

REFERENCES

1. *Estebe, R.*: Congenital Dislocation of the Hip. *J. Bone Jt Surg.* 42-B: 253-263, 1960.
2. *Hulth, A., Norberg, I. & Olsson, S. E.*: Coxa Plana in the Dog. *J. Bone Jt Surg.* 44-A: 918-930, 1962.
3. *Jonsäter, S.*: Coxa Plana. *Acta orthop. Scandinav. Suppl.* 12, 1953.
4. *Langenskjöld, A., Sarpio, O. & Michelsson, J. E.*: Experimental Dislocation of the Hip in the Rabbit. *J. Bone Jt Surg.* 44-B: 209-215, 1962.
5. *Lemoine, A.*: Vascular Changes after Interference with Blood Flow of Femoral Head of Rabbit. *J. Bone Jt Surg.* 39-B: 763-777, 1957.
6. *Massie, W. K.*: Vascular Epiphysial Changes in Congenital Dislocation of the Hip. *J. Bone Jt Surg.* 33-A: 284-306, 1951.
7. *Meyer, J.*: Mb. Calvé-Perthes' and Dysplasia Epiphysialis Capitis Femoris. Address to the Danish Orthop. Assn. *J. Bone Jt Surg.* 45-B: 433, 1963.
8. *Moltzen-Nielsen, H.*: Calvé-Perthes'-Krankheit, Malum deformans juvenilis coxae bei Hunden. *Arch. wiss. prakt. Tierheilk.* 72: 91-108, 1938.
9. *Rokkanen, P.*: Aseptic Necrosis of the Femoral Head. *Acta orthop. Scandinav. Suppl.* 58, 1962.
10. *Trueta, J. & Amato, V. P.*: The Vascular Contribution to Osteogenesis. 3. *J. Bone Jt Surg.* 42-B: 571-587, 1960.
11. *Wilkinson, J. & Carter, C.*: Congenital Dislocation of the Hip. *J. Bone Jt Surg.* 42-B: 669-688, 1960.