

From the Department of Orthopaedic Surgery, University of Basel  
(Director: Professor G. Chapchal, M.D., F.I.C.S.),  
Basel - Homburg/Saar - Basel - Trier

## DISCOPATHIA LUMBALIS

### *Degeneration of Lumbar Discs and their Operative Treatment*

*By*

G. CHAPCHAL, G. FRIES, J. U. BAUMANN & E. MÜLLER

Received 17.iii.66

Low back pain, lumbago and ischias are common diagnoses in daily practice. These conceptions do not differentiate between single aetiological groups and their pathological changes. An adequate therapy, however, is only possible if based on an exact diagnosis. Apart from neurogenic and myogenic low back pain, its spinal origin can only be recognised on an x-ray picture. Thus changes and lesions of the vertebral bodies, vertebral arches, facet—joints as well as of the intervertebral discs must be considered. A table of the diagnoses of 278 patients from the Orthopaedic Department at Utrecht, of which one of us was chief at that time (statistics from 1.1.1959) gives information concerning the frequency of the different aetiologies.

*Table 1*

Diagnosis	Cases	%
Discopathia lumbalis	108	39.0
Spondylolysis	77	27.7
Spondylolisthesis	58	20.8
Lumbosacral anomalies	19	6.8
Osteoarthritis of intervertebral joints	16	5.7

### M A T E R I A L

The material evaluated here, consists of 147 operatively treated cases of discopathy. The revision of the cases involves pronounced late control, up to 12 years after the operation, 125 cases from the years 1950-1958 and 22 cases from 1959-1962.

## PATHOLOGY

As a mechanically functioning unit, the spine can work perfectly only as long as its anatomy is normal and the static-dynamic equilibrium is maintained. The same is also true for the single *segments of movement*, which are made up of the unit of vertebral bodies, intervertebral discs and intervertebral joints. Only the full elasticity of the intervertebral discs, *i.e.* the integrity of their structure and their biological condition guarantees normal function within the segment of movement.

The hydrolic pressure of the nucleus which is due to its high water content guarantees its extraordinary elasticity in childhood and youth. Depending on the progressive degeneration, the elasticity of the intervertebral disc decreases more and more, beginning at the end of the second decade of life.

It becomes compressed between the vertebrae which in turn come closer together. The articular surfaces of the intervertebral joints shift and under these patho—mechanical conditions are prematurely worn out, what limits their function. The oedematous swollen ligaments of the arthrotic intervertebral joints cause irritation of the nerve roots with local and irradiating pain.

The tissue mass of the intervertebral disc protrudes peripherally under the pressure and pulls on the Sharpey—fibers stimulating the formation of spondylotic spikes on the vertebrae. If the main pressure of the swollen disc is directed dorsally, protrusion of its dorsal wall as a whole or a locally circumscribed prolapse into the vertebral canal ensues, causing compression symptoms.

The result is reflectory muscular immobilisation of the diseased segments with myalgia due to functional overloading and poor circulation of the respective muscle parts. When judging back pain, the periosteum must be taken into account as its origin and as the medium of transmittance.

## CLINICAL PICTURE

Low back pain stands in the foreground of the *clinical picture*. In more than half the cases it is combined with irradiating pain in one leg. Only a small percentage complained about pain in both legs. It is true that there are also cases which feel irradiating pain in the lower extremities exclusively and have no backache. This concerned only about 5 per cent of the cases.

*Table 2. Localisation of complaints in 147 discopathies.*

Low back pain	Pain in one leg	Pain in both legs
140 times 95 %	86 times 58.5 %	26 times 17.7 %

Corresponding to the cramping of the musculature and fixation of a certain section of the vertebral column, there is a limitation of function of the whole spine. At the level of the degenerated intervertebral disc, pain can be elicited by pressure and axial compression, the paraspinal musculature is usually sensitive to pressure. The patients are markedly hindered.

*Table 3. Working capacity of 147 patients before the operation.*

Working capacity	Full	partial	Incapacitate	Information missing
Number of patients	49	43	50	5
%	33.3	29.3	34.0	3.4

64 per cent of discopathy sufferers are partially or totally unable to work. Their symptoms lasted from onset to the time of operation an average of 4 years and 10 months. Most patients had repeated conservative treatment and were often forced to interrupt their work for a longer or shorter period of time. So the situation becomes also a social problem.

*Table 4. Sex distribution of discopathies in 147 patients.*

Sex	Number of cases	%
♂	69	46.9
♀	78	53.1

*Table 5. Average age of 147 patients with discopathies at registration for the operation.*

Sex	Average age in years
♂	39 <sup>0</sup> / <sub>12</sub>
♀	37
♂ + ♀	39

*Table 6. Age of 147 operated patients divided into decades.*

Decade	2.	3.	4.	5.	6.	7.
No. of cases	1	23	60	47	14	2
%	0.7	15.5	40.8	32.0	9.5	1.4

We have clearly seen that there is a significant accumulation of discopathies in the 4th and 5th decade, making up 72,8 per cent of all cases. There is an average of  $41^{10}/_{12}$  years between the onset of symptoms and the development of a clinical syndrome which forces the patient to operation at an average age of 39 years because of the mass of complaints. The fact that women are affected not only  $2\frac{1}{2}$  years earlier but are also affected 6.1 per cent more frequently than men is not uninteresting. Since the male sex is generally more exposed to heavy manual work, one must look in these figures for a relationship to pregnancy and the physical exertion of the birth process. In fact the women in this series consisted mainly of mothers of several children. The accumulation of 84 per cent of discopathies in the intervertebral discs L 4–L 5–SI confirms not only the well known fact that these discs combine the greatest functional performance but also that bodily stress plays a great role in the origin of discopathy. Therefore greater importance must be attributed to physical stress as a determining moment, than to the individual constitutional disposition, since multilocular discopathies only appear in a small percentage. These statements can be corroborated statistically by the following tables.

*Table 7. Localisation of discopathy in 147 patients with 178 affected and operated intervertebral discs.*

Localisation	L <sub>1</sub> –L <sub>2</sub>	L <sub>2</sub> –L <sub>3</sub>	L <sub>3</sub> –L <sub>4</sub>	L <sub>4</sub> –L <sub>5</sub>	L <sub>5</sub> –S <sub>1</sub>
Number of discs affected	2	14	14	62	86
%	1.1	7.8	7.8	35	48.3

#### THERAPY

In general practice it has frequently become customary to start treatment of lumbago or lumbago-ischias symptomatically without exact diagnostic clarification. Once the diagnosis has been made, a consequent operative therapy should be encouraged since it is only this procedure

Table 8. Isolated and combined occurrence of discopathy.

Discopathy	No. of cases	% *	No. of discs	% *
Isolated	119	81	119	67
Combined	28	19	59	33
<i>Combined</i>				
Not adjacent	1	3.5	2	3.6
Adjacent	26	96.5	57	96.4
L <sub>4-5</sub> +L <sub>5</sub> -S <sub>1</sub>	21	80	42	73.7
Others	5	20	15	26.3

\* The percentages apply to the corresponding group above.

Table 9. Anamnestic information from 147 patients as to the cause of the discopathy.

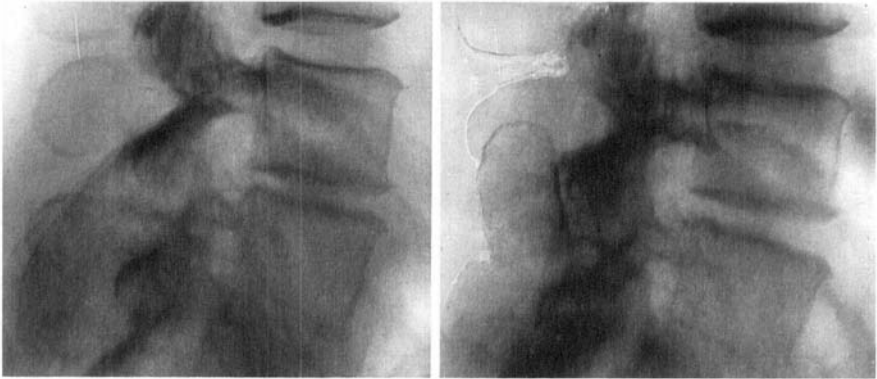
Anamnesis	Number of cases	%
Accident*	30	20.4
Positive family history	41	27.9
No information	76	51.7

\* The relationship to accident was only objectively confirmed in a few isolated instances.

Table 10. Classification according to bodily stress during work (reliable data were only obtained from 88 patients with discopathy).

Work load	Heavy labour	Moderately hard labour	Light labour or sitting occupation	Feminine occupations with physical stress
Cases	21	17	16	34
%	23.9	19.3	18.2	38.6

which is in a position as a causal measure to remove the pain. In principle it is the final immobilisation of the affected segment of movement. *Spondylodesis* presumes the operative inspection of the intervertebral discs by laminectomy. A herniotomy is only indicated in the specially situated cases of a dorsal protrusion of the disc. In order to bridge over the segment of movement, we wedge a graft taken from the dorsal iliac crest between the spinal processes.



a.

b.

a. *Discopathie L 4/5 preoperatively.*

b. *The same case postoperatively after fusion. Observe the significant widening of the intervertebral space.*

*The operative technique* is as follows: After preparation of the affected spinal processes, the interspinal ligament is resected and the spinal processes freshened. At the same time, the lumbar spine is kyphosed. The distance between the prepared spinal processes is measured and a strong pelvic graft with indented ends is clamped between the spinal processes. The patient is then brought into lordosis by appropriate elevation of the upper and lower ends of the operating table, whereby the spinous processes come nearer to each other, while the intervertebral space widens due to the graft and the disc can expand again. At the same time the surfaces of the intervertebral joints are brought back into normal relationship to each other. After completion of wound healing the patient receives a plaster corset in which he must lie for 3 months. After this period of time the lumbar graft is so far incorporated that it can already be exposed to axial pressure. In order to avoid bending stress, the recumbency-plaster cast is replaced by a shorter plaster corset which is applied in a standing position. In the case of a suitable job with little physical exertion, work can already be resumed at this stage. The final removal of the plaster cast follows after another 3 months. After a short period of care those patients with a manual job are now also able to work again.

## RESULTS

The results of this operative procedure in discopathies are excellent, especially if the operation is carried out early. Early operation should be specially strived for, before changes in the intervertebral joints, in the intervertebral foramina and above all in the nerve roots have developed.

The quality of the results can best be judged from the working capacity of the patients. The following statistics give information on the matter and a clear picture on the value of the method.

*Table 11. Working capacity of 145 patients before and after operation.*

		Working capacity			Not evaluated
		Full	Partial	Incapa- citate	
Before operation	cases	49	43	50	3
	%	33.8	29.7	34.5	2
After operation	cases	100	23	11	11
	%	69.0	15.8	7.6	7.6

It is of outstanding significance, that the number of patients capable of working after the operation rose to almost 70 per cent, while the number of those unable to work was barely 18 per cent. Before the operation those fully able to work, those able to work part time and those incapable of working were approximately equally divided among the three groups.

It is also important that the patients can return to their old jobs, *i.e.* that they are not forced to change their profession due to the operation. Here also we can present very encouraging figures.

*Table 12. Change of profession after the operation of 147 patients.*

		Number of cases	%
Profession	changed	14	9.6
	unchanged	126	87.0
Not evaluated		5	3.4

If one considers that 30 per cent had a hard manual job, 19 per cent a moderately hard one and that the 39 per cent of women belonged to the hard working social group, then the already low percentage of change of occupation of 9.6 per cent is insignificant.

If we consider the entire material critically, then the results are not only promising, but are to be considered excellent. Unfortunately 4 patients could not be followed-up. These, 2.7 per cent, do not influence the general evaluation of the results. If we base the evaluation on only three groups, good, satisfactory and poor, 87.9 per cent of good and satisfactory results, taking extensively into account the subjective impressions of the patients, can be designated as very satisfac-

tory in view of the overall result. In our opinion, a further differentiation could only follow the subconscious wish of the author for a higher evaluation of the results.

*Table 13. Results of the operation in 145 patients with discopathies.*

subjective	Opinion objective	Number of cases	Percentage
Satisfied	good	116	80
Partially satisfied	satisfactory	14	9.7
Dissatisfied	poor	11	7.6
Not evaluated		4	2.7

The good results speak for themselves. We would like however, to subject the 11 cases = 7.6 per cent with poor results to a more detailed analysis. In 2 patients a marked failure of the operative procedure was involved, since on the appearance of late symptoms after the operation a hernia of the nucleus pulposus could be demonstrated by myelography and operative treatment was required. All the remaining cases (9) gave a poor result owing to partial resorption of the bone graft or to a pseudarthrosis of the upper or lower spinous process. We only saw once that the graft was not incorporated either above or below. Insufficient immobilisation is certainly primarily responsible for the formation of a pseudarthrosis. As a second cause, the technique of implantation is of importance. If the graft is placed too loosely between the spinous processes, then a pseudarthrosis threatens to form between it and the spinous processes. If, on the other hand, the graft is clamped too tightly between the spinous processes, then the bone tissue is altered and undergoes similarly a pseudarthrosis under these conditions. Finally there is a further observation to be added, which is not applicable to the above 147 cases. It has been made previously on operations for spondylolysis and spondylolisthesis and concerns the use of *tibial grafts*, which were wedged in the same way between the spinous processes. Owing to the considerably harder consistency of the bone and to its reduced osteogenetic power as compared to pelvic bone, we observed a considerably higher frequency of pseudarthrosis with these grafts. It was for this reason that we were persuaded to use *pelvic grafts* exclusively.

It is remarkable that a series of patients complained of discomfort although they placed themselves into the group of the pleased, *i.e.*

satisfied. With this fact as a starting point we would like to compare objectively the 80 per cent of good results with the 17.3 per cent of moderate and poor results. Thus in Table 14 we find a summary of the postoperative complaints in 25 patients without statement of the combination which can be seen from the numbers without further comment.

*Table 14. Subjective complaints after the operation.*

		Number of patients		
No complaints		116		
Complaints		25		
Localisation		back	one leg	both legs
Type of complaint		How many times stated		
Pain		21 ×	17 ×	5 ×
Stiffness		20 ×		

Pain on coughing, sneezing and pressing is typical. We have tried to evaluate these complaints before and after the operation. We obtained reliable answers from only 70 patients.

*Table 15*

Pain on coughing, sneezing, pressing		
Number of cases	Before operation	After operation
	62	11
Percentage	88.5	15.7

If one considers the total of all postoperative complaints in those 25 patients which must be counted among the moderately satisfied and the poor results, the symptom free interval lasted 8 months after the operation. Regarding the symptom of pain on coughing, sneezing and pressing, we would like to mention that among 147 operated discopathies, we have found a herniated nucleus pulposus in only 20 cases (13.8 per cent).

Out of 147 discopathies which we operated, 141 cases could be evaluated for an end result; among them 116 obtained a good result and 25 were failures. Expressed in percentage this is 82.2 per cent positive against 17.5 per cent negative results. These numbers warrant the following conclusions:

1) In the treatment of discopathies, operative treatment should be undertaken as soon as possible.

2) The operative treatment consists of a spondylodesis with exploratory laminectomy.

3) The spondylodesis should be carried out with an iliac graft with grooves which is clamped between the spinous processes.

4) Postoperative immobilisation lasts 3 months in recumbency and a further 3 months in a plaster of Paris jacket.

5) Using the above technique, symptoms could be entirely relieved in 82.2 per cent of all patients.

6) Postoperatively the ratio of number of patients with full working capacity to those able to work partially to those unable to work at all was 70:15:8. A change in the patients' occupation occurred in a ratio of 1:9. 9/10th of the patients returned eventually to their previous occupation.

7) The duration of treatment of 7 months is justified in view of the much longer period of incapacity under conservative treatment and of the final result.

#### DISCUSSION

We would like to emphasize that our method of treatment and our experiences have been concerned primarily with the "degenerative low back syndrome" and not with acute herniated intervertebral discs, which occur mainly in the third decade of life (*Kraeyenbuehl & Zander 1953*). There has been much controversy as to whether to combine operations for intervertebral disc herniation with spinal fusion or not, and we do not consider our contribution a general plea for intervertebral fusion in all cases of discus hernia.

In young patients with isolated, acute intervertebral disc herniation, without any considerable degree of accompanying changes of the intervertebral joints, careful and complete disc removal has shown favorable results in a very high percentage. (*O'Connell 1951, Semmes & Murphey 1954, Bucy 1961*).

There can be no question however, that discopathy leads with time to regular derangement of the intervertebral joints. For example the clinical importance of facet arthrosis was stressed by *Putti* (1932, 1933) and concomitant pathology in the ligamentum flavum of practical significance was described by *Malmros* (1942). The interrelation of discopathy with intervertebral joint arthrosis and foraminal narrowing

was also demonstrated in an anatomic-pathological study by one of us (*Baumann 1957*).

A large number of patients belonging to the group we are reporting upon, suffered from a combination of symptoms originating at different points in the intervertebral segment of motion.

We agree with *Harmon (1964)* that for the therapeutic solution of the problems of low back pain and sciatica, attention has too long been focused exclusively on intervertebral disc herniation. While direct nerve root compression must be eliminated, freedom from symptoms in degenerative low back disorders can best be secured by an intervertebral bone block. This opinion is corroborated by our finding, that 9 out of 11 unsatisfactory results were related to failure to obtain bone fusion. The rate of failure in obtaining intervertebral fusion observed by *Harmon (1964)* following anterior interbody fusion does not differ substantially from ours. The anterior approach apparently allows the period of recumbency following the blocking operation to be reduced to about one week. We have found nerve root inspection a very important step in our procedure, which the anterior approach does not allow. As the total period of convalescence does not differ considerably, the posterior procedure described here is, therefore, preferred by the authors.

#### SUMMARY

Follow-up results are reported on 147 patients who had been operated for a lumbar degenerated disc syndrome by posterior exploratory partial laminectomy and interspinous fusion with iliac grafts. There were 89.7 per cent of good and satisfactory results. 87 per cent of the patients could continue their previous occupation. The advantages of a posterior approach which allows inspection of the spinal canal and the nerve roots over anterior interbody fusion are stressed.

#### ZUSAMMENFASSUNG

Bericht über Ergebnisse von 147 Spondylodesen wegen Degeneration lumbaler Zwischenwirbelscheiben.

Die Nachuntersuchung wies 89.7 pro zent guter und befriedigender Ergebnisse auf. 87 pro zent der Patienten konnten ihren ursprünglichen Beruf wieder aufnehmen. Die Durchführung der hinteren Spondylodese erlaubt die Inspektion des Spinalkanals u. der Nervenwurzeln vor der Verblockung mit dem Span. Darin liegt ein Vorteil gegenüber der vorderen intercorporalen Verblockung.

## RESUME

Résultat de 147 arthrodèses vertébrales pour dégénérescence du disque intervertébral lombaire.

Les examens de contrôle ont montré des résultats bons et satisfaisants dans 89.7 pour cent des cas. 87 pour cent ont pu reprendre leur profession antérieure. L'arthrodèse postérieure donne l'avantage de pouvoir durant l'opération contrôler le canal spinal et les racines nerveuses avant son exécution avec un greffon.

C'est un grand avantage par rapport à l'arthrodèse par voie antérieure.

## REFERENCES

- Armstrong, J. R. (1951) The causes of Unsatisfactory Results from the Operative Treatment of Lumbar Disc Lesions. *J. Bone Jt Surg.* **33B**, 31-35.
- Baumann, J. U. (1957) Beiträge zur Kenntnis der Altersveränderungen der Lendenwirbelsäule beim Menschen unter besonderer Berücksichtigung von Bandscheiben und kleinen Wirbelgelenken. *Helv. chir. Acta* **24**, 9-38.
- Bucy, P. C. (1961) Neuroanatomical and Neurosurgical Aspects of Herniated Intervertebral Discs. *A.A.O.S. Instructional Course Lectures* **18**, 21-35.
- Chapchal, G. (1956) Frühoperation bei der Behandlung der lumbalen Bandscheiben degeneration. *Contemporary Rheumatology* 340-342.
- Chapchal, G. (1957) Quelques remarques sur la dégénérescence du disque intervertébral et son traitement. *La Presse Médicale* **75**, 1380-1382.
- Compere, E. L., Schnute, W., Compere, C. L. & Thompson, R. G. (1958) Intervertebral Disc Removal and Spine Fusion. *Amer. J. Surg.* **96**, 624.
- Harmon, P. H. (1964) Indications for Spinal Fusion in Lumbar Diskopathy, Instability and Arthrosis. *Clin. orthop.* **34**, 73-107.
- Harmon, P. H. (1964) A Simplified Surgical Technic for Anterior Lumbar Diskectomy and Fusion. *Clin. orthop.* **37**, 131-144.
- Luck, J. V. (1961) Discogenic Syndromes-Factors in Differential Diagnosis. *A.A.O.S. Instructional Course Lectures* **18**, 35-40.
- Malmros, R. (1942) Den lumbale Discusprolaps og ligamentaere Rodkompression. Einar Munksgaard, Kopenhagen.
- O'Connell, J. E. A. (1951) Protrusion of the Lumbar Intervertebral Discs. *J. Bone Jt Surg.* **33B**, 8-30.
- Semmes, R. E. & Murphey, F. (1954) Ruptured Intervertebral Discs: Cervical, Thoracic and Lumbar, Lateral and Central. *Surg. Clin. N. Amer.* 1095.
- Stinchfield, E. & Cruess, R. L. (1961) Indications for Spine Fusion in Conjunction with Removal of Herniated Nucleus Pulposus. *A.A.O.S. Instructional Course Lectures* **18**, 41-46.
- Töndury, G. (1958) Ueber neuere Erkenntnisse zur Entwicklung der Wirbelsäule und ihre Bedeutung zum Verständnis von Wirbelsäulenmissbildungen. *Wirbelsäule in Forschung und Praxis* **5**, 7.