

From Pori General Hospital (Head: Professor Aulis Korhonen, M.D., deceased),
Pori, Finland.

TREATMENT OF "MALLET FINGER" DEFORMITY BY MEANS OF SKIN STRIP

By

PEKKA NUMMI

Received 22.XI.66

Rupture of the extensor tendon of the terminal phalanx of the finger is a common complaint and often awkward to treat. The tendon tissue here is thin, so it may be easily ruptured even by a small trauma. The rupture may be subcutaneous, and the dorsal corner of the terminal phalanx is often fissured together with tendon tissue. The rupture may also frequently occur in connection with a wound or laceration. The rupture results in a so-called mallet finger deformity.

A fresh subcutaneous rupture is usually treated conservatively with immobilization. Since the hand must be washed and is in partial use, immobilization with plaster-of-paris often fails. The plaster when moistened becomes soft and loses its efficiency. This has resulted in the construction of various metal splints (*e.g. Winterstein 1951*). Despite all efforts the results achieved by conservative therapy are only relatively good. *Hallberg & Lindholm (1960)*, for example, presented a series of 107 patients treated conservatively and followed up; an extension defect of over 20 degrees remained in 53 of these cases, while another 22 continuously suffered some degree of pain.

Pratt, Bunnell & Howard (1957) described internal fixation with percutaneous drilling, a method in which a Kirschner wire drilled percutaneously through the terminal and the basal phalanges acts as an internal splint. *Böhler (1953)* described a fixation with two wires drilled crosswise through the terminal phalangeal joint.

A rupture accompanying a cut can be treated when the wound is being closed, for example with a percutaneous, so-called figure-of-eight suture using metal wire (*Moberg 1956*).

In cases in which conservative treatment has failed or the injury

has been neglected for a long time, surgery is necessary. One method is the fixation of the extensor tendon, as described by *Bunnell* (1944); the loose end of the tendon is fixed with a pull-out wire suture at its point of insertion. *Nichols* (1951) proposed reconstruction with the aid of a graft taken from the palmaris longus tendon.

Since the operative methods of treatment are relatively laborious, the present author used simple reconstruction with the aid of whole-thickness skin strip for the treatment of the "mallet finger" deformity. The use of skin in tendon repairs has long been known. For example, *Loewe* (1913) replaced the defect of the extensor tendon of the thumb with a strip of skin from which the epidermis had been scraped off. Having used skin for the plastics of inguinal hernia he found that a tissue specimen taken from it later showed metaplasia. The sweat and sebaceous glands peculiar to the skin disappeared while the elastic fibres were well preserved. A similar finding was made by *Rehn* (1919), who studied graft changes also by animal experiments. Subsequently skin has been increasingly used in tendon reconstruction, as stated *e.g.* by *Brandis* (1941). Earlier the epidermis was removed, but whole-thickness skin was later introduced. Its usefulness and the metaplasia occurring in it have been studied in animal experiments *e.g.* by *Kivilaakso* (1955) and *Jokinen* (1958). The former found that the skin graft gradually became similar to the original tendon tissue. *Jokinen* found in her studies that a tendon replaced with skin was equal after one year to normal tendon tissue in tensile strength.

Whole-thickness skin was used in the reconstruction of the extensor tendon of the terminal phalanx described below.

M A T E R I A L

The series of patients derived from Pori General Hospital during 1957-65. All types of cases, regardless of the type of injury involved, were treated, as can be seen from the attached table. One of the patients was female, the others male. Six were under 15 years of age, the balance were adults, and the oldest was 51. The fingers affected were 4 forefingers, 6 middle fingers, 8 ring fingers, and 1 little finger.

M E T H O D O F T R E A T M E N T

The techniques were as follows: a T-incision was made in the skin (Figure 1 a). The strip of skin remained attached at the distal part of the finger. The strip must be a minimum of 2 mm wide. The skin at the sides of the finger was detached from its base over a sufficiently wide area so that, on closing, the margins extended across

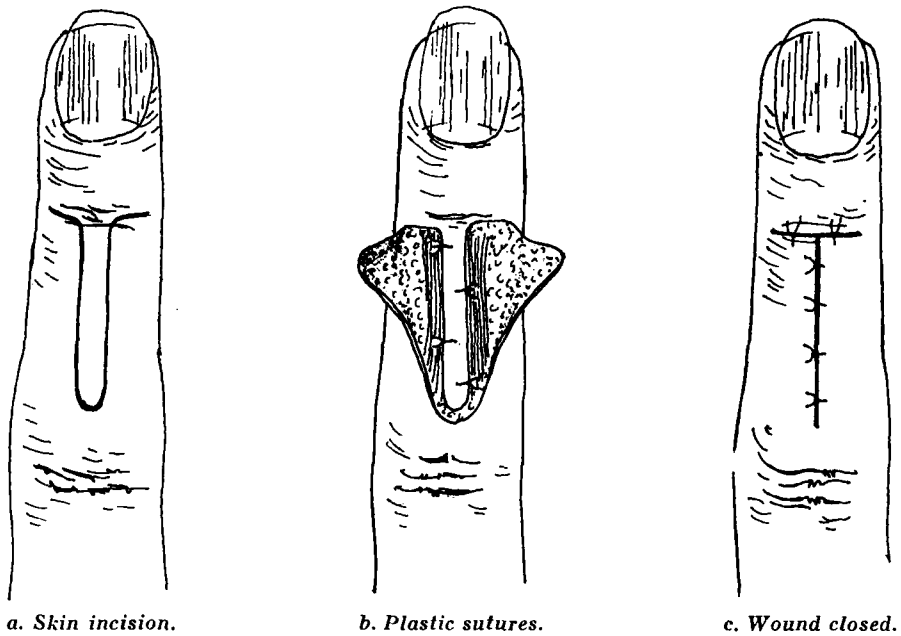


Figure 1.

the strip of skin. The strip of skin was sutured, with the terminal phalanx overextended, to the proximal aponeurosis with 4-5 mercelen sutures (Figure 1 b). The wound was closed so as to cover the strip of skin (Figure 1 c). The finger was immobilized, with the terminal phalanx overextended, by means of a metal or plaster-of-paris splint for 3-5 weeks (see Table 1).

All the patients were treated at the outpatient clinic, and prophylactically they were given penicillin or some other antibiotic.

RESULTS OF TREATMENT

All the patients were followed up, and the results presented are late findings. The periods of observation ranged from 6 months to 8 years.

The table gives the therapeutical result as related to the type of injury and the date by which treatment started.

In all cases of subcutaneous rupture the therapeutical result was good, although many were treated weeks after the injury. Figure 2 gives an example of the result.

Ruptures accompanying a cut were treated in the secondary phase after the wound had healed, and the result was good in all of them.

There were 6 ruptures accompanied by lacerated bruises; the result

Table 1. Cases Treated with Skin Plastics and Results of Treatment.

		No.	Immobiliza- tion, weeks	Suppuration of sutures, ended, weeks after operation	Result of treatment*
Subcutaneous rupture	Skin plastics within 2 weeks of injury	4	3-6	4-7	good
	No primary treatment, skin plastics within 3-4 weeks of injury	2	3-5	4-8	good
	Primary plaster-of-paris immobilization, skin plastics within 6-7 weeks of injury	3	3-5	0-4	good
Rupture and cut	No primary treatment, skin plastics within 3-6 weeks of injury	3	3-4	4-12	good
	No primary treatment, skin plastics within 11 weeks of injury	1	4	0	good
Rupture and lacerated bruise	No primary treatment, skin plastics within 4 weeks of injury	1	3	6	good
	No primary treatment, skin plastics within 7 weeks of injury, transverse fracture of terminal phalanx	1	5	3	good
	No primary treatment, skin plastics within 3 weeks of injury	1	4	4	fair
	No primary treatment, skin plastics within 10-21 weeks of injury	2	3-4	6	fair
	No primary treatment, skin plastics within 11 weeks of injury transverse fracture of middle phalanx	1	4	4	poor
Total		19			

* Results of treatment:

good = extension deficit less than 5°, flexion deficit less than 10°.

fair = extension deficit less than 35°.

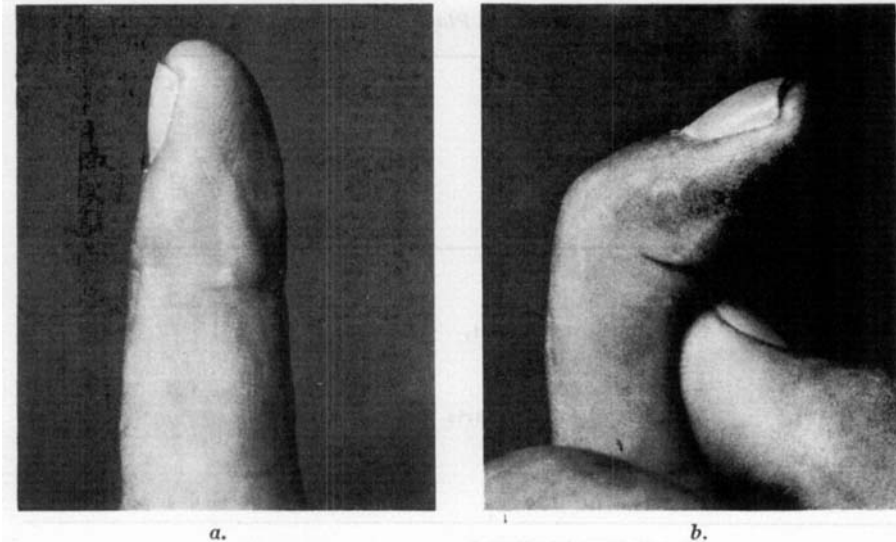


Figure 2. Male patient, aged 33 years. Subcutaneous rupture of the extensor tendon of the terminal phalanx of the middle finger of right hand photographed 5 years after treatment. a. extension, b. flexion.

was good in only 2. In 3 cases the result was inconclusive, while one, a case of open comminuted fracture of the terminal phalanx, showed no improvement.

A complication was infection of the wound in the late phase. The infection was always superficial. Sutures used in the skin plastics were removed as they became visible. The dates when the suppuration ended are given in the table.

DISCUSSION

A review of the therapeutical results shows that the method of treatment described provides a good result in subcutaneous rupture regardless of the lapse of time from injury to treatment. The same applied to the treatment of old ruptures associated with a cut. In complicated cases of lacerated bruise improvement is possible if the passive function of the joint is intact and no important scarring is present in the dorsal skin of the middle phalanx or in the aponeurosis. The infection of the wound is understandable as the plastics form, as it were, a skin pocket. The therapeutical result did not suffer from the infections. It is therefore difficult to say which affects the improvement more in this treatment: the support which the skin strip provides and the metaplasia

that occurs in the skin strip, or the cicatricial tissue formed by infection.

No cyst formation or disfiguring scars were noted.

SUMMARY

The author describes a method of treating a ruptured extensor tendon of the terminal phalanx of the finger. A strip is taken from the dorsal skin of the finger so that its distal end remains attached at the terminal phalanx. The strip of skin is sutured to the proximal aponeurosis using mercelen sutures. The skin detached from its base along the sides of the finger is sutured on top of the strip. The finger is immobilized for 3-5 weeks. The sutures caused superficial infection in almost all the cases, but this did not impair the therapeutical result. The tendon healed well in all simple subcutaneous ruptures and in ruptures accompanying a wound, despite the fact that the majority were not treated until over 3 weeks after the injury. In cases with lacerated bruises the result was inconclusive.

RESUME

L'auteur décrit une méthode de traitement de la rupture du tendon extenseur de la phalange terminale du doigt. Un lambeau de la peau dorsale du doigt est prélevé de manière que son extrémité distale reste attachée à la phalange terminale. Le lambeau de peau est réuni à l'aponévrose proximale par sutures mercelènes. La peau détachée de sa base le long du doigt est suturée sur le sommet du lambeau. Le doigt est immobilisé pendant 3 à 5 semaines. Les sutures provoquent une infection superficielle dans pratiquement tous les cas, mais cela ne nuit pas au résultat thérapeutique. Le tendon se guérit bien dans tous les cas de rupture sous-cutanée simple et dans les ruptures qui accompagnent une blessure, malgré le fait que la majorité des cas n'ont pas été mis en traitement immédiatement, mais qu'il s'est parfois écoulé plus de trois semaines après la lésion. Dans les cas de contusions lacérées, le résultat n'a pas été concluant.

ZUSAMMENFASSUNG

Der Verfasser beschreibt eine Methode zur Behandlung der zerrissenen Strecksehne der Endphalanx des Fingers. Ein Streifen der dorsalen Haut des Fingers wird verwendet derartig dass sein distales Ende an

der Endphalanx befestigt bleibt. Der Hautstreifen wird mittels Mercelennähten an die proximale Aponeurose genäht. Die von ihrer Basis gelöste Haut an den Fingerseiten wird nun über den Streifen genäht. Der Finger wird 3–5 Wochen ruhiggestellt. Die Nähte verursachten in fast allen Fällen eine oberflächliche Infektion, was jedoch das Behandlungsergebnis nicht störte. Die Sehne heilte gut in allen Fällen von einfachen subkutanen Rupturen und von Rupturen im Zusammenhang mit einer Wunde, obwohl die Mehrzahl erst über drei Wochen nach dem Schaden behandelt wurden. In Fällen mit lacerierten Wunden war der Erfolg unsicher.

REFERENCES

1. v. Brandis, H.-J. (1941) Die Cutisplastik nach E. Rehn. *Der Chirurg* **13**, 418.
2. Bunnell, S. (1944) *Surgery of the Hand*. J. B. Lippincott Company, Philadelphia.
3. Böhler, J. (1953) Behandlung der Strecksehnenaustrisse der Fingerendglieder mit percutanen Bohrdrähten. *Msschr. Unfallheilk.* **56**, 216.
4. Hallberg, D. & Lindholm, A. (1960) Subcutaneous Rupture of the Extensor Tendon of the Distal Phalanx of the Finger: "Mallet Finger". Brief Review of the Literature and Report on 127 Cases Treated Conservatively. *Acta chir. scand.* **119**, 260.
5. Jokinen, T. (1958) Tensile strength of the whole-thickness skin graft used as replacement of tendon and ligament defects. An experimental study. *Acta orthop. scand.*, Suppl. 36.
6. Kivilaakso, R. (1955) Changes in the whole-thickness skin graft buried in tissue. Experimental study. *Acta orthop. scand.* Suppl. 18.
7. Loewe, O. (1913) Ueber Hautimplantation an Stelle der freien Faszienplastik. *Münch. med. Wschr.* **60**, 1320.
8. Moberg, E. (1956) *Akut handkirurgi*. C. W. K. Gleerups Förlag, Lund.
9. Nichols, H. M. (1951) Repair of extensor-tendon insertions in the fingers. *J. Bone Jt Surg.* **33 A**, 836.
10. Pratt, D. R., Bunnell, S. & Howard Jr., L. D. (1957) Mallet finger. Classification and methods of treatment. *Amer. J. Surg.* **93**, 573.
11. Rehn, E. (1919) Zu den Fragen der Transplantation, Regeneration und ortseinsetzenden funktionellen Metaplasie. (Sehne – Fascie – Bindegewebe.) *Arch. klin. Chir.* **112**, 622.
12. Winterstein, O. (1951) Behandlung der Strecksehnenunterbrechung an den Fingerendgliedern. *Schweiz. med. Wschr.* **81**, 789.