Acta orthop. Scandinav. 43, 438–460, 1972

The Orthopaedic Hospital of the Invalid Foundation,
Helsinki, Finland.

SUBTALAR EXTRA-ARTICULAR FUSION IN THE TREATMENT OF VALGUS AND VARUS DEFORMITIES IN CHILDREN

A Review of 162 Operations in 136 Patients

UOLEVI LAHDENRANTA & PAULI PYLKKÄNEN

Accepted 13.iv.72

Since Grice reported his cases of extra-articular subtalar arthrodesis of the foot in children in 1952, the operation has become widely used in the treatment of unstable feet resulting from paralysis in children. It has made a major contribution towards solving the problems associated with paralytic feet in young growing children.

The first papers published (Baker & Dodelin 1958, Grice 1952, 1955, 1959, Malvarez 1957, Weissman, Torok & Kharmosh 1957, Westin & Hall 1957) reported good results after a short follow-up period. Since the grafts are placed in the tarsal sinus, they are essentially extra-articular in position and should therefore cause the least possible interference to growth. The advantage of the method is that height is restored to the tarsus by the operation. Corrective extra-articular fusion of the subtalar joint also restores the normal alignment on the talonavicular and calcaneocuboid joints. The technique is simple and mechanical fixation of the joint is obtained with the grafts. The operation is recommended as a definitive procedure for correcting the deformity in young growing children, but in 1957 Grice still could not give a final answer as to whether this operation represents a definitive procedure or whether it must be followed by triple arthrodesis at a later date. However, by 1959 he could state that in properly selected patients, there were strong indications that it would be a definitive procedure.

Since that time many surgeons (Baker & Hill 1964, Brown 1963, Friedman 1965, Haraldsson 1965, Herold et al. 1965, Hunt & Brooks 1965, Picard & Mimran 1961, Schneider & Westin 1963, Thomas 1967,

Zachariae 1963) have presented their results of this operation, analysing the complications and factors causing unsatisfactory or poor results. The purpose of the present paper is to review our experience of correcting the valgus deformity of the foot in children by means of the usual subtalar extra-particular bone-graft fusion, and the varus deformity by the usual method or its modifications.

MATERIAL AND METHODS

From 1956 to 1969, 136 children (74 boys and 62 girls) underwent the Grice operation at the Orthopaedic Hospital of the Invalid Foundation. Both ankles were operated on in 26 children (21 boys and 5 girls). The total of ankles treated was therefore 162 (Table 1).

Valgus deformity was the indication for 134, varus deformity for 28 operations. The former was produced by poliomyelitis in 118 ankles and by other diseases in 16 ankles, the varus deformity by poliomyelitis in 23 and other diseases in 5 ankles.

Only one patient was operated on in 1956, the year when the operation was introduced. Because of an epidemic of poliomyelitis, 58 valgus ankles and 15 varus ankles were treated in 1957–1958. All varus deformities were operated on from 1957 to 1965.

Table 1. The disease that had caused valgus or varus deformity in the growing foot of 136 children.

Disease	No. of patients	No. of ankles, by deformity	
		Valgus	Varus
Poliomyelitis	118	118	23
Cerebral palsy	3	3	–
Static planovalgus	3	3	–
Meningomyelocele	2	3	–
Chondrodystrophy	1	2	–
Ehlers-Danlos syndrome with talus verticalis	1	2	–
Polyradiculitis	1	1	–
Traumatic rupture of the anterior tibialis muscle	1	1	–
Arthrogryposis	1	1	–
Talipes equinovarus	2	–	2
Muscular dystrophy	1	–	1
Fourth lumbar hemivertebra and deformity of the lower limbs	1	–	1
Traumatic lesion of the fibular nerve	1	–	1
Total	136	134	28

Table 2. Age of patients at operation, at follow-up and duration of follow-up for valgus and varus deformities.

	Age at operation				
Years	3–4	5–6	7–8	9–10	11–16
No. of valgus ankles	33	33	36	25	7
No. of varus ankles	5	4	13	4	2
	Age at follow-up				
Years	6–10	11–12	13–14	15–16	17–23
No. of valgus ankles	14	21	21	31	47
No. of varus ankles	1	1	–	6	20
	Duration of follow-up				
Years	Under 1	1–2	3–4	5–8	9–13
No. of valgus ankles	3	11	11	41	68
No. of varus ankles	–	–	2	5	21

The ages of the patients ranged from 3 to 16 years. Only 9 ankles of children aged 11 years or more were operated on. A follow-up examination was carried out in the spring of 1970, with a total of 149 ankles, of 124 patients, examined both clinically and roentgenologically. Running follow-up entries, with roentgenograms and photographs, were available in the hospital records on all of them, as well as on the 12 patients who failed to attend this particular follow-up examination. The follow-up periods ranged from just under a year to 12 years, average 9 years. *At the time of the follow-up examination or the last outpatient clinic visit, nearly two-thirds of the treated ankles were completely or almost completely full-grown* (Table 2).

Operative Technique

These operations were made by 23 surgeons. The varus deformities were operated by 8 surgeons.

The original technique described by Grice in 1952 was always used to correct the valgus deformity. The autogenous bone was taken from the proximal metaphyseal region of the tibia. In addition to the two grafts, either cancellous bone or bone chips were frequently placed in the tarsal sinus around the grafts. The period of immobilization in a below-the-knee plaster cast was three months, with no weight-bearing for six to eight weeks and the remaining period in a walking cast.

Varus deformity was treated with the so-called "reversed Grice operation". The

original Grice method was used in 11 cases. Its modification, developed by A. Langenskiöld, was used in 17 varus ankles. In this modification, the stability of the subtalar joint is achieved by means of a Blount's staple driven from the lateral side of the tarsal sinus across the subtalar joint, thus fixing the ankle in the correct position. Underneath the staple, in the emptied tarsal sinus, cancellous bone and bone chips, but no true bone grafts, are placed. In 3 cases the staple was omitted, but the tarsal sinus was filled with cancellous bone and bone chips. Postoperative treatment with plaster cast immobilization was the same as in the original Grice operation.

Tendon transfers were carried out intraoperatively. If necessary, re-transfers were made one or more years postoperatively to eliminate deformity. In a few cases the Grice operation was performed after unsuccessful attempts at correcting the deformity by tendon transfers alone. Only the Achilles tendon, in the elimination of equinus deformity, was lengthened preoperatively as an integral part of the correction.

RESULTS

The results were classified as good, satisfactory, or poor. The result was interpreted as good if the subtalar joint, when the ankle was at right angles, showed not more than 5° of valgus and no varus at all; as satisfactory if the varus of the subtalar joint was not more than 5° and valgus not more than 15°, and poor if the varus exceeded 5° or valgus 15°. If a Grice operation had to be reperformed on the same ankle, the final result assessed was that of the refusion. If after the Grice operation, a triple arthrodesis had been carried out before the follow-up examination, the result of the Grice operation was classified as poor.

The early or primary results are those which became manifest during the first six months, while those observed after six months are classified as late results.

The assessment of the varus and valgus deformities on the basis of roentgenograms proved to be difficult, and therefore the assessment of the final results is based on clinical observations made while the patient was walking and standing.

In a few cases the ossification of the grafts was difficult to assess from roentgenograms only. In these cases the stability of the arthrodesis was ascertained also by clinical examination.

Early Results

The operation itself, as a technical problem, is easy and safe. No fatal complications occurred.

In no case did osteitis develop in the tarsal sinus region. A slight inflammation developed in one case at the site from which the graft had been taken. On three occasions an inflammation developed at the site of reinsertion of tendon transferred intraoperatively. These inflammations also healed rapidly after the reinsertion sutures had been removed.

In operations for *valgus deformity* the early result was good on 126 occasions. Undercorrection occurred on seven occasions, and only once did the operation result in overcorrection, i.e. a varus deformity .

The series included severely paralysed patients with osteoporosis of the ankles. In such ankles the bone grafts tend to sink too deeply into the talus and/or calcaneus. This, however, was the cause only twice of insufficient correction. Non-ossification or slow ossification of grafts which were in a good position produced undercorrection in two cases, whereas in three undercorrected ankles the grafts were well positioned and rapidly ossified.

In *varus deformities* the early result of the operation was good in twenty-one cases. No overcorrection was obtained primarily but undercorrection occurred seven times. Inadequate results followed both the original Grice operation and the modified method.

Late Results

The late results in *valgus deformities* differed a great deal from the early results. Good late results numbered 81, satisfactory 32, and poor 21. In the deformities following polio, the satisfactory results showed

Table 3. Late results after Grice operations for valgus and varus deformities caused by poliomyelitis or other diseases.

Disease	Good	Satisfactory		Poor		All
		Undercorrection	Overcorrection	Undercorrection	Overcorrection	
			Valgus deformity			
Polio	75	11	12	3	17	118
Others	6	9	–	1	–	16
All	81	20	12	4	17	134
			Varus deformity			
Polio	6	4	1	11	1	23
Others	1	1	–	3	–	5
All	7	5	1	14	1	28

approximately equal numbers of over- and undercorrections, and the poor late results were mainly due to overcorrection. The poor and satisfactory final results in valgus deformities due to conditions other than poliomyelitis were always undercorrections (Table 3).

In *varus deformities,* the late results were good on 7, satisfactory on 6 and poor on 15 occasions. An undercorrection recorded at the early follow-up was a prognosis for the late results, for later satisfactory and poor results were almost invariably undercorrections (Table 3).

Factors Influencing the Late Results

Refusions and their causes: Extra-articular refusions were carried out on eight ankles, one to three years after the primary operation. The indications were either a non-ossification of the primary fusion and/or deformities that had remained or developed after the Grice operation.

In 14 *valgus ankles* the primary grafts failed to fuse. Ossification in a good position was achieved by means of refusion in 4 valgus ankles. In one *varus ankle* the primary grafts were not ossified, but a refusion using the modified method led to a good result. In two valgus ankles and one varus ankle the refusion did not improve the deformity.

Of the 10 non-ossified *valgus ankles,* no less than 7 attained a good result, 2 a satisfactory and one a poor result. This was unexpectedly good. In only two of the cases with a good final result, tendon transfer had been carried out intraoperatively, and in another two the Achilles tendon had been lengthened. In the event of non-ossification, the cicatrix developing in the tarsal sinus is sufficiently strong, and position retainment of the dynamic balance of the ankle is not much disturbed.

Grice operation without tendon transfers: Subtalar fusion alone, without tendon transfer, was performed in 55 *valgus ankles.* A good two-thirds of the final results were good, and only a few were poor. It is worth pointing out that the satisfactory results almost without exception represented undercorrection, and only two cases with poor results were overcorrected. Eleven *varus deformities* were treated with a Grice fusion alone. Only two were operated on with the customary method, and the final result was good in both. With Langenskiöld's modification, equal numbers of the final results were good, satisfactory and poor. The satisfactory and poor results were almost exclusively due to undercorrection (Table 4).

Table 4. Late results after Grice operations and its modifications without or with tendon transfers.

Operation	Good	Satisfactory		Poor		All
		Undercorrection	Overcorrection	Undercorrection	Overcorrection	
			Valgus deformity			
Grice operation without tendon transfers	38	11	1	2	3	55
Grice operation with tendon transfers	43	9	11	2	14	79
All	81	20	12	4	17	134
			Varus deformity			
Grice operation without tendon transfers	2	–	–	–	–	2
Grice operation with tendon transfers	2	1	–	6	–	9
Langenskiöld operation without tendon transfers	3	2	1	3	–	9
Langenskiöld operation with tendon transfers	–	2	–	5	1	8
All	7	5	1	14	1	28

Grice operation combined with tendon transfers: When *valgus deformities* were corrected, over half the number of the final results were good. The satisfactory results were due as much to under- as to overcorrection, but the poor final results almost exclusively to overcorrection (Table 4).

It was unexpected that the transfer of the two peroneal tendons to the dorsum of the foot should have produced poor and satisfactory results, especially because of overcorrection, i.e. the development of a varus deformity. A transfer of only one peroneal tendon produced overcorrection relatively much more seldom and led to a good final result in about two-thirds of the cases, whereas when both peronei were transferred only less than one-third produced a good final result. Transfer of the two peronei to the calcaneus produced an overcorrection relatively much less frequently than their transfer to the dorsum pedis, but even so the danger did exist (Table 5).

Table 5. Intraoperative tendon transfers and late results after different types of combined procedures for valgus deformities.

Type of intraoperative tendon transfers		Good	Satisfactory Under-correction	Satisfactory Over-correction	Poor Under-correction	Poor Over-correction	All
To Dorsum Pedis	Both peronei	11	2	5	1	9	28
	Peroneus brevis or longus	15	2	3	1	1	22
	Others	2	1	–	–	1	4
	All	28	5	8	2	11	54
To Calcaneus	Both peronei	7	2	1	–	2	12
	Peroneus brevis or longus	6	–	1	–	1	8
	Others	2	2	1	–	–	4
	All	15	4	3	–	3	24

Table 6. Intraoperative tendon transfers and late results after different types of combined procedures for varus deformities.

Type of intraoperative tendon transfers		Good	Satisfactory Under-correction	Satisfactory Over-correction	Poor Under-correction	Poor Over-correction	All
To Dorsum Pedis	Tibialis anterior	1	2	–	3	1	7
	Tibialis posterior	–	–	–	3	–	3
	Others	1	–	–	–	–	1
	All	2	2	–	6	1	11
To Calcaneus	Tibialis posterior	1	–	–	–	–	1
	Tibialis posterior and both peronei	1	–	–	1	–	2
	Others	1	–	–	2	–	3
	All	3	–	–	3	–	6

When *varus deformities* were corrected nearly two-thirds the final results were poor. These poor results were almost exclusively due to undercorrection (Table 4). There was only one instance of overcorrection, produced by transfer of the anterior tibial tendon (Table 6).

The *lengthening of the Achilles tendon* is not considered a tendon transfer. It was combined with the Grice operation 9 times preoperatively and 17 times intraoperatively. Twice only was it necessary to lengthen the Achilles tendon after a Grice operation. The equinus deformity was usually easy to control.

Tendon transfers before and after a Grice operation: Before Grice operation, attempts had been made to correct 8 valgus ankles by tendon transfers alone. The degree of correction was practically always insufficient; only once was there an overcorrection, and the result was never good. It should be borne in mind that the present study was concerned with ankles whose deformity necessitated a later Grice operation. Three attempts had been made to correct the varus deformity by tendon transfer alone but the results were inadequate. However, in one valgus and one varus ankle the transferred tendon, which at first gave an inadequate degree of correction, after a later Grice operation resulted in overcorrection; the valgus ankle developed a varus deformity and the varus ankle a valgus deformity.

Attempts were made on seven occasions to improve the result of a Grice operation by tendon transfers, carried out one to eight, average a good three years, after the subtalar fusion. The varus deformity which has developed postoperatively into a valgus ankle could be corrected once but five attempts failed. Nor could the inadequate result of a modified Grice operation on one varus ankle be improved by tendon transfers.

Triple Arthrodesis

By the time of the follow-up, triple arthrodesis had been carried out in 14 valgus and 8 varus ankles. Only once was the causative factor a valgus deformity resulting from undercorrection, while in the other cases a varus deformity was involved, in valgus ankles arising from overcorrection and in varus ankles from undercorrection.

At the time of the operation the patients were 10 to 18 years old. The triple arthrodesis was performed 3 to 13 years, average 7½ years, after the Grice operation. It restored the ankles to a good or at least satisfactory position as regards varus and valgus deformities. In two cases the equinus position was eliminated at the same time by means of the Lambrinudi modifications.

The Effect on the Bones and Ligaments

The routine and also the modified extra-articular fusion proved to have little effect on the growth of the talus and calcaneus bones. On the completion of growth, after the talus and calcaneus had been ossified and assumed their final form, the joint space seen on roentgenography in the extra-articularly fused subtalar joints was found to

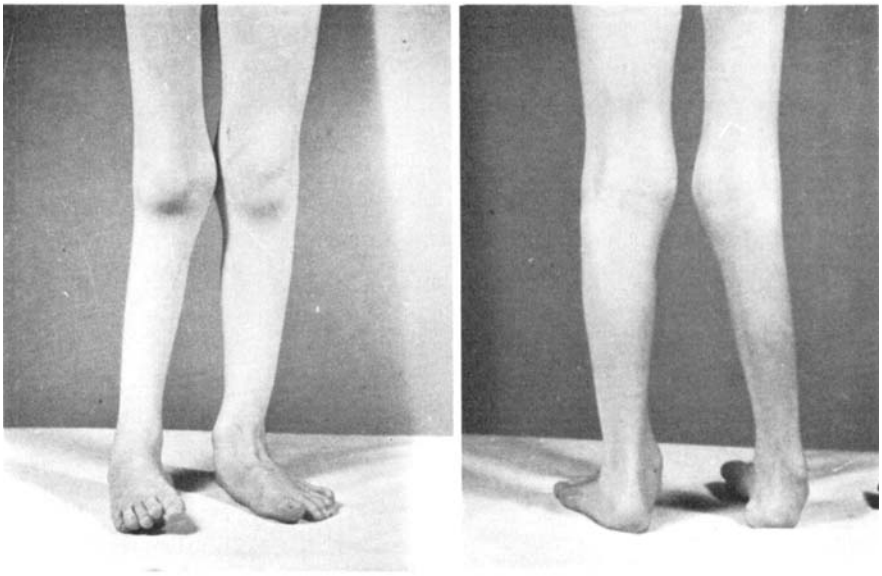

Figure 1 A. The patient was a four-year old boy who had had poliomyelitis eighteen months earlier. Preoperative back and front views showing planovalgus deformity on the left and varus deformity on the right side.

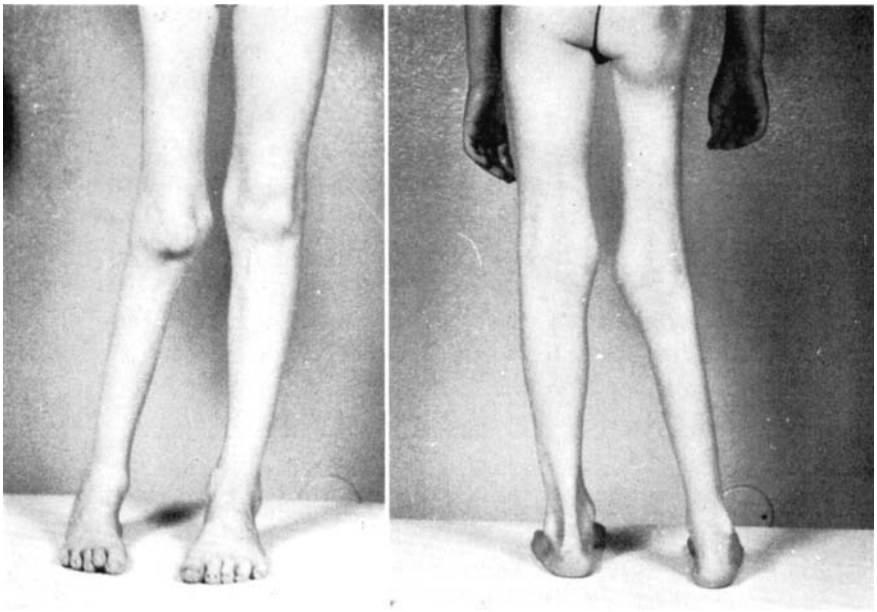

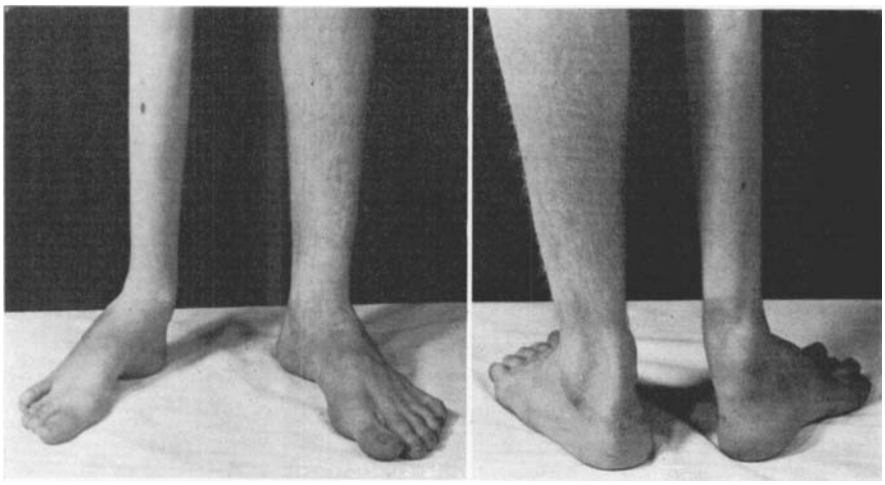

Figure 1 C. Back and front views twelve years postoperatively when the boy was sixteen years old. The result on the left side was good and on the right side satisfactory, the preoperative varus deformity having changed into a moderate valgus with a considerable calcaneus deformity in a stabilized heel in a totally paralysed foot.

have greatly narrowed. The anterior part of the subtalar joint, especially, had narrowed or even completely ossified, according to the plain roentgenography. On the completion of the growth phase, 10 subtalar joints proved to be almost totally fused.

In the case chosen as a sample (Figure 2), the complete fusion of the subtalar joint resulted from a too radical removal of the cartilaginous surfaces of the tarsal sinus. Furthermore, the grafts to the talus had been placed too posteriorly, with too much cancellous bone around the grafts. In some cases the grafts were placed parallel to the tibia while the ankle was in equinus position, extending obliquely from the posterior part of the talus to the anterior part of the calcaneus. For this reason the fusion spread even outside the tarsal sinus. Even in these cases the effect to Grice arthrodesis on the growth on the talus and the calcaneus proved to be slight.

In severely paralysed lower limbs the whole ankle and foot remained

---

Figure 1 B. Back and front views eighteen months after the usual Grice procedure and tendon transfers, e.g. fibulares and tibialis posterior to dorsum pedis on the left side, and the modified Grice-Langenskiöld, so-called "reversed Grice" on the right side. The boy was nearly six years old.

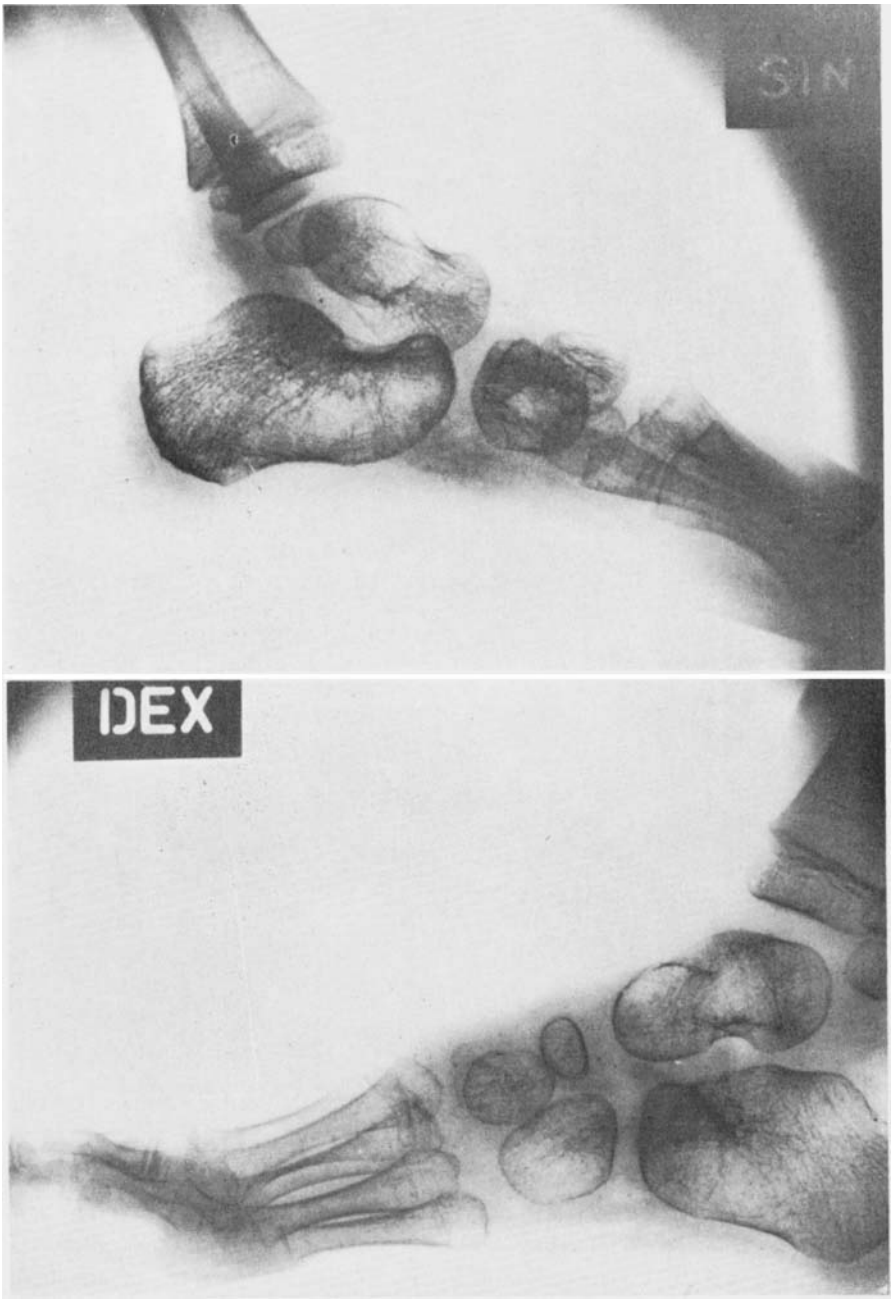

Figure 1 D. Preoperative roentgenograms.

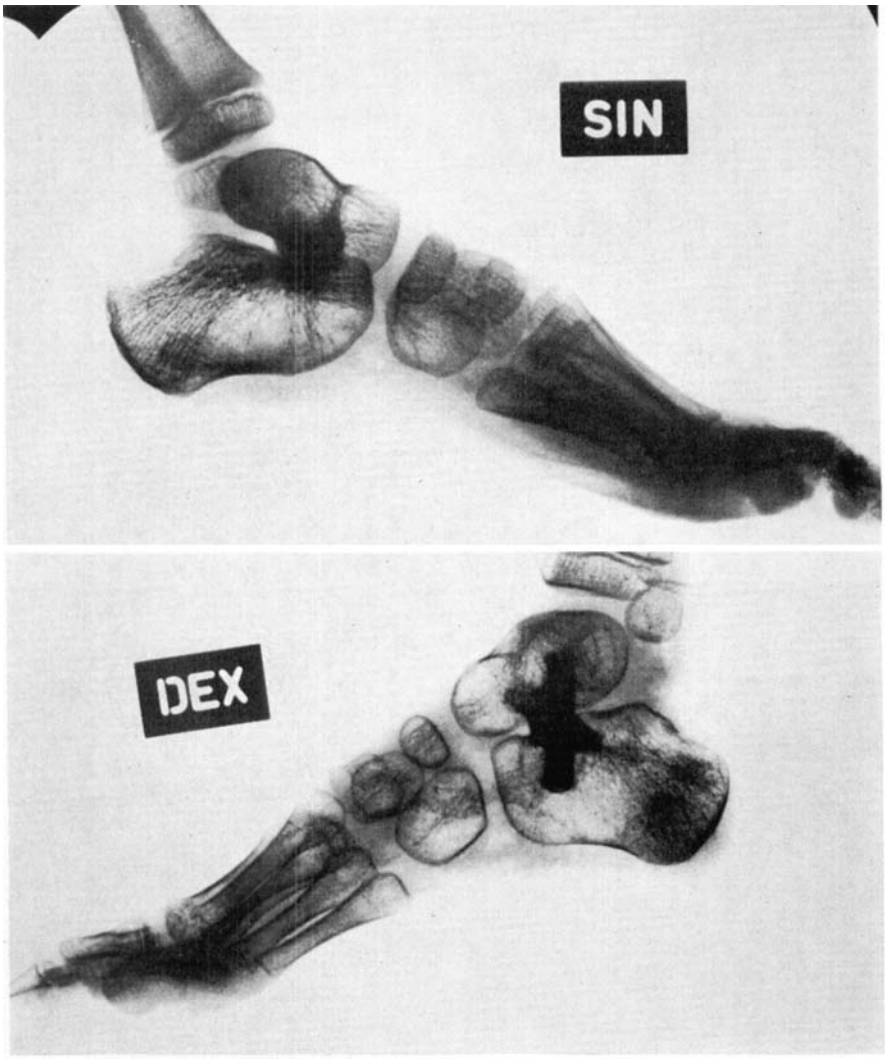

Figure 1 E. Roentgenograms twelve months postoperatively.

small in size. The growth and formation of the talus and calcaneus was decisively affected by the paralysis of the triceps surae. When this muscle, or the muscles transposed to replace it, were weak, a calcaneus deformity, which Grice arthrodesis was unable to prevent, often developed gradually in the course of years. On the other hand, provided the triceps surae muscle functioned well in a foot otherwise, perhaps,

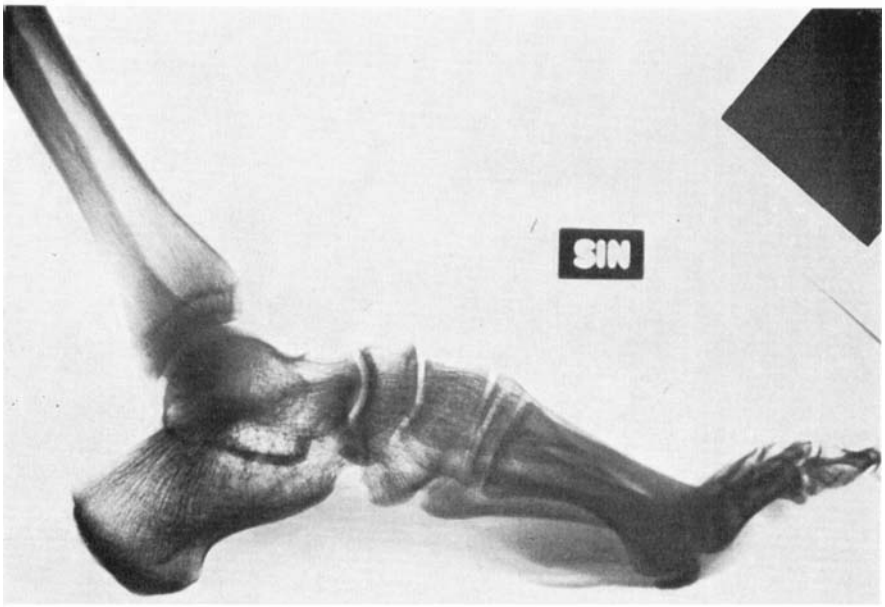
SIN

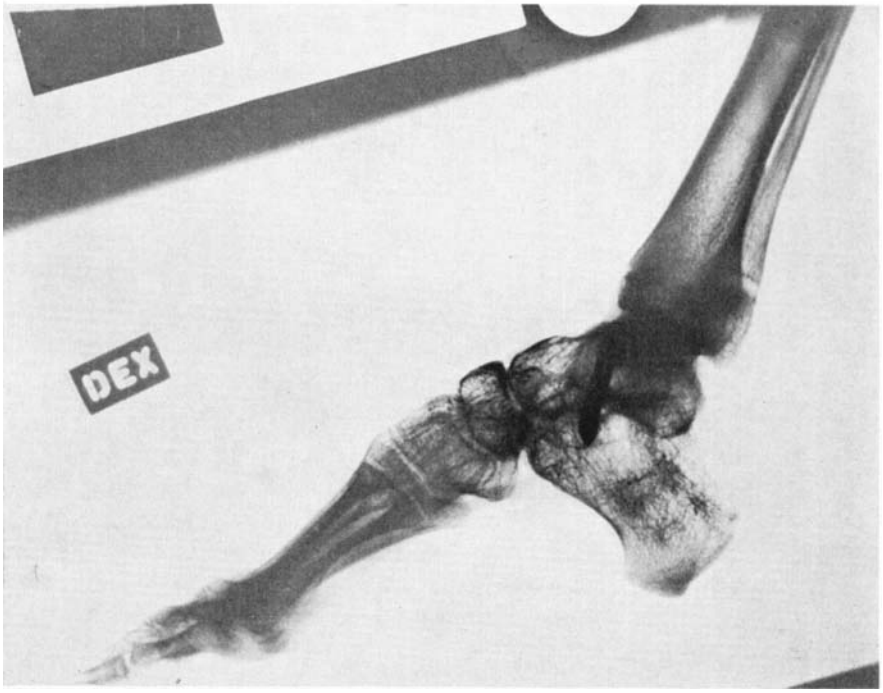
DEX

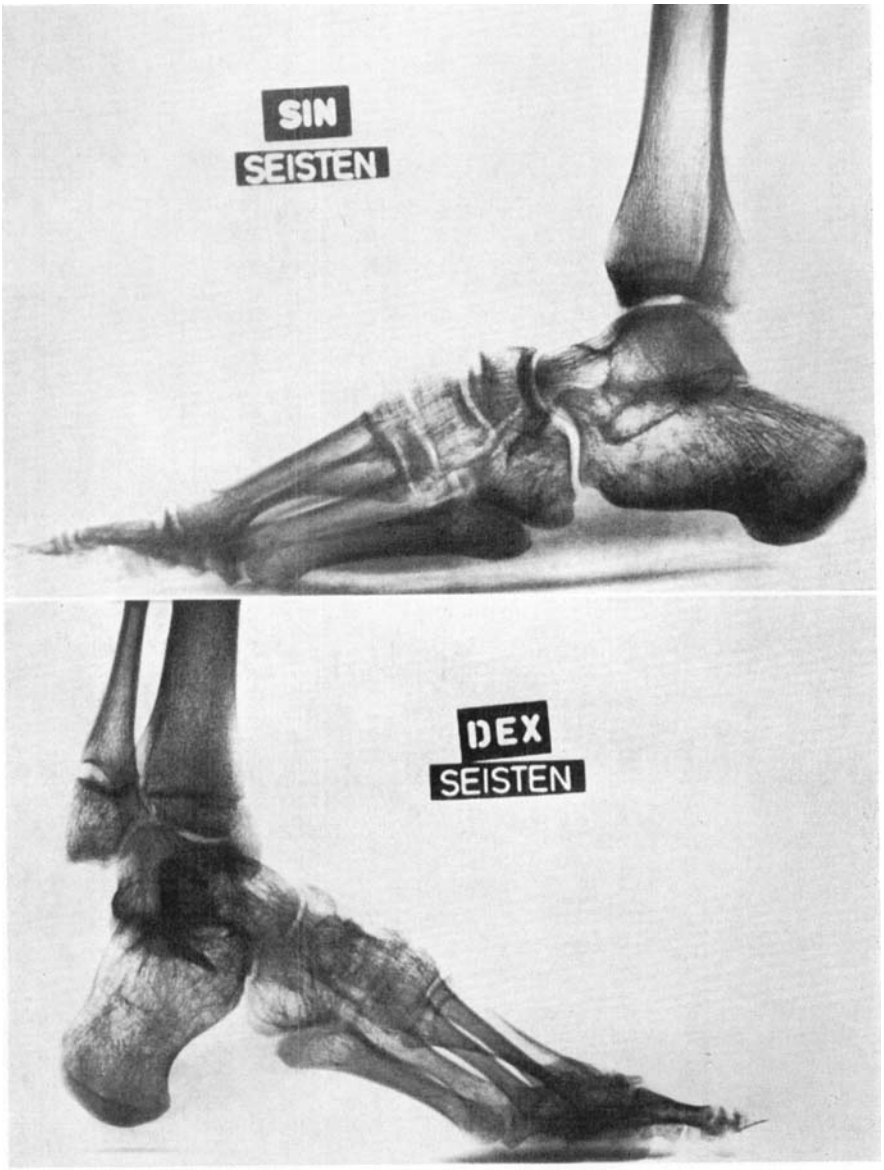

Figure 1 F. Roentgenograms twelve years postoperatively, in supine and standing positions (standing = seisten).

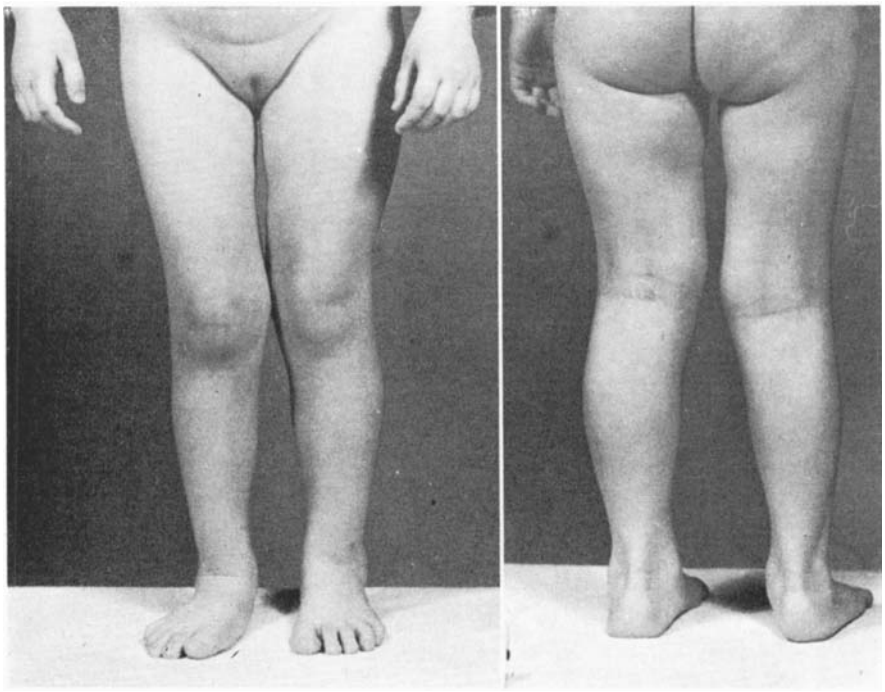

Figure 2 A. The patient was a four-year old girl who had had poliomyelitis at the age of six months. Preoperative back and front views showing planovalgus deformity on the right side.

even severely paralysed, the calcaneus and talus developed to a normal appearance during the years of growth.

The muscles attached to the more distal bones of the ankle and the metatarsus affected the position and formation of these bones during the period of growth. It should be particularly noted that Grice arthrodesis only corrected the valgus and varus deformities of the ankle, whereas the correction of the planus deformity depended, for the most part, on the strength of the muscles and the stability of the ligaments affecting the distal side of the subtalar joint.

The ligaments of the talocrural joint might be assumed to have become overstretched in the paralysed lower limbs, since pre- and even postoperatively the lower limb, in addition to ankle deformity, may have been affected e.g. by deformities in rotation and knee position. Postoperatively the inversion and eversion forces and strain of the paralysed ankle, without the movement of the subtalar joint, af-

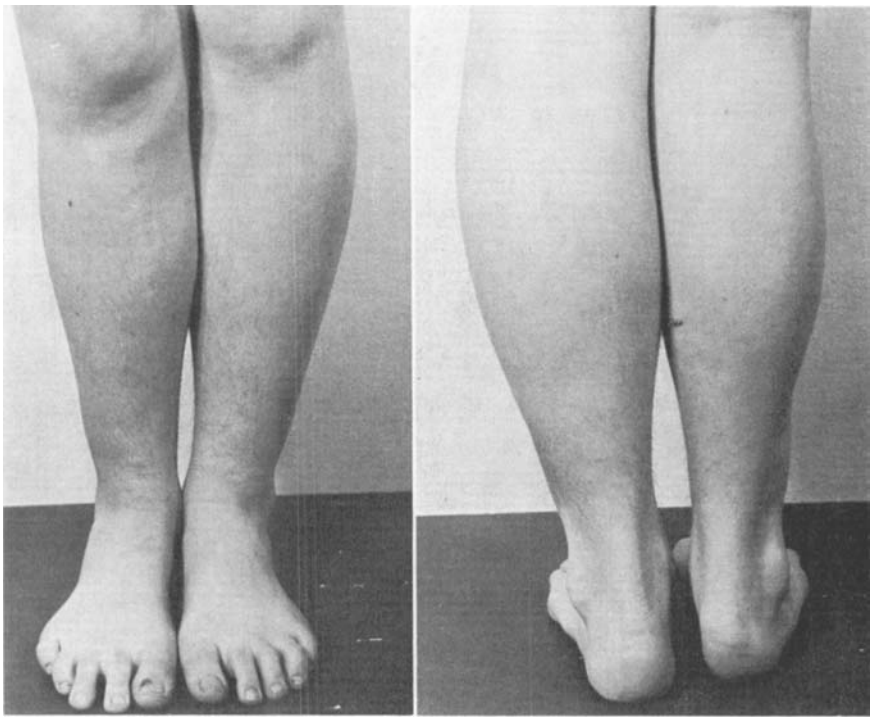

Figure 2 B. Back and front views twelve years postoperatively when the girl was seventeen years old. The result on the right side, after the usual Grice operation and the transfer of fibulares to dorsum pedis is good.

fect the talocrural joint. Furthermore, paralysed patients are more susceptible to accidents than are healthy subjects. However, in none of these ankles were the ligaments of the talocrural joint seen to become so slack as to require treatment. Only a few instances of minor overstretching were noted. Apparently the muscular balance could be relatively well taken care of by means of intraoperative tendon transpositions. In fact, the ligaments of the talocrural joint, ligamentum deltoides in the valgus ankles, and the lateral ligaments in the varus ankles proved to be able to withstand considerable strain. For this reason the ankles could really be stabilized vis-à-vis the inversion-eversion movements by means of the arthrodesis of the subtalar joint.

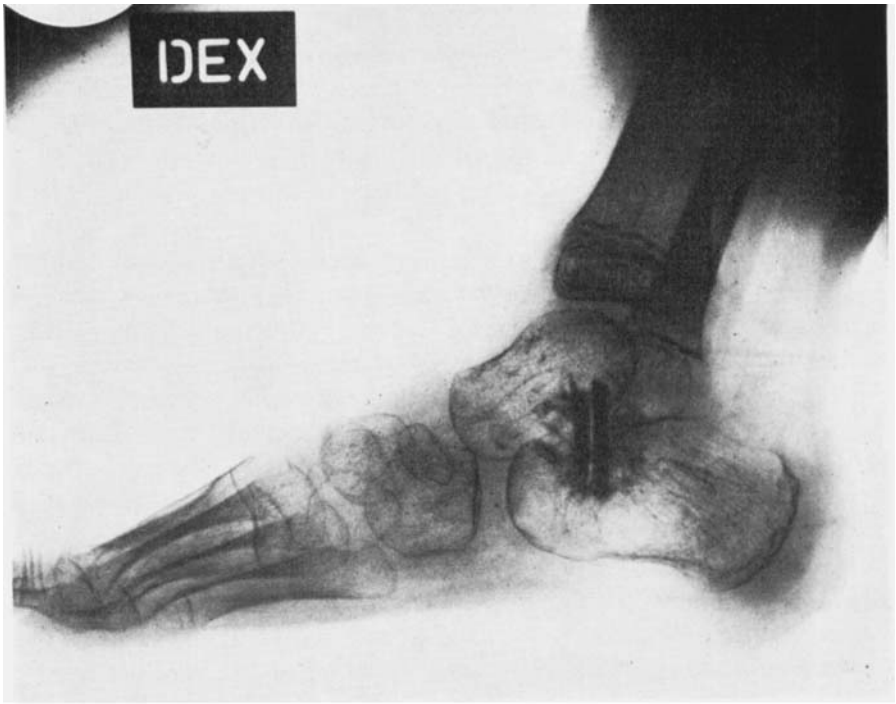
DEX

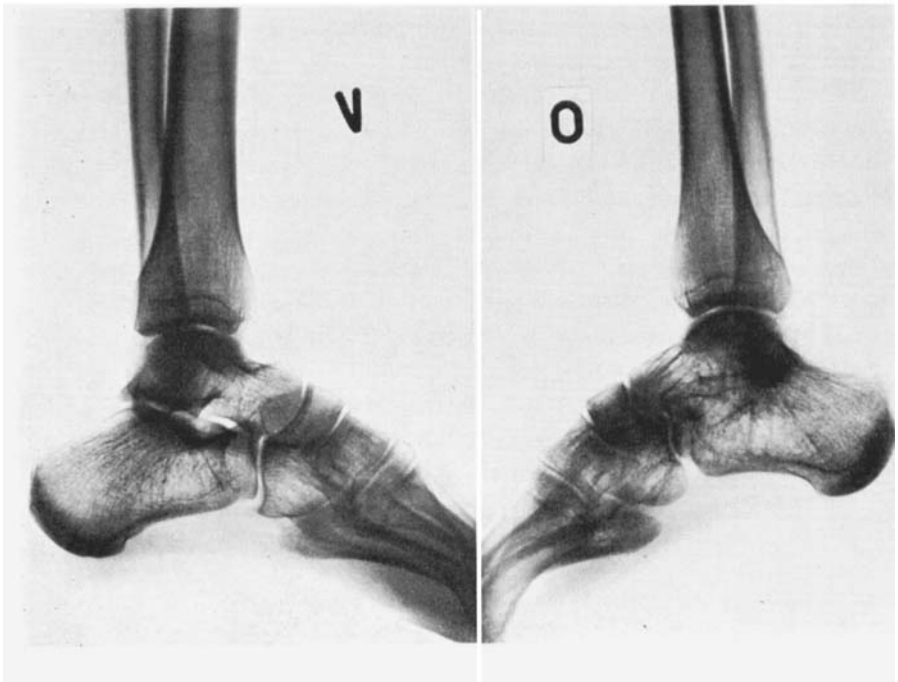
V
O

DISCUSSION

The follow-up period of the present material of 162 corrective extra-articular subtalar fusions averaged nine years and was therefore markedly longer than in earlier reports. At the follow-up examination two-thirds of the patients were past, or almost past, the period of growth, and the position of their ankles can therefore be considered as final.

Pollock & Carrel (1964) are among those who claimed that the longer the period of observation, the higher the frequency of poor results. In the present study, also, the early and late results differed considerably. The late follow-up did show considerably more poor results than the early follow-up. In valgus ankles the poor late results were mainly due to the gradual development of overcorrection with concomitant varus deformity. For the varus ankles the early results were usually good, but in most cases the varus deformity returned in the course of time.

The observation period for the early results was only six months. The operated ankles remained in plaster cast for twelve weeks of this period. Expecially the muscles used for tendon transfers require time for recovery after removal of the plaster cast. *For this reason the early results may be considered mainly to show the degree of correction produced by the extra-articular fusion, whereas in the late results the dynamic balance is the decisive factor.*

Not knowing the basis of the various materials, it is difficult to compare the results. Even in comparisons within one material it should be noted that e.g. tendon transfers are made when dynamic balance in inversion and eversion is poor. Furthermore, e.g. the weakness or absence of dorsiflexion or plantar flexion in the ankle may make tendon transfers necessary. *The results of the original Grice operation and one combined with tendon transfers must therefore be compared with caution, bearing in mind the original ankle deformities and dynamic balances.*

When valgus deformities are corrected by *tendon transfer alone,* the gradual development of overcorrection is a risk to be considered. For example, Fried & Hendel (1957), in their study of paralysed valgus

---

← *Figure 2 C. Roentgenogram six weeks postoperatively.*

Figure 2 D. Roentgenograms of the operated and healthy ankle twelve years postoperatively. The entire subtalar joint has fused.

ankles found that replacement of the paralysed tibialis posterior muscle with the two peronei easily led to overcorrection, a varus deformity. They therefore rejected this tendon transfer. Hagelstam (1957) was satisfied with peroneal transfers in the ankles of polio patients. However, in many cases a slight valgus deformity still remained. Six of 105 peroneal transfers in Hagelstam's material gradually led to overcorrection and varus deformity.

Grice (1959), on the basis of a five-year follow-up, uttered a word of warning. Transfer of both peroneal tendons in a combined Grice operation to the medial side of the dorsum pedis anteriorly beneath the spring ligament into the naviculare should only be used in severe valgus deformities, because the follow-up study had shown that some of the feet with this type of transfer had developed late varus complications. In 108 of the 112 Grice operations reported by Pollock & Carrel, both peroneal muscles were transferred. The result was poor in 37.5 per cent of all ankles. The most common complication in this material of paralysed valgus ankles (108 by poliomyelitis and 4 by spina bifida), after an average follow-up period of 2.6 years, was a late varus deformity. It was therefore concluded that even in severe invertor-evertor imbalance, *only one peroneal tendon* should be transferred. From the present material it seems that transfer of both peroneal tendons to the calcaneus is not nearly so risky for the position of the ankle as their transfer to the dorsum pedis. If in a severely paralysed valgus ankle the plantar flexion force of the foot is not existent, the transfer of both peroneal tendons to the calcaneus is the method of choice, provided the dynamic balance is maintained and the force of inversion reduced if required. But if the transfer is to the dorsum pedis, only one of the peroneal tendons should be transferred.

As for operative technique (Ingram 1963), it should be emphasized that the position of the ankle must first be corrected, and not until then should bone grafts be placed firmly in position to stabilize the talocalcaneal joint. The bone grafts were placed in position by the method described by Grice, so that they would stop the calcaneus from sliding lateroposteriorly to the talus. In the varus ankles the bone grafts should have the opposite tilt to prevent the calcaneus from moving anteromedially to the talus. When correcting the deformity of the talocalcaneal joint in both valgus and varus ankles, the objective is also to bring the talonavicular and calcaneocuboid joints to normal positions, these joints constituting a functional unit. It cannot be denied that the stress on the latter two increases after talocalcaneal

fusion. Grice (1959) said, however, that inasmuch as a more normal alignment is obtained by this procedure, there appears to be less change in the talonavicular joint than was previously observed in untreated, flexible, valgus deformities. Few patients of the present series complained of tired feet and only a couple of them of a slight pain. The arthrotic changes sometimes seen roentgenologically in the talonavicular, calcaneocuboid, and cuneonavicular joints were very mild. The follow-up period is too short and the patients too young for the examination of these late changes in adjacent articulations. Apparently, with the stress of work and increased body weight the ankles in which the final degree of correction was poor, or satisfactory, may later gradually develop arthrosis, and a triple arthrodesis is indicated.

The present series was heterogeneous as far as the underlying disease was concerned, but in different types of paralysis the ankles show a similar dynamic imbalance. The corrections of the dynamic balance required in addition to the corrective subtalar fusion proved to be a difficult problem. It is absolutely indispensable to keep the postoperative position of the ankle under continuous observation, at least as long as the child is growing. If the operation is to be used extensively for the treatment of static planovalgus, the simultaneous tendon transfers, e.g. the recommended transfer of the peroneus brevis to the dorsum of the foot (Lange 1968), should be taken with a certain reserve. Only the more flagrant deformities should be treated, since there is the risk of a gradual overcorrection to varus deformity.

SUMMARY

The subtalar extra-articular fusions performed at the Orthopaedic Hospital of the Invalid Foundation from 1956 to 1969 were reviewed. 141 ankles were operated on for poliomyelitis and 21 for other diseases.

Valgus deformity was the cause of 134 and varus deformity of 28 operations. The original technique described by Grice was always used to correct the valgus deformity. Varus deformity was corrected by using a modification developed by A. Langenskiöld, in addition to the usual method.

The patients' ages ranged from 3 to 16 years; only 9 children were 11 or older. The follow-up periods ranged from just under a year to 12 years, average 9 years. At the time of the follow-up nearly two-thirds of the treated ankles were completely or almost completely full-grown.

The early results, which became manifest during the first six months, and the late results differed considerably. The late follow-up examination did show considerably more poor results than the early follow-up examination. In valgus ankles the poor late results were mainly due to the gradual development of overcorrection with concomitant varus deformity. For the varus ankles the early results usually were good, but in most cases the varus deformity returned in the course of time.

Tendon transfers were carried out intraoperatively. From the present material it seems that *transfer of both peroneal tendons to the calcaneus is not nearly so risky for the position of the ankles as their transfer to the dorsum pedis.* If the transfer is to the dorsum pedis, only one of the peroneal tendons should be transferred, to avoid overcorrection.

The Grice operation is excellent and in most cases a definitive procedure for the valgus deformity. The varus ankles were refractory to treatment. Good and satisfactory late results were obtained in half of all varus ankles, but also in poor late results the alignment of tarsal bones was better during the growth period, and thereafter it was easier to perform the corrective triple arthrodesis. The principal and most important thing is to keep the deformity of the growing ankle under observation through the whole growth period. Without this, it is impossible to avoid late complications, over- or undercorrection. It is particularly important to make every effort to prevent the late varus deformity.

REFERENCES

Baker, L. D. & Dodelin, R. A. (1958) Extra-articular arthrodesis of the subtalar joint (Grice procedure). Results in seventeen patients with cerebral palsy. *J. Amer. med. Ass.* **168**, 1005–1008.

Baker, L. D. & Hill, L. M. (1964) Foot alignment in the cerebral palsy patient. *J. Bone Jt Surg.* **46**-A, 1–15.

Brown, F. W. (1963) Orthopaedic surgery in the mentally retarded. *J. Bone Jt Surg.* **45**-A, 841–853.

Fried, A. & Hendel, C. (1957) Paralytic valgus deformity of the ankle. Replacement of the paralyzed tibialis posterior by the peroneus longus. *J. Bone Jt Surg.* **39**-A, 921–932.

Friedman, M. S. (1965) Subtalar bone block for pes plano-valgus. *J. Bone Jt Surg.* **47**-A, 1087–1088.

Grice, D. S. (1952) An extra-articular arthrodesis of the subtalar joint for correction of paralytic flat feet in children. *J. Bone Jt Surg.* **34**-A, 927–940.

Grice, D. S. (1955) Further experience with extra-articular arthrodesis of the subtalar joint. *J. Bone Jt Surg.* **37**-A, 246–259.

Grice, D. S. (1959) The role of subtalar fusion in treatment of valgus deformities of the feet. *Instructional course lectures, The American Academy of Orthopaedic Surgeons,* vol. 16, pp. 127–150. The C. V. Mosby Co., St. Louis.

Hagelstam, L. (1957) Muscle and tendon transposition in the lower limb in poliomyelitis. *Acta orthop. scand.* **27**, 49–63.

Haraldsson, S. (1965) Pes plano-valgus staticus juvenilis and its operative treatment. *Acta orthop. scand.* **35**, 234–256.

Herold, H. Z., de Leon Falewski, G., Fried, A. & Torok, G. (1965) Extra-articular subtalar arthrodesis of Grice. *J. Bone Jt Surg.* **47**-B, 199.

Hunt, J. C. & Brooks, A. L. (1965) Subtalar extra-articular arthrodesis for correction of paralytic valgus deformity of the foot. Evaluation of forty-four procedures with particular references to associated tendon transference. *J. Bone Jt Surg.* **47**-A, 1310–1314.

Ingram, A. J. (1963) Anterior poliomyelitis. Extra-articular arthrodesis of subtalar joint for talipes equinovalgus. *Campbell's operative orthopaedics,* 4th ed., vol. 2, pp. 1390–1392. The C. V. Mosby Co., St. Louis.

Lange, M. (1968) Operation von Green-Grice für die Behandlung paralytischer Plattfussdeformitäten. *Orthopädische Operationslehre. Ergängzungsband: Neueste Operationsverfahren,* pp. 226–228. J. F. Bergmann Verlag, München.

Langenskiöld, A. Personal communication.

Malvarez, O. (1957) Artrodesis subastragalina extraarticular en el pie valgo pronado paralitico. Artrodesis minima. Estudio de 87 casos. *Rev. Orthop. Traum. (B. Aires)* **2**, 251–259.

Peabody, C. W. (1938) Tendon Transposition. An end-result study. *J. Bone Jt Surg.* **20**, 193–2005.

Picard, J. J. & Mimran, R. (1961) Opération de Grice. *Rev. Chir. orthop.* **47**, 590–597.

Pollock, J. H. & Carrell, B. (1964) Subtalar extra-articular arthrodesis in the treatment of paralytic valgus deformities. A review of 112 procedures in 100 patients. *J. Bone Jt Surg.* **46**-A, 533–541.

Schneider, F. R. & Westin, G. W. (1963) Subtalar extra-articular arthrodesis: six-year follow-up post-polio paralytic foot. *J. Bone Jt Surg.* **45**-A, 653.

Thomas, F. N. (1967) Arthrodesis of the subtalar joint. *J. Bone Jt Surg.* **49**-B, 93–97.

Weissman, S. L., Torok, G. & Kharmosh, O. (1957) L'arthrodése extraarticulaire avec transplantation tendineuse concomitante dans de traitement du pied plat valgus paralytique du jeune enfant. *Rev. Chir. orthop.* **43**, 79–95.

Westin, G. W. & Hall, C. B. (1957) Subtalar extra-articular arthrodesis. *J. Bone Jt Surg.* **39**-A, 501–512.

Zachariae, L. (1963) The Grice operation for paralytic flat feet in children. *Acta orthop. scand.* **33**, 80–90.

Correspondence to:

Uolevi Lahrenta & Pauli Pylkkänen
Invalidisäätiön Ortopedinen sairaala
Tenholantie 10
Helsinki, Finland