

Orthopedic Hospital, Copenhagen, Denmark.

**AMPUTATIONS WITH AND WITHOUT MYOPLASTY  
ON RABBITS WITH SPECIAL  
REFERENCE TO THE VASCULARIZATION**

*(Paper read in Dansk Ortopædisk Selskab on April 30th, 1971)*

**CHR. HANSEN-LETH & I. REIMANN**

Accepted 27.x.1971

Amputation involves vascular changes in the stump, in the soft tissues as well as in the bone. By means of myoplasty the circulation is increased through improved active muscle function; this applies to the arterial supply as well as to the venous return, as reported by Mondry (1952) and demonstrated by Dederich (1968) by means of angiography.

It is clinical experience that hypervascularization and tortuous vessels develop post-operatively, as among others Leriche (1950), Erikson (1965) and Langhagel (1968) have proved by angiography, but these investigations were not made until 3-4 weeks after the amputation.

On the basis of experimental studies, Hulth & Olerud (1962) also showed the occurrence of hypervascularization and tortuous vessels. Erikson & Olerud (1966) mention a primary decrease in the vascular diameters which, after a couple of days, is followed by a dilation; also frequent occurrence of spurs is observed in the stump.

The aim of the present study is to compare the essential changes occurring after amputation with myoplasty and without myoplasty, respectively. Growing rabbits were used for the experiments and it was thus possible also to study the effect of amputation on the growth of bone.

**EXPERIMENTS**

20 female rabbits, 3-4 months old, were used for the investigation. Amputation was performed on the right crus. In ten cases the amputa-

tion was performed with myoplasty, in ten other cases without myoplasty. The operations were performed under Nembutal anesthesia and sterile conditions.

In the myoplasty cases the muscles are joined in groups over the bone end by interrupted catgut sutures; in the cases without myoplasty the skin is sutured across the bone with interrupted nylon sutures.

In two cases without myoplasty (M 12, M 17) haematoma developed, and in one case with myoplasty (M 24) necrosis sicca occurred in the stump. No other complications were observed, especially no infections.

The rabbits were killed at intervals ranging from  $\frac{1}{2}$  to 10 weeks after amputation, after labelling with tetracycline (Reverin), 30 mg/kg body weight, twice at an interval of 3 days.

In connection with the killing, microangiography was performed according to a modification of the method of Trueta & Harrison (1953). Under Nembutal anaesthesia the peritoneum is opened and a cannula placed distally in aorta abdominalis. The animal, which is heparinized, is bled through the vena cava inferior. By perfusion with saline at 1 m pressure the remaining blood is washed out, and perfusion is continued with 25 per cent micropaq for approx. one hour, and then approx. ten minutes with micropaq with 10 per cent formaline. After removal of skin the hind part of the body is fixed in 10 per cent formaline. By macroscopical examination the amputation stumps were studied with regard to occurrence of infection, haematoma, or necrosis, and as to the result of the myoplasty. The bone in the stump is inspected with regard to the formation of spurs, and to possible closing (osseous or fibrous) of the medullary cavity.

Radiographs have been made of the macroscopic specimens with a view to the microangiographies performed, using X-rays from a Machlett A. E. G. X-ray tube (Carl Drenck). The pictures were taken at a distance of 40 cm; industry film Gevaert Structurix D 7 was used, exposure time 12 minutes at 19 m. Amp. and 19 Kv. For the evaluation the classification described by Erikson (1965) was used, taking into consideration the degree of vascular richness, the degree of dilation, presence of tortuous vessels and formation of spurs (see Table 1).

For the evaluation of the vascular changes in the bone, distal  $1\frac{1}{2}$  cm specimens of tibia were sawn off the amputation stumps; these specimens are decalcified, fixed in methyl metacrylate, ground down to approx. 2.5 mm thickness, photographed on a spectroscopy plate at a distance of 40 cm, exposure time 12 minutes, 19 m. Amp. and 40 Kv.

Table 1. Arteriographical findings.

Case no.	Operation	Time (week)	Vascular richness			Vascular width			Tortuous vessels	Spur
			(Calf)	(Thigh)	(In the distal end of the stump)	a. fem.	a. popl.	a.gen. supr.		
18	Amputation with myoplasty	½	2	1	2	2	2	÷1	1	1
1	—	1	3	1	1	3	2	1	1	1
24	—	1	3	÷1	1	1	÷1	÷1	1	1
26	—	1	2	÷1	2	3	2	1	1	1
4	—	2	2	1	2	1	2	1	1	1
5	—	3	2	1	2	1	2	1	1	3
23	—	4	1	1	1	1	2	1	1	1
20	—	6	1	1	1	1	÷1	1	2	1
3	—	7	1	÷1	1	1	1	1	2	3
2	—	10	1	÷1	2	1	÷1	1	1	2
22	Amputation without myoplasty	½	2	1	1	2	3	1	1	1
17	—	½	3	3	1	1	3	2	1	1
12	—	1	÷1	÷1	1	1	1	1	1	1
16	—	1	÷1	1	3	1	1	1	1	2
13	—	2	2	1	3	1	3	2	2	2
14	—	2	3	1	1	1	1	2	3	2
15	—	3	3	1	1	2	1	2	3	2
21	—	4	1	÷1	1	1	1	2	2	2
7	—	5½	1	1	1	1	÷1	2	2	3
9	—	8	1	2	1	1	÷1	2	1	2

Vascular richness: 1: Same as at the corresponding level of the intact leg. 2: Moderately increased. 3: Markedly increased.

Vascular width: 1: Same as at the corresponding level of the intact leg. 2: Moderate dilation. 3: Marked dilation. ÷1: Narrower as at the corresponding level of the intact leg.

Tortuous vessels: 1: No. 2: Moderate occurrence. 3: Abundant occurrence.

Spur: 1: No spur. 2: Small spur. 3: Marked spur.

Time: Interval from amputation to death of animal.

In 6 cases specimens were examined from the same level of the side not amputated.

The effect of the amputation on the growth factor is investigated by means of tetracycline labelling.

The proximal tibia ends from both sides are dissected out, imbedded in methyl metacrylate, ground down to a thickness of 50–60  $\mu$ ; on these microscopic specimens the interval is measured between fluorescent lines which correspond with the primary calcification at the time of labelling. The measurements made in a fluorescence microscope with an ocular (magnification  $8 \times 10$ ) are taken on undecalcified specimens, and in each single case 2–3 specimens were measured, as measurements from the same stump may vary up to 20 per cent.

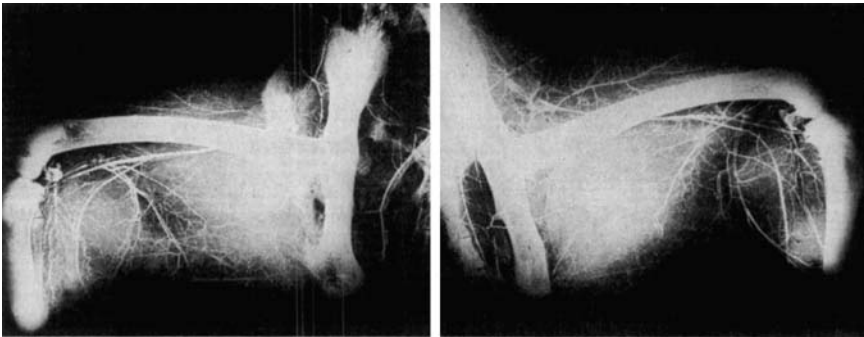## RESULTS

As it appears from Table 1, an increase in vascular richness is found in crus  $\frac{1}{2}$ –3 weeks after the amputation. In cases with myoplasty the vascular richness reaches maximum already one week after amputation, whereas in cases without myoplasty this maximum is not reached before 2–3 weeks after amputation. In the femur no increase in vascular richness is observed.

The degree of dilation is evaluated in the arteria femoralis, popliteal area, and the arteria genus suprema. Only moderate and transient dilation is seen and it takes place at the same time as the hypervascularization observed.

With regard to the presence of tortuous vessels, which is not a normal occurrence, it was found in only two of the cases with myoplasty and not until after the 6th week, whereas it was found to be almost constantly present in cases without myoplasty and then already after the second week. The origin of tortuous vessels is not elucidated; it may be a case of neoformation or of changes in the existing vessels. The tissue trauma may be followed by an arterial dilation and partial occlusion, but this is not consistent with tortuous vessels being present only in some cases.

Besides, metabolic conditions in the tissue and its need for circulation, or the extent of nerve control in the smooth musculature may also play a part. Erikson (1965) found by clinical studies a clear correlation between the development of tortuous vessels, hypervascularization, stump pains, and necrosis. From the table it also appears that development of spurs is discovered in 4 of the cases with myoplasty and in 7 cases without myoplasty. According to Erikson & Olerud (1966), the formation of spurs is a consequence of haematoma in the stump, whereas Dederich (1970) finds invariably a vascular bundle



*Figure 1. Radiograph from case 14, angiography 2 weeks after amputation without vessels, and small formation of spur (the amputated side is seen at left, the unamputated at right).*

directed towards the spur and believes that it is secondary to ligature vessels which are fixed by suture to periost.

Figure 1 shows angiographies performed 2 weeks after amputation without myoplasty, distinct hypervascularization, presence of tortuous vessels and of a small spur.

The vascular changes in the bone are seen in Table 2.

In the bone a hypervascularization and moderate dilation are seen corresponding to the vascular state of the soft tissues. As regards tortuous vessels, these are already noted 4 days after the amputation and observed in approximately half of the number of cases.

Furthermore, in the 6 cases in which we had specimens from the normal side for comparison, a pronounced hypervascularization is found in the amputated bone.

In 5 of the cases a decrease in the diameter of the arteries is noted, and only in one case is increased dilation observed six weeks after amputation.

Figure 2 shows cases of amputation with myoplasty 6 weeks after amputation.

The effect of the amputation on the growth by means of tetracycline labelling is calculated as the difference between the growth rate in the amputated side and the unamputated side, expressed in percentage of the growth rate of the unamputated side. The growth in the unamputated side may vary from one animal to the other, but by this method of calculation it has no influence on the resulting measurements. The results are illustrated in the diagram Figure 3. This dia-

Table 2. Microangiographic findings in the bone stump.

Case no.	Operation	Time (week)	Vascular richness	Tortuous vessels
M 18	Amputation with myoplasty	$\frac{1}{2}$	3	2
M 1	—	1	2	2
M 24	—	1	3	2
M 4	—	2	1	1
M 5	—	3	2	2
M 23	—	4 $\frac{1}{2}$	3	2
M 20	—	6	3	2
M 3	—	7	2	1
M 2	—	10	2	2
M 22	Amputation without myoplasty	$\frac{1}{2}$	2	1
M 17	—	$\frac{1}{2}$	3	2
M 12	—	1	3	2
M 16	—	1	2	1
M 13	—	2	2	1
M 14	—	2	3	2
M 15	—	3	3	1
M 21	—	4	3	1
M 7	—	5 $\frac{1}{2}$	2	1
M 9	—	8	1	1

## Vascular richness:

1: No.

2: Moderately increased.

3: Markedly increased.

## Tortuous vessels:

1: No.

2: Moderate occurrence.

3: Abundant.

Time: Interval from amputation to death of animal.

gram shows a marked increase in growth starting within the first week after amputation and reaching a maximum between the 2nd and 3rd week, then reaching the same level as the unamputated about the 4th week. The lower curves in the Figure give a graphical representation of the hypervascularization in crus, and it is seen that maximum of growth acceleration and hypervascularization coincide.

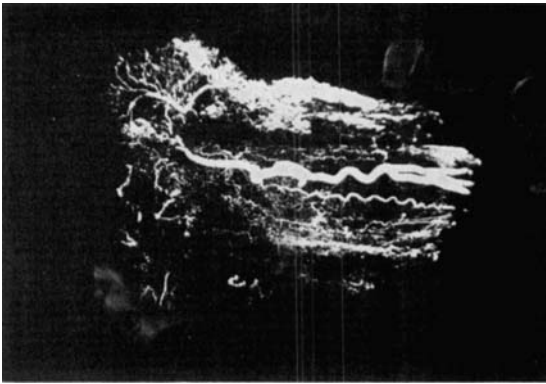


Figure 2. Illustrates bone angiography from case 20, six weeks after amputation with myoplasty. Shows pronounced hypervascularization, dilation, and presence of tortuous vessels.

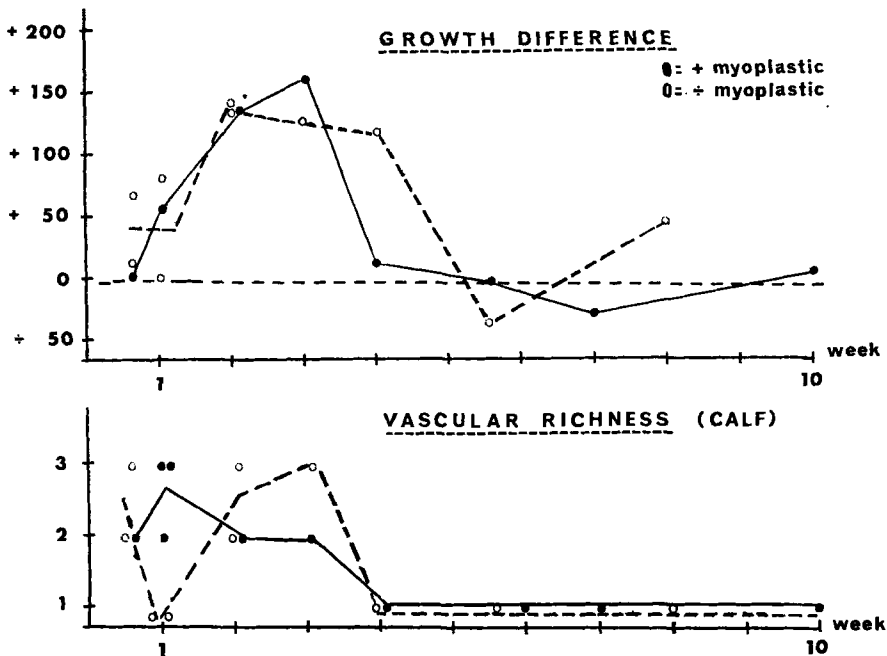
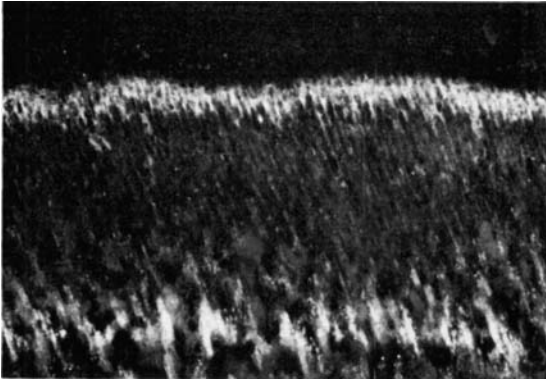


Figure 3. Growth stimulation and hypervascularization in crus immediately after amputation.

Figure 4 shows an example of a fluorescence picture of a case one week after amputation. In Figure 5 a counterpart from the unamputated side of the same animal is seen.

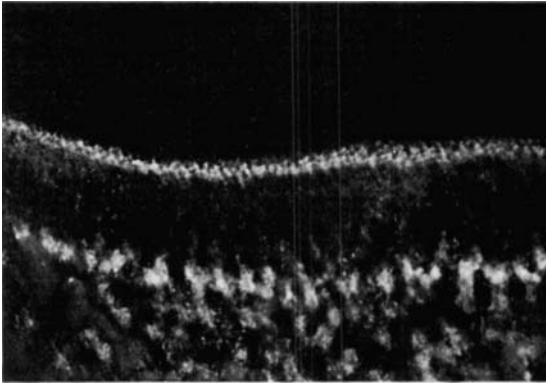


*Figure 4. Fluorescence photo of 50  $\mu$  thick non-decalcified specimen from proximal tibia of amputated side from case 24.*

#### DISCUSSION

In connection with amputation, pronounced changes are observed in the vascularization, as hypervascularization in soft tissues as well as in bone, a transient dilation, and development of tortuous vessels and formation of spurs are proved. Erikson & Olerud (1966), by means of angiographies performed on live rabbits, found a constriction of arteries and veins immediately after amputation, which may be explained by a reflectorically provoked spasm. It is also possible that oedema or haematoma play a part. From the second to the third day they observed a dilation, continuing to the fourth week as a maximum; there are cases, however, where the dilation continues till after the fourth month, but this is not consistent with the findings in the present material where, as mentioned, dilation has been only moderate and takes place parallel with the hypervascularization. As regards hypervascularization and rate dilation, the present study disclosed no evident difference between cases with and without myoplasty.

Hulth & Olerud (1962) regard the presence of tortuous vessels as an indication of vascular neof ormation; Hasse (1960) believes that change of pressure may be the explanation. Erikson & Hulth (1962), on the basis of a clinical material, mention that it is especially in patients with pains or necrosis in the amputation stump that tortuous vessels are observed. Erikson (1965), likewise on the basis of a clinical material, has found development of tortuous vessels in amputation stumps (without myoplasty) in 1/3 of the cases. In the present study a marked increase in the incidence of tortuous vessels was noted in cases where myoplasty has not been performed. Correspondingly, Erikson & Olerud (1966) report that the tortuous vessels are observed



*Figure 5. Fluorescence photo of 50  $\mu$  thick non-decalcified specimen from comparison side of same animal as in Figure 4.*

after some weeks and simultaneously with hypervascularization reaching its maximum.

Also in the present study the formation of spurs is found to have increased appreciably in cases where myoplasty was not performed, and as mentioned by Erikson & Olerud (1966), this may be explained by haematoma being a possible cause.

Langhagel (1968) describes the effect of myoplasty on the early closing of the medullary cavity. In this study macroscopic investigation disclosed fibrous or osseous closing apart from 4 cases which had all been investigated within one week after amputation. Of these 4 cases one was with myoplasty, the remaining 3 without myoplasty.

#### S U M M A R Y

Vascular changes occurring after crus amputation are investigated in 20 rabbits 3 months old, half with myoplasty and half without myoplasty. Microangiographies were performed at time intervals ranging from  $\frac{1}{2}$  to 10 weeks after amputation.

The investigations showed that hypervascularization occurs in the crus stump, in the soft tissues as well as in the bone, and also a moderate transient dilation. No certain difference is proved between cases without myoplasty and cases with myoplasty. The development of tortuous vessels and the formation of spurs is found to have increased appreciably in cases without myoplasty. By means of tetracycline labelling a clear growth acceleration is observed in the amputated side. The acceleration takes place parallel with the hypervascularization.

## REFERENCES

- Dederich, Rolf (1970) *Amputationen der unteren Extremität. Technische Orthopädie.* Georg Thieme Verlag, Stuttgart.
- Erikson, Uno (1965) Circulation in traumatic amputation stumps. *Acta radiol. (Stockh.)*, Suppl. 238.
- Erikson, Uno & Hulth, Anders (1962) Circulation of amputation stumps (arteriographic and skin temperature studies). *Acta orthop. scand.* **32**, 159-170.
- Erikson, Uno & Olerud, Sven (1966) Healing of amputation stumps, with special reference to vascularity and bone. *Acta orthop. scand.* **37**, 20-28.
- Hasse, H. M., Rau, G. & Schoop, W. (1963) Angiographische befunde an amputationsstumpfen. *Z. Kreis.-Forsch.* **49**, 326-330.
- Hedström, Östen (1969) Growth stimulation of long bones after fracture or simular trauma. A clinical and experimental study. *Acta orthop. scand.* Suppl. 122.
- Hulth, Anders & Olerud, Sven (1962) Studies on amputation stumps in rabbits. *J. Bone Jt Surg.* **44-B**, 431-435.
- Langhagel, Joachim (1968) *Angiographische Untersuchungen der Stumpsdurchblutung bei Beinamputierten unter besonderer Berücksichtigung osteo- und myoplastischer Stumpfkorrekturen, Arbeit und Gesundheit.* Georg Thieme Verlag, Stuttgart.
- Leriche, R. (1950) Étude critique des mécanismes de la douleur chez es amputés: nouvelles orientations de son traitement. *J. Chir.* **66**, 5.
- Mondry, F. (1952) Der muskelkräftige Ober- und Unterschenkelstumpf. *Chirurg* **23**, 517-519.
- Sundén, Göran (1967) Some aspects of longitudinal bone growth. *Acta orthop. scand.* Suppl. 103.
- Trueta, J. & Harrison, M. H. M. (1953) The normal vascular anatomy of the femoral head in adult man. *J. Bone Jt Surg.* **35-B**, 442-461.

Correspondence to :

Dr. Chr. Hansen-Leth  
Orthopaedic Hospital  
Hans Knudsens Plads  
2100 Copenhagen Ø.  
Denmark