

Orthopaedic Unit, Randers Central Hospital, Randers, Denmark

A CASE OF CARPAL TUNNEL SYNDROME ON THE BASIS OF AN ABNORMALLY LONG LUMBRICAL MUSCLE

JØRGEN ERIKSEN

Accepted 12.i.73

The carpal tunnel syndrome is defined as sensory and motor symptoms from the median nerve according to its distribution area distal to the wrist joint (Rasmussen & Stougård 1969). The symptoms are caused by a compression of the nerve in its passage through the carpal tunnel. The causes of this compression can, according to Entin (1968), be divided into the following groups: (1) diminution of the volume of the carpal tunnel, (2) increase in the volume of the structures which together with the median nerve pass through the carpal tunnel, (3) accompanying symptom in a systemic disease. Included in the above-mentioned groups (1) and (2) are the rare cases of carpal tunnel syndrome caused by anatomical variants.

In our unit we have recently observed a case of a rare anatomical variant in connection with an operation for carpal tunnel syndrome.

CASE HISTORY

A 31-year-old worker who for six years had suffered from pains in the right wrist joint radiating down to the right hand and up the lower arm. When admitted to hospital the patient complained of paraesthesiae in the entire right hand, not especially limited to the median area, and also of lack of strength in the right hand and lower arm. On examination tenderness was observed over the right median nerve at the flexor retinaculum and also over the nerve in the lower arm. There was furthermore clear diminution of strength in the wrist joint and elbow joint on the affected side. An x-ray of the forearm and hand showed nothing abnormal. At operation an anatomical variant was discovered, as the lumbrical muscle from the profundus tendon to the third finger arose more proximal than usual on the tendon (Figure 1).

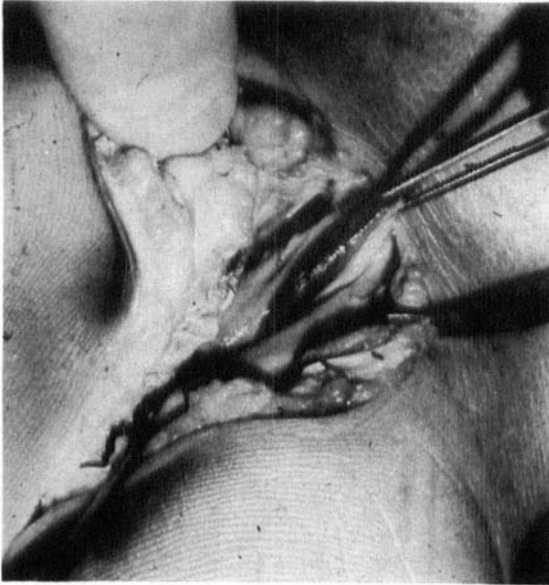


Figure 1. The forceps are gripping the lumbrical muscle from the profundus tendon to the third finger. The small artery forceps are located proximally on the radial side of the severed flexor retinaculum. Between these can be seen the median nerve.

When the hand was in a position of rest the origin lay proximal to the upper edge of the flexor retinaculum. There was no visible compression of the median nerve, but the above-mentioned abnormality could cause compression of the nerve during exercise.

DISCUSSION

In the literature only very few cases of carpal tunnel syndrome on the basis of anatomical variants have been described. In Phalen's comprehensive material of 1966 relating to 654 patients operated for carpal tunnel syndrome, none was found with the above-mentioned aetiology. This can, as he states himself, be due to the method of operation, as most of these patients were operated on through a transverse incision in the palm, and this gives a poor visual survey. In the material of Rasmussen & Stougård (1969) it was found that among 91 operated cases only a single one was caused by an anatomical variant. In this abnormally long muscle bellies to the sublimis tendons were found. This variant has also been described by Tanzer (1969), Robbins (1963) and Bunnel (1964).

Only once before has an abnormally proximal origin of the lumbrical muscles been described as the cause of carpal tunnel syndrome (Touborg-Jensen 1970).

SUMMARY

A case is reported of carpal tunnel syndrome due to an anatomical variant in the form of an abnormally proximal origin of a lumbrical muscle.

REFERENCES

- Bunnel, S. (1964) Nerves. *Surgery of the hand*. J. B. Lippincott Co., Philadelphia.
- Entin, M. A. (1968) Carpal tunnel syndrome and its variants. *Surg. Clin. N. Amer.* **148**, 1097.
- Phalen, G. S. (1966) The carpal tunnel syndrome. *J. Bone Jt Surg.* **48-A**, 211.
- Rasmussen, J. & Stougård, J. (1969) Karpaltunnelsyndrom. *Nord. Med.* **81**, 366.
- Robbins, H. (1963) Anatomical study of the median nerve in the carpal tunnel and etiologies of the carpal tunnel syndrome. *J. Bone Jt Surg.* **45-A**, 953.
- Tanzer, R. C. (1959) The carpal tunnel syndrome. *J. Bone Jt Surg.* **41-A**, 626.
- Touborg-Jensen, A. (1970) Carpal tunnel syndrome caused by an abnormal distribution of the lumbrical muscles. *Scand. J. Plast. Reconstr. Surg.* **4**, 72.

Correspondence to:

Jørgen Eriksen
Lavendelvej 10
7400 Herning
Denmark