

The Robert Jones and Agnes Hunt Orthopaedic Hospital,
Oswestry, England.

THE FIXATION OF EXPERIMENTAL FEMORAL SHAFT TORQUE FRACTURES

M. J. S. HUBBARD

Accepted 9.x.72

Spiral fracture of the shaft of the femur often occur in the elderly and their internal fixation presents a difficult problem (Roberts 1962). The following experiments show how spiral fractures may be produced by torque in the cadaver and how different methods of internal fixation withstand torque stress.

METHODS

Twenty fresh cadaveric femora were subjected to 4 consecutive tests each.

1. *Breaking Torque*: The femur was held in the specially moulded vice of the "Avery" torque testing machine by the middle and upper thirds so that 15.0 cm of shaft remained free between the distal edge of the vice clamp and the adductor tubercle. The other torque vice of the machine was then applied to the intercondylar areas anteriorly and posteriorly and tightened. This position of the torque vice clamp was chosen so that the length of the fracture would not exceed 10 cm. Above this length plating would have been difficult (Figure 1).

A torque moment was then applied and the minimum torque generated to break the femur was recorded from the torque testing machine graph.

The 20 fractures produced were all spiral in type and had a longitudinal length of between 7.5 cm and 10.0 cm (mean 8.1 cm). All extended to within 5.0 cm of the level of the adductor tubercle.

2. *Minimum Torque after Kuntscher Nail Fixation*: The largest available nail of 15 mm in stainless steel was used to negotiate the proximal shaft fragment after reaming. The minimal distal medullary diameter was 16 mm. The nail was introduced into the cancellous bone of the distal fragment. Test 1 was repeated and the minimum torque moment recorded. There was no further damage to any of the bones during the second test. The large minimal distal diameter resulted from the proximity (5 cm) to the adductor tubercle.

3. *Minimum Torque after Double Plate Fixation*: The Kuntscher nail was then withdrawn and the fracture fixed using two Muller compression plates. One 8 hole and one 6 hole plate with a total of 10 screws were inserted. Five 7.5 mm screws were placed in the distal fragment (Figure 2). Attempts at compression caused




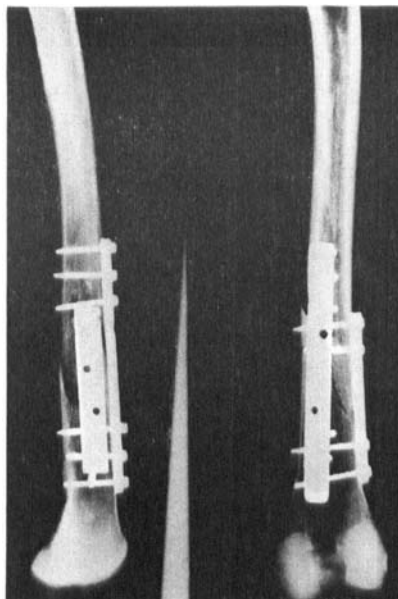
Figure 1. The avery torque testing machine.

comminution at the fracture site. The torque test was performed as before; some secondary fractures occurred at the screw holes. The plates and screws were then removed.

4. Minimum Torque after Kuntscher Nail and Cement Fixation: After reaming the distal fragment, 80 g of slow setting methylmethacrylate cement (Simplex C.) were prepared. When of doughy consistency they were introduced by a punch into the medullary canal of the distal fragment away from the fracture site. The same

Figure 2. Double compression plate fixation of a spiral fracture of the shaft of a cadaveric femur.

Compression screws were used throughout and five were placed in the distal fragment.



Kuntscher (15 cm) was inserted. The cement was allowed to set for 20 min and the torque test repeated. The minimum Torque generated was recorded.

RESULTS

These figures are given in the graph in Figure 3 and in Table 1.

Test 1: The breaking torque was inversely proportional to age, with males slightly stronger than females in the younger age groups. The type of fractures produced were remarkably uniform (Figure 3) (Lindahl 1968).

Test 2: The Kuntscher nail was never able to obtain a firm grip of the distal fragment and the low values recorded confirm this (Table 1).

Test 3: The failure of this form of fixation was caused by the distal screws cutting through the softer bones of the distal fragment. Compression and fixation of the spiral fracture also proved difficult. The poor hold the compression screws obtained on the distal cortex made the final strength of compression small (Table 1).

Since the plates and screws in all tests remained completely unbent and undamaged, the failure could not be attributed to them. The absence of a well-developed cortex in the distal third was an important factor.

Table 1. Breaking torque moment: Adult femur shafts in kilogram centimeters.

Number	Age	Sex	Normal femora	Kuntscher nail fixation	Compression double plate fixation	Kuntscher nail & acrylic fixation
1	50	♂	1064	11.5	40	200
2	53	♀	665	19.5	66	200
3	19	♂	3225	19.5	80	132
4	67	♂	532	20.0	52	132
5	67	♀	495	20.0	46	528
6	71	♂	532	26.0	36	200
7	68	♀	505	13.0	42	205
8	70	♀	532	13.0	58	200
9	22	♀	1264	20.0	46	264
10	48	♂	798	31.0	42	132
11	61	♂	1011	19.5	78	132
12	26	♂	1330	6.5	75	200
13	52	♂	1064	19.5	57	140
14	53	♀	851	31.0	62	200
15	50	♀	798	20.0	72	180
16	68	♀	532	13.0	40	220
17	70	♀	495	20.0	47	220
18	72	♀	425	13.0	57	140
19	76	♀	505	20.0	52	200
20	80	♂	528	19.5	70	220

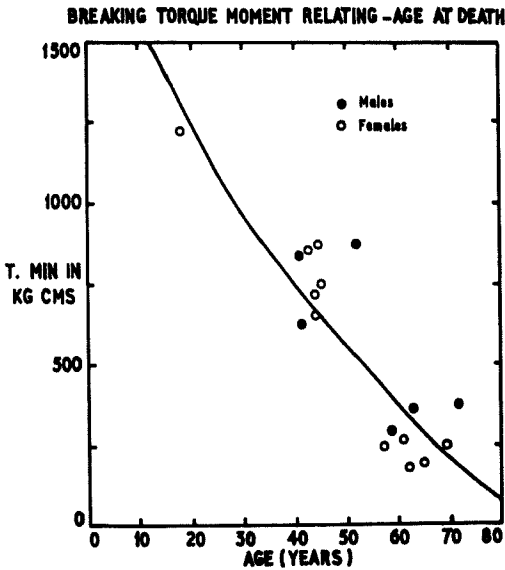


Figure 3.

Test 4: The failure point coincided with the fracture of the plastic at the fracture site. The nail still remained embedded in the plastic in the distal fragment after this point (Table 1).

DISCUSSION

As a torque moment produced spiral oblique fractures in the cadaveric femur on every occasion, it is very probable that similar forces produce them in life (Perkins 1956). The minimum breaking torque generated is a useful comparison of the strength of the methods used for fixation.

From a mechanical point of view a Kuntscher nail alone is quite unsuitable. Nail and cement, or plates and screws, may be useful forms of fixation of oblique shaft fractures, as long as non-weight bearing is adhered to until union is complete. Nail and cement can be used in spiral fractures longer than 10.0 cm, when plating becomes difficult. Even on the shorter fractures of the lower third, nail and cement is the strongest fixation available, although compression plates and screws have produced excellent clinical results (Slatis 1971).

Although 20 mm Kuntscher nails are now available and their strength increases as the fourth power of their radius, the massive reaming may reduce the cortex by half (Clawson 1971). Previous reports of double plates versus the 11 mm Kuntscher nail in the femur showed the latter had no fixation (Lindahl 1965). Sintered fibre attachments for similar femoral implants have been found to be only one-fifth as strong as the acrylic bond (Galente 1971). Ceramic bonds were only one-fiftieth the strength of the acrylic bond (Welsh 1971).

Attempts at placing screws through or around a slotted nail are technically difficult and secondary screw hole fractures remain a problem (Charnley 1970).

Before acrylic cement can be recommended for use in human fracture fixation, more must be known of its effects on callus. Early work (Wiltse 1957) showed periosteal callus should bridge a 2" gap filled by acrylic cement in the monkey femur. Endosteal callus and remodelling appeared reduced by the mere physical presence of the cement rather than by a cytotoxic effect.

Nail and acrylic has been used for fractures through metastases (Singh 1966), when union by bone is not an important consideration. Large quantities (40 g) of intramedullary cement do not appear to prevent per-operative sub-trochanteric fractures from uniting in total

hip replacement patients (Charnley 1970). Initial reports of the fixation of per-trochanteric fractures of the femur with nail plate and cement were favourable (Scheuba 1969), but the late complications of infection and re-fracture attributed to inadequate callus have resulted in the cessation of this method (Scheuba 1970). The present technique places the cement distally away from the fracture site so as to fix the nail distally without interrupting the callus formation. With this modification, nail and cement should now be tested in animals before its limited use in elderly humans with spiral fractures can be advocated.

SUMMARY

1. The minimum torque generated in experimental fractures of the femoral shaft is described.
2. The same fractures were fixed consecutively with Kuntscher nail, double compression plates and Kuntscher nail and cement, and were similarly tested in torque.
3. Possible use of nail and cement to fix torque fractures are discussed.

ACKNOWLEDGEMENT

My thanks are due to Rolls Royce Limited, Crewe, for technical facilities for this research; to the Department of Pathology of Crewe Memorial Hospital and the Kent & Canterbury Hospital for specimens, and to North Hill Plastics for their supply of the acrylic cement.

REFERENCES

- Charnley, J. (1970) *Acrylic cement in orthopaedic surgery*, p. 69. 1st ed. E. & S. Livingstone.
- Clawson, D. K., Smith, R. F. & Hensen, S. T. (1971) Closed intramedullary nailing of the femur. *J. Bone Jt Surg.* **53-A**, 681-692.
- Galent, J., Rotoker, W., Luck, R. & Ray, R. (1971) Sintered fibre metal composites as a basis for the attachment of implants. *J. Bone Jt Surg.* **53-A**, 101-114.
- Kuntscher, G. (1967) *The practice of intramedullary nailing*, p. 6. Charles C. Thomas, Springfield, Ill.
- Lindahl, O. (1965) The rigidity of immobilisation of oblique fracture. *Acta orthop. scand.* **35**, 39-52.
- Lindahl, I. & Lindgren, A. (1968) Cortical bone in man. Variation in tensile strength with age and sex. *Acta orthop. scand.* **39**, 127-135.
- Muller, M. E., Allgower, M. & Willneger, H. (1965) *The technique of internal fixation of fractures*, p. 4. Springer-Verlag, New York.
- Perkins, G. (1956) The value of knowing the direction and nature of the force causing a fracture. *J. Bone Jt Surg.* **38-B**, 227-237.

- Roberts, N. (1962) Fractures of the shaft of the femur, *Modern trends in orthopaedics*, ed. Clarke, J. M. P., Butterworths.
- Scheuba, G. (1966) Schenkelhalsfraktur mit Palaeos genagelt. *Klin Med. (Wien)* **37**, 219-221.
- Scheuba, G. (1971): Personal communication.
- Singh, S. H. (1965) The use of plastic cement in the treatment of pathological fractures due to malignancy. *Proc. roy. Soc. Med.* **20**, 121-122.
- Slatis, P., Ryoppy, S. & Huittinen, V. M. (1971) A.O.I. osteosynthesis of fractures of the distal third of the femur. *Acta orthop. scand.* **42**, 163.
- Welsh Peter, Pilliar, R. M. & McNab Ian (1971) Surgical implants: The role of surface porosity in fixation to bone acrylic. *J. Bone Jt Surg.* **53-A**, 963-976.
- Wiltse, L. L., Hall, R. H. & Steneheim, J. C. (1961) Experimental studies regarding possible uses of self-curing acrylic in orthopaedic surgery. *J. Bone Jt Surg.* **39-A**, 961-972.

Correspondence to:

M. J. S. Hubbard

The Robert Jones & Agnes Hunt Orthopaedic Hospital
Oswestry, England