

Department of Neurosurgery S, Aarhus Kommunehospital,  
Aarhus, Denmark.

## EXTRADURAL PSEUDOCYSTS

### *A Cause of Pain after Lumbar-Disc Operation*

SV. E. BØRGESEN & P. S. VANG

Accepted 9.x.72

Extradural cysts may be either congenital or acquired. The most frequent site of the congenital cyst is the mid-thoracic region, but a few with lumbar and cervical localization have also been described (Wiese & Foster 1955, Smith & Chavez 1958, Gortvai 1963, Glasauer 1966). They are often associated with osseous changes in the spine, such as kyphosis, scoliosis and widening of the interpedicular distance (Dastur 1963). These cysts are most commonly encountered in patients aged from 20 to 50 years.

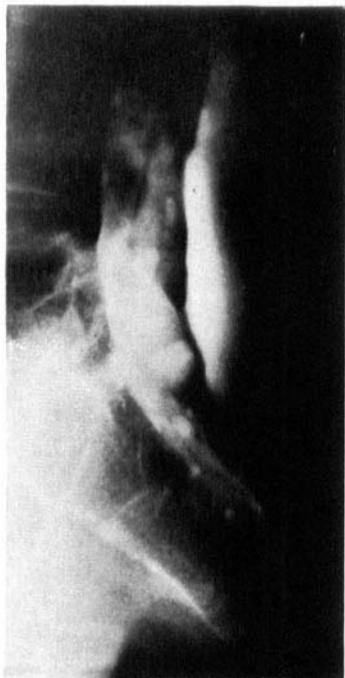The acquired cysts develop after surgery or, less frequently, trauma to the spine. They are mentioned in the literature under such names as meningeal pseudocysts, spurious meningocele or extradural arachnoid cysts. As the meninges are not necessarily involved in the formation of the cyst wall, we find that a more accurate term would be *extradural pseudocysts*.

The purpose of this paper is to present three cases of postoperative extradural pseudocysts, and to contribute to the discussion on the causes of unsatisfactory results from the operative treatment of lumbar-disc lesions.

#### CASE REPORTS

*Case 1.* A 47-year-old woman, operated in 1965 and 1968 for herniation of the fifth lumbar disc. In 1970 laminectomy was performed for herniation of the third and fourth lumbar disc. A month after discharge lumbar pain recurred, now radiating down the left leg posteriorly to the heel. There was also pain localized to the coccyx radiating towards the anus. The pain could be provoked by forward bending of the head and increased in intensity on abdominal straining. Paraesthesiae localized to the lateral border of the left foot and its lateral toes were present.

Delicate palpation of the lumbar region elicited violent pain, and fluctuation was demonstrated. On the lower limbs, hypaesthesiae of the lateral border of the



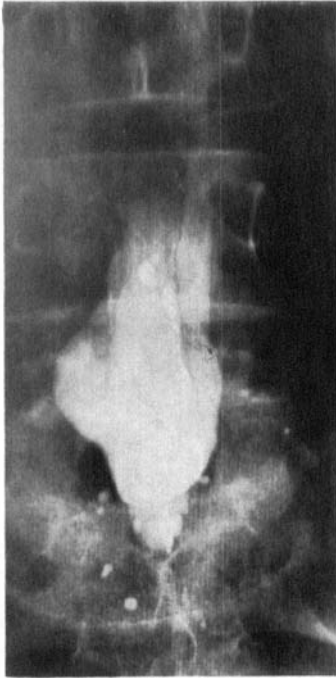*Figure 1. Case 1. Lumbar myelogram demonstrating an extradural lake of contrast.*

left foot and its two lateral toes was revealed. Lasègue's sign was negative on both sides. Conray myelography showed a massive contrast filling behind the dural sac (Figures 1-3).

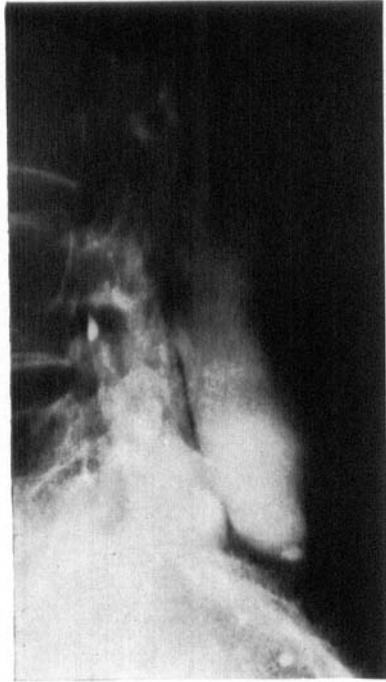In 1971, an extradural pseudocyst was removed, measuring  $11 \times 5 \times 4$  cm. It contained cerebrospinal fluid. In the cavity there were two dural perforations, the upper of which contained a hernia of caudal nerve roots. The hernia was reduced and the dural defects were closed. No signs of root compression or of recurring prolapse were noticed. Histological examination of the cyst wall revealed a membrane, internally bond by flat uncharacteristic cells on a layer of connective tissue cells.

At a follow-up examination 3 months after operation the patient was almost symptom-free. Some lumbar pain was still present when the spine was subjected to physical strain.

*Case 2.* A 26-year-old woman operated on twice for herniation of the fifth lumbar disc in 1967. The symptom recurred, and in 1968 laminectomy on the fourth and fifth lumbar vertebrae was performed, revealing pronounced scar formation around the dural sac; severe arachnoiditis was seen on opening of the dural sac. The pain persisted, and in 1968 division of the right thoracic lateral spinothalamic tract was performed. The patient was free of discomfort for four months, but then progressively severe lumbar pain with radiation in the right lower limb developed. The pain aggravated on abdominal straining. Physical examination showed fixation of the lumbar region and tenderness on palpation and pressure on the lower lumbar vertebrae. Weakness of dorsiflexion of the left



*Figure 2.*



*Figure 3.*

*Figure 2 + 3. Case 1. An extradural pseudocyst is shown in two planes, stretching from the lower border of the third lumbar vertebra to the sacrum.*

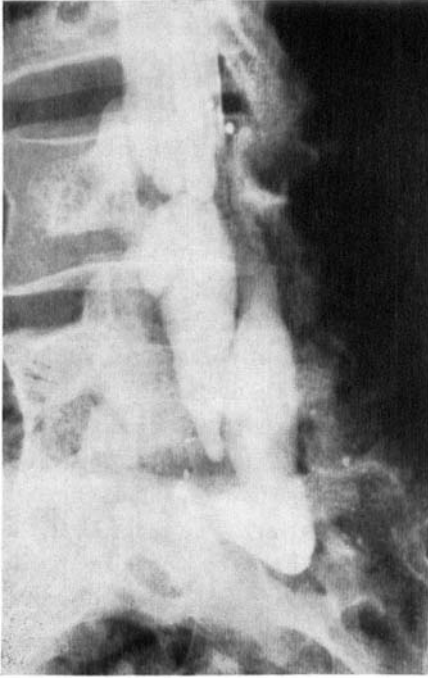
foot and the left first toe were noticed. Lasègue's sign could not be elicited. Conray myelography (Figure 4) showed a large, contrast-filled cavity behind and to the left of the dural sac.

In 1969, resection of the cyst was performed. Downwards in the left side of the dural sac there was a small perforation from which cerebrospinal fluid leaked out. No disc lesion was found.

Histological examination of the cyst showed a membrane resting on a layer of collagen parallel fibres, shading into loose connective tissue with a large number of proliferating vessels surrounded by lymphocytic infiltrations.

Postoperatively, some improvement was seen, but the symptoms of severe arachnoiditis gradually recurred, causing great discomfort to the patient.

*Case 3.* A 23-year-old man, operated for herniation of the fifth lumbar disc in 1963 and again in 1966. The last operation resulted in complete relief of pain, but in 1968 symptoms of root compression developed. A new operation revealed a cyst downwards in the operative cavity, measuring  $3 \times 3 \times 1$  cm and containing cerebrospinal fluid. The cyst was not excised, but sealed off from the dural sac. In addition, a herniation from the fifth disc was removed. Since this last operation the patient has been completely free of symptoms.



*Figure 4. Case 2. Lumbar myelogram (Pantopaque) prone, showing a compression of the dural sac caused by an extradural pseudocyst. Arachnoiditic changes are evident.*

#### PATHOGENESIS

Acquired extradural cysts arise from a defect in the dura. Herniation of the arachnoid may develop through the defect, so that the arachnoid forms part of the cyst wall (Schurr 1955, Rosenblum & Derow 1963). If the lesion involves the arachnoid, cerebrospinal fluid escapes into the surrounding extradural tissue. Normally, the fluid will be absorbed, but if the escape of liquor continues, the absorption mechanism becomes insufficient, owing to protein precipitation and connective tissue reaction (Shahinfar & Schechter 1966). Thus, a non-absorbing membrane develops, forming the wall of the pseudocyst. Histological examination of the wall shows either arachnoid lining or a layer of flat connective tissue cells resting on an outer layer of vascular, loose connective tissue (Shahinfar & Schechter 1966, Miller & Elder 1968). At the hole in the dura a thickened fibrous edge develops. Herniation of a nerve root through the hole in the dura may occur (Wilkinson 1971).

## CLINICAL FEATURES

The symptoms of an extradural pseudocyst are often the same as those experienced in herniation of a lumbar disc. They are back pain, radicular pain, loss of muscular power and sensory disturbances. In addition, meningeal symptoms, such as headache and neck pain, may occur (Hyndmann & Gerner 1946, Swanson & Fincher 1947, Borgström 1954, Pagni et al. 1961, Rosenblum & Derow 1963, Shahinfar & Schechter 1966, Miller & Elder 1968, Rinaldi & Peach 1969). The pain may increase in intensity on abdominal straining and on changes in posture.

Clinical examination may reveal signs of root involvement, such as pareses, sensory disturbances and changes in the deep reflexes. Neck stiffness may be present. The lumbar spine is fixed, and spasms of the paravertebral muscles are often present. A fluctuant mass may occasionally be palpated, and sometimes the pain and headache are accentuated by pressure on the cyst. The cyst may be so large that the skin bulges outward. There is no correlation between the size of the pseudocyst or of the dural defect and the severity of the pain or other symptoms. The time interval between the occurrence of the defect in the dura and the discovery of the cyst may vary from a few months to several years.

## RADIOGRAPHIC APPEARANCE

Plain radiographs of the lumbar spine usually do not reveal the presence of an extradural pseudocyst. Sequelae of a previous laminectomy or traumata to the spine, or narrowing of the intervertebral spaces or marginal osteophytes may be visualized. A few cases are on record in which radiography demonstrated calcified areas in extradural pseudocysts (Rosenblum & Derow 1963, Shahinfar & Schechter 1966). Myelography with a water-soluble contrast medium will often secure the diagnosis. Cases have been described in which the injection needle directly entered an extradural pseudocyst (Shahinfar & Schechter 1966). On subarachnoid injection of the contrast medium it is possible to visualize extradural compression (Figure 4). The filling of an extradural pseudocyst may be difficult and time-consuming if the dural defect is small or blocked by a herniated nerve root. An extradural contrast lake is suggestive of an extradural pseudocyst (Figure 1).

## DISCUSSION

In surveys of operations for disc herniations, poor results are reported with frequencies ranging from 7 to 25 per cent (Malmros 1942, Love 1947, O'Connell 1951, Guillaume & Janny 1953, Gurdjian et al. 1961, Jochheim et al. 1961, Nashold & Hrubec 1971). Too much weight should scarcely be attached to these figures as they depend to a great extent on such factors as the selection of the patients, the experience of the surgeon and the postoperative treatment. However, there will always be a reason for a poor result, and as stated by Armstrong (1967), "most of these conditions are amenable to treatment, either surgical or conservative. There is far too general a tendency to accept operative failures as irreparable and abandon further treatment, whereas in fact most of these patients can be salvaged by appropriate measures."

As causes of painful conditions after operations for disc lesions may be mentioned: unrecognized lateral herniations (Herlin 1959), bilateral and multiple herniations (Campbell & Whitfield 1947, Armstrong 1951, Greenwood et al. 1952, Horwitz & Rizzoli 1967), subsequently occurring herniations; root lesions which have arisen during operation or developed on account of long-continued root compression; root compression caused by ligamentum flavum remnants; arthritic changes in the intervertebral joints; discitis and infection of other localization in the region may give rise to lumbar pain and radicular symptoms (Armstrong 1951, Knudsen 1963, Pilgaard 1969). Further causes may be arachnoiditis (Hughes 1966), ankylosing spondylitis (De Palma & Rothman 1970), and last but not least psychogenic factors.

Extradural cysts are a rare complication of operation for lumbar disc herniation. The operative results after closure or excision of the pseudocyst are reported to be good (Pagni et al. 1961, Miller & Elder 1968, Rinaldi & Peach 1969, Wilkinson 1971). The formation of an extradural pseudocyst should be prevented by meticulous closure of the dural defect.

The patients described in the literature had often undergone one or more operations for lumbar-disc herniation (Hyndman & Gerber 1946, Swanson & Fincher 1947, Pagni et al. 1961, Shahinfar & Schechter 1966, Miller & Elder 1968, Wilkinson 1971). Epstein (1962) described a case which occurred after repeated lumbar punctures. Extradural pseudocysts have also been reported to develop after direct traumata to the lumbar spine (Shapiro & Faske 1950). Incidentally, in many cases, congenital extradural cysts will remain asymptomatic until a trauma to the region has been sustained (Gortvai 1963).

## CONCLUSIONS

The diagnosis of lumbar extradural pseudocyst may occasionally be established on the basis of the history and clinical findings, but a carefully performed myelography with a water-soluble contrast medium will usually be required. Extradural pseudocysts are a rare cause of pain after operation for lumbar-disc herniation. However, several investigators claim that they are less rare than suggested by the relatively small number of published cases. The results of surgical treatment of extradural pseudocysts are good. Thus there is every reason to emphasize the importance of myelography in the evaluation of patients with recurrent pain after lumbar-disc operation, not only in the demonstration of the presence of a pseudocyst, but also in the disclosure of other of the above-mentioned causes of pain.

## SUMMARY

Three cases of lumbar extradural pseudocyst which developed after surgery for lumbar-disc herniation are reported. The literature on pathogenesis, clinical features and radiographic appearance is briefly reviewed. It is emphasized that the results of surgical treatment of extradural cysts are good. Some other causes of recurrent pain after operation for lumbar-disc herniation are mentioned. Myelography is recommended as a useful adjunct in the clarification of the nature of the recurrent pain.

## REFERENCES

- Armstrong, J. R. (1951) The causes of unsatisfactory results from the operative treatment of lumbar disc lesions. *J. Bone Jt Surg.* **33-B**, 31-35.
- Armstrong, J. R. (1967) *Lumbar disc lesions*, pp. 296-302. 3rd ed. E. & S. Livingstone Ltd., Edinburgh, London.
- Borgström, S. G. (1954) Meningocele som komplikation vid diskbråksoperation. *Nord. Med.* **51**, 783.
- Campbell, E. & Whitfield, R. D. (1947) Certain reasons for failure following disk operations. *N. Y. Med.* **47**, 2569-2573.
- Dastur, H. M. (1963) The radiological appearance of spinal extradural arachnoid cysts. *J. Neurol. Neurosurg. Psychiat.* **26**, 231-235.
- Epstein, B. S. (1962) *The spine. A radiological text and atlas*, pp. 557-560. 2nd ed. Lea & Febiger, Philadelphia.
- Glasauer, F. E. (1966) Lumbar extradural cyst. *J. Neurosurg.* **25**, 567-570.
- Gortvai, P. (1963) Extradural cysts of the spinal cord. *J. Neurol. Neurosurg. Psychiat.* **26**, 223-230.
- Greenwood, J. J., McGuire, T. H. & Kimbell, F. (1952) A study of the causes of

- failure in the herniated intervertebral disc operation. *J. Neurosurg.* 9, 15-20.
- Gurdjian, E. S., Ostrowski, A. Z., Hardy, W. G., Lindner, D. W. & Thomas, L. M. (1961) Results of operative treatment of protruded and ruptured lumbar discs. *J. Trauma* 1, 158-176.
- Guillaume, J. & Janny, P. (1953) Etude critique du traitement chirurgical de la lombosciatique d'après l'étude statistique de 1000 cas opérés. *Presse méd.* 61, 172-174.
- Herlin, L. (1959) *Ischias och bäckensmärtor vid lumbosacrala nervrotskompressioner*, pp. 20-27. Svenska Tryckeriaktiebolaget, Stockholm.
- Horwitz, N. H. & Rizzoli, H. V. (1967) *Postoperative complications in neurosurgical practice*, pp. 237-257. Williams and Wilkins Co., Baltimore.
- Hughes, J. Trevor (1966) *Pathology of the spinal cord*, pp. 133-135. Lloyd-Duke Ltd., London.
- Hyndman, O. R. & Gerber, W. F. (1946) Spinal extradural cysts, congenital and acquired. Report of cases. *J. Neurosurg.* 3, 474-486.
- Jochheim, K. A., Loew, F. & Rütt, A. (1961) *Lumbaler Bandscheibenvorfall*, pp. 60-64, Springer-Verlag, Berlin-Göttingen-Heidelberg.
- Knudsen, V. (1963) Spinal epidural absces. *Ugeskr. Læg.* 125, 651-656.
- Love, J. G. (1947) The disc factor in low-back pain with or without sciatica. *J. Bone Jt Surg.* 29, 438-447.
- Malmros, R. (1942) *Den lumbale discusprolaps og ligamentære rodkompression*. Munksgaard, Copenhagen.
- Miller, P. R. & Elder, F. W., Jr. (1968) Meningeal pseudocysts (meningocele spurius) following laminectomy. *J. Bone Jt Surg.* 50-A, 268-276.
- Nashold, B. S. & Hrubec, Z. (1971) *Lumbar disc disease, a twenty-year clinical follow-up study*. Mosby Co., St. Louis.
- O'Connell, J. E. A. (1951) Protrusions of the lumbar intervertebral discs. *J. Bone Jt Surg.* 33-B, 8-30.
- Pagni, C. A., Cassinari, V. & Barnasconi, V. (1961) Meningocele spurius following hemilaminectomy in a case of lumbar discal hernia. *J. Neurosurg.* 18, 709-710.
- De Palma, A. F. & Rothman, R. H. (1970) *The intervertebral disc*, pp. 324-353. W. B. Saunders Co., Philadelphia, London.
- Pilgård, S. (1969) Discitis (closed space infection) following removal of lumbar intervertebral disc. *J. Bone Jt Surg.* 51, 713-716.
- Rinaldi, I. & Peach, W., Jr. (1969) Postoperative lumbar meningocele. *J. Neurosurg.* 30, 504-507.
- Rosenblum, D. J. & Derow, J. R. (1963) Spinal extradural cysts. *Amer. J. Roentgenol.* 90, 1227-1230.
- Schurr, P. H. (1955) Sacral extradural cysts. *J. Bone Jt Surg.* 37-B, 601-605.
- Shahinfar, A. H. & Schechter, M. M. (1966) Traumatic extradural cysts of the spine. *Amer. J. Roentgenol.* 98, 713-719.
- Shapiro, A. L. & Faske, L. (1950) Meningocele spinalis traumatica spuria. *Ann. Surg.* 131, 124-126.
- Smith, G. W. & Chavez, M. (1958) Lumbar extradural cysts—congenital. *Arch. Neurol. Psychiat. (Chic.)* 80, 436-440.
- Swanson, H. S. & Fincher, E. F. (1947) Extradural arachnoidal cysts of traumatic origin. *J. Neurosurg.* 4, 530-538.

- Wiese, B. L. & Foster, J. J. (1955) Congenital spinal extradural cysts. *J. Neurosurg.* **12**, 421-427.
- Wilkinson, H. A. (1971) Nerve-root entrapment in "traumatic" extradural arachnoid cyst *J. Bone Jt Surg.* **53-A**, 163-166.

Correspondence to:

Sv. E. Børgesen  
Department of Neurosurgery S  
Aarhus Kommunehospital  
Aarhus, Denmark