

The Orthopaedic Hospital of the Invalid Foundation,
Helsinki, Finland

**RESULTS OF TREATMENT
FOR ANTERIOR RECURRENT DISLOCATION
OF THE SHOULDER JOINT
WITH THE EDEN-HYBBINETTE OPERATION**

T. SAM LINDHOLM

Accepted 1.xi.73

This study describes the follow-up results of a series of patients operated on for anterior recurrent dislocation of the humero-scapular joint using the Eden-Hybbinette technique and followed postoperatively by early mobilization of the upper extremity.

Operative Technique and Postoperative Treatment

A ventral incision was made distally from the coracoid process. The interval between the pectoralis major and deltoid muscles was opened. The cephalic vein was protected. The subscapular tendon was divided near its insertion into the neck of the humerus. The joint capsule was opened and the glenoid rim identified. A transplant measuring about 1.5-3 cm in breadth and length was taken from the anterior iliac crest. After trimming to a T or V shape it was placed intra-articularly in a subperiosteal pocket made with a chisel in the glenoid rim in a ventro-caudal position. A part of the transplant measuring 0.5-1 cm protruded above the joint surface. The joint capsule was duplicated and the subscapular tendon was as a rule shortened. The wound was closed in layers.

The upper limb was immobilized to the wall of the chest with a Velpeau bandage for one or two weeks and then changed to a mitella. Two weeks after the operation pendular movements of the extremity were allowed. Three weeks postoperatively abduction movements were commenced under the guidance of a physiotherapist. Five weeks postoperatively all movements were allowed.

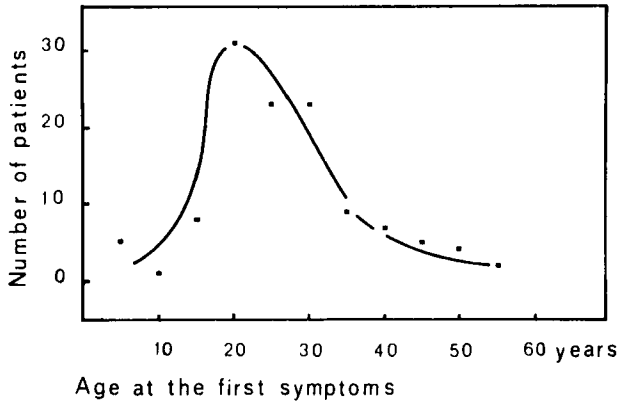


Figure 1. The first symptoms of dislocation occurred in two thirds of the patients between 16 and 30 years, about one half of these being between 16 and 25 years.

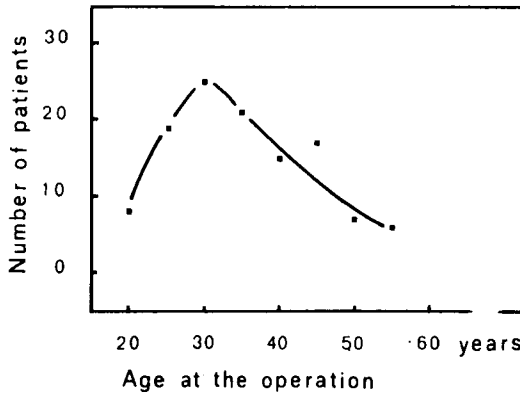


Figure 2. Approximately two thirds of the patients were operated on before the age of 36. The youngest patient was 16 and the oldest 56.

MATERIAL

The series consisted of 118 patients with 124 anterior recurrent dislocations of the gleno-humeral joint operatively treated at the Orthopaedic Hospital of the Invalid Foundation, Helsinki, Finland, during the years 1945-1971. The 118 patients were made up of 90 males and 28 females. The right shoulder was involved in 64 cases and the left in 44. There were 8 cases with a bilateral dislocation, 6 in males and 2 in females. The males had 45 unilateral dislocations on the right side and 36 on the left; the females, 19 on the right and 8 on the left.

The age distribution patterns of the treated patients at the onset of the symptoms of the dislocation, the age at the time of the first operation and the interval between the symptoms and the first operation are seen in Figures 1-3.

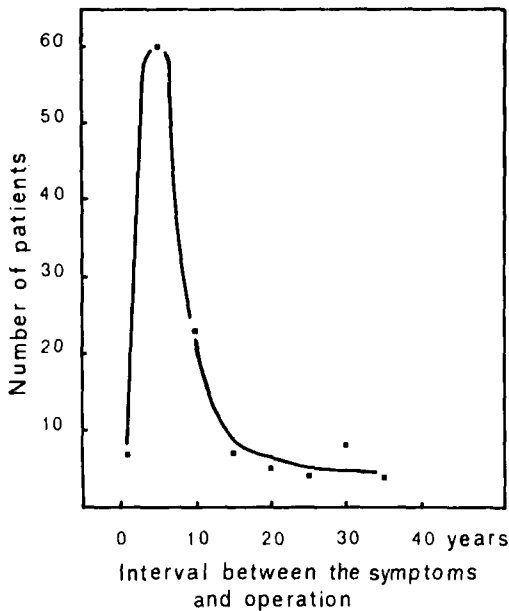


Figure 3. The interval between the first dislocation and the operation was between 1 and 5 years in half of the patients and between 1 and 10 years in two thirds.

Trauma was the cause of the first dislocation in 77 shoulders. In 52 of these the dislocation was attributed to a direct injury to the shoulder, in 21 to a forced movement and, in 4 to a combination of these. The dislocation was spontaneous in 47 shoulders. In 2 of these the glenoid fossa was congenitally abnormal.

The frequency of recurrent dislocation (101 shoulders) in relation to age at the onset of symptoms is seen in Table 1.

The dislocation had been primarily reduced by a doctor in 40 cases, mostly without anaesthesia. In 56 cases the patient himself or a layman had reduced it. In the remainder of cases the situation in this respect was unclear.

The duration of immobilization after the first reduction was less than 3 weeks for the majority of patients; only in three cases did the duration exceed 3 weeks.

Before the operation, redislocation caused discomfort or pain in 94 shoulders. There were no complaints in 30 shoulders. The mobility of the shoulder joint was preoperatively good in 106 shoulders, fair in 12 and poor in the remainder (due to muscle weakness in 4 shoulders and a plexus lesion in 2).

In the preoperative X-ray examination (taken with the arm in inward or outward rotation) the typical defect in the postero-lateral part of the humeral head was noticed in 42 shoulders, and a fracture of the anterior rim of the glenoid in 27 shoulders.

The technique described above was the first operation carried out for recurrent anterior dislocation in 104 unilateral and six bilateral cases. There were in addition eight cases who came to our hospital for reoperation. Reoperation was undertaken in five of these after an earlier soft tissue operation (capsulorrhaphy) with

redislocation of the joint, and was regarded as necessary after a bone block operation in three cases before loosening of the transplant. In one of these an Eden-Hybbinette operation had been performed twice at another hospital at an interval of five months, and a third one was now undertaken because of redislocation. The transplant worked loose in this case too, and arthrotomy and extirpation of the transplant were performed. The capsule was duplicated and the subscapularis shortened.

Table 1. The frequency of recurrence in 101 shoulders is more pronounced in the younger age groups especially under 20 years. The patients could not remember the number of dislocations for 23 of the 124 shoulders.

Age at the first dislocation of the shoulder (years)	Number of recurrences in 101 cases			
	< 10	11-20	21-30	> 30
< 10	5	4	5	10
11-20	8	8	6	23
21-30	10	5	3	7
31-40	3	1		1
41-50	2			
	28	18	14	14

A questionnaire concerning the postoperative state was sent to all of the patients. 93 of the patients answered it. Those patients with poor mobility of the shoulder joint, postoperative redislocations and those reoperated because of detachment of the bone graft were clinically re-examined. In the other cases the available data in the records were used. More than half of the patients were observed for 6 years and one-fourth of 11 years postoperatively. For 93 of the patients the age at follow-up was between 21 and 50 years.

RESULTS

The results of the questionnaire and the re-examinations are seen in Table 2. The general condition of the shoulder joint was good in 111 cases, joint mobility was normal or fair in 118 and gave no pain in 79. In the clinical examination during the follow-up time it was noticed that flexion was impaired in 22 shoulders, abduction in 11, inward rotation in 9 and outward rotation in 28. The joint had been redislocated in 2 cases once, in one case twice and in two cases more often postoperatively.

Observations concerning the shoulders with postoperative redislocation may be summarized as follows:

Table 2. The functional result of the operated shoulder joint according to the questionnaires and the follow-up examination.

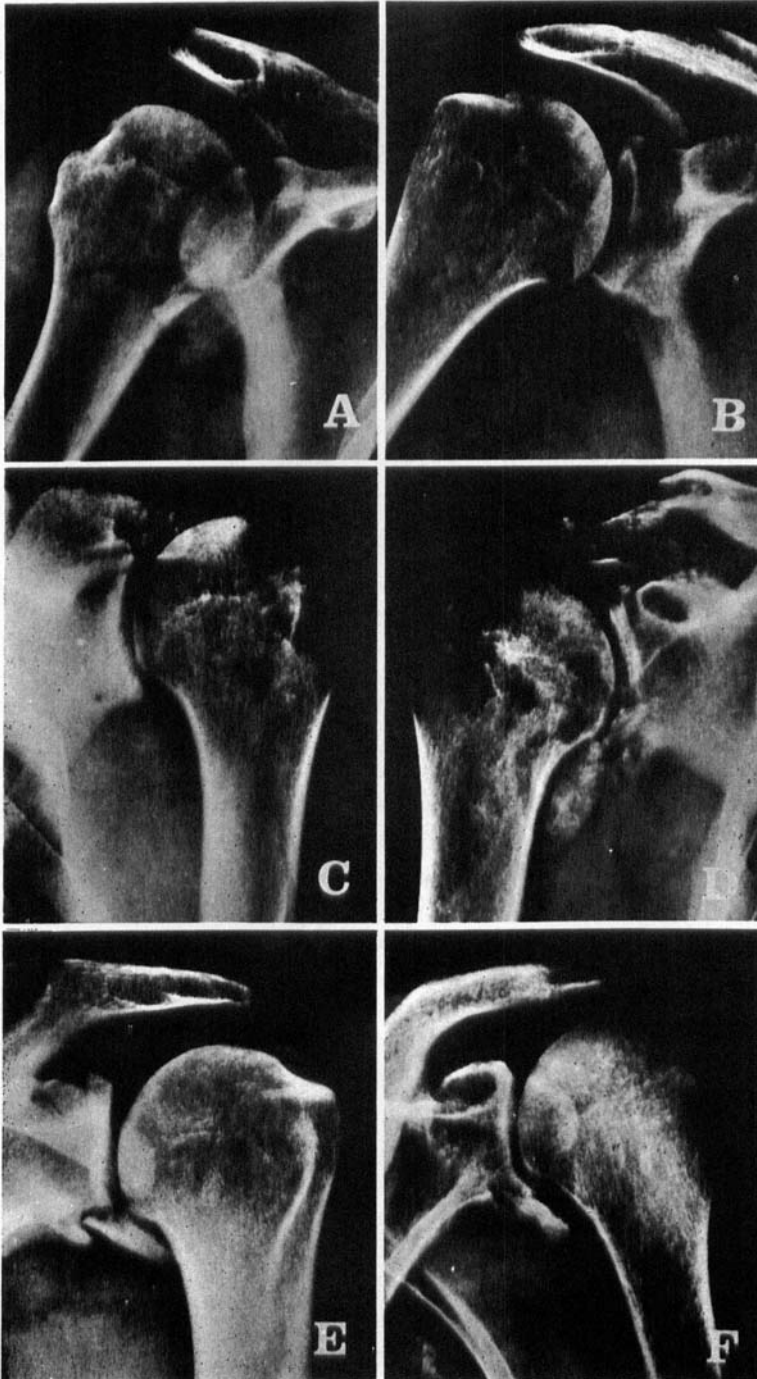
<i>General Condition of the Shoulder</i>	
good	111
fair	9
poor	4
	124
<i>Pain in the Shoulder</i>	
upon movement	18
at rest	4
both	23
no complaint	79
	124
<i>Mobility of the Shoulder Joint</i>	
normal	81
fair	37
poor	6
	124
no redislocation	119
redislocated	5
	124

A 60-year-old male had a dislocation 4 years postoperatively after trauma to the shoulder. In X-rays the transplant was in place but fragmented.

A 57-year-old male had 5 redislocations, the last being about 20 years after the operation. X-rays revealed that the glenoidal surface was flattened and that there was a defect in the postero-lateral surface of the caput humeri. The transplant was in place.

A 55-year-old male had one redislocation postoperatively probably as a result of a trauma. X-rays showed that the transplant was in position.

Figure 4. Postoperative radiographs of shoulders showing different conditions of the bone transplants. A. fused, B. fused, but with distal resorption, C. fully resorbed, D. fractured and fragmented, E. not fused but attached by a fibrous bone connection, F. the transplant has fused but there is an area of resorption around it and the distal part is probably loose.



A 52-year-old male had many redislocations postoperatively. He was operated on 15 years previously. X-rays revealed that the transplant was loosened.

A 27-year-old female treated operatively 8 years previously had two redislocations which she reduced herself. In the X-rays the transplant is in place and consolidated. The cause of the redislocations is unknown.

In the postoperative X-ray follow-up the bone transplant was in place and consolidated in 109 shoulders. In 4 the transplant was partly resorbed distally and in 3 fully resorbed on an average one year after operation. The transplant was partly loosened in 4 shoulders on an average 3 years postoperatively and in another 4 it was fully loosened on an average 7 months postoperatively. The postoperative state of bone transplants is shown in Figure 4.

In 10 cases there were prominent osteoarthritic changes in the joint and in 5 myositis ossificans round the joint.

DISCUSSION

Recurrent dislocation is more frequent in the shoulder than in any other joint. The dislocation may be of a traumatic, habitual or congenital type. The cause of the recurrence depends on several factors, such as the age of the patient (Rowe & Sakellarides 1961), the site and nature of the primary injury (McLaughlin & MacLellan 1967) and the length of immobilization after the initial dislocation.

Anterior recurrent dislocation has been treated in the main with 3 types of operative techniques, i.e. transfer of tendons in the shoulder joint, e.g. the long head of the biceps tendon (Nicola 1929), subscapularis, the Putti-Platt operation (Magnuson & Stack 1943, Osmond-Clarke 1948) reattachment of the capsule (Bankfort 1938, du Toit & Roux 1956, Boyd & Hunt 1965) and bone block operations (Eden 1918, Hybbinette 1932, Palmer & Widen 1948). In Finland the latter operative technique or the Eden-Hybbinette operation has proved very useful (Langenskiöld 1939, Hublin 1946, v. Hellens 1947, Solonen & Rokkanen 1972).

The operations of this series of patients were performed by a great many surgeons. Reoperation according to Eden-Hybbinette was performed in five cases after a soft tissue operation with postoperative redislocation; good results were achieved in four of these cases. In the fifth case arthrodesis of the humero-scapular joint was finally per-

formed for painful osteoarthritis. Follow-up examination revealed re-dislocations in five cases. In one case the redislocation was due to detachment of the bone transplant. The redislocation in three cases must be attributed to trauma or a congenital disorder of the articular surface. No explanation has been found for the postoperative redislocation in the fifth case. It should be noted that the transplant has stayed in position in these four cases. No postoperative redislocation has been established in the cases with resorption of the graft.

It thus appears that postoperative redislocation occurred only in this case with a loose graft. The recurrence rate after the Eden-Hybbinette operation was consequently 4.3 per cent at the follow-up. Other materials report a recurrence rate of 15 per cent (v. Hellens 1947), six per cent (Hublin 1946), one case out of 120 (Hindmarsh & Lindberg 1967), and five cases out of 95 (Solonen & Rokkanen 1972).

A capsulorrhaphy was also performed in conjunction with the block operation, and as a rule a shortening of the subscapular tendon. This explains to some extent why no redislocation occurred postoperatively despite the working loose of the fragment in some cases. The local formation of scar tissue on the site of a transplant under resorption may also prevent recurrence. Postoperative immobilization in a plaster cast has not been regarded as indicated; instead, active postoperative mobilization in stages was used. This procedure is also less unpleasant for the patient. In addition, it gives in most cases a complete range of movement in the joint fairly quickly after the operation.

Postoperative osteoarthritis was seen in only 10 cases of this material, which is to be regarded as a low incidence. The literature reports incidences ranging from 70 (Hindmarsh & Lindberg 1967) to 11 per cent (Solonen & Rokkanen 1972).

The experience gained at this hospital is that our operative technique plus active postoperative mobilization give a very good outcome in the majority of the cases. The technique may also be regarded as indicated in the cases in which earlier soft tissue operations have failed.

SUMMARY

The results of the treatment of 124 anterior recurrent dislocations of the shoulder joint with the Eden-Hybbinette operative technique are reported. In the operation the iliac block was placed intra-articularly and early mobilization of the extremity was emphasized. Reoperation

with this technique after earlier soft tissue operations generally gave good results.

Postoperative redislocations mainly caused by a new trauma occurred in 5 shoulders. Resorption or loosening of the transplant was noted in 15 shoulders during the observation time.

Only one redislocation was noted after the transplant had worked loose. Some patients were restricted in flexion, abduction or inward or outward rotation of the shoulder joint postoperatively.

The technique is recommended for the treatment of recurrent anterior dislocation even though reoperation by other methods has failed.

REFERENCES

- Bankhart, A. S. B. (1938) The pathology and treatment of recurrent dislocation of the shoulder joint. *Brit. J. Surg.* **26**, 23.
- Boyd, H. B. & Hunt, H. L. (1965) Recurrent dislocation of the shoulder; the staple capsulorrhaphy. *J. Bone Jt Surg.* **47-A**, 1514.
- Eden, R. T. (1918) Zur Operation der habituellen Schulterluxation unter Mitteilung eines neuen Verfahrens bei Abriss am inneren Pfannenwande. *Dtsch. Z. Chir.* **144**, 268.
- von Hellens, A. (1947) Über die habituelle Schulterluxation. *Ann. Chir. Gynaec. Fenn. Suppl.* 3.
- Hindmarsh, J. & Lindberg, A. (1967) Eden-Hybinette operation for recurrent dislocation of the humero-scapular joint. *Acta orthop. scand.* **38**, 459.
- Hublin, H. (1946) Erfarenheter av fall opererade för habituellt humerusruxation. *Nord. Med.* **30**, 1004.
- Hybinette, S. (1932) De la transplantation d'un fragment osseux pour remédier aux luxations récidivantes de l'épaule; constatations et résultats opératoires. *Acta chir. scand.* **71**, 411.
- Langenskiöld, F. (1939) Operation av habituellt humerusruxation enligt Eden-Hybinette. *Nord. Med.* **37**, 2883.
- McLaughlin, H. L. & MacLellan, D. I. (1967) Recurrent anterior dislocation of the shoulder. II. A comparative study. *J. Trauma* **7**, 191.
- Magnuson, P. B. & Stack, J. K. (1943) Recurrent dislocation of the shoulder. *J. Amer. med. Ass.* **123**, 889.
- Nicola, T. (1929) Recurrent anterior dislocation of the shoulder. *J. Bone Jt Surg.* **11**, 128.
- Osmond-Clarke, H. (1948) Habitual dislocation of the shoulder, Putti-Platt operation. *J. Bone Jt Surg.* **30-B**, 19.
- Palmer, I. & Widen, A. (1948) The bone block method for recurrent dislocation of the shoulder-joint. *J. Bone Jt Surg.* **30-B**, 53.
- Rowe, C. R. & Sakellarides, H. T. (1961) Factors related to recurrences of anterior dislocations of the shoulder. *Clinical orthopaedics*, p. 20, ed. De Palma, A. F., J. B. Lippencott Co., Philadelphia.

- Solonen, K. A. & Rokkanen, P. (1972) The results of operative treatment for recurrent dislocation of the glenohumeral joint. *Acta orthop. scand.* **43**, 101.
- du Toit, G. T. & Roux, D. (1956) Recurrent dislocation of the shoulder; a twenty-four years study of the Johannesburg stapling operation. *J. Bone Jt Surg.* **38-A**, 1.

Correspondence to:

T. Sam Lindholm, M.D.
The Orthopaedic Hospital of the Invalid Foundation
Tenholantie 10
00280 Helsinki 28
Finland