

Department of Neurosurgery and Orthopaedic Surgery, Odense Hospital, Denmark.

UNSTABLE FRACTURES IN CHILDREN WITH ACUTE, SEVERE BRAIN INJURY

E. ADLER PETERSEN & J. HAASE

Accepted 13.ix.73

An ever increasing number of children with multiple injuries are being admitted every year to the departments of neurosurgery, usually after traffic accidents.

In severe cases the orthopaedic surgical treatment is complicated by cerebrally elicited increased muscle tonus combined with abnormal mobility patterns. Conventional immobilization, e. g. of femoral fractures, in adhesive plaster traction is rendered difficult, or impossible. Therefore, the question of operative fixation of the fractures has sometimes to be discussed by the neurosurgeon and orthopaedic surgeon. This problem does not seem to have been discussed in the literature, not even in major textbooks (Blount 1955, Sharrard 1971).

M A T E R I A L

During the period 1. 4. 1967 to 31. 9. 1969 a total of 22 children with brain injuries and unstable fractures of the long bones were admitted to the Department of Neurosurgery, Odense Hospital. In age they ranged from 3 to 15 years, median 8 years. 16 of the patients were boys.

The site of the fractures was in 14 cases the lower leg—bilateral in one—the femoral shaft in 12—bilateral in 3—the forearm in 3, and the humerus in 2 cases. Three of the children died soon after the accident and did not require orthopaedic treatment. A 7-year-old boy with fractures of both lower legs, treated by immobilization in plaster cast, required intermittent ether anaesthesia, gallamine iodide, clomethiazole edisylate, and respirator therapy through almost 4 months because of severe brain-stem attacks and constant, severe, generalized increase of tonus and seizures. A 13-year-old boy with a fracture of the lower leg had, over several months, considerable increase of tonus which was difficult to manage, and as a result the fracture united in a poor position, although it was immobilized in a plaster cast. A boy aged 4 with a fracture of the femoral shaft was treated with adhesive plaster traction. Despite energetic sedative treatment he had almost constant brain-stem attacks and died one week after admission. An 8-year-old boy with bilateral fracture of the femoral shaft will be described in detail below. In the

other patients the fractures were treated conservatively; all regained consciousness fairly soon and did not present major tonicity problems during the treatment.

The problems relating to operative fixation of extremity fractures in children will now be illustrated by a characteristic case history.

CASE REPORT

A boy, aged 8 years, was admitted as an emergency to a local hospital after a traffic accident. He was in pre-shock, exhibited a dilated left pupil inactive to light, and severe generalized increase of tonus. In the right temple there was a large scalp wound. There were also multiple wounds in the face, and several teeth were broken. In addition, multiple extremity fractures had been sustained. The patient was treated with intubation, hyperventilation, and blood transfusion. To exclude left-sided extracerebral haematoma, a cranial trephination was done on the left, revealing severe diffuse contusion of the brain.

After the condition had been stabilized, the patient was transferred to the Department of Neurosurgery where he remained deeply unconscious, with generalized increase of tonus, and an inactive, dilated left pupil. He had a severely displaced fracture low on the right forearm, and the hand was oedematous and cyanosed. On both thighs there were large haematomas and considerable angulation caused by fractures of both femoral shafts (Figure 1 a). Lastly, there was an incomplete fracture high on the left tibia.

Exploratory burr holes revealed diffuse cerebral contusion. A tracheostomy was established, and thereafter the orthopaedic surgeons reduced the forearm fracture and applied a plaster cast. The fractures of the lower limbs were treated by adhesive plaster traction. Despite medication with phenobarbitone, chlorpromazine chloride, and pethidine chloride, the patient went on exhibiting a violent increase in tonus at the slightest touch. As the condition was unchanged one week after the accident, osteosynthesis of both femoral fractures was done, and they were fixed with double plating (Figure 1 b). The lower-leg fracture was stable and was treated in a plaster cast. A few days later the patient was relaxed on unchanged medication and no longer presented any major nursing problems. The first weeks of the course are illustrated in Figure 2.

Slowly, the level of consciousness increased, and 3 weeks after the accident the patient started opening his eyes, 6 weeks after he could say a few words, and 10 weeks after he could distinguish colours and write a few figures and words. The fractures had then healed, and the osteosynthesis material was removed.

One year after the accident the boy could walk and run, but in a somewhat ataxic manner, and he quickly tired. Mentally he showed behavioural disturbances, characterized by aggressive tendencies. Isotope liquorgraphy and pneumoencephalography disclosed severe, communicating, obstructive hydrocephalus, so that a right-sided ventriculo-atrial shunt was established (Kjærsgaard-Pedersen & Haase 1973). Thereafter, he made a rapid mental recovery.

Two and a half years after the accident he was doing normally for his age at school, was playing naturally with his mates, and was, unlike before, good and helpful at home. His gait showed no abnormalities, the lower limbs were of equal length, and mobility in the hip and knee joints was free. Follow-up x-rays showed

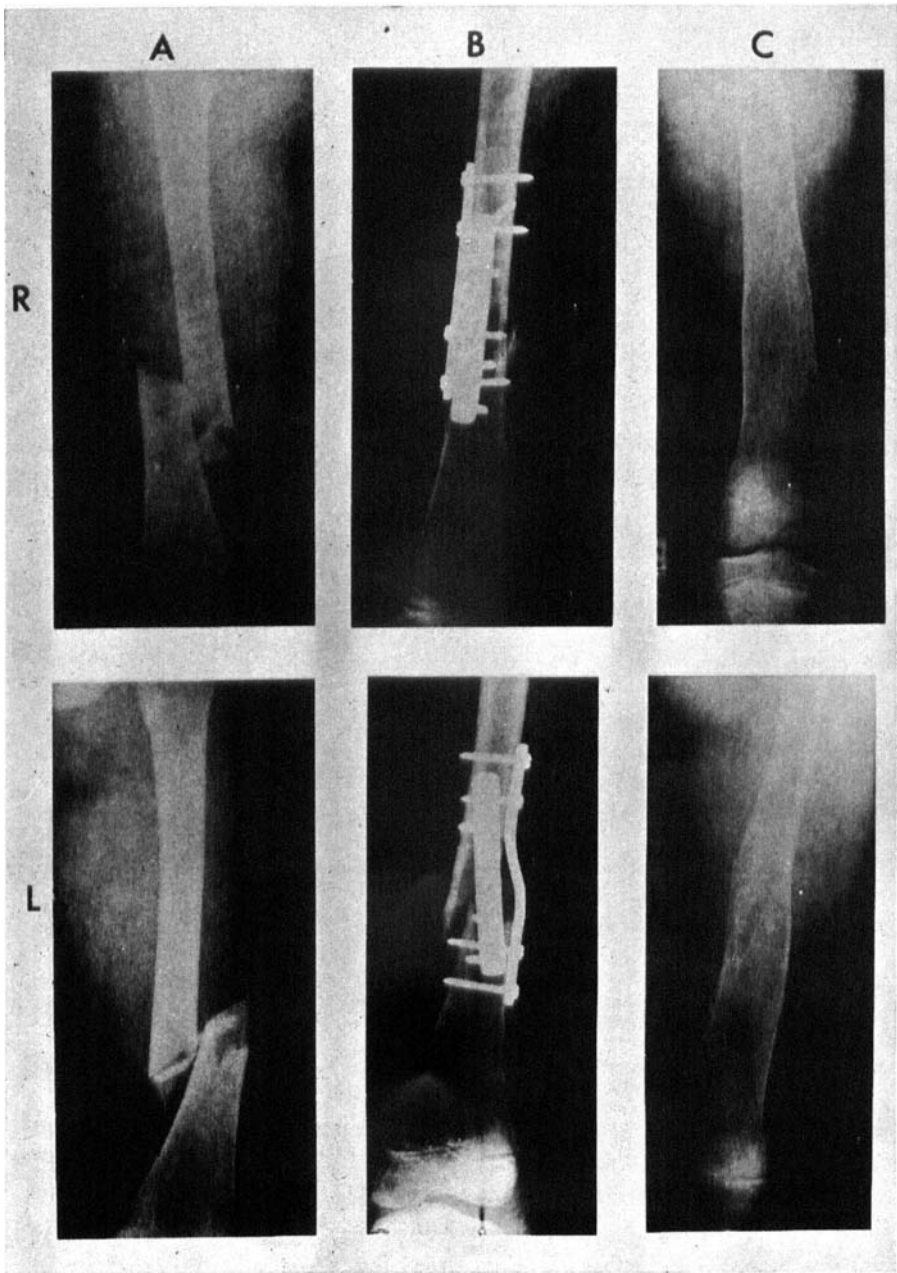


Figure 1. A: Right (R) and left (L) femur in the a-p projection at admission. B: Right and left femur after osteosynthesis. C: Right and left femur 2½ years after the accident. The osteosynthesis material has been removed.

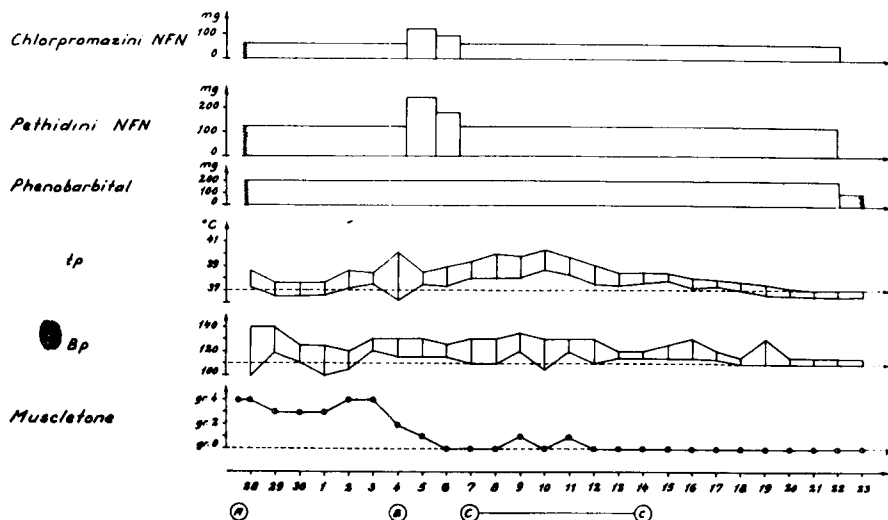


Figure 2. The first 25 days of the course in an 8-year-old boy with severe cranial trauma. Treatment at admission to Department of Neurosurgery (A), bilateral femoral osteosynthesis (B), and period of bronchopneumonias and thrombophlebitis in the upper limbs (C—C).

Bp: Blood pressure.

Tp: Temperature.

Muscle tone:

Grade 0: Normal tonus, normal mobility pattern.

Grade 1: Intermittently slightly increased tonus, normal mobility pattern.

Grade 2: Intermittently increased tonus and abnormal mobility patterns on rough manipulation.

Grade 3: Constantly increased tonus with abnormal mobility patterns elicited by rough manipulation, suction, etc.

Grade 4: Constantly increased tonus and unprovoked abnormal mobility pattern.

perfectly united fractures in both femora, without any signs of angulation (Figure 1 c).

DISCUSSION

Femoral fractures in children without cerebral injury differ in many ways from femoral fractures in adults. Union is rapid, non-union extremely rare, and there is a marked tendency to spontaneous correction of deformities (Guldhammer 1963). As a rule, adhesive plaster traction is sufficient to achieve the goal. Instability of the fracture and pain at the fracture site seldom pose any problem after one week's treatment. Complications are rare. Thompson & Mahoney (1951) found only 9 cases of Volkmann's contracture among 1239 femoral fractures

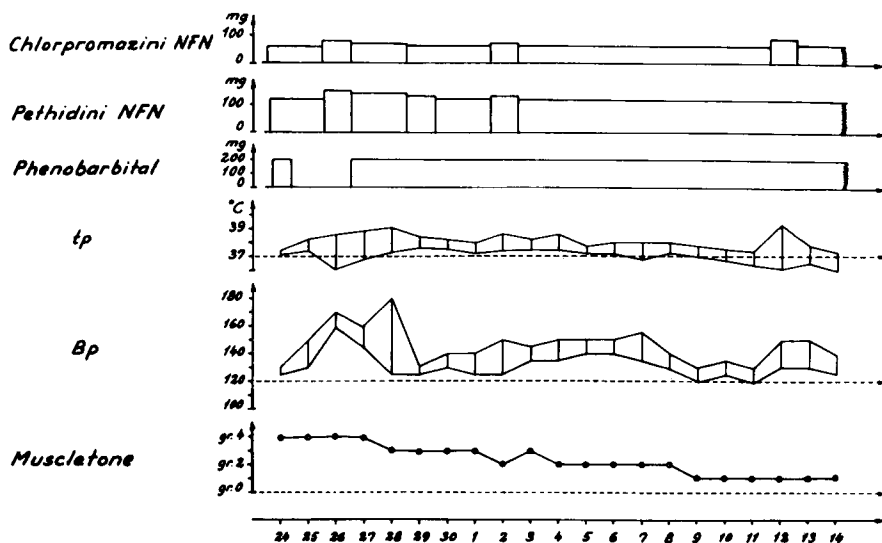


Figure 3. The first 20 days of the course in a 13-year-old boy with a severe cranial trauma. Note the continuously increased tonus, the relatively high blood pressure, and the subfebrile temperature despite high doses of sedatives. No osteosynthesis.

in children. There is very seldom indication for osteosynthesis, considering the numerous complications of this treatment (Blount 1955). In a prospective study Barfod & Christensen (1959) found that conservatively treated patients had a shorter treatment period and achieved better results as regards longitudinal growth. Accordingly, they too rejected osteosynthesis.

The situation is a different one in patients with co-existing severe brain injury, deeply unconscious, and with varying degrees of generalized increase in muscle tonus, brain-stem attacks, or other abnormal patterns. In the most severe cases this condition may last for weeks or months (Overgaard et al. 1970), caused by disturbances of brain-stem function. This muscle-tonus controlling function is affected by all afferent impulses which increase muscle tonus and intensify abnormal mobility patterns. The violent muscle activity, thus induced, entails enormous production of heat. *Inter alia* because of autonomous disturbances, the patient is unable to give off this heat and rapidly develops hyperthermia. This increases the demands on the oxidative metabolism of the brain, further deteriorating the patient's condition. Simultaneously with the muscle activity, the systolic blood pressure rises, and in patients with severe brain injuries this increases the risk

of cerebral oedema. Therefore, an attempt is made to lower the blood pressure and reduce the spontaneous, involuntary muscle activity by restricting afferent stimuli to the brain stem as far as is possible. This is aided by restricting sound stimuli and touch to a minimum, partly by combined phenobarbitone, chlorpromazine chloride, and pethidine chloride medication.

In children with the above-mentioned, severe brain injuries the constant afferent impulses (sensory and proprioceptive) from the area of the fracture to the brain stem contribute highly to maintaining an increased muscle tonus and abnormal mobility patterns. This again inhibits fracture stability, and a vicious circle is set up.

In the present case the general de-afferentiating treatment was not sufficient to counteract the increase in tonus, presumably because immobilization of the fracture sites was insufficient. It was, therefore, deemed necessary to stabilize the fractures by osteosynthesis in order to reduce the afferent impulses sufficiently and thereby improve the cerebral condition. And indeed, immediately after the osteosyntheses the patient was relaxed on unchanged medication (Figure 2). In the reported case both femora were fractured, so that leg length was not likely to become unequal after the osteosyntheses. In this connection it should be pointed out that the cerebral condition should always take priority to possible secondary disturbances of longitudinal growth in cases of unilateral osteosynthesis.

In retrospect, another two of the patients from this hospital probably ought to have been subjected to operation. Figure 3 illustrates the course in a 13-year-old boy with severe cerebral contusion and a low, unstable fracture of the left lower leg. For a long time there was marked increase in tonus and an elevated blood pressure despite large doses of sedatives. Consciousness was lowered for about 2 months, and the plaster immobilization of the lower-leg fracture proved insufficient, the fracture uniting in a poor, rotated position. Furthermore, pressure wounds caused by the plaster later called for skin grafting in two sites. A more stable fixation of the fracture by osteosynthesis would presumably have reduced the afferent impulses to the brain stem and thereby improved tonicity, leading to better union of the fracture. The other patient was the above-mentioned 7-year-old boy with fracture of both lower legs who required 4 months' treatment by intermittent ether anaesthesia and curarization. Osteosynthesis of the fractures might possibly have shortened and eased this very severe course. In both children the osteosyntheses could presumably have been performed very simply by Hoffmann's apparatus.

CONCLUSION

Operative fixation of extremity fracture is usually not indicated in children. However, if severe brain injuries co-exist, the serious tonic disturbances elicited by the brain injuries should entail contemplation of operative fixation of co-existing extremity fractures. This should be done partly to obtain optimal union of the fractures and partly to facilitate the difficult general nursing of the unconscious child.

SUMMARY

On the basis of a case of operative fixation of bilateral femoral fracture in an 8-year-old boy, the treatment of fractures in children with unstable extremity fractures and co-existing severe brain injuries is discussed. It is concluded that operative fixation of extremity fractures in children may constitute an important link in their neurosurgical treatment.

REFERENCES

- Barfod, B. & Christensen, J. (1959) Fractures of the femoral shaft in children with special reference to subsequent overgrowth. *Acta chir. scand.* **116**, 236.
- Blount, W. P. (1955) *Fractures in children*. Williams & Wilkins company, Baltimore.
- Guldhammer, E. H. (1963) Vækststimulation efter fraktur. Disp. København.
- Kjærsgaard Pedersen, K. & Haase, J. (1973) Isotope liquorgraphy in the demonstration of communicating obstructive hydrocephalus after severe cranial trauma. *Acta neurol scand.* **49**, 10.
- Overgaard, J., Haase, J., Hein, O., Laursen, B., Rønde, F., Barnkop, F., Hinke, H. (1970) Trafiktraumatiske hjernelæsioner. *Ugeskr. Læg.* **132**, 695.
- Sharrard, W. J. W. (1971) *Paediatric orthopaedics & fractures*. Blackwell Scientific Publications, Oxford.
- Thompson, S. A. & Mahoney, L. J. (1951) Volkmann's ischaemic contracture: relationship to fracture of the femur. *J. Bone Jt Surg.* **33-B**, 336.

Correspondence to:

Erik Adler Petersen
Department of Orthopaedic Surgery
Odense Hospital
DK-5000, Odense, Denmark