

Martina Hansens Hospital, Sandvika, Norway.

## SPONDYLOLISTHESIS

### *A Review of 71 Patients*

ASLE VEBOSTAD

Accepted 3.i.74

With regard to spondylolisthesis many questions still seem to be unresolved. The purpose of this follow-up was to find out the results of the treatment as given in this hospital, and to find out if spondylolisthesis is of any importance in pregnancy and for delivery, and if possible, to make a contribution to the discussion on progressive slipping.

#### MATERIAL AND METHODS

A total of 109 patients have been treated for spondylolisthesis at Martina Hansens Hospital during the period 1937-1970. Six patients have been excluded because they were treated primarily at other hospitals. Sixteen patients have recently been examined clinically and roentgenologically; the others received a questionnaire. Fifty-five patients replied to the questionnaire and 32 did not; some were dead. Out of the 71 patients who constitute the material in this survey, 29 were treated surgically and 42 conservatively. The patients were asked to evaluate the results as excellent, good or poor. They were asked to distinguish between the result during the first 2 years and the final result. This was because it is felt that many patients do not continue their exercises and therefore the pain may return. All 71 patients are considered as having olisthesis, but slipping less than 5 mm may be questionable. The degree of vertebral displacement is measured in mm and adapted to the one-to-four scale of Meyerding (1938).

#### RESULTS

The age and sex distribution are shown in Table 1 (all 109 patients). There were 62.4 per cent men and 37.6 per cent women. This corresponds to the findings of Neugebauer (1956), Friberg (1939) and Meyerding (1941), but Laurent (1958) reported only 46 per cent men in his series of 809 patients.

*Table 1. Age and sex distribution of 109 patients treated for spondylolisthesis.*

Age	Men	Women	Total
10-19	6	6	12
20-29	9	5	14
30-39	16	7	23
40-49	18	11	29
50-59	9	7	16
60-69	10	5	15
Total	68	41	109

*Table 2. Age at onset of symptoms among 42 patients treated conservatively.*

Age	0-10	11-20	21-30	31-40	41-50	51-60	61-70
No.	4	14	8	6	8	-	2

*Table 3. Degree of slipping, measured in mm, and adapted to the scale of Meyerding, among 42 patients treated conservatively.*

mm Meyerding	0-10	11-20	21-30	31-total lux.
M	14	8	1	-
F	14	2	2	1
Total	28	10	3	1

*Table 4. Age and sex distribution of 42 patients treated conservatively.*

Age	Men	Women	Total
10-19	3	2	5
20-29	3	3	6
30-39	2	4	6
40-49	10	4	14
50-59	3	1	4
60-69	3	4	7
Total	24	18	42

*Table 5. Results of conservative treatment of 42 patients.*

	First 2 years	Final
Excellent	8	4
Good	20	20
Poor	14	18
Total	42	42

*Table 6. Age and sex distribution among 29 patients treated by operation.*

Age	Men	Women	Total
10-19	2	2	4
20-29	4	-	4
30-39	7	1	8
40-49	3	3	6
50-59	3	1	4
60-69	3	-	3
Total	22	7	29

### *Conservative Treatment*

Forty-two patients were treated with physiotherapy with active exercises, bedrest and in a few cases a supporting corset. The observation period varied from 3 to 24 years (average 10.9 years). Table 2 shows the age at onset of symptoms in this group. The location of the lesion was the fifth lumbar vertebra in 27 patients, the fourth in 14 patients and the third in one patient. The degree of vertebral displacement is seen in Table 3.

Table 4 shows the age and sex distribution in the conservative group.

Nine of these 42 patients related their symptoms to an adequate trauma. The time which elapsed from onset of symptoms to treatment varied from  $\frac{1}{2}$  to 57 years (average 12.8 years). All 42 patients had back pain; 25 of them had, in addition, radiating pain, in some cases typical sciatica. Eight patients had a positive Lasegue's sign, 4 patients had sensory disturbances and 7 patients had loss or diminution of ankle jerk.

Table 5 indicates the results of conservative treatment, good or excellent in 24 out of 42 cases.

The average stay in hospital was 56.9 days. Eleven patients in the group had changed their occupation and 9 patients had disability insurance.

*Table 7. Age at onset of symptoms among 29 patients treated by operation.*

Age	0-10	11-20	21-30	31-40	41-50
No.	2	12	7	6	2

*Table 8. Degree of slipping, measured in mm, and adapted to the scale of Meyerding, among 29 patients treated by operation.*

mm Meyerding	0-10	11-20	21-30	31-total lux.
M	13	6	3	-
F	5	1	-	1
Total	18	7	3	1

*Table 9. Results of operative treatment in 29 patients.*

	First 2 years	Final
Excellent	8	10
Good	12	8
Poor	9	11
Total	29	29

*Table 10. Results of posterior fusion in 11 patients.*

	First 2 years	Final
Excellent	5	7
Good	6	3
Poor	-	1
Total	11	11

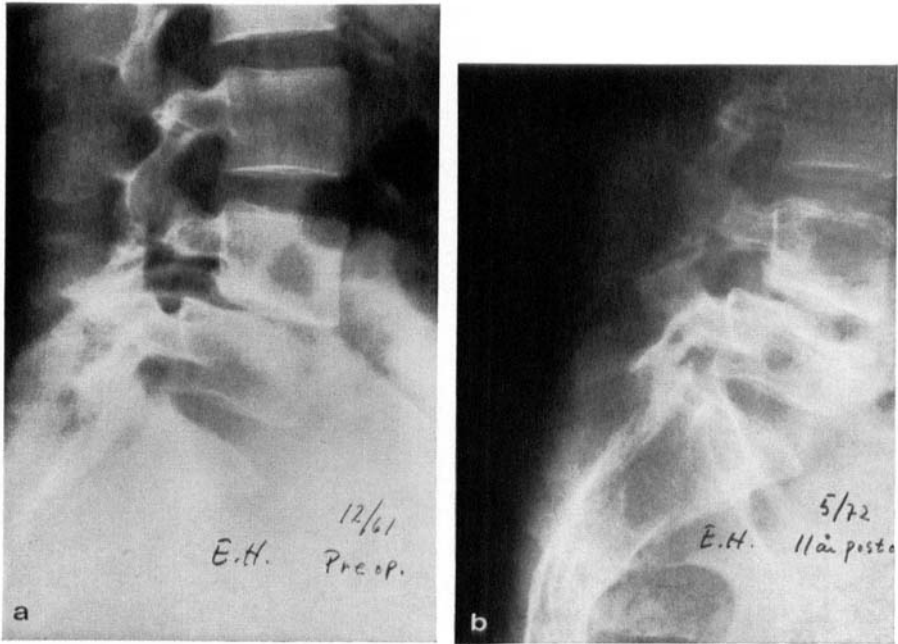


Figure 1. Before (a) and 11 years after (b) lateral intercorporeal fusion. Transplant resorbed, but patient reports the result as excellent.

### *Operative Treatment*

The period of observation in this group of 29 patients varies from 2 to 26 years (average 12.8 years). The symptoms prior to treatment lasted from 1 to 32 years (average 11.1 years). Age and sex distribution are shown in Table 6 and age at onset of symptoms in Table 7. The location of the lesion was the fifth lumbar vertebra in 22 patients, the fifth and fourth in 2 patients and the fourth in 5 patients. Twelve out of these 29 patients operated upon related their symptoms to an adequate trauma. Five of them had changed their occupation and 10 of them had disability insurance. The degree of vertebral displacement is demonstrated in Table 8; most patients had a slipping of less than 10 mm (Meyerding grade 1).

Fifteen of these 29 patients had radiating pain, 5 had positive Lasegue's sign, 3 had sensory disturbances and 6 had loss or diminution of ankle jerk at the time of operation. In the total group of 71 patients, 3 patients had bladder disturbances. The average stay in hospital was 106.8 days.

The results of operative treatment are listed in Table 9. Table 10 shows the results of posterior fusion, performed in 11 cases. In 7 cases a transperitoneal fusion was performed, one with an excellent result and 6 with poor results. In 6 cases only a resection of one or more spinous processes was performed, 3 of them with good or excellent results and one with a temporarily good result. Simple laminectomy was performed only 3 times, twice with a good result and once with a poor result. In one case a lateral intercorporeal fusion was performed. The patient reports the result as excellent, although fusion has not been obtained (Figure 1). The last patient had various combined operations. He reports the result as good, although he has disability insurance.

There were no serious complications of the operative treatment.

### *Spondylolisthesis in Pregnancy and Delivery*

In this material 10 women had given birth to 16 children before the onset of symptoms. None of them had unusual pain during pregnancy and labour. Fifteen women had given birth to 24 children after the onset of symptoms; 7 out of these 15 women suffered from increased pain during pregnancy and 3 during labour. There were no cases of prolonged labour or other signs of mechanical obstruction. One of the women had 2 spontaneous abortions. Two women had avoided pregnancy because of their back lesion.

### *Progressive Slipping*

It still seems to be a matter of dispute whether progressive slipping does or does not occur. In this series, 30 patients had 2 or more X-ray examinations, with a time lapse between the first and the last examination varying from 1 to 16 years (average  $5\frac{1}{2}$  years). Three female patients presented a total lumbosacral luxation, the progression being observed in one of them (Figure 2); the others were total when first seen. They had a pronounced trapezoid-shaped fifth lumbar, with a rounding-off of the sacrum, but there is no early X-ray to determine whether these changes are primary or secondary.

Two patients, aged 18 and 51 years, had a progressive slipping of 8 and 10 mm, respectively. The last one is demonstrated in Figure 3. Nine patients had a small progression of 2-5 mm, and 16 patients had no progression at all. Those with a small progressive slipping were equally distributed in all age groups.

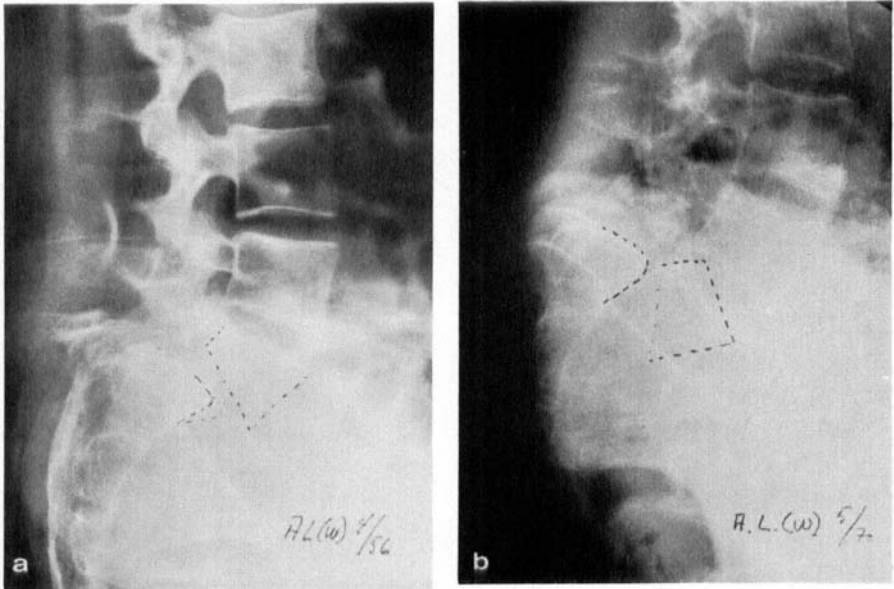
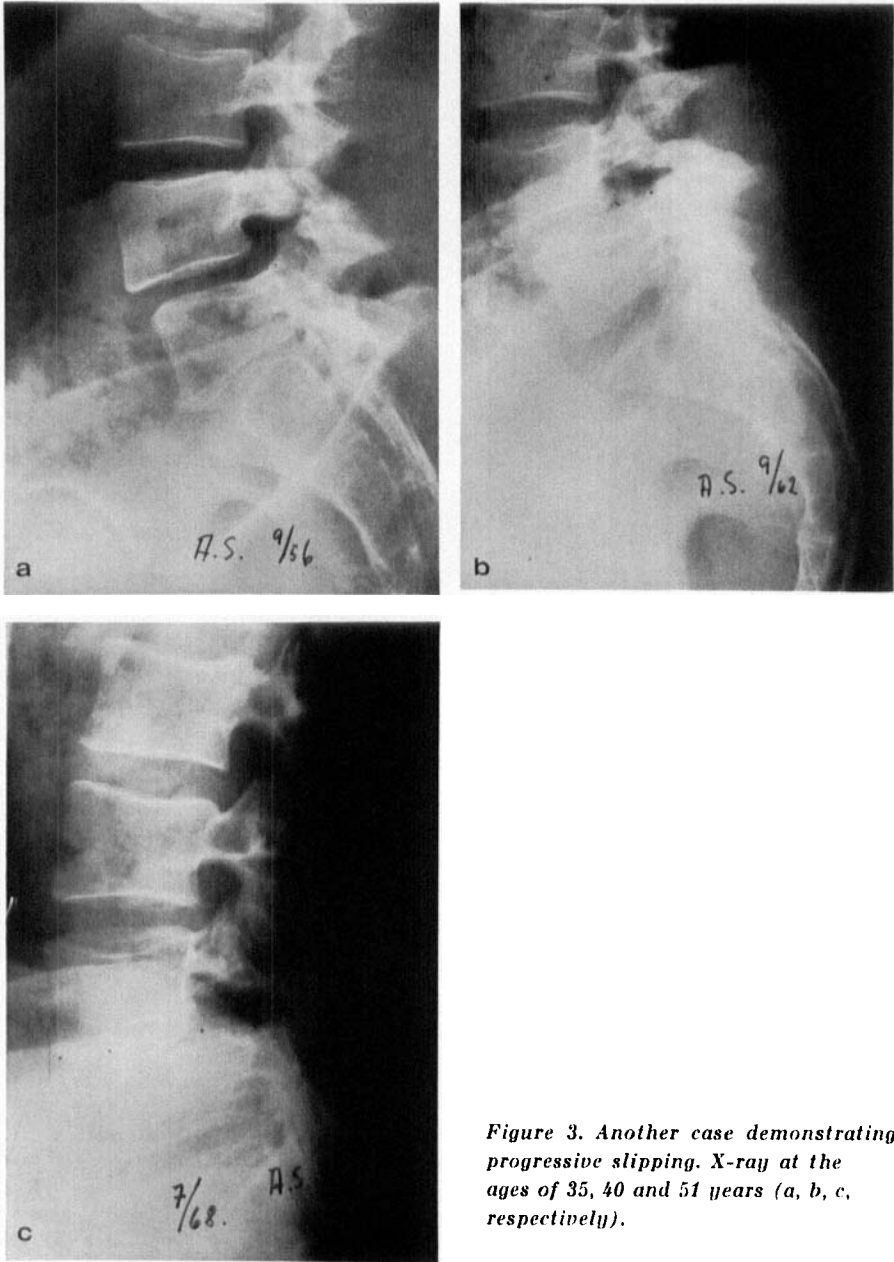


Figure 2. A case of progressive slipping; X-ray at the ages of 15 years (a) and 29 years (b). Laminectomy at the age of 26.

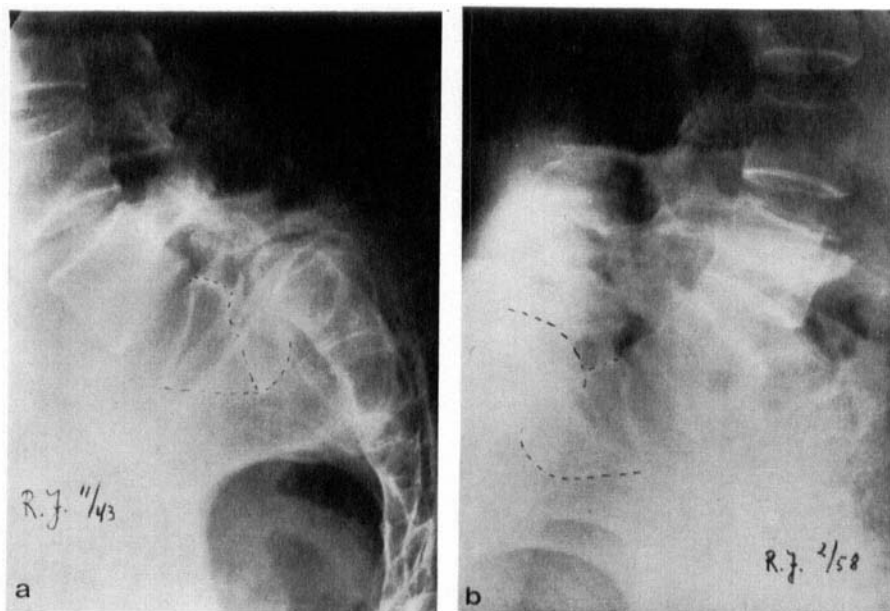
#### DISCUSSION

Spondylolisthesis obviously causes segmental spinal instability, with an increased demand for muscular support. This instability causes back pain because of pull on ligaments and nerve roots. A great proportion of patients were satisfied with the results of conservative treatment (Table 5). This kind of treatment is usually given a fair chance before operation is considered. The young patients with a congenital type of spondylolisthesis might be an exception to this rule. In these few cases a fusion operation should be considered. The only patient with total luxation treated conservatively in this material was satisfied with the treatment (Figure 4), and the only patient with total luxation treated with laminectomy received no benefit from the operation.

The time period between onset of symptoms and treatment varied from  $\frac{1}{2}$  to 57 years (average 12.8 years) in the conservative group. This fact indicates that the lesion is not very disabling, which was also pointed out by Friberg (1939) and Laurent (1958). On the other hand the symptoms probably increase gradually in most cases and at the



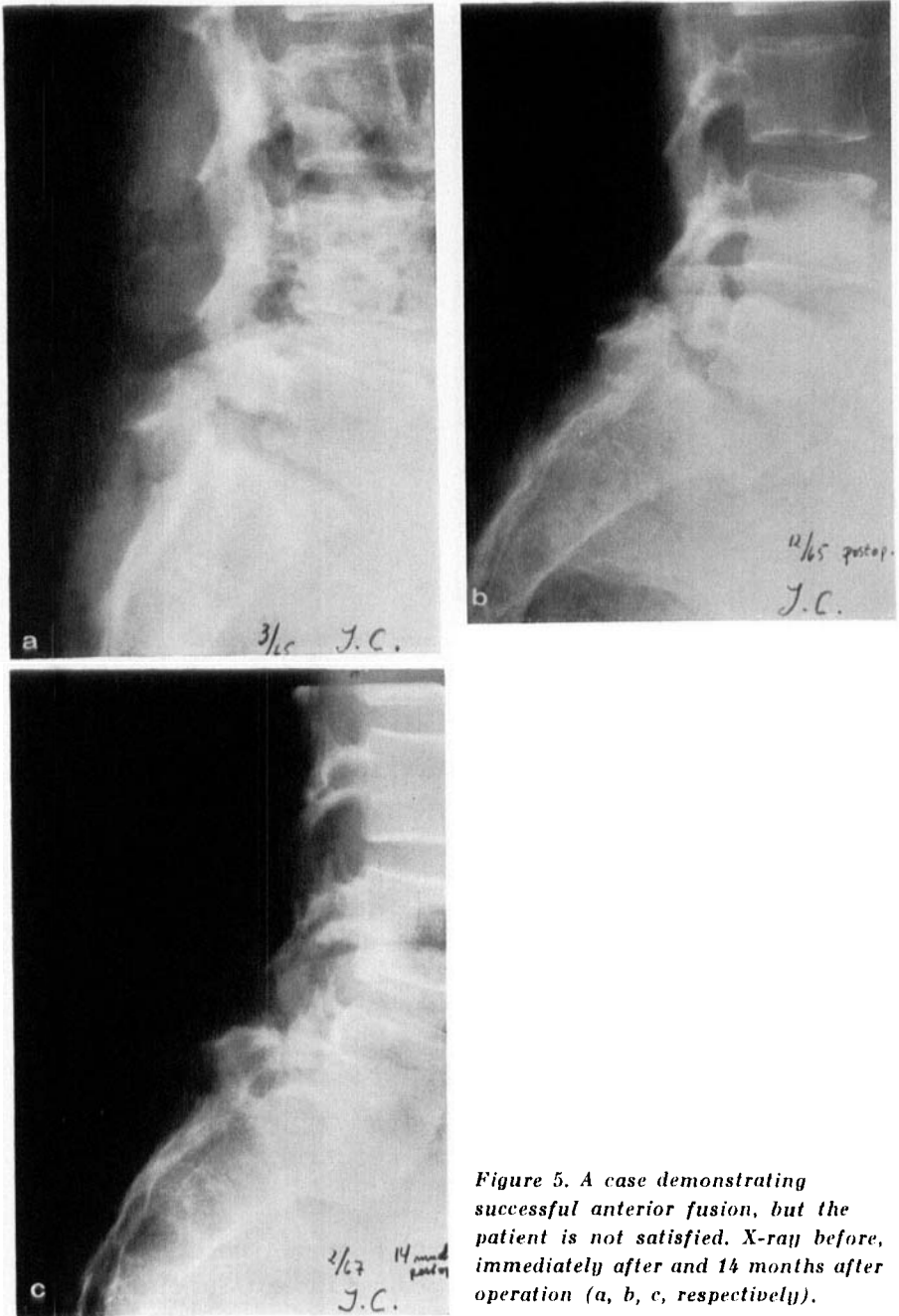
*Figure 3. Another case demonstrating progressive slipping. X-ray at the ages of 35, 40 and 51 years (a, b, c, respectively).*



*Figure 4. The only patient with total luxation treated conservatively. X-ray at the ages of 34 (a) and 49 (b). She was satisfied with the conservative treatment.*

time of hospitalization the patients are considerably disabled and in need of corrective treatment.

Few women have been treated by operation, probably because they normally have less heavy work than men, and also because they seem to come to treatment a little later, often at the menopausal age (Table 1). The posterior fusion seems to give good results (Table 10). This finding is comparable with similar reports in the literature (Bosworth et al. 1955, Friberg 1939, Meyerding 1941). In any case, the posterior fusion seems to have a decreasing popularity nowadays. Newman (1973) seems to prefer a posterolateral fusion and Schmorl & Junghans (1971) favour a posterior intercorporeal fusion. In contradistinction to the transperitoneal route, it allows simultaneous decompression, and may also be combined with a posterior fusion. Transperitoneal intercorporeal fusion has given poor results in this material, only one out of 7 patients was satisfied. Figure 5 demonstrates one of the six patients who was not satisfied, although fusion has been obtained. In this material there has been no experience with the posterior intercorporeal fusion, but the method seems reasonable from



*Figure 5. A case demonstrating successful anterior fusion, but the patient is not satisfied. X-ray before, immediately after and 14 months after operation (a, b, c, respectively).*

a mechanical point of view. Gill & White (1965) and Woolsey (1954) consider the fusion operations to be unnecessary. They claim that a decompression operation (laminectomy) gives most patients relief from pain. They have found fibrous masses at the isthmus with various kinds of nerve root compression. Laminectomy has only been performed 3 times in this material, one with poor results (Figure 2) and 2 with good results. This operation is obviously best suited to the cases where sciatic pain and not spinal instability is the main problem. It should be mentioned that Davis & Bailey (1972) reported good results from laminectomy in 83 per cent of cases if there were minimal arthritic changes, and in 58 per cent if there were moderate to severe arthritic changes.

In some cases the disc is considered to be the source of pain, at least if it protrudes. This was probably true in one case. The patient had excellent results from lateral intercorporeal fusion, although fusion was not obtained (Figure 1). With few exceptions the patients in this review had reduced disc height, but myelography has seldom been performed. Alvik (1969) preferred laminectomy and in some cases a transperitoneal intercorporeal fusion at a second stage. Harrington & Tullos (1971) preferred intercorporeal posterior fusion for children.

In this review spondylolisthesis had some importance for the pregnant women as 7 out of 15 women suffered from increased pain during pregnancy and 3 during labour. In 2 of these women the increased pain continued, but in no case did this back lesion seem to cause mechanical obstruction. Dandy & Shannon (1971) reported 14 normal pregnancies and 4 miscarriages whereas 2 labours were prolonged.

There were at least 3 patients with significant progressive slipping in this series of 30, and 9 patients had a slipping of 2-5 mm, which must be regarded as questionable. Some authors (Friberg 1939, Laurent 1958) state that progressive slipping is most likely to occur between the age of 10 and 20. A possible relation between progressive slipping and a trapezoid shape of the fifth lumbar body has been pointed out by Friberg (1939), but Laurent (1958) made some measurements and concluded that there was no such relationship. He thought that the trapezoid shape must be a secondary change. Hitchcock (1940) reported 3 cases of progressive slipping; the patients were 4, 13 and 45 years old. Bosworth et al. (1955) found evidence of progressive slipping in 2 cases. Laurent & Einola (1961) reported this feature in 23 out of 52 cases. It has been noted in this review that a trapezoid shape of the fifth lumbar body coincides with a rounded upper contour of the

sacrum, and that these features are more pronounced in severe vertebral displacement.

#### CONCLUSIONS

1. Conservative treatment in the case of spondylolisthesis has a reasonable chance of success.
2. Posterior fusion gives a good result in 80–90 per cent, and this is supported by several other authors.
3. The pain produced in this lesion often increases in pregnancy and in labour, but probably the women should not be dissuaded from pregnancy.
4. Progressive slipping does occur, but in a small proportion of cases.

#### SUMMARY

Seventy-one patients have been reviewed, of whom 42 were treated conservatively and 29 by operation. Good results were obtained in 24 out of 42 patients in the conservative group. Posterior fusion gave good results in 10 out of 11 cases. Transperitoneal intercorporeal fusion only gave good results in one out of 7 cases. The importance of spondylolisthesis in pregnancy and delivery is discussed. Seven out of 15 patients had increased pain in pregnancy and 3 in labour, but there were no prolonged labours suggesting mechanical obstruction. Progressive slipping was demonstrated clearly in 3 cases out of 30 and 9 out of these 30 had a small progressive slipping of 2–5 mm. It seems that a trapezoid shape of the fifth lumbar body and a rounded upper contour of the sacrum (ball and socket) predispose to severe vertebral displacement, but this has not been proved. These features may be secondary changes.

#### REFERENCES

- Alvik, I. (1969) Spondylolistese. *T. norske Lægeforen.* **89**, 1344–1346.
- Borkow, S. E. & Kleiger, B. (1971) Spondylolisthesis in the newborn. *Clin. Orthop.* **81**, 73–76.
- Bosworth, D. M., Fielding, J. W., Demarest, L. & Bonaquist, M. (1955) Spondylolisthesis. *J. Bone Jt Surg.* **37-A**, 767–786.
- Dandy, D. J. & Shannon, M. J. (1971) Lumbo-sacral subluxation. *J. Bone Jt Surg.* **53-B**, 578–595.
- Davis, I. S. & Bailey, R. W. (1972) Spondylolisthesis. *Clin. Orthop.* **88**, 46–49.
- Friberg, S. (1939) Studies on spondylolisthesis. *Acta chir. scand.*, Suppl. 55.

- Gill, G. G. & White, H. L. (1965) Surgical treatment of spondylolisthesis without spine fusion. *Acta orthop. scand.*, Suppl. 85.
- Harrington, P. R. & Tullos, H. S. (1971) Spondylolisthesis in children. *Clin. Orthop.* **79**, 75-84.
- Hitchcock, H. H. (1940) Spondylolisthesis. *J. Bone Jt Surg.* **1**, 1-16.
- Kleinberg, S. (1934) Spondylolisthesis in an infant. *J. Bone Jt Surg.* **16**, 441-444.
- Laurent, L. E. (1958) Spondylolisthesis. *Acta orthop. scand.*, Suppl. 35.
- Laurent, L. E. & Einola, S. (1961) Spondylolisthesis in children and adolescents. *Acta orthop. scand.* **31**, 45-64.
- Meyerding, H. W. (1932) Spondylolisthesis. *Surg. Gynec. Obstet.* **54**, 371-377.
- Meyerding, H. W. (1938) Spondylolisthesis as an etiologic factor in backache. *J. Amer. med. Ass.* **111**, 1971-1976.
- Meyerding, H. W. (1941) Low backache and sciatic pain associated with spondylolisthesis and protruded intervertebral disc: Incidence, significance and treatment. *J. Bone Jt Surg.* **2**, 461-470.
- Neugebauer, H. (1956) Spondylolisthesis und ihre neurologischen Ausfallerscheinungen. *Z. Orthop.* **87**, 393-399.
- Newman, P. H. (1973) Surgical treatment for derangement of the lumbar spine. *J. Bone Jt Surg.* **55-B**, 7-19.
- Newman, P. H. & Stone, K. H. (1963) The etiology of spondylolisthesis. *J. Bone Jt Surg.* **45-B**, 39-59.
- Pfeil, E. (1971) Spondylolysis und spondylolisthesis bei Kindern. *Z. Orthop.* **109**, 17-33.
- Schmorl, G. & Junghans, H. (1971) *The human spine in health and disease*. Grunc & Stratton. New York and London.
- Schreiner, K. E. (1935) *Zur osteologie der Lappen*. p. 256-258. Oslo.
- Stewart, T. D. (1953) The age and incidence of neural-arch defects in Alaskan natives, considered from the standpoint of etiology. *J. Bone Jt Surg.* **35-A**, 937-950.
- Woolsey, R. D. (1954) The mechanism of neurological symptoms and signs in spondylolisthesis at the fifth lumbar, first sacral level. *J. Neurosurg.* **11**, 67-76.

Correspondence to:

Dr. Asle Vebostad  
Martina Hansens Hospital  
1300 Sandvika  
Norway