

Department of Orthopaedic Surgery and Accident Service, the Central Hospital,  
8900 Randers, Denmark.

## LESIONS OF THE VOLAR FIBROCARILAGO IN FINGER JOINTS

*A 2-Year Material*

J. T. MØLLER

Accepted 3.xii.73

Interest in the pathological-anatomical changes in the sprained finger dates essentially from investigations by Moberg & Stener (1953) and Stener (1963), in whose work it was pointed out that exact diagnosis with determination of localization and distribution of the ligamentary injuries is decisive for treatment and prognosis.

Just as the collateral ligaments hinder lateral movements, the fibrocartilago volaris functions as the passive retardation of non-physiological extension movements in the finger joints. Therefore, lesions of the volar fibrocartilage occur during trauma involving a moment of hyperextension. The trauma most often consists of a combination of hyperextension, sideways deviation and axial trauma with simultaneous injury to the collateral ligaments and/or bone ends adjacent to the joints.

In the four ulnar metacarpo-phalangeal joints the fibrocartilage is very thin. In the interphalangeal joints it consists of two lateral, solid strands, and a thin, axial part, ending proximally in a free border (Gad 1967). Ruptures in these joints can occur in one of the proximal insertion corners, being unilateral, or in both, viz. total, or in the distal part.

The diagnosis: lesion of the fibrocartilago volaris is characterized by local tenderness and pain on hyperextension. With flexion from this position the pain disappears but reappears near the point of maximum flexion.

This publication concerns itself with the results of a follow-up investigation of conservatively treated cases with the aforementioned diagnosis, with or without subluxation, luxation or volar avulsion. The

lesions are divided into types, based on the clinical and roentgenological findings, and treatment and prognosis is evaluated in relation to this division.

#### MATERIAL AND METHODS

A total of 139 injuries were treated between Sept. 1970 and Sept. 1972, of which 57 were women and 82 were men. 54 per cent were in the age group 11-15 years, 24 per cent were 16-20 years old, and 12 per cent were from 21-25. The investigation covered 109 patients with 111 injuries, consisting of 121 fingers and 138 joints. A follow-up study was performed 1 to 24 months, with an average of 8.4 months, after the injury. The standard treatment was immobilization of the finger with the joint in semi-flexion with the help of a flexible, foam-rubber-covered aluminum splint for 2 to 4 weeks. Injuries with total rupture of the collateral ligaments are not included in the investigation.

#### *Aetiology*

Balls striking the fingers accounted for 39 per cent, falls 27 per cent, struck fingers 10 per cent and others 24 per cent.

Sequelae are graded in the following manner:

- + cold water and forceful loading brings on mild pain.
- ++ moderate pain from tapping or from performing normal work.
- +++ considerable pain daily, symptomatic restriction of movement, dystrophic appearance.

Movement restriction and passive hyperextension possibility without subjective sequelae were less than 10°, and are not listed as sequelae.

#### *Statistics*

X<sup>2</sup> test and Yates' correction with 5 per cent as significance limits.

At the primary investigation of a joint with hyperextension trauma the lesion corresponding to the area with the maximum soreness of the volar fibrocartilage was found with the help of a narrow blunt instrument. This localized tenderness lasts for up to several years after healing or defective healing, and can be demonstrated most easily during simultaneous passive hyperextension of the joint.

#### RESULTS

On the basis of journal notes, X-rays and the clinical findings of the follow-up investigation the lesions could be divided up into three groups and nine types (Figure 1). Group 1 consists of joints with normal configuration and movement, but with a unilateral soreness on the side of the proximal insertion. The joints in group 2 had bilateral

**TYPES**



1A

As 1A, but total proximal rupture



2A

3A

As 1B, but total or:



1B



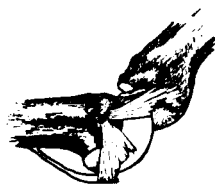
2B



3B



1C



2C

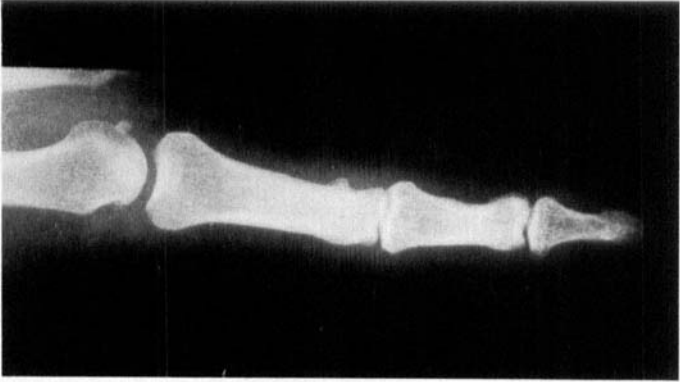


3C

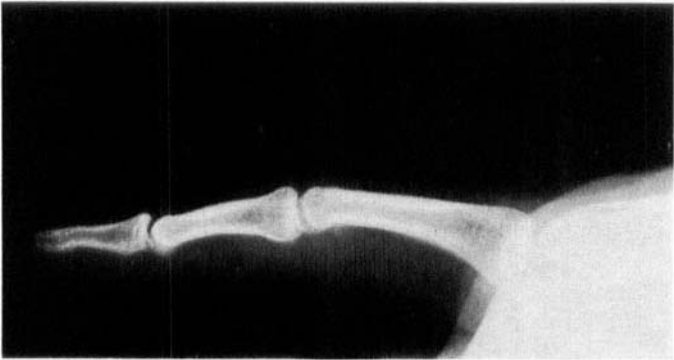*Figure 1. In group 1 the lesion is unilateral and proximal, in group 2 it is total and proximal. In group 3 the lesion is distal and occurs with or without bone fragmentation. The types marked B have simultaneous lesion of the collateral ligaments. C stands for luxation or subluxation.*

proximal soreness. In group 3 are listed the joints where the soreness was localized in one or both of the distal insertion corners, with or without volar bone fragments. The number of lesions with bone fragments make up 42 per cent of group 3. The types marked B in Figure 1 had thickening corresponding to an earlier lesion of the collateral ligaments, while the types marked C were primarily luxated or subluxated.

Rupture of the middle of the volar fibrocartilage happens only rarely, and in such a case there exists the possibility of interposition of the distal piece, as illustrated in Figure 1, 2 B, C.

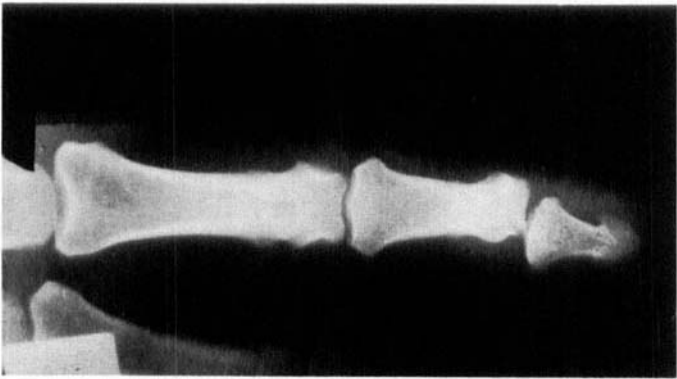


*Figure 2 a.*

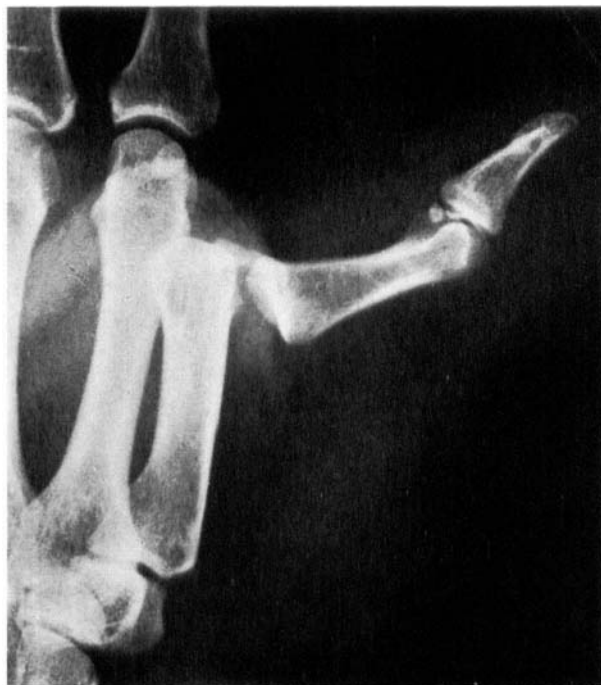

*Figure 2 b.*

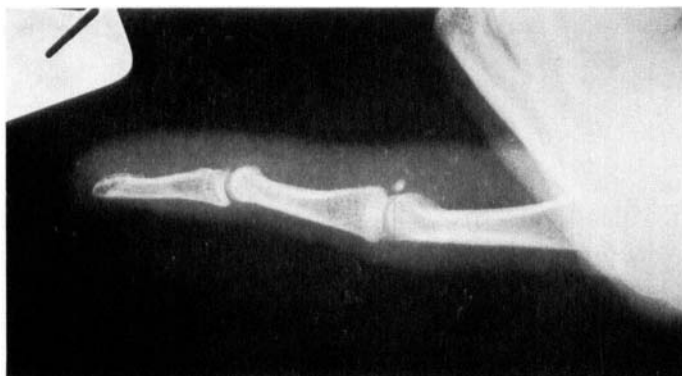*Unilateral, proximal lesion, type 1 A, healed with periost reaction, is shown in Figure 2 a, b.*



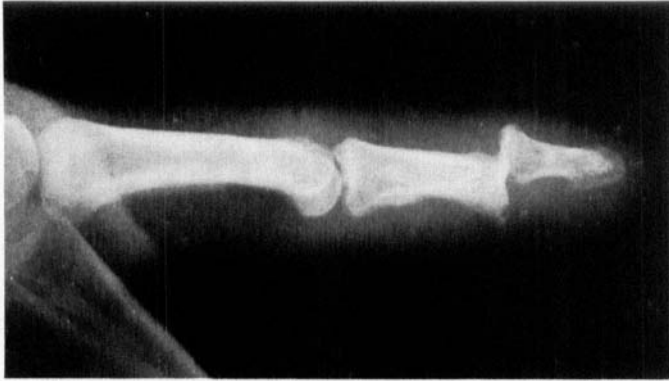*Figure 3 shows subluxation, type 1 C.*



*Figure 4 shows total, proximal rupture with instability, type 2 C, on a 38-year-old woman, who 6 months later had normal finger movements and no annoyance.*



*Figure 5 shows an unhealed fragment, type 3 A.*



*Figure 6 shows luxation with volar fragment, type 3 C.*

Some of the types can be demonstrated roentgenologically. Type 1 A can be so demonstrated, when simultaneously with the lesion some of the periosteum is displaced, giving rise to bone formation (see Figure 2 a, b).

*Movement* (average given in parentheses).

Group 1 had normal movement. Type 2 A often had a possibility of passive hyperextension of 15–30° (15°), and sequelae were correlated with more than 15° hyperextension. Types 2 B, C had an average of 5° hyperextension. Types 3 A, B often had 10–15° (7°) flexion defect and 10° (4°) increased extension. Type 3 C had 10–15° (10°) flexion and 10–15° (7°) extension defects.

*Prognosis*

The number of sequelae according to the particular types of lesions appears in Table 1. The frequency was 11 per cent for the proximal and 50 per cent for the distal lesions, immobilized for 3 to 4 weeks ( $P < 0.01$ ). There were significantly ( $0.05 > P > 0.02$ ) more women than men with sequelae in group 3, namely 66 per cent women against 33 per cent men, and for types 3 A, B without fragments, 83 per cent women against 17 per cent men ( $0.1 > P > 0.05$ ). The effect of immobilization for 3 to 4 weeks as compared with 2 weeks or shorter was significantly better for type 2 A. There was no difference for types 1 A–C. For the other types, the numbers were too small for the effect to be properly evaluated.

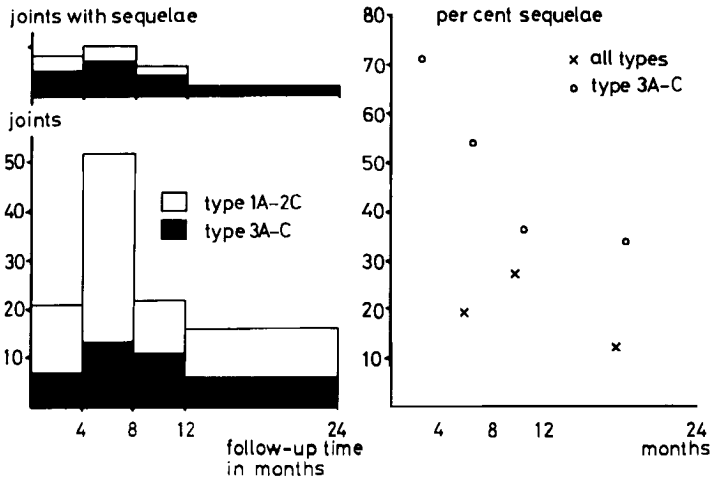


Figure 7. The relationship between follow-up time and sequelae for all injuries and for group 3.

Table 1. The table shows the great difference in frequency of sequelae between proximal and distal lesions. Fourteen of the joints in types 3 A, B had volar bone fragments, four had sequelae. In type 3 C, four had volar fragments and three had sequelae.

Immobilized 3-4 weeks										
Type	1 A	1 B	1 C	2 A	2 B	2 C	3 A	3 B	3 C	Total
Number	33	13	6	14	2	6	17	8	12	111
Seq.	+	2	1	1	2	1	6	3	5	21
	++								2	2
	+++		1					1	1	3
Immobilized 2 weeks or less										
Number	13		3	4		1	5		1	27
Seq.	+			2			3			5
	++			1		1				2
	+++									

Of 14 patients, nine women and five men with type 3 A, B lesions with volar fragments, all in P.I.P. joints, four had sequelae. All these were women, and the sequelae were related to unhealed fragments. Three out of four patients with type 3 C with fragments had movement

restrictions and annoyance. Figure 7 shows the relationship between the frequency of sequelae and follow-up time for group 3 and for all the injuries.

#### DISCUSSION

Only treatment results of materials consisting of types with bone fragments with or without luxation are published in the literature. Lee (1963) reported 22 cases with avulsed fragments without luxation, treated with plaster cast for 14 days. Of these 23 per cent had annoyance after 6 years. In the present work it was found that, after an average of 9 months' follow-up time, 28 per cent had sequelae, all correlated to unhealed fragments, while the frequency of sequelae without fragments was 50 per cent (the difference was not significant). Also included in Lee's cases are 7 fracture dislocations, treated for 18 days with plaster cast. Five had annoyance after 4 years. In this investigation 3 out of 4 with fracture dislocations had annoyance. Robertson et al. (1946) operated on 7 fracture dislocations and fixed the fragments with a three-wire system. They all improved but the observation time was only one week. Wilson & Rowland (1966) fixed 15 cases with Kirschner wires and obtained decidedly good results for the inhomogeneous materials. Moberg & Stener used pull-out wire in their case reports with good results.

Interposition of the distal piece of a ruptured fibrocartilage causes locking and flexion defects. For this reason, normal movement must be assured before the joint is immobilized. Proske (1926) and Stener (1963) have described lesions of this type discovered during the course of operations. The present study included a patient whose insufficient reposition was considered to be the cause of a 45° flexion defect. The patient did not desire an operation. Locking with extension defects can be caused by a lesion in the capsules between the collateral and the ligamentum accessorium (Kølle-Jørgensen 1962) and osteophytes on the capitulum in arthritic joints (Goodfellow 1961).

Previously, we have treated fibrocartilage lesions by immobilization for up to 5 weeks, later 2 to 4 weeks. Now we would recommend 2 weeks for proximal, unilateral lesions and 3 to 4 weeks for the others. An operation is recommended in those cases where X-rays during extension of the joint show dislocation of a volar fragment.

The reduction in immobilization time which can be realized in this manner in a material such as that under consideration here, where

43 per cent of the lesions are unilateral and proximal, has great economic significance in terms of sick-days saved.

#### SUMMARY

A total of 109 patients with 138 finger injuries with lesion of the volar fibrocartilage, with or without luxation or avulsed volar bone fragment, were examined an average of 8.4 months after the accident. Treatment consisted of immobilization in a flexible, foam-rubber-covered aluminium splint for 2 to 4 weeks.

Based on the clinical and roentgenological findings the lesions could be divided into three groups: unilateral proximal, bilateral proximal (total), and distal, and nine types, depending upon possible simultaneous damage to the collateral ligaments or luxation. An essential symptom in the dividing into groups has been the distinct soreness in the injured part of the fibrocartilage. Soreness can be demonstrated at the primary examination, and lasts for up to several years after healing. A considerably higher frequency of sequelae was found in the distal lesions and the frequency was twice as high for women as for men. In the case of distal lesions without luxation or avulsed volar fragment the difference due to sex was even greater.

It is concluded that unilateral proximal lesions require immobilization for only 2 weeks, whereas other types should be immobilized for 3 to 4 weeks. Fracture dislocations and lesions where X-rays during extension of the joint show dislocation of a volar bone fragment should be treated surgically, for example, by fixation with pull-out wire or, in the D.I.P. joints, possibly with arthrodesis.

#### ACKNOWLEDGEMENT

These studies were supported by the Danish Medical Science Research Council.

#### REFERENCES

- Gad, P. (1967) *The anatomy of the volar part of the capsules of the finger joints. J. Bone Jt Surg.* **49-B**, 362-367.
- Goodfellow, J. W. & Weaver, J. P. A. (1961) Locking of the metacarpo-phalangeal joints. *J. Bone Jt Surg.* **43-B**, 772-777.
- Kølle-Jørgensen, P. (1962) A ligamentous lesion causing locking of the metacarpo-phalangeal joint of the index finger. *Ugeskr. Læg.* **12**, 404-406.

- Lee, M. L. H. (1963) Intra-articular and peri-articular fractures of the phalanges. *J. Bone Jt Surg.* **45-B**, 103-109.
- London, P. S. (1971) Sprains and fractures involving the interphalangeal joints. *The Hand.* **3**, 155-158.
- Moberg, E. & Stener, B. (1953) Injuries to the ligaments of the thumb and fingers. *Acta chir. scand.* **106**, 166-186.
- Proske, R. (1926) Über die dorsale Luxation im Grundgelenk die 2.-5. Fingers. *Beitr. klin. Chir.* **136**, 528-536.
- Robertson, R. C., Cawley, J. J. & Faris, A. M. (1946) Treatment of fracture-dislocation of the interphalangeal joints of the hand. *J. Bone Jt Surg.* **28**, 68-70.
- Stener, B. (1963) Hyperextension injuries to the thumb-rupture of ligaments, fracture of sesamoid bones, rupture of flexor pollicis brevis. *Acta chir. scand.* **125**, 275-293.
- Wilson, J. N. & Rowland, S. A. (1966) Fracture-dislocation of the proximal interphalangeal joint of the finger. *J. Bone Jt Surg.* **48-A**, 493-502.

Correspondence to:

Dr. J. T. Møller  
Østervangsvej 26 C  
DK-8900 Randers  
Denmark

Translator: Robert Fluhr