

Department of Orthopaedic Surgery, The Central Hospital, Holstebro, Denmark.

ACUTE SLIPPED CAPITAL FEMORAL EPIPHYSIS

Treatment in 8 Cases

H. OVERGAARD NIELSEN

Accepted 27.v.75

The literature on slow gradual slipping of the upper femoral epiphysis is comprehensive: Oram (1952), Salenius & Kivilaakso (1968), Sørensen (1968), and others. In the case of acute (traumatic) slipped capital femoral epiphysis, however, reports presenting both the treatment applied and the results achieved are scanty. The treatment of this acute condition is also uncertain, often resulting in a defective hip (Ratliff 1968).

The present communication is intended as a contribution to the discussion on results obtained by various methods of treatment, compared to the results achieved by the treatment as laid down by Watson-Jones (1946).

MATERIAL AND METHOD

A total of 75 patients with slipped capital epiphysis have undergone treatment in the Orthopaedic Department of Holstebro Central Hospital during the period 1958-1972. Of this total, eight, all boys were acute cases according to the definition of Fahey & O'Brien (1965). The average age was 13 years (10 to 15 years). Five were of the obese type; six had some discomfort, for periods of from 3 weeks to 6 months, in the hip which subsequently received treatment. The trauma was moderate in all patients, but following the trauma, none of the patients was able to bear any weight on the leg on account of pain, and in all cases shortening of the leg was demonstrated as well as external rotation. Admission to the department took place from 1 to 5 days after the trauma, all patients being admitted originally as acute cases to the local hospital. The degree of slipping varied from $\frac{1}{4}$ to $\frac{1}{2}$ of the width of the neck of the femur.

Immediately after admission wire traction was applied through the tubercle of the tibia, with an average load of 6.5 kg (from 2 to 10 kg). Satisfactory reduction was obtained in an average of 12 days (6 to 23 days), and the position was immobilized by internal fixation with Kirschner wires, three of which were left in place for subsequent removal, at the earliest on closure of the epiphysis. Post-

Table 1. Physical examination and roentgenological findings on follow-up examination of eight patients treated for acute slipped capital femoral epiphysis by forceful traction followed by drilling through with Kirschner wire.

No.	Period of observation	Physical examination	Roentgenological findings
1.	12 years	Normal conditions	Slight deformation of the head and neck of femur.
2.	3 years	1 cm shortening otherwise normal.	Slight deformation of neck, head normal.
3.	11 years	Normal conditions	Normal conditions.
4.	6 years	1 cm shortening, loss of inward rotation	Slight deformation of the head and neck of femur.
5.	5 years	1.5 cm shortening, otherwise normal.	Slight deformation of the head and neck of femur.
6.	11 years	Severely limited motion.	Pronounced degenerative arthritis.
7.	2 years	Normal conditions	Normal conditions.
8.	3 years	Normal conditions.	Normal conditions.

operatively, traction was maintained by skin traction on the lower limb from 5 to 44 days, with a load of from 1 to 5 kg. The patients were then ambulatory with the help of a Thomas splint until the closure of the epiphyseal line. The time elapsing from the start of treatment until a roentgenogram showed closure of the epiphysis varied between 4 and 6 months.

RESULTS

The subsequent course has been free from complications, and in particular none of those who have received treatment have shown any signs of development of necrosis of the epiphysis.

The patients were followed up from 2 to 12 years after treatment (Table 1). None of them reported any discomfort from the treated hip. A physical examination showed normal motion of the hip in six patients; inward rotation was lost in two patients, and in one of these there was in addition limitation of flexion and outward rotation. In three patients there was shortening of from 1 to 1.5 cm. Roentgenograms showed normal conditions in three patients (Figure 1 a-c). In four patients the picture on the affected side, compared to the

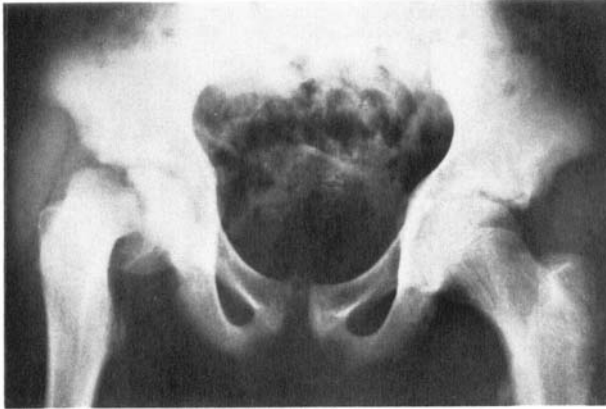


Figure 1 a. Roentgenological examination of both hip joints of a 15-year-old boy (No. 3), 1 day after minor trauma to the right hip, showing pronounced slipping on the right side.

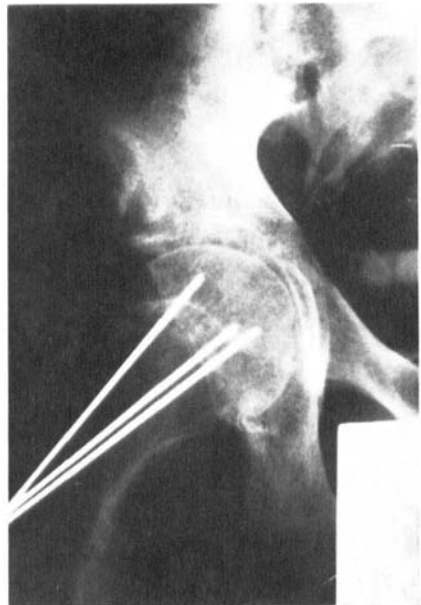


Figure 1 b. Same patient 23 days later, after traction and fixation with Kirschner wires.

healthy side, was one of slight to moderate deformity of the femoral neck, in the form of shortening, together with flattening of the head (Figure 2 a-c). One patient had obvious signs of degenerative arthritis, with narrowing joint space, sclerosis and exostosis (Figure 3 a-c). On follow-up examination, two of the patients had slight lateral instability

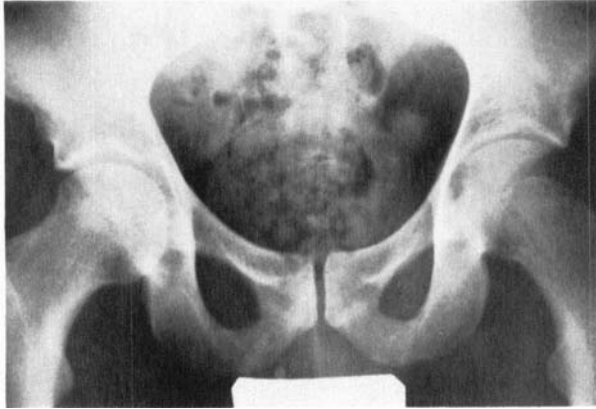

Figure 1 c. Same patient 11 years later, showing normal conditions.

in the extended knee. This must be ascribed to the forceful traction during the treatment. The looseness did not give rise to any complaints. Two patients who were of the obese type at the time of treatment had developed normal body build by the time of follow-up, whereas three patients were still severely obese.

It might be mentioned that 7 months after treatment on the one side, patient no. 8 developed acute slipped capital femoral epiphysis on the

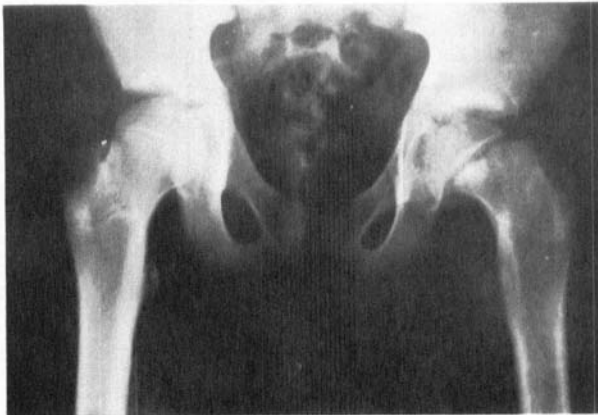

Figure 2 a. Roentgenological examination of both hip joints of a 12-year-old boy (No. 1), a few hours after a minor trauma to the left hip, showing pronounced slipping on that side.

Figure 2 b. Same patient 6 days later, after traction and fixation with Kirschner wires.

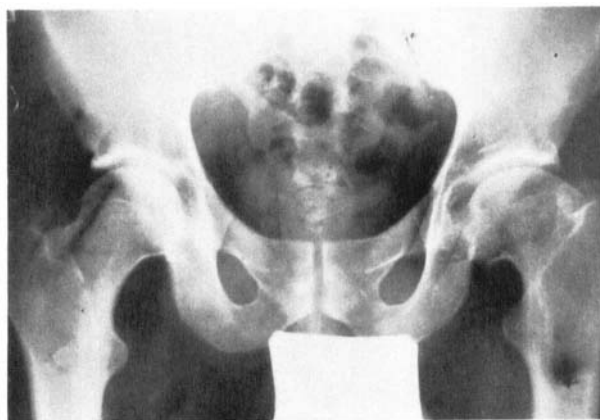
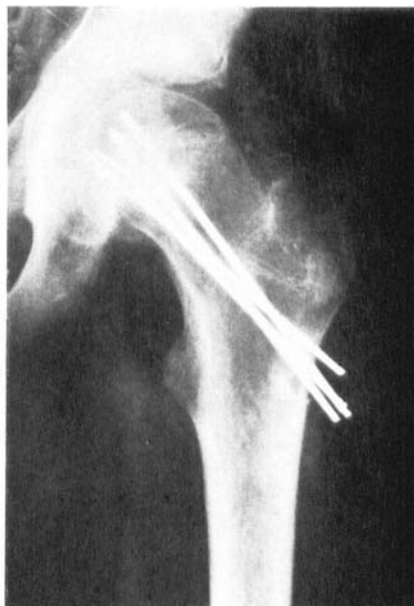

Figure 2 c. Same patient 12 years later. Flattening of the head of femur and shortening of the neck so that the trochanter major almost reaches the same level as the head.

other side. The treatment of this hip has not been included in the present investigation, as the period of observation was less than 2 years, but in this case also no necrosis of the head of the femur was found to have developed 12 months after the start of treatment.

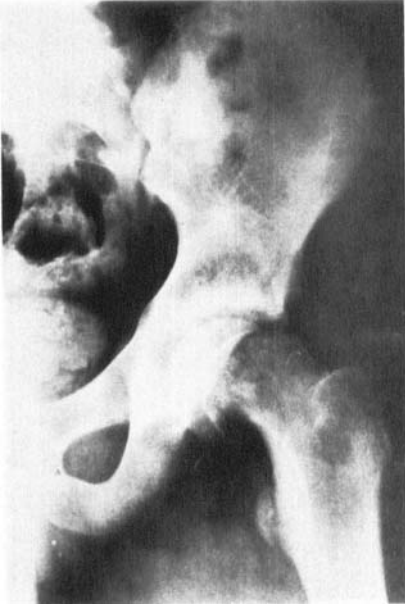

Figure 3 a. Roentgenological examination of the left hip joint of a 14-year-old boy (No. 6), a few hours after a minor trauma to the left hip, showing pronounced slipping.

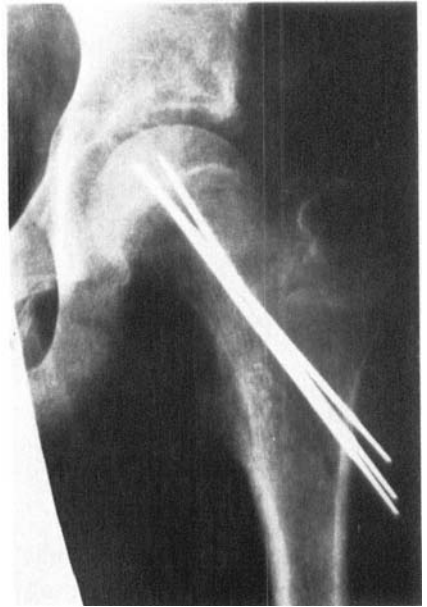

Figure 3 b. Same patient 15 days later, after traction and fixation with Kirschner wires.

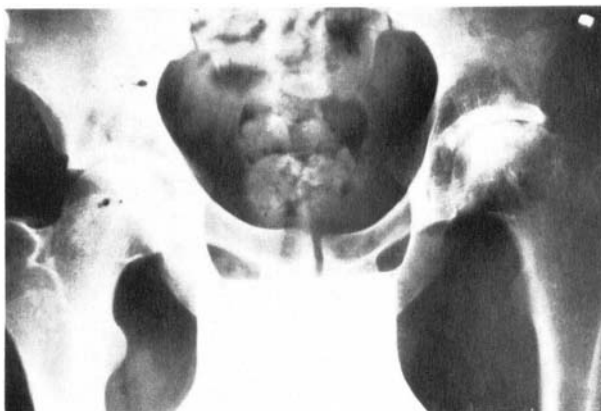

Figure 3 c. Same patient 11 years later, with pronounced degenerative arthritis on the left side, compared with the right hip.

DISCUSSION

Traumatic epiphyseolysis of the proximal end of the femur is far more uncommon than slow, gradual slipping; in the literature it is reported as amounting to 5–25 per cent of all cases. In acute slipping, there is the possibility of achieving an anatomically correct reduction, as reparatory changes which hinder this have not yet occurred. Reduction must be regarded as being of great significance in avoiding subsequent development of degenerative arthritis. The reduction may be by manipulation under general anaesthesia (Barash et al. 1971, Casey et al. 1972, Fahey & O'Brien 1965), but it is not unusual for the treatment to be accompanied by serious complications in the form of necrosis of the epiphysis. Casey et al. (1972) have five cases of necrosis of the epiphysis in 12 patients treated. Schein (1967) has two cases of necrosis of the femoral head in four patients treated by manipulation. Watson-Jones (1946) reports 25 per cent. Another method of treatment of slipping is open reduction. In this form of treatment, a figure as high as 75 per cent has been reported for the risk of necrosis of the head of the femur (Schein 1967). We have employed a third treatment procedure in order to achieve reduction, viz. forceful extension at the hip with the aid of traction on the tubercle of the tibia, and no development of necrosis of the head of the femur has been observed with this treatment. Schein (1967) and Casey et al. (1972), in treatment of three and twelve patients respectively, likewise found no cases of necrosis of the head following traction treatment.

After reduction, the epiphyseal head must be immobilised by fixation until the epiphyseal line has disappeared, using one or another form of osteosynthesis. Thin Kirschner wires are considered most suitable for this, as more massive osteosynthesis material might push the head away from the neck, thereby increasing the risk of traumatising the blood supply to the head, resulting in necrosis of the head (Schein 1967). With regard to late results, Fahey & O'Brien (1965) report satisfactory results in $\frac{2}{3}$ of their patients after manipulation or traction followed by internal fixation, the period of observation varying from 2 to 16 years. In the material of Barash et al. (1971), $\frac{3}{4}$ of the results were satisfactory after manipulation or traction plus fixation. Their material comprises eight patients with a period of observation of from 2 to 8 years. In evaluating late results, it must be taken into consideration that the various series are small, and that the periods of observation are often relatively short.

In the present material, with a period of observation of from 2 to 12 years, roentgenologically normal conditions were found in three out of eight patients and four of the eight patients had slight to moderate deformation of the neck and head of the femur, changes which may lead to the development of degenerative arthritis on account of the altered weight-bearing conditions in the hip joint. One of the eight patients had pronounced degenerative arthritis.

With a view to avoiding the development of necrosis of the head of the femur, the results of the present study and the review of other materials would appear to suggest that the treatment of choice is traction (Schein 1967, Casey et al. 1972).

SUMMARY

The results are reported of the treatment of eight cases of acute (traumatic) slipped capital femoral epiphysis, reduced by forceful traction on the tubercle of the tibia, followed by drilling through with Kirschner wires. No necrosis of the epiphysis developed among the eight cases. In the light of these results, this therapy is recommended in cases of acute slipping of the capital femoral epiphysis. On the other hand, as far as the late complications are concerned, such as degenerative arthritis, the late results are probably no better than those obtained with other forms of treatment.

REFERENCES

- Barash, I. L., Galante, J. O. & Ray, R. D. (1971) Acute slipped capital femoral epiphysis. *Clin. Orthop.* **79**, 96-103.
- Casey, B. H., Hamilton, H. W. & Bobechko, W. P. (1972) Reduction of acutely slipped upper femoral epiphysis. *J. Bone Jt Surg.* **54-B**, 607-614.
- Fahey, J. J. & O'Brien, E. (1965) Acute slipped capital femoral epiphysis. *J. Bone Jt Surg.* **47-A**, 1105-1125.
- Oram, V. (1952) *Epiphysiolytis capitis femoris*. Thesis, Universitetsforlaget i Aarhus.
- Ratliff, A. H. C. (1968) Traumatic separation of the upper femoral epiphysis in young children. *J. Bone Jt Surg.* **50-B**, 757-770.
- Salenius, P. & Kivilaakso, R. (1968) Results of treatment of slipped upper femoral epiphysis. *Acta orthop. scand.*, Suppl. 114.
- Schein, A. J. (1967) Acute severe slipped capital femoral epiphysis. *Clin. Orthop.* **51**, 151-166.
- Sørensen, H. K. (1968) Slipped upper femoral epiphysis. *Acta orthop. scand.* **39**, 499-517.
- Watson-Jones, R. (1946) *Fractures and joint injuries*. 3rd ed. vol. 2, p. 612. E. & S. Livingstone, Edinburgh.

Key words: acute slipped capital femoral epiphysis

Correspondence to:

Reservelæge Henning Overgaard Nielsen
Valmuevej 61, DK-7500 Holstebro
Denmark