

Department of Orthopaedic Surgery, Lund University Hospital, Sweden.

THE CARPAL TUNNEL SYNDROME

A Retrospective Study of 400 Operated Patients

CARL-HENRIK HYBBINETTE & LENNART MANNERFELT

Accepted 15.ii.75

The carpal tunnel syndrome (CTS) is the most common and the most important of all the entrapment neuropathies of the extremities. Space-reducing lesions in the carpal tunnel cause a rise in pressure which provokes symptoms from the pressure-sensitive median nerve. The symptoms are referred to as CTS and consist of the triad pain, sensory disturbance and thenar atrophy (Brain et al. 1947, Kopell & Thompson 1963).

History

This condition was first described in 1853 by Paget. Later Marie & Foix (1913) gave a histological description of the changes in the nerve, intraneural sclerosis and destroyed myelinous fibres and suggested operative treatment which was first carried out by Woltman in 1941. Cannon & Love published in 1946 a series of nine patients who had had surgical treatment. The number of articles on this subject has increased during the years but there are only a small number of studies on the late results of relatively large series involving surgical treatment, and the results vary to some extent among these reports. Therefore we thought it would be of interest to analyse a fairly large series of operations performed in our clinic.

M A T E R I A L

During the years 1962-1971, 506 cases of carpal tunnel syndrome in 400 patients have been operated upon at the Hand Surgical Unit of the Orthopaedic Clinic in Lund. As in other materials (Phalen 1972) there is a predominance of women who comprise more than 70 per cent of the total number of patients (Table 1). The youngest patient was 18 years of age and the oldest 85. The majority, 61 per cent,

were between 41 and 60 years of age (Table 2). Their mean age was 53 years. The number of operations have increased over the years.

Table 1. Relationship between sex and operated side in 400 patients with CTS.

	Right	Right+left	Left	Total
Women	148	72	62	282
Men	64	22	32	118
Total	212	94	94	400

Table 2. Sex and age distribution in 400 patients operated for CTS.

Sex/Age	-20	21-30	31-40	41-50	51-60	61-70	71-80	81-	Total
Women	2	21	26	63	104	47	15	4	282
Men	-	4	5	23	43	35	8	-	118
Total	2	25	31	86	147	82	23	4	400

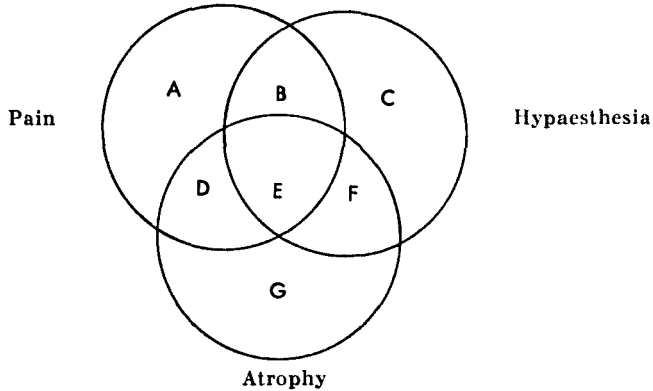
After a review of all the records we sent follow-up letters with questionnaires to all patients. Enquiries were made regarding pain, decreased sensibility, the condition of the scar, rheumatoid arthritis or other complaints in the hand. Nineteen patients had died and 11 could not be traced. Thus 30 patients with 41 operated hands were excluded from the material when considering the late results. The remaining 370 patients with 465 operated hands had a mean observation time of 3.7 years (1-11 years).

DIAGNOSIS

The diagnosis was established on the basis of both the history and a physical examination.

Patients' history

The patients complained of paraesthesia, often of a tingling character, occurring in the median distribution of the hand. The paraesthesia often started in the third finger, and was characteristically nocturnal. These symptoms could develop into real pain, sometimes radiating proximally into the fore- and upper arm. The nocturnal pain awakened the patient, who tried to relieve the symptoms by allowing the hand to drop over the bedside, by shaking the hand or by soaking it in a handbath. During the morning the symptoms usually diminished but they could return during active use of the hand. Later, sensation decreased, skilled finger movements were lost, weakness of the hand added to the other symptoms and sometimes the patient noticed a wasting of the thumb muscles.



	A	B	C	D	E	F	G
All 506 operations	142	164	-	26	167	5	2
Rheumatoid arthritis, 196 operations	65	59	-	14	58	-	-
Colles' fracture, 28 patients	2	14	-	-	11	1	-

Figure 1. Distribution of the various symptoms in 400 CTS patients.

Physical examination

Pain. The nocturnal pain could be reproduced in the daytime in two ways, either by a venous stasis of the arm (Vainio 1957) or by non-forced complete wrist flexion, as described by Phalen (1951). A tourniquet inflated to 100 mmHg around the upper arm was used in the venous stasis test. One or both of these methods could usually reproduce or exaggerate the numbness and tingling pain in the median distribution of the hand within 3 minutes, most often within 30-60 seconds. The test using venous stasis was performed on 120 arms, and was positive in 106, of which 102 were cured by the operation.

Sensation. In 336 hands (66 per cent) there was subjective decreased sensation. Hypaesthesia in the median distribution of the hand was tested with touch, pin-prick and/or two-point discrimination. In some few cases burns resulted because of the diminished sensation.

Atrophy. Thenar atrophy involving the opponens pollicis and/or the abductor pollicis brevis was noticed in 198 hands (39 per cent). The best way to detect small degrees of thenar atrophy was to observe the thenar eminence in profile.

Weakness. Occasionally only decreased strength in these muscles was observed, measured against breaking force with an Intrinsicmeter (Mannerfelt 1966). Some patients could not oppose the thumb.

Combination of symptoms. Almost one third of all the operated cases had only pain, one third had pain and hypaesthesia and one third had pain, hypaesthesia and atrophy. Among the patients with rheumatoid arthritis there were more cases with only pain than pain combined with other symptoms. Among the cases with carpal tunnel syndrome resulting after a Colles' fracture only a minority had pain alone and most of the patients had pain, hypaesthesia and often also atrophy (Figure 1).

Duration of symptoms. The duration of symptoms in 318 out of 506 cases varied.

Slightly less than three quarters had had symptoms for less than 2 years, but five patients had had symptoms for more than 20 years. No certain correlation between the duration and the combination of the symptoms could be shown.

Electrodiagnosis. Electrodiagnostic determination of the conduction time for the sensory and the motor fibres of the median nerve and electromyographic studies were used in 199 patients, often when there was diagnostic uncertainty. In 180 of these patients the results revealed a carpal tunnel syndrome. In 19 patients with 22 operated hands these investigations were normal, but other objective signs made a diagnosis of carpal tunnel syndrome probable and 18 of the 22 operated hands were cured after the operation. Thirteen of these 22 hands had pain only, seven had hypaesthesia and two had atrophy.

Earlier diagnosis

Cervical rhizopathy may have some similarities with the carpal tunnel syndrome (Campbell 1962). 82 of the 400 patients had been treated earlier for rhizopathy, often over many years, the longest being 30 years. 75 of these 82 patients were completely pain-free in their hands after operation for CTS, thus excluding a diagnosis of rhizopathy. Some few hands with oedema had been diagnosed as Dupuytren's contracture.

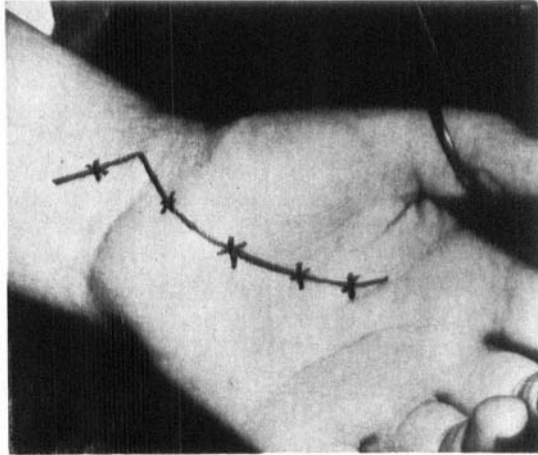
Table 3. The different conditions producing CTS in 400 patients.

Condition	No. of patients			No. of hands
	Women	Men	Total	
Tenosynovitis in rheumatoid arthritis	106	45	151	196
Tenosynovitis, non-specific chronic or fibrosis	104	34	138	170
Fractura radii, Colles' fracture	22	6	28	32
Carpal arthrosis, pseudarthrosis of scaphoideum	2	11	13	13
Torsion or blunt trauma	4	7	11	12
Diabetes mellitus	8	3	11	17
Thyroid diseases	8	—	8	9
Pregnancy	7	—	7	8
Contraceptive pill	9	—	9	15
Ganglion	3	4	7	7
Muscle bellies in the carpal tunnel	—	3	3	3
Lipoma in the carpal tunnel	1	—	1	1

Pathology

Tenosynovitis of the flexor tendons combined with rheumatoid arthritis was the most common cause of the syndrome, occurring in almost 30 per cent of the patients. Thickening of the flexor synovialis was an almost regular finding at operation. Of the 506 cases treated surgically, 112 had biopsy specimens taken of the flexor synovialis. The pathologists reported that 20 of these were rheumatoid arthritis, reported above, and the rest were dominated by those with a chronic non-specific inflammation, many had fibrosis of the synovialis or oedema and in

Figure 2. Incision used for splitting the transverse carpal ligament.



a minority there were no pathologic changes. In some patients various systemic factors, diabetes mellitus or myxoedema, may have contributed to the syndrome, almost always combined with thickening of the synovialis. Retention of water during pregnancy or when taking contraceptive pills was sometimes a cause of the syndrome. Fractures and other injuries about the wrist could be causative factors. In the traumatic group women dominated in the patients with Colles' fracture and men in the patients with carpal arthrosis caused by previous fractures, mostly of the scaphoid bone. Rare causes of increase in the volume of the contents of the carpal tunnel were ganglions, lipomas and abnormal muscle bellies in the tunnel. In some patients nothing abnormal was found at operation (Table 3).

TREATMENT

Medical treatment

Not every patient with CTS needs surgical treatment (Mumenthaler 1964). Splinting of the wrist, analgetics, diuretics, antiflogistics or injections of steroids into the carpal tunnel can help, but not very often and especially not when the symptoms have been present for a long period of time (Vaughan-Jackson 1966).

Surgical treatment

Operations were performed on patients with pains which were severe or of long duration, and on patients with decreased sensation or thenar atrophy. However, in pregnancy we often waited for possible recovery after delivery (Wilkinson 1960).

All the operations were carried out in a bloodless field and either under brachial plexus block or general anaesthesia. Seventeen surgeons performed the operations; one (Mannerfelt) carried out 211 operations, eight surgeons performed 26-43 operations each and the rest fewer than eight operations. The same operative technique has been used by all surgeons over the last 8 years. We used a curved incision following the thenar base (Figure 2) to expose the transverse carpal ligament which was divided at its ulnar border. A small strip of it was resected. The

distal part of the tendon of *m. palmaris longus* was resected. Neurolysis of the thenar motor branch was always performed. Various anatomical anomalies were found during this manoeuvre, reported earlier by Mannerfelt & Hybbinette (1972). The bottom of the carpal tunnel was inspected to exclude tumours, ganglions or bony spurs (Brooks 1952, Mannerfelt & Norman 1969, Inglis et al. 1972). Tenosynovectomy was carried out when we found pronounced thickening of the flexor synovialis. Exact suture of the skin with an atraumatic technique was followed by immobilization of the wrist in a splint for about 10 days.

Very often a compression of the median nerve was observed under the ligament, and in 185 cases a pseudoneuroma proximal to the compression was reported. In 34 cases no compression was observed but 29 of these cases became pain-free.

Postoperative care. The hand was kept elevated for 24 hours. A sling was avoided to prevent swelling of the hand. Early active finger flexion and extension were of the utmost importance in patients with rheumatoid arthritis or marked tenosynovitis in order to prevent postoperative adhesions of the flexor tendons.

RESULTS

Early results

The relief of pain was often dramatic. The patient noticed a great amelioration of the symptoms and had an undisturbed night's rest which had not been possible for a long time. Total or almost total relief from the pain was reported in 455 of the 506 operated cases soon after the operation. The majority of the not completely successful cases had minor paraesthesias which were of more than 3 months postoperative duration. Many patients were relieved from the CTS but experienced discomfort caused by other diseases: viz., 12 cases of rheumatoid arthritis, eight cases of cervical rhizopathy, seven cases of diabetic polyneuropathy, six cases of idiopathic polyneuropathy, one patient with intraneural posttraumatic fibrosis and one with pain after Colles' fracture.

Long-term results

Pain. The patients who replied that they did have pain were examined in all cases, except two who did not wish to participate in the follow-up.

In the late examination among the 370 patients with 465 operations seven patients had pain which could be attributed to a median nerve irritation in the carpal tunnel.

Pain of another origin was found in 40 patients with 46 operated hands. Of these patients, 17 had rheumatoid arthritis, 12 cervical rhizopathy and five discomfort after a fracture. No significant differ-

ences in results between the operations performed by the different surgeons could be found. 98 per cent of the patients were thus relieved from the pain caused by a carpal tunnel syndrome. The age of the patient or duration of the symptoms did not seem to influence the result.

Sensation. The return of normal sensation was usually slower than the regression of the pain. In the late examination group 256 patients with 311 operations had hypaesthesia preoperatively. It was found that 24 patients with 27 operated hands still had hypaesthesia because of nerve affection in the carpal tunnel. Of these, nine cases were more pronounced and the rest only slightly with a small decrease in sensation at most, often at the top of the third finger. Ninety per cent of the patients with hypaesthesia were thus relieved after the operation.

Atrophy. The general impression was that the thenar atrophy usually regressed although it sometimes tended to be permanent. This aspect was not examined systematically in this work but is now being studied in a prospective study at the clinic.

Reoperations

It was necessary to re-explore 18 hands in 17 patients because of pain. One of these patients was reoperated last year and is thus not included in the 10-year survey. In four cases it was found that the distal part of the transverse carpal ligament was still intact. In other cases we found fibrous proliferation and adhesions within the carpal tunnel and/or hypertrophied tenosynovitis of the flexor tendons, as did also Langloh & Linscheid (1972). An epineurectomy was performed in only one patient, reoperated last year.

The patients with incomplete sectioning of the transverse carpal ligament had incomplete or no relief after the first operation and were reoperated after a mean period of time of 5 months (range 1-9). The patients with tenosynovitis or fibrous proliferation usually obtained relief after the first operation but later the carpal tunnel syndrome returned and they were reoperated after an average period of 19 months (range 4-48).

The mean observation time of these 18 reoperations was 3.4 years, ranging from 10 months to 7 years.

The results of the reoperations with regard to pain were good in 10 hands, fair (improved condition) in seven and poor in one (with an intraneural fibrosis following a severe compression trauma).

Complications

Two patients operated in the first years with a transverse incision sustained an injury to the sensory palmar branch and one to the thenar branch of the median nerve. Eight patients considered the scar to be ugly; six of these developed keloid in the scar and were operated with excision of the scar. Three patients developed a shoulder-hand-finger syndrome postoperatively.

Carpal tunnel syndrome associated with some other conditions

Rheumatoid arthritis. In our material this was a common cause of CTS. These patients often had pain as a result of tenosynovitis and arthritis in the hand but a careful investigation often revealed the CTS as also mentioned by Barnes & Currey (1967). Bilateral operation was rather common, 42 patients out of 151, compared with 54 out of 249 non-rheumatoid patients. Fifteen patients (in whom CTS was the initial symptom) developed rheumatoid arthritis after the operation.

Colles' fracture. The syndrome could start immediately after the accident (though this could not be verified) or after some time because of malposition, abundant callus, oedema, intra-articular exudate or haematoma (Abbot & Saunders 1933, Kinley & Evarts 1968, Frykman 1967). There could be a regression of the symptoms when the patient used the hand, and one therefore waited 1-2 months before operating. 28 patients with Colles' fracture were operated. The results were good in 21, fair in three and the rest did not have CTS, but symptoms related to the fracture.

Peripheral neuropathies. When the nerve was involved in a peripheral neuropathy, here most often diabetes mellitus, it was more susceptible to the various causes of carpal tunnel syndrome. There were 11 patients with diabetes mellitus; three of the women also had rheumatoid arthritis and two of the men some trauma as an additional factor. The postoperative period was often protracted before they became pain-free, and one of the poorest results was in a diabetic operated bilaterally twice, the poor result being due to the polyneuropathy.

Mistakes

Eight of the patients were not helped at all and are considered as being wrongly diagnosed. The true diagnosis was cervical rhizopathy in four, neurosarcoma of the brachial plexus in one, syringomyelia in one,

post-radiologic damage of the brachial plexus in a women with malignancy of the breast, and one aneurysm of the subclavian artery.

DISCUSSION

This series with 506 operations in 400 patients over a period of 10 years is one of the largest reported in the literature. Phalen (1972) reported on 235 operated wrists, Yamaguchi et al. (1965) 459 cases, Czeuz et al. (1966) 430 operated patients and from Europe Semple & Cargill (1969) 150 operated patients. From Scandinavia, Rasmussen & Stougård (1969) reported on 78 patients and Rietz & Örne (1967) on 65 patients.

This series differs somewhat from the others in that rheumatoid arthritis was an important aetiological factor, accounting for 151 of the 400 operated patients. One specific factor mentioned previously is the contraceptive pill. In this series 49 women were less than 40 years of age, and of these nine used the pill and had no other possible cause of the syndrome. There have also been many more young women with this combination of the carpal tunnel syndrome and the pill, but where there was no indication for surgery.

The duration of the symptoms, the age of and the distribution of the patients are about the same as in other reports, such as Phalen's (1972).

The test with venous stasis has proved very valuable in establishing the diagnosis and we think it is as good as the wrist-flexion test. Like Tanzer (1959), we consider the tourniquet test described by Gilliatt & Wilson (1953), provoking ischaemia of the hand, to be uncertain.

The majority of the patients had disabling symptoms with pain and decreasing sensation. Operation was not carried out on patients with only vague symptoms, although none of our patients became worse after the operation. In a similar manner to Lipscomb (1959) and Lichtman et al. (1968) operative treatment was not restricted.

The transverse carpal ligament should be divided under direct vision. Blind splitting of the ligament is not recommended because it is often not complete and because it makes inspection of the carpal tunnel impossible. Neurolysis of the thenar motor branch is necessary, at least in the patients with atrophy. We do not think that internal neurolysis as suggested by Curtis & Eversman (1973) is necessary as a routine operation, at least not at the first operation. Like Phalen (1972) we think that it may be dangerous because even minor trauma may result in painful causalgia.

The result of the operation is mostly very good considering relief of

the pain and amelioration of the hypaesthesia. Many cases with thenar atrophy will regenerate postoperatively. Our findings do not agree with those of Semple & Cargill (1969), who reported failure in 25 per cent of the patients, perhaps because of irreversible neuropathy. We agree with Phalen (1966) and Rietz & Önné (1967) that it is a rewarding and successful operation.

SUMMARY

Carpal tunnel syndrome is a common cause of pain, often combined with hypaesthesia in the median distribution of the hand and atrophy of the thenar. We describe pre-, per-, and post-operative findings in 400 patients. Venous stasis is a good diagnostic method in establishing the syndrome. Operative treatment generally gives freedom from pain and normalization of sensibility.

REFERENCES

- Abbott, L. C. & Saunders, J. B. C. (1933) Injuries of the median nerve in fractures of the lower end of the radius. *Surg. Gynec. Obstet.* **57**, 507-516.
- Barnes, C. G. & Currey, H. L. F. (1967) Carpal tunnel syndrome in rheumatoid arthritis. *Ann. rheum. Dis.* **26**, 226-233.
- Brain, R. W., Wright, A. D. & Wilkinson, M. (1947) Spontaneous compression of both median nerves in the carpal tunnel. *Lancet* **i**, 277-282.
- Brooks, T. (1952) Nerve compression by simple ganglion. *J. Bone Jt Surg.* **34-B**, 391-400.
- Campbell, E. D. R. (1962) The carpal tunnel syndrome, investigation and assessment of treatment. *Proc. roy. Soc. Med.* **55**, 401-405.
- Cannon, B. W. & Love, J. G. (1946) Tardy median palsy, median neuritis, median thenar neuritis amenable to surgery. *Surgery* **20**, 210-216.
- Curtis, R. C. & Eversman, W. W. (1973) Internal neurolysis as an adjunct to the treatment of the carpal-tunnel syndrome. *J. Bone Jt Surg.* **55-A**, 733-740.
- Czeuz, K. A., Thomas, E. J., Lambert, E. H., Love, J. G. & Lipscomb, P. R. (1966) *Mayo Clin. Proc.* **41**, 232-241.
- Frykman, G. (1967) Fracture to the distal radius including sequelae. *Acta orthop. scand.*, Suppl. 108.
- Gilliatt, R. W. & Wilson, T. G. (1953) A pneumatic tourniquet test in the carpal tunnel syndrome. *Lancet* **ii**, 595-597.
- Inglis, A. E., Straub, L. R. & Williams, C. S. (1972) Median nerve neuropathy at the wrist. *Clin. Orthop.* **83**, 48-54.
- Kinley, D. L. & Evarts, C. M. (1968) Carpal tunnel syndrome due to a small displaced fragment of bone. *Cleveland Clin. Quart.* **35**, 215-222.
- Kopell, P. H. & Thompson, W. A. (1963) *Peripheral entrapment neuropathies*. Williams and Wilkins Co., Baltimore.
- Langloh, N. D. & Linscheid, R. L. (1972) Recurrent unrelieved carpal-tunnel syndrome. *Clin. Orthop.* **83**, 41-47.

- Lipscomb, P. R. (1959) Tenosynovitis of the hand and the wrist. *Clin. Orthop.* **13**, 164-181.
- Litchman, H. M., Silver, C. M. & Simon, S. D. (1968) The carpal tunnel syndrome. *Int. Surg.* **50**, 269-275.
- Mannerfelt, L. (1966) Studies on the hand in ulnar nerve paralysis. *Acta orthop. scand.*, Suppl. 87, 63-68.
- Mannerfelt, L. & Norman, O. (1969) Attrition ruptures of flexor tendons in rheumatoid arthritis caused by bony spurs in the carpal tunnel. *J. Bone Jt Surg.* **51-B**, 270-277.
- Mannerfelt, L. & Hybbinette, C. H. (1972) Important anomaly of the thenar motor branch of the median nerve. *Bull. Hosp. Jt Dis.* **33**, 15-21.
- Marie, P. & Foix (1913) Atrophie isolée de l'éminence thénar d'origine névritique. *Rev. neurol.* **26**, 647-649.
- Mumenthaler, M. (1964) Die Therapie des Carpal Tunnel Syndroms. *Dtsch. med. Wschr.* **89**, 2424-2425.
- Paget, J. (1853) *Lectures on surgical pathology*, p. 43. Longman, Brown, Green and Longmans, London.
- Phalen, G. S. (1951) Spontaneous compression of the median nerve at the wrist. *J. Amer. med. Ass.* **145**, 1128-1133.
- Phalen, G. S. (1966) The carpal tunnel syndrome. *J. Bone Jt Surg.* **48-A**, 211-228.
- Phalen, G. S. (1972) The carpal tunnel syndrome. *Clin. Orthop.* **83**, 29-40.
- Rasmussen, J. & Stougård, J. (1969) Karpaltunnelsyndrom. *Nord. Med.* **81**, 366-370.
- Rietz, K. A. & Önne, L. (1967) Analysis of sixty-five operated cases of carpal tunnel syndrome. *Acta chir. scand.* **133**, 443-447.
- Semple, J. C. & Cargill, A. O. (1969) Carpal-tunnel syndrome. *Lancet* **i**, 918-919.
- Tanzer, R. C. (1959) The carpal tunnel syndrome. *Clin. Orthop.* **II**, 171-180.
- Vainio, K. (1957) Carpal canal syndrome caused by tenosynovitis. *Acta rheum. scand.* **4**, 22-27.
- Vaughan-Jackson, O. I. (1966) Carpal tunnel compression of the median nerve. *Clinical surgery. The hand*, pp. 197-201. Butterworth, London.
- Wilkinson, M. (1960) The carpal tunnel syndrome in pregnancy. *Lancet* **ii**, 453-454.
- Woltman, H. W. (1941) Neuritis associated with acromegaly. *Arch. Neurol. Psychiat. (Chic.)* **45**, 680-682.
- Yamaguchi, D. M., Lipscomb, P. R. & Soule, E. H. (1965) Carpal tunnel syndrome. *Minn. Med.* **48**, 22-26.

Key words: median nerve compression; aetiology; diagnostic findings; operative treatment; short and long-term results

Correspondence to:

Carl-Henrik Hybbinette
Department of Orthopaedic Surgery
Lund University Hospital
Lund, Sweden

Lennart Mannerfelt
Goldenbuhl Krankenhaus
Villingen im Schwarzwald
West Germany