

Department of Orthopaedics, University of Athens, Accident Hospital K.A.T.,
Kifissia, Athens, Greece.

BONE LESIONS IN PIGMENTED VILLONODULAR SYNOVITIS

TH. PANTAZOPOULOS, Z. STAVROU, C. STAMOS, G. KEHAYAS &
G. HARTOFILAKIDIS-GAROFALIDIS

Accepted 7.iii.75

Pigmented villonodular synovitis is a rather rare disease affecting the synovial membrane of various joints, bursae and tendon sheaths. It may appear in either a diffuse or a localised form. The aetiology of this condition is unknown, although various theories have been postulated, such as repeated minor trauma to the synovium (Greenfield & Wallace 1950, Wright 1951, Fisk 1952, Young & Hudacek 1954), a local disturbance in lipid metabolism (Atmore et al. 1956, Kumon 1969, Hirohara & Morimoto 1971), and an inflammatory process (Jaffe 1964, Aegerter & Kirkpatrick 1968, Byers et al. 1968). Infection, however, is accepted as the cause of the disease by most writers, but the aetiological agent is still unknown.

The pathological findings in the early stages of the disease consist of a non-specific inflammatory reaction of the synovial membrane which becomes oedematous and thickened. As the proliferative reaction progresses several cells are found infiltrating the synovium as plasma cells, histiocytes, fibroblastic cells and giant cells. Lipid-bearing xanthoid cells and macrophages are also seen. The stroma resembles undifferentiated mesenchymal tissue.

Macroscopically the synovial membrane is oedematous and hypertrophic, with villus or nodular proliferation and with a brown colour due to pigmentation with haemosiderin.

Pigmented villonodular synovitis is a monoarticular condition usually affecting the knee and the phalangeal joints, whereas the hip, elbow, ankle and other joints are rarely involved (Byers et al. 1968, Nilsson & Moberger 1969). Bone lesions in pigmented villonodular synovitis are only occasionally seen in the joints usually affected by the disease. They are not uncommon, however, in the rarely involved joints (Jaffe 1960, Chung & Janes 1965). But even in these joints only a few cases

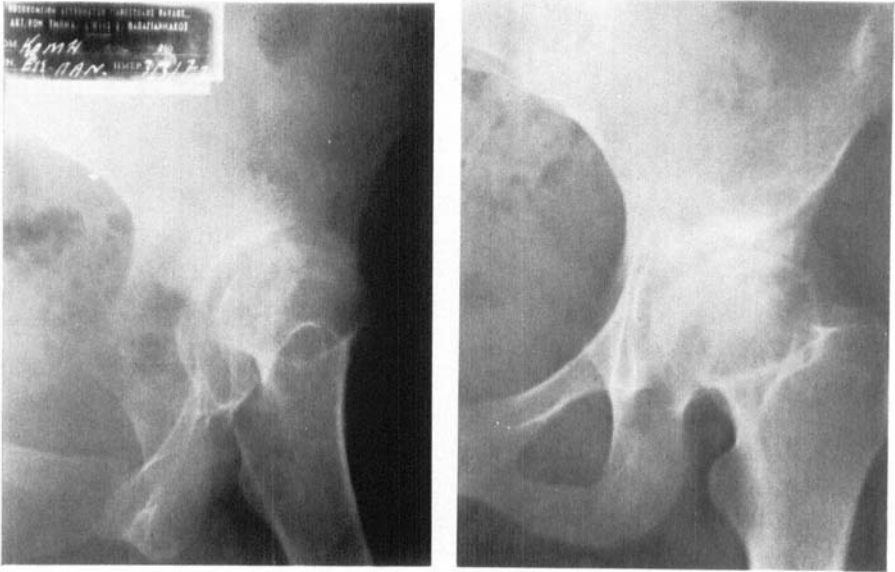


Figure 1. A-P and lateral radiographs of left hip with pigmented villonodular synovitis showing bone lesions.

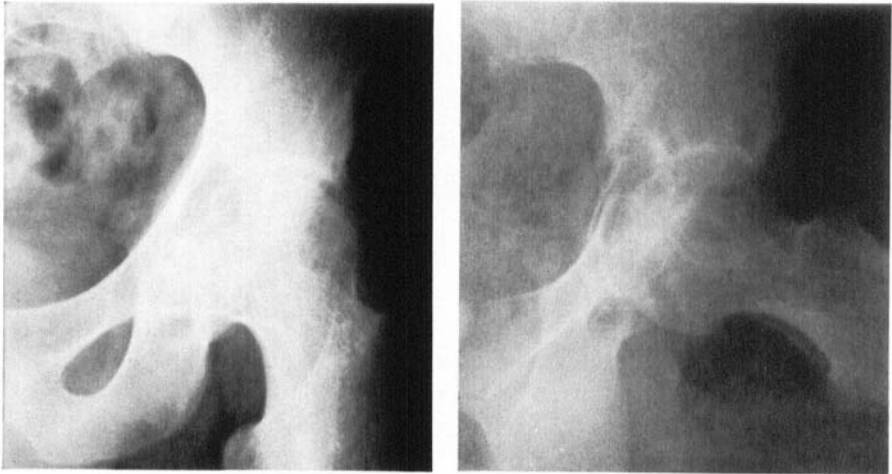
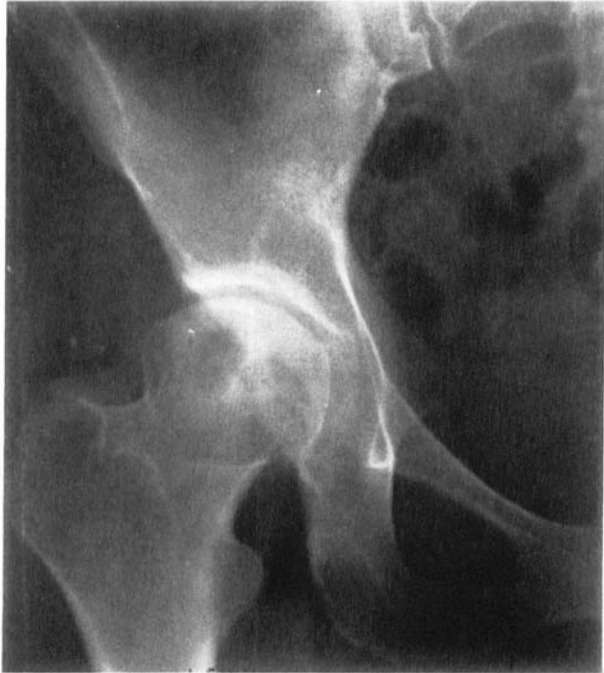

Figure 2. A-P and lateral radiographs of left hip showing bone lesions in a patient suffering from pigmented villonodular synovitis.

have been reported of this condition in association with bone changes (Ghormley & Romness 1954, Breimer & Freiburger 1958, McMaster 1960, Snook 1963, Chung & Janes 1965, Scott 1968, Nilsson & Moberger 1969, Van Rens 1972).

*Figure 3.
A-P radiograph of
right hip showing
normal joint space
and bone cysts at the
head of the femur
in a patient
suffering from
pigmented
villonodular synovitis.*



In this paper seven cases of pigmented villonodular synovitis with bone lesions are presented. The purpose of this study is to draw attention to the rare but possible occurrence of bone involvement in pigmented villonodular synovitis in order to avoid misdiagnosis of this condition as other more common joint diseases with similar bone changes. The various theories put forward on the pathogenesis of the bone lesions in pigmented villonodular synovitis are mentioned and the radiographical appearance of this condition is described along with the histological picture on which the diagnosis should be established.

MATERIAL

The age range of our seven patients was from 20 to 52 years. Four of these were women and three were men. The hip joint was affected in four patients (Figures 1, 2, 3, 4) and the knee, shoulder and ankle, respectively, in the three remaining patients (Figures 5, 6, 7).

The symptoms consisted of progressive pain of long duration; at times locking of the joint and stiffness. In the case in which the shoulder was involved an enlarged subdeltoid bursa was present, while effusion and synovial thickening were found in the knee and ankle joints.

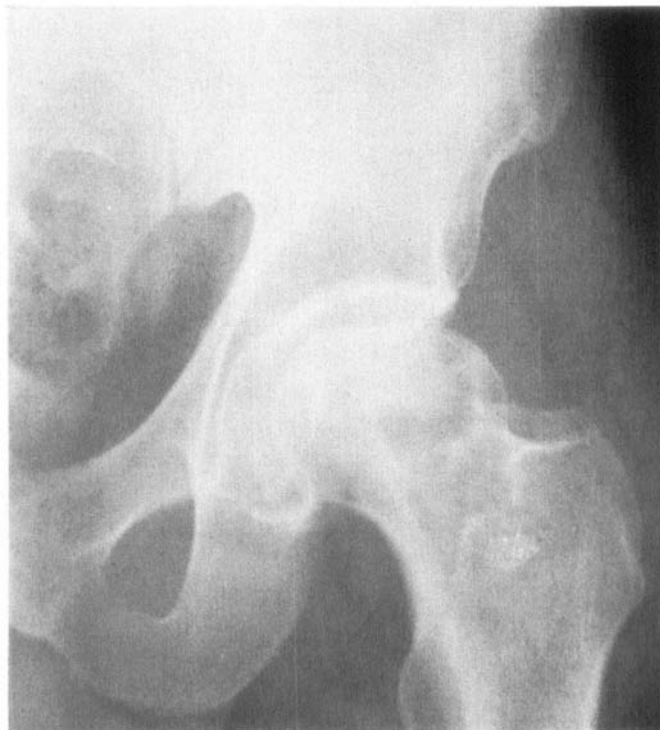

Figure 4.
A-P radiograph of
left hip with bone
cysts in the head
of the femur in a
patient suffering
from pigmented
villonodular
synovitis.

Radiographically the most common finding was bone cysts situated at some distance from the articular surfaces, usually well defined but not sclerotic. The articular space was preserved and in the late stages of the disease secondary osteoarthritic changes had progressively developed.

All the laboratory findings were normal in our patients, apart from a raised E.S.R. in the case affecting the shoulder. In all seven cases biopsy of the synovium confirmed the diagnosis. Histological examination revealed villus hypertrophy of the synovial membrane, which indicated active proliferation of the synovial cells, and variable fibrosis (Figure 8). Among these stromal cells, giant cells, lipid-bearing xanthoid cells and haemosiderin-bearing cells were occasionally seen. Haemosiderin was also found extracellularly. The synovial membrane was quite vascular (Figure 9). The involved bone showed thinner trabeculae and cysts containing synovial tissue similar to that described above.

As regards treatment, synovectomy with curettage of the bone cysts was carried out in the knee and two of the hip joints, whereas arthrodesis was performed in the case of the third patient with the hip joint affected and in the case with the ankle involved, because of the advanced stage of the disease (Figures 10, 11). In the fourth hip, synovectomy has been advised, following the biopsy, while in the case of the shoulder the subdeltoid bursa was excised because, during the synovial biopsy of the joint, it was found to be involved in the disease. The last two of our patients are awaiting final surgical treatment following their biopsies.

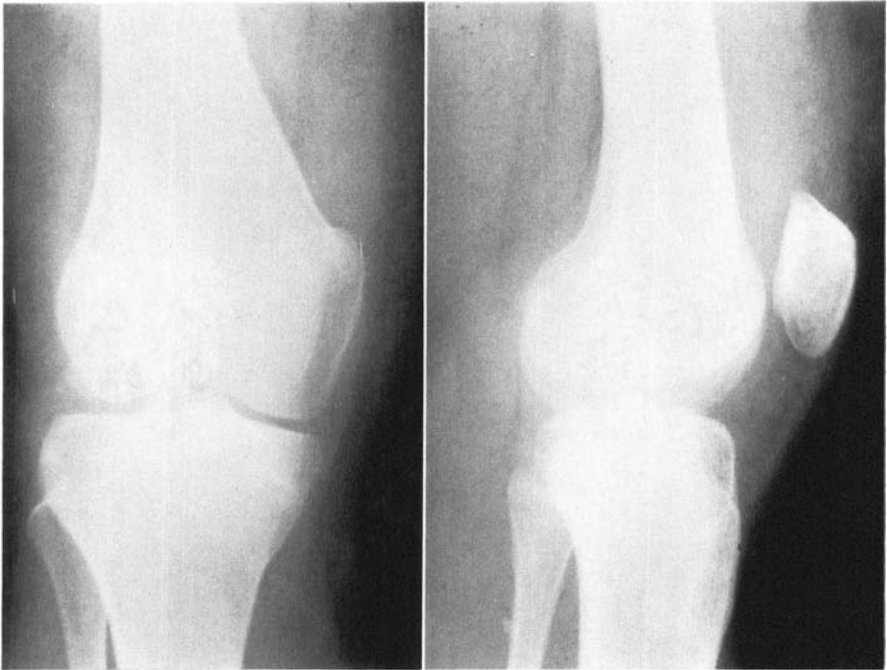


Figure 5. A-P and lateral X-rays of right knee with pigmented villonodular synovitis showing bone cyst at the medial femoral condyle and at the anterior site of the tibial epiphysis.

RESULTS

The arthrodesed ankle and hip have been painless without any signs of regression for 6 months and 2 years since operation, respectively. Two of the remaining three patients, in whom synovectomy and curettage of the bone cysts was performed, are doing well 9 months and 3 years after the operation, respectively. The third patient, whose hip joint was operated upon, deteriorated 1 year post-operatively with more pain and stiffness of the joint, regression of the bone lesions and collapse of the weightbearing area of the femoral head (Figure 12). In this case a total hip replacement was carried out (Figure 13).

DISCUSSION

It appears that bone lesions in pigmented villonodular synovitis are not so rare, especially in the joints not commonly affected by the disease

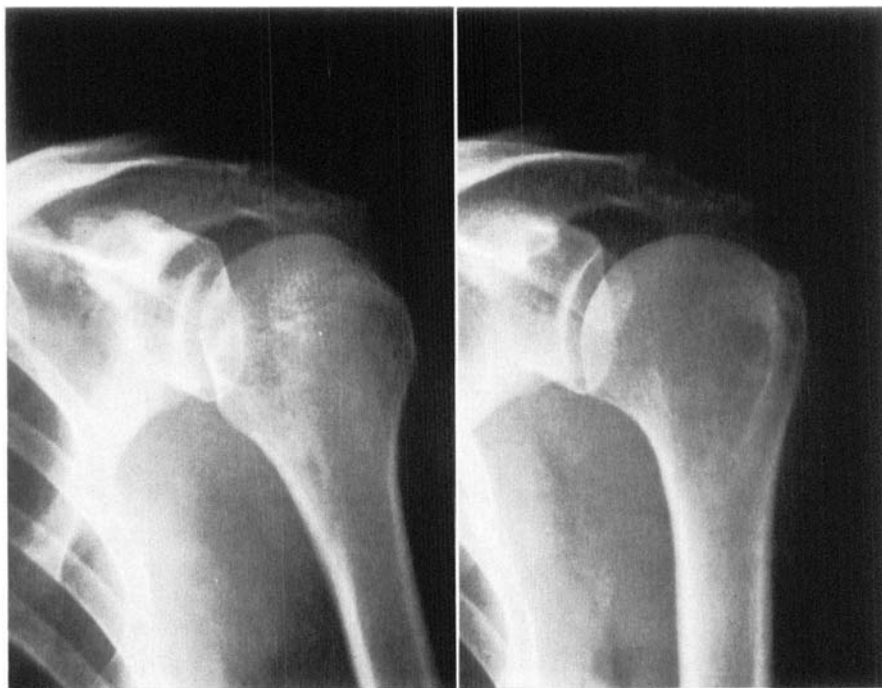

Figure 6. X-rays of left shoulder affected by pigmented villonodular synovitis with bone cysts in the head of the humerus.

such as the hip, ankle, shoulder and others (Ghormley & Romness 1954, Chung & Janes 1965, Breimer & Freiburger 1958, Scott 1968, Nilsonne & Moberger 1969, Van Rens 1972). Being aware of the possible presence of these bone changes in pigmented villonodular synovitis is very helpful in distinguishing this condition from other more common joint diseases with similar bone changes such as osteoarthritis, monoarticular rheumatoid arthritis, and avascular necrosis of the head of the femur in cases where the hip joint is involved. This is even more important since the bone changes occurring in pigmented villonodular synovitis can be mistaken for a neoplastic bone or joint lesion such as synovioma. There is at least one case of pigmented villonodular synovitis with bone changes reported in the literature which was misdiagnosed as malignant synovioma and hind-quarter amputation was performed (Byers et al. 1968). In another reported case of pigmented villonodular synovitis with bone changes affecting the hip joint, the

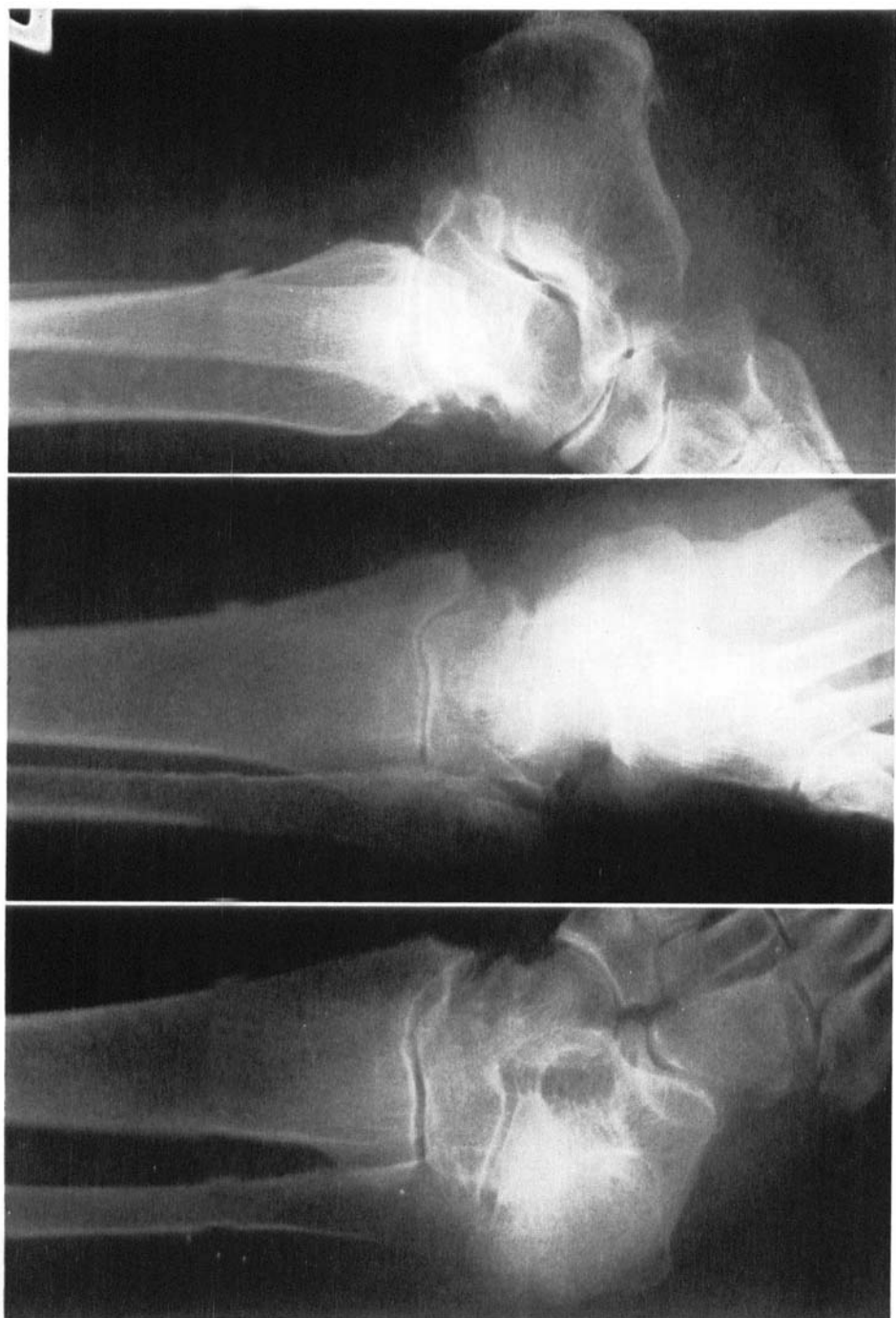

Figure 7. Radiographs of right ankle joint with pigmented villonodular synovitis. Cystic lesions are mainly seen in the body and neck of the talus.

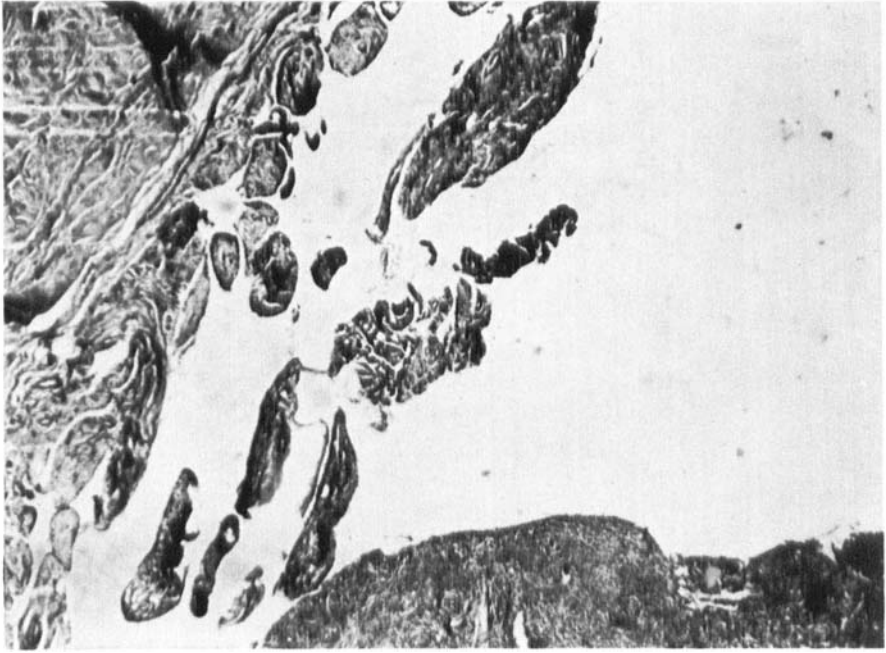


Figure 8. Pigmented villonodular synovitis. Villus hypertrophy of the synovial membrane.

synovial proliferation had a retroperitoneal extension simulating an abdominal tumour (Carr et al. 1954).

The diagnosis of the condition is based upon the usual clinical signs and the absence of positive laboratory findings, but it is mainly made from the radiographical appearance and confirmed by biopsy.

The classical X-ray findings, apart from the soft tissue swelling in the case of involvement of a superficial joint, are the bone cysts which are seen at some distance from the articular surface of the affected joint. They vary in appearance, being usually well-defined and non-calcified (McMaster 1960, Byers et al. 1968, Scott 1968). There is no narrowing of the joint space apart from in the final stages of the disease when segmental necrosis and arthritic changes can be seen (Figure 12).

The characteristic radiographical findings, however, are the bone cysts described. Their pathogenesis is not clear, although several theories have been put forward. It has been postulated that the extuberant villonodular tissue and the effusion of the joint cause high

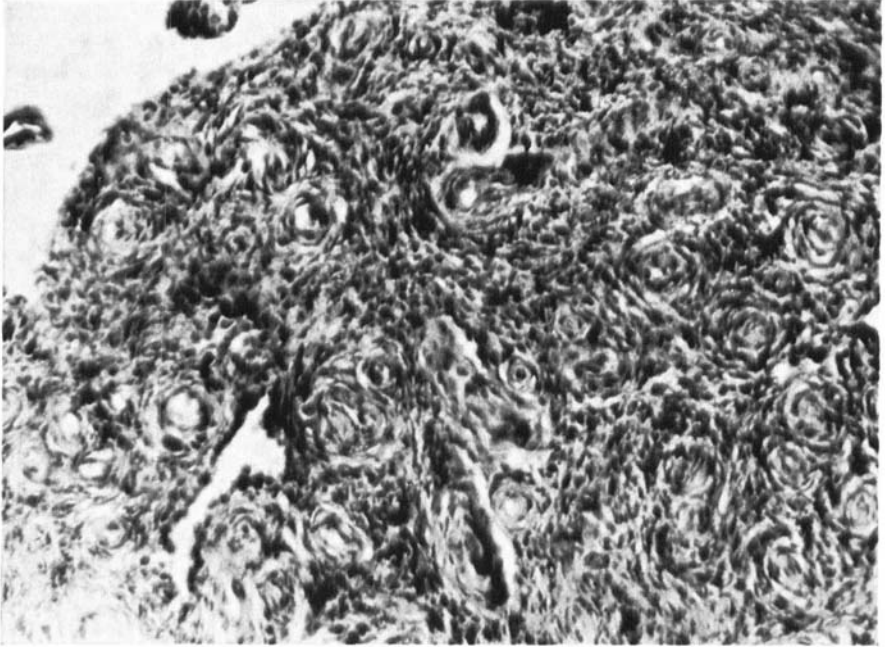


Figure 9. Pigmented villonodular synovitis. Highly cellular tissue with multinuclear cells.

intra-articular pressure. This in turn results in small areas of osteoporosis near the joint where the bone cysts are developed. The thus-formed cysts are finally invaded by the hypertrophic synovium of the joint through fractures of the cystic walls (Chung & Janes 1965). The high intra-articular pressure found by other authors as well (Scott 1968) may explain the rare occurrence of the bone cysts in the knee joint, which is more usually affected by the disease. This is because the articular cavity of the knee is large and can be expanded contrary to joints more rarely involved by the disease, such as the hip, the ankle, etc., in which bone changes are a rather common finding.

According to McMaster (1960) the cysts are created by the extension of villonodular tissue into the bone through the chondro-osseous area at the articular margin. Scott (1968) has found, however, that the invasion of the bone by the hyper-trophic synovium takes place through the vascular foramina along with the epiphyseal vessels. The villonodular tissue thus invading the bone is further expanded within the bone substance, producing the bone cysts by pressure atrophy.

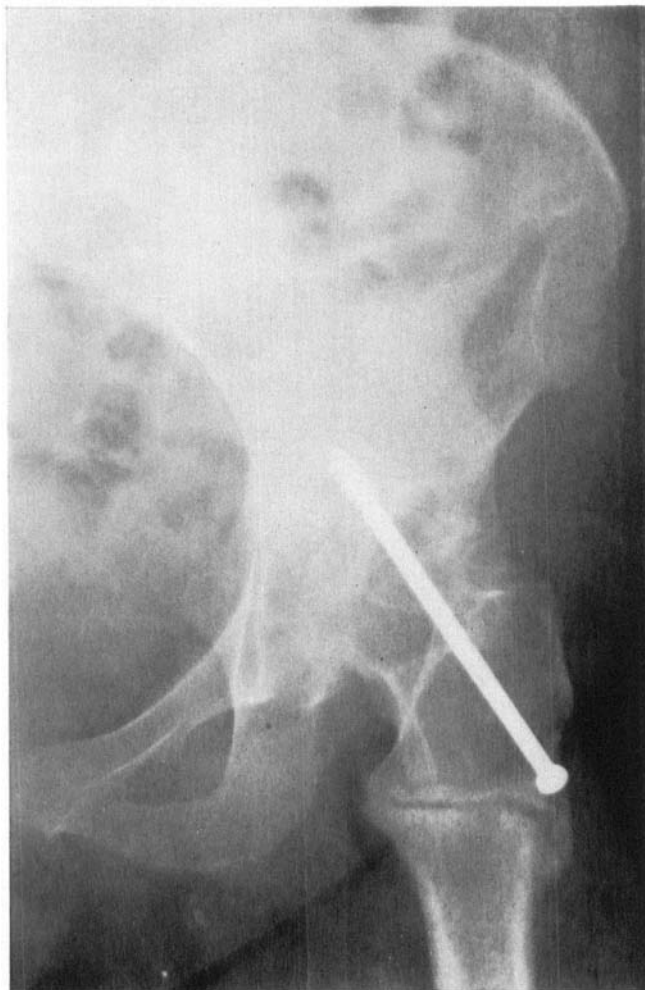


Figure 10.
A-P radiograph of
the case shown in
Figure 1 two years
after arthrodesis.

Total synovectomy seems to be accepted by most authors as the best treatment for pigmented villonodular synovitis. In the presence of bone lesions it should be combined with curettage of the bone cysts, which must be filled by cancellous bone chips when large (Byers et al. 1968, Scott 1968). Radiotherapy is also proposed, either as the only treatment (Friedman & Schwartz 1957) or combined with surgery whenever total synovectomy and/or complete curettage of the cysts are inadequate (Scott 1968, Byers et al. 1968). Radiotherapy, however, should not be advised as the main treatment for this condition when

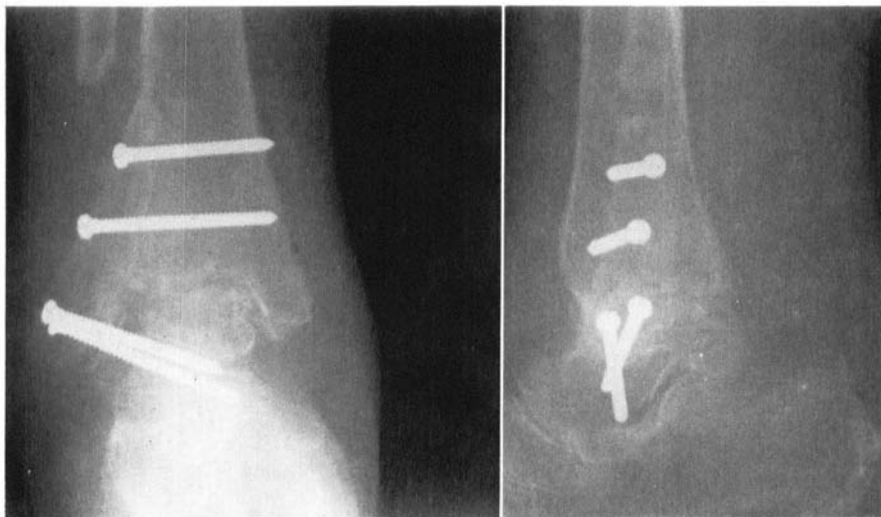

Figure 11. A-P and lateral radiographs of the case shown in Figure 7 following arthrodesis.

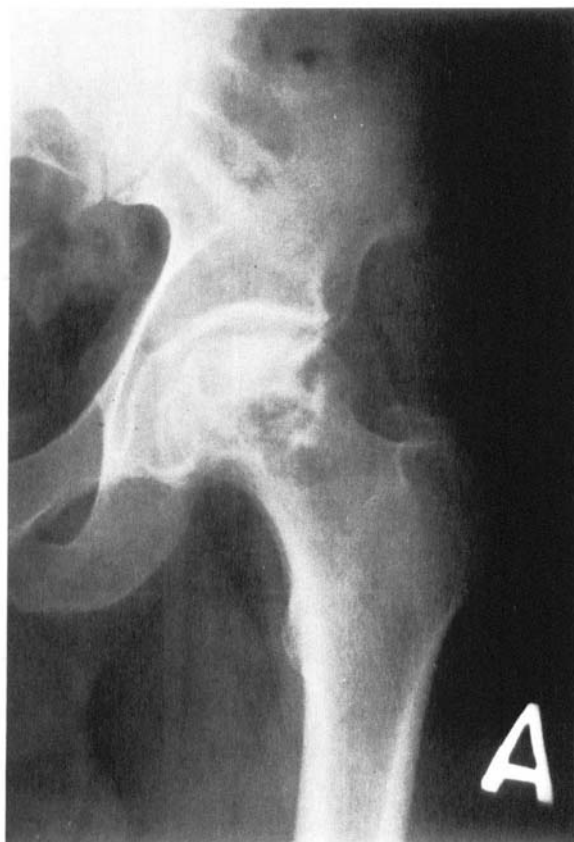

Figure 12. A-P radiograph of the case shown in Figure 4 one year after synovectomy. Note deterioration of the bone lesions and collapse of the weightbearing area of the femoral head.

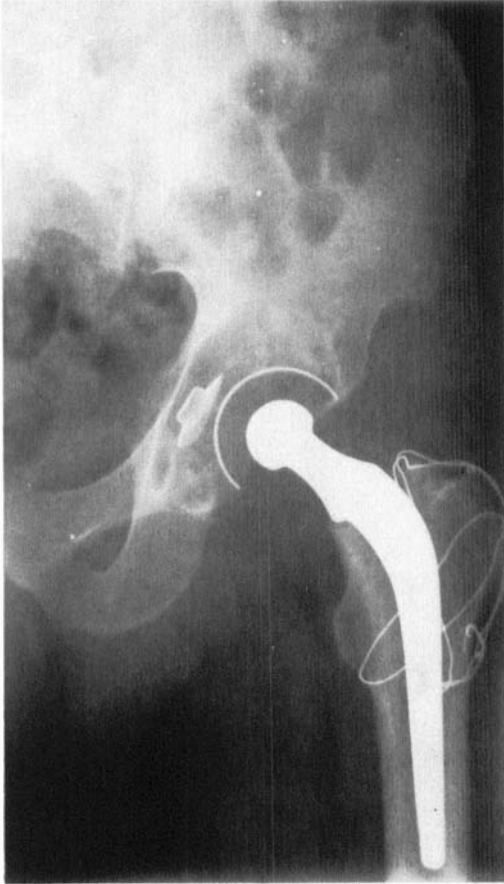


Figure 13. A-P radiograph of the case shown in Figures 4 and 12 following total hip arthroplasty.

the bone lesions are extensive, especially in young patients, because of possible stiffness of the joint and because of its carcinogenic effect.

Finally, in the case of severe and permanent damage to the joint more radical treatment is advised. Arthrodesis or total replacement arthroplasty are the methods of choice depending on the joint affected and the age of the patient (Byers et al. 1968, Van Rens 1972).

SUMMARY

Seven cases of pigmented villonodular synovitis with invasion of the bone are described, four affecting the hip and the remaining three involving the knee, shoulder and ankle joint, respectively. The patho-

genesis of the bone changes and the radiographical appearance of the involved joints are described. The methods of treatment are discussed.

REFERENCES

- Aegerter, E. & Kirkpatrick, J. A. (1968) *Orthopedic diseases*. W. B. Saunders Company, Philadelphia, London, Toronto.
- Atmore, W. G., Dahlin, D. C. & Ghormley, R. K. (1956) Pigmented villonodular synovitis. A clinical and pathological study. *Minn. Med.* **39**, 196.
- Breimer, C. W. & Freiburger, R. H. (1958) Bone lesions associated with villonodular synovitis. *Amer. J. Roentgenol.* **79**, 618.
- Byers, P. D., Cotton, R. E., Deacon, O. W., Lowy, M., Newman, P. H., Sissons, H. A. & Thompson, A. D. (1968) The diagnosis and treatment of pigmented villonodular synovitis. *J. Bone Jt Surg.* **50-B**, 290.
- Carr, C. R., Berley, F. V. & Davis, W. C. (1954) Pigmented villonodular synovitis of the hip joint. *J. Bone Jt Surg.* **36-A**, 1007.
- Chung, S. M. K. & Janes, J. M. (1965) Diffuse pigmented villonodular synovitis of the hip joint. *J. Bone Jt Surg.* **47-A**, 293.
- Fisk, G. R. (1952) Hyperplasia and metaplasia in synovial membrane. *Ann. roy. Coll. Surg. Engl.* **11**, 157.
- Friedman, M. & Schwartz, E. E. (1957) Irradiation therapy of pigmented villonodular synovitis. *Bull. Hosp. Jt Dis. (N.Y.)* **18**, 19.
- Ghormley, R. K. & Romness, J. O. (1954) Pigmented villonodular synovitis (xanthomatosis) of the hip joint. *Proc. Mayo Clin.* **29**, 171.
- Greenfield, M. M. & Wallace, K. M. (1950) Pigmented villonodular synovitis. *Radiology* **54**, 350.
- Hirohara, K. & Morimoto, K. (1971) *Ultrastructure of bone and joint diseases*. Igaku Shoin Ltd., Tokyo.
- Jaffe, H. L. (1960) Discussion on pigmented villonodular synovitis with invasion of bone. Report of six cases by Paul E. McMaster. *J. Bone Jt Surg.* **42-A**, 1183.
- Jaffe, H. L. (1964) *Tumors and tumorous conditions of the bones and joints*. Lea and Hebigel, Philadelphia.
- Kumon, H. (1969) An experimental study on the pathogenesis of pigmented villonodular synovitis. *J. Jap. Orthop. Assoc.* **43**, 343.
- McMaster, P. E. (1960) Pigmented villonodular synovitis with invasion of bone. *J. Bone Jt Surg.* **42-A**, 1170.
- Nilsson, U. & Moberger, G. (1969) Pigmented villonodular synovitis of joints. *Acta orthop. scand.* **40**, 448.
- Scott, P. M. (1968) Bone lesions in pigmented villonodular synovitis. *J. Bone Jt Surg.* **50-B**, 306.
- Snook, G. A. (1963) Pigmented villonodular synovitis with bone invasion. A report of two cases. *J. Amer. med. Ass.* **184**, 424.
- Van Rens, Th. J. G. (1972) Pigmented villonodular synovitis of the hip joint. *Acta orthop. belg.* **38**, 221.
- Wright, C. J. E. (1951) Benign giant cell synovioma. An investigation of 85 cases. *Brit. J. Surg.* **38**, 257.

Young, J. M. & Hudacek, A. G. (1954) Experimental production of pigmented villonodular synovitis in dogs. *Amer. J. Path.* **30**, 799.

Key words: synovitis; villonodular; joints

Correspondence to:

Th. Pantazopoulos
Department of Orthopaedics
University of Athens
Athens, Greece