

The Department of Orthopaedic Surgery, Hollywood Presbyterian Hospital,
Los Angeles, California, USA.

USE OF ULTRASOUND TO DETECT FAT EMBOLI DURING TOTAL HIP REPLACEMENT

JAMES H. HERNDON, CHARLES O. BECHTOL & DALLAS P. CRICKENBERGER

Accepted 21.viii.74

Venous fat embolism has been implicated as a possible cause of fatality associated with total hip replacement or hemiarthroplasty of the hip in which methylmethacrylate cement is used. Twenty-eight deaths have been reported (two following total knee replacement) in which autopsy findings in sixteen patients have demonstrated pulmonary fat emboli (Adams et al. 1972, Harris 1970, Hyland & Robins 1970, Cohen & Smith 1971, Charnley et al. 1971, Daniel et al. 1972, Burgess 1970, Dandy 1971, Durbin et al. 1970, Gresham & Kuczynski 1970, Gresham et al. 1971, Phillips et al. 1971, Powell et al. 1970, Thomas et al. 1971). In three patients bone marrow emboli were seen and one patient had fat emboli in the myocardium (Kepes et al. 1972, Sevitt 1972).

A recent report by Kelly et al. (1972) demonstrated that ultrasound provided a simple and reliable method for detecting fat emboli in dogs and humans after long-bone fractures. We have utilized the Doppler effect with a simple noninvasive ultrasonic technique to detect fat emboli in the venous return from the lower extremity in an unselected group of patients undergoing total hip replacement.

MATERIAL AND METHODS

Thirty-four unselected patients undergoing total hip replacement were studied by monitoring over the common femoral vein of the operated extremity with a Doppler ultrasonic flowmeter. The Medsonics Doppler flowmeter model BF4A with a signal of 5.8 MHz was used in the first nineteen cases, the Parks Doppler flowmeter model 802 with a standard pencil probe with an output signal of 9.7 MHz was used in thirteen cases, and the Parks Doppler flowmeter model 801 with a fifteen degree flat probe was used in two cases.

Supported by the Joint Implant Surgery and Research Foundation.

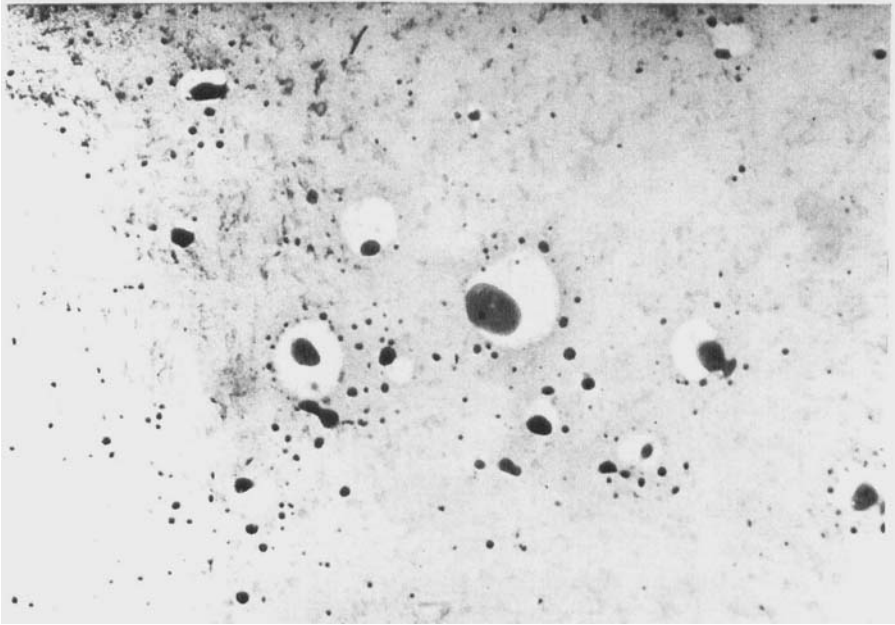


Figure 1. Cryostat frozen section preparation demonstrating number and relative size of fat emboli in femoral vein aspirate drawn during peak ultrasound activity. Stained with oil-red-O. ($\times 310$).

Blood flow in the common femoral vein was monitored continuously throughout the operative procedure. Sounds were recorded on a Sony cassette tape recorder in thirteen cases; four of these recordings were dubbed onto a one inch magnetic tape, annotated by a reference time code to facilitate pulses of interest and pertinent portions of the data were digitalized at 5000 samples per second. From this data impulses to be analyzed were selected and reduced on a computer to yield an energy spectrum analysis and Fourier analysis. Frequency regions from 3 to 3000 Hz and in selected cases up to 7500 Hz were studied. In three cases the surgeon (COB) injected less than 1 cm³ of clear liquid marrow fat, and in two cases injected 2 cm³ of room air into a small vein exposed in the operative field. Sounds over the common femoral vein were recorded, analyzed and compared to the sounds recorded during the total hip procedure.

Twenty-one patients also underwent femoral vein catheterization prior to surgery. Under sterile conditions and fluoroscopic control a number seven french disposable Cordis angiographic catheter was passed percutaneously into the brachial vein and manipulated into the common femoral vein. Blood samples were drawn preoperatively, during the period of peak activity heard with the ultrasound flowmeter and at the end of the operation. A control was drawn simultaneously from an arm vein. All samples were drawn in glass syringes which had been washed in acetone and dried carefully. All laboratory glassware was washed twice in alcohol-ether and dried carefully.




Figure 2. Photomicrograph of millipore filter containing fat emboli in femoral vein aspirate drawn during peak ultrasound activity. Filter stained with Sudan IV. ($\times 310$).

The aspirated blood was divided into two samples. A 3 cm³ aliquot was allowed to clot and analyzed for fat emboli by the cryostat frozen section test described by Huaman et al. (1971). The remaining blood (7 cm³ per specimen) was anticoagulated with EDTA and analyzed for fat emboli by millipore filtration and triglyceride determination as described by Gurd (1970).

RESULTS

As the femoral component was inserted burbling sounds were heard in some cases, but characteristic "chirps" were heard in thirty-two of the thirty-four cases studied. Their intensity and frequency increased rapidly as the prosthesis was firmly seated. After variable amounts of time the chirps became more distinct, decreased in frequency and intensity, and gradually diminished.

No sounds were detected in the two cases in which a Parks Doppler model number 801 with a fifteen degree flat probe taped over the groin was used. In each case the probe came loose with movement of the extremity during the procedure. It is essential that the ultrasound

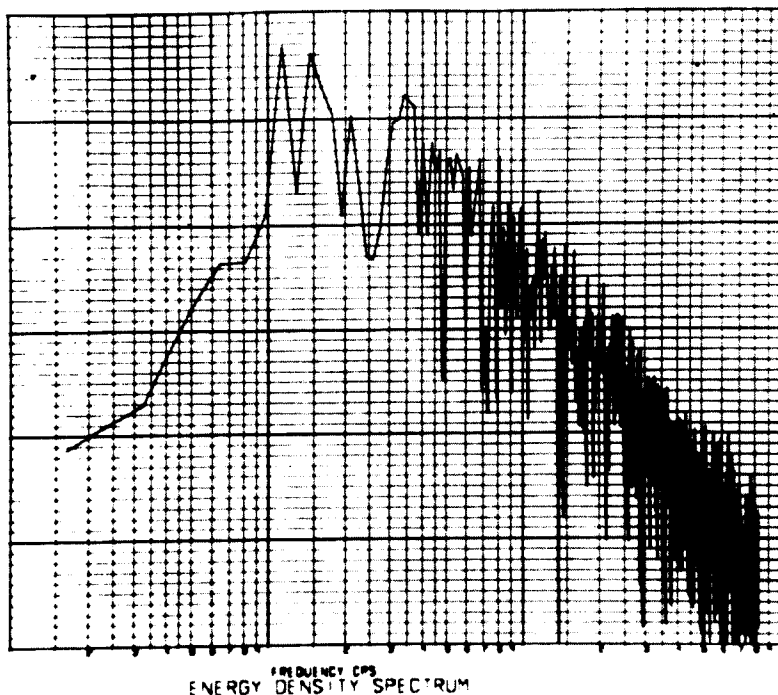


Figure 3. Energy density spectrum analysis of the chirps recorded with the ultrasound flowmeter during insertion of the femoral component. Note peak in region of 100 cycles per second with a steady uniform decrease in the higher frequency regions.

probe be coupled to the skin with an aqueous gel to allow for transmission of the echo.

Both the cryostat frozen section of clot and analysis for fat emboli by Gurd (1970) established that during insertion of the femoral component, when the sounds recorded by the Doppler flowmeter were at their peak, fat emboli were released into the venous circulation (Figures 1 and 2). At this time during the operation the mean number of fat globules per high power field in the frozen section of clotted blood drawn from the femoral vein was 79 (control 1.7; $P < 0.001$). The mean number of fat globules on the millipore filter was 360 per high power field (control 6.8; $P < 0.001$). The mean drop in triglyceride level after filtration was 27.8 mg per 100 ml (control 1.2; $P < 0.001$). In each case however the preoperative and postoperative values were almost identical to the controls.

An energy density spectrum analysis and Fourier analysis carried

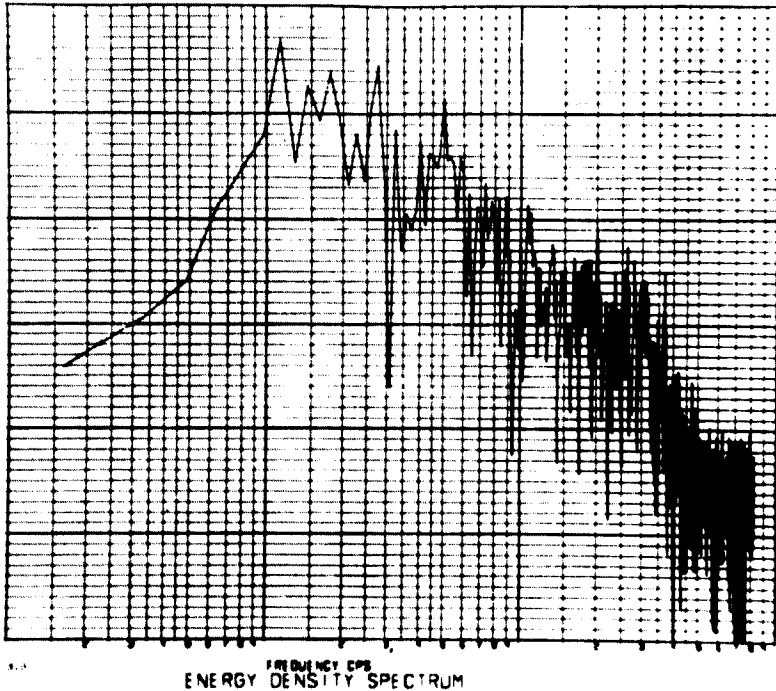


Figure 4. Energy density spectrum analysis of the pure chirps recorded with the ultrasound flowmeter during known injection of liquid marrow fat. The curve is indistinguishable from the energy density spectrum analyses carried out on the patients during insertion of the femoral component.

out on four patients revealed similar frequency contents. The audible chirps were shown to be composed of many smaller distinct sounds that could not be distinguished by the human ear (Figure 3). The frequency analysis of the chirps showed a broad band of energy content ranging from 10 to 3000 Hz peaking between 50 and 100 Hz. The distinct chirps lasted up to 0.4 s while the smaller units ranged from 2 to 5 ms in duration. The interval between the sounds was 10 to 15 ms. The frequency spectrum of the chirps varied in each patient and from patient to patient. No definite signature was obtained.

The control injection of liquid marrow fat was heard as pure chirps by the observer (Figure 4) and the control injection of air was heard as burbling (Figure 5). Thus to the observed it was apparent that two different sounds were heard, but energy density spectrum analyses were unable to give a signature to either type of sounds or equate them to the sounds heard during insertion of the femoral component in total hip replacement.

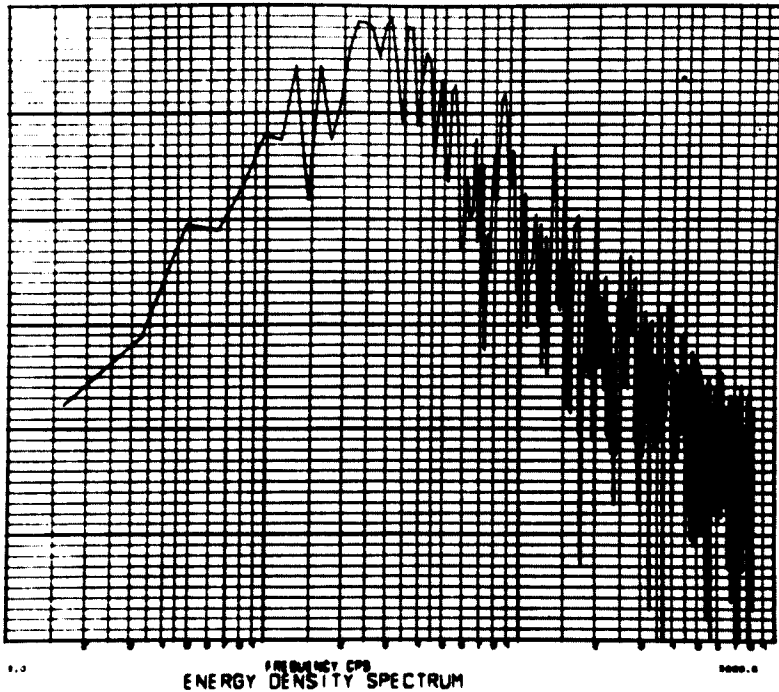


Figure 5. Energy density spectrum analysis of the burbling sounds recorded with the ultrasound flowmeter during known injection of air. The curve is indistinguishable from the energy density spectrum analyses carried out on the patients during insertion of the femoral component.

The average duration of activity was 4.2 min. Sounds lasted from just a few chirps to 11 min in duration. The length of activity varied with surgical technique, i.e. whether a vent was used during insertion of the cement and prosthesis into the femur (Figure 6). The longest period of activity was recorded in Group I in which no vent was used. The mean duration of activity was reduced by almost one-half when a catheter attached to suction was used as a vent (Group II; $P < 0.01$). In Group III (drill hole as a vent) the mean duration of activity was only 2.5 min ($P < 0.01$ compared to Group I). Group IV included two patients who underwent revision of a previously cemented prosthesis and minimal ultrasound activity and fat emboli were detected.

During the remaining surgical procedure with continuous monitoring with the ultrasound probe in thirty-two patients a few chirps were heard during reaming the acetabulum (one case), during seating the acetabular component (five cases) and during insertion of the cement

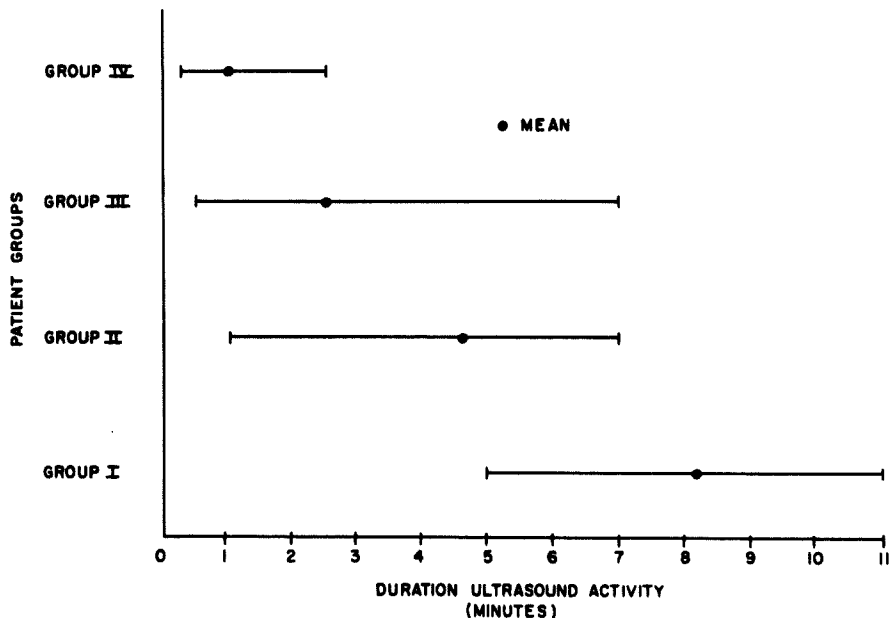


Figure 6. Duration of ultrasound activity recorded during insertion of the femoral component. Longest periods of activity were heard when no vent was used. Shortest duration of activity was recorded in patients with a previously cemented prosthesis.

into the femur (ten cases). In each instance only a few transient chirps were heard.

DISCUSSION

Ultrasound has been widely used to monitor blood flow in arterial and venous peripheral vascular disease (Strandness et al. 1966, Sigel et al. 1972), blood pressure (Kemmerer 1967), arterial flow during arterial and ventricular arrhythmias (Benchimol et al. 1969), fetal heart beat (Bernstine & Callagan 1966), to detect venous air emboli (Edmonds-Seal & Maroon 1969) and recently to detect venous fat emboli following fractures of the lower extremity (Kelly et al. 1972).

The ultrasonic instruments can also detect fat emboli during total hip replacement. In the cases studied fat emboli were released every time during insertion of the femoral component and rarely in very small quantities during reaming the acetabulum, seating the acetabular component or during insertion of the cement into the femur.

Characteristic "chirps" were heard with the ultrasound which were

proven to be fat emboli by blood analyses. Kelly et al. (1972) recently described these same "chirps" as representing fat emboli released by fractures involving the femur or tibia. They carried out sonogram frequency analyses which showed that the loudest chirps had a frequency of 2.5 to 8.0 KHz, a duration of 2 to 3 ms and an occurrence of up to three emboli in 20 ms. We carried out an energy density spectrum analysis and Fourier analysis which showed similar duration and interval for the sounds as Kelly's study but the frequency of our sounds varied from 50 to 100 cycles per second—much lower than Kelly described. Our analyses also demonstrated that the audible sounds were composed of many smaller distinct sounds not detected by the listener. The frequencies of these sounds varied in each patient and from patient to patient although they sounded similar to the listener. We were not able to establish a definite signature for each sound. This may be due to the large number of variables: different sizes of fat globules, adherence of platelets, other products of reaming such as fragmented red and white blood cells, possible air emboli, summation effect of different fat emboli being detected as a single large embolus by the Doppler probe, changes in flow rate, turbulence, and fat emboli being recorded more than once as they passed through the ultrasound beam.

The fat studies proved the nature of the particles causing the chirps, but the ultrasound flowmeter did not. Patterson & Kessler (1969) have shown that ultrasound gives little information about the nature of microemboli—both bubbles and solid particles produced similar echos. Circulating bubbles have been described as "chirps", "plobs" and sounds similar to high-pitched scratching noise produced when a phonograph needle strides across a moving record (Maroon et al. 1968).

Clinically we were able to differentiate two sounds during seating of the femoral component—a few burbling sounds initially as the prosthesis was being inserted in a few cases and the "chirps" which were present in each case monitored. The burbling sounds were similar to the listener as the sounds heard when a known sample of air was injected into a small exposed vein. The chirps were similar to the sounds heard when a known sample of liquid marrow fat was injected into a small exposed vein and by blood analyses were proven to be fat emboli. Thus although the observer felt he clinically could differentiate the sounds, the energy density spectrum analysis could not (both were very similar). These analyses may be too precise, but further support Patterson & Kessler's (1969) contention.

Ultrasound does however give useful information about the quantity of particles. Patterson & Kessler (1969) demonstrated a direct linear relationship between the number of particles and the number of echoes per unit time. Our data suggest that air embolism does occur in some cases of total hip replacement during insertion of the femoral component, but in every case a larger and more significant amount of fat emboli are released into the venous circulation. Ultrasound is an excellent clinical tool to monitor the amount of fat emboli during the operative procedure. Significant decreases in the quantity of fat emboli can be maintained by proper positioning of the femur, thorough evacuation of marrow contents after reaming and by the proper use of a vent (suction tube or drill holes) during the procedure.

SUMMARY

Use of the Doppler principle with an ultrasound flowmeter provided a method of detecting fat emboli during total hip replacement. A measure of the quantity of fat emboli and when the embolism occurs during the operative procedure is possible with this method.

By the use of a suction catheter inserted in the intramedullary canal or the placement of large drill holes in the lateral cortex of the femur the amount of fat released into the venous circulation can be reduced.

Although no definite signature could be obtained for the audible "chirps" by energy density spectrum analysis the observer could readily distinguish these chirps from the burbling noise produced by air emboli. Ultrasound is an easy, noninvasive and reliable technique for detecting fat emboli during total hip replacement.

ACKNOWLEDGEMENTS

The authors would like to thank John C. Cerrone, M.D., Robert W. Woods, M.D., Charlotte Yamada, Patsy K. Richards, Mark Trummel, Ph.D. and the staff of the Jet Propulsion Laboratory, and James Pugh, Ph.D. for their assistance in this study.

REFERENCES

- Adams, J. H., Graham, D. I., Mills, E. & Sprunt, T. G. (1972) Fat embolism and cerebral infarction after use of methylmethacrylate cement. *Brit. med. J.* **3**, 740.
- Benchimol, A., Maroko, P., Gartlan, J. & Franklin, D. (1969) Continuous measurements of arterial flow in man during atrial and ventricular arrhythmias. *Amer. J. Med.* **46**, 52-63.

- Bernstine, R. L. & Callagan, D. A. (1966) Ultrasonic Doppler inspection of the fetal heart. *Amer. J. Obstet. Gynec.* **95**, 1001-1004.
- Burgess, D. M. (1970) Cardiac arrest and bone cement. *Brit. med. J.* **3**, 588.
- Charnley, J., Murphy, J. C. M. & Pitkeathly, D. A. (1971) Fractured femur and fat embolism. *Internal Publication* **32**, 1-2.
- Cohen, C. A. & Smith, T. C. (1971) The intraoperative hazard of acrylic bone cement: report of case. *Anesthesiology* **35**, 547-549.
- Dandy, D. J. (1971) Fat embolism following prosthetic replacement of the femoral head. *Injury* **3**, 85-88.
- Daniel, W. W., Coventry, M. B. & Miller, W. E. (1972) Pulmonary complications after total hip arthroplasty with Charnley prosthesis as revealed by chest roentgenograms. *J. Bone Jt Surg.* **54-A**, 282-283.
- Durbin, F. C., Jeffery, C. C., Jones, G. B., Ling, R. S. M., Scott, P. J., Woodyard, J. E. & Wrighton, J. D. (1970) Cardiac arrest and bone cement. *Brit. med. J.* **4**, 176-177.
- Edmonds-Seal, J. & Maroon, J. C. (1969) Air embolism diagnosed with ultrasound. *Brit. J. Anaesth.* **24**, 438-440.
- Gresham, G. A. & Kuczynski, A. (1970) Cardiac arrest and bone cement. *Brit. med. J.* **3**, 465.
- Gresham, G. A., Kuczynski, A. & Rosborough, D. (1971) Fatal fat embolism following replacement arthroplasty for transcervical fractures of femur. *Brit. med. J.* **2**, 617-619.
- Gurd, A. R. (1970) Fat embolism: an aid to diagnosis. *J. Bone Jt Surg.* **52-B**, 732-737.
- Harris, N. H. (1970) Cardiac arrest and bone cement. *Brit. med. J.* **3**, 523.
- Huamen, A., Nice, W. & Young, I. (1971) Cryostat test for fat embolism. *Lab. Med.* **2**, 37-42.
- Hyland, J. & Robins, R. H. C. (1970) Cardiac arrest and bone cement. *Brit. med. J.* **4**, 176-177.
- Kelly, G. L., Dodi, G. & Eisman, B. (1972) Ultrasound detection of fat emboli. *Surg. Forum.* **23**, 459-461.
- Kemmerer, W. T. (1967) Indirect measurement of human blood pressure by the Doppler ultrasonic technique. *Surg. Forum.* **18**, 164-165.
- Kepes, E. R., Underwood, P. S. & Becsey, L. (1972) Intraoperative deaths associated with acrylic bone cement. *J. Amer. med. Ass.* **222**, 576-577.
- Maroon, J. C., Goodman, J. M., Horner, T. G. & Campbell, R. L. (1968) Detection of minute venous air emboli with ultrasound. *Surg. Gynec. Obstet.* **127**, 1236-1238.
- Patterson, R. H. & Kessler, J. (1969) Microemboli during cardiopulmonary bypass detected by ultrasound. *Surg. Gynec. Obstet.* **129**, 505-510.
- Phillips, H., Cole, P. V. & Lettin, A. W. F. (1971) Cardiovascular effects of implanted acrylic bone cement. *Brit. med. J.* **3**, 460-461.
- Powell, J. N., McGrath, P. J., Lahiri, S. K. & Hill, P. (1970) Cardiac arrest associated with bone cement. *Brit. med. J.* **3**, 326.
- Sevitt, S. (1972) Fat embolism in patients with fractured hips. *Brit. med. J.* **2**, 257-262.
- Sigel, B., Felix, Jr., W. R., Popky, G. L. & Ipsen, J. (1972) Diagnosis of lower limb venous thrombosis by Doppler ultrasound technique. *Arch. Surg.* **104**, 174-179.
- Strandness, Jr., D. E., McCutcheon, E. P. & Rushmer, R. F. (1966) Application of a

transcutaneous Doppler flowmeter in evaluation of occlusive arterial disease.
Surg. Gynec. Obstet. **122**, 1039-1045.

Thomas, T. A., Sutherland, I. C. & Waterhouse, T. D. (1971) Cold curing acrylic bone cement. *Anesthesia* **26**, 298-302.

Key words: ultrasonics; embolism, fat; hip joint; hip

Correspondence to:

James H. Herndon, M.D.
313 Blodgett Medical Building
Grand Rapids, Michigan 49506, USA