

DISTAL DISINERTION OF THE PATELLAR LIGAMENT COMBINED WITH AVULSION FRACTURES AT THE MEDIAL AND LATERAL MARGINS OF THE PATELLA

A Case Report and an Experimental Study

LARS PETERSON & BERTIL STENER

Department of Orthopaedic Surgery II, Sahlgren Hospital, University of Gothenburg, Sweden.

A 12-year-old boy presented with a proximally retracted patella 5 months after an injury to the left knee. The clinical and radiographic features and the findings at operation led to the conclusion that the original lesion had been a distal disinsertion of the patellar ligament combined with avulsion fractures at the medial and lateral margins of the patella, produced by the medial and lateral longitudinal patellar retinacula. Loading experiments on amputation and cadaver specimens showed that these retinacula, apart from being tendons for the vastus medialis and the vastus lateralis, respectively, constitute a direct fibrous connection of considerable strength between the patella and the tibia and thus are capable of producing avulsion fractures.

Key words: avulsion fracture; patella; retinaculum, clinical and experimental study

Accepted 26.viii.76

Avulsion fractures at the medial and lateral margins of the patella produced by the medial and lateral longitudinal patellar retinacula seem to be little known. Indeed, an extensive search in the literature has failed to reveal any previous report of such a case. Most anatomical textbooks and handbooks describe the medial and lateral longitudinal patellar retinacula as tendinous structures which directly connect the vastus medialis and the vastus lateralis, respectively, to the tibia, but omit to mention that they also, like the patellar ligament, connect the patella to the tibia (Figure 1). An exception is Callander's

Surgical Anatomy (Anson & Maddoch 1958) where this fact is clearly stated. Indeed, the bond between the patella and the tibia through the medial and lateral longitudinal patellar retinacula is very strong as will be shown below by a clinical case and by loading experiments on amputation and cadaver specimens.

CASE REPORT

A 12-year-old boy fell from a tree and sustained an injury to the left knee. At hospital 30 ml of blood was aspirated from the joint and an elastic bandage was applied. Radiography revealed a rounded fragment of bone lateral to the apex of the patella (lower thin arrow in the

oblique projection in Figure 2), it was interpreted by the radiologist as being possibly either the result of an old fracture or a patella bipartita. (Other abnormalities as shown in Figure 2 were not noticed at that time.) Five weeks after the injury it was noted that the boy was unable to extend the knee fully; the deficit was about 15°. Five months after the injury it was recognized that the left patella was retracted upwards and there was a protrusion anterior to the upper end of the tibia; the patient could still not extend the knee fully. New radiographs were taken (Figures 3 and 4) and compared with those made immediately after the injury (Figure 2). This comparison, together with the clinical picture and the findings when the knee was later operated upon, permitted the conclusion that the original lesion had been a distal disinsertion of the patellar ligament combined with avulsion fractures of the patella produced by the medial and lateral longitudinal patellar retinacula (Figure 5). In the Figures 2, 3 and 4, the fragments avulsed from the lateral margin of the patella have been marked by thin arrows, whereas the fragment avulsed from the medial margin has been marked by a thick arrow. The fragments had grown and obtained a more evident bony structure during the 5 months that had elapsed after the injury. During this time too, two pieces of bone had formed at the disinserted end of the patellar ligament (asterisk in Figures 3 and 4). At the operation the lowermost of these was fastened by a screw to the tibial tubercle, once the patella and the patellar ligament had been drawn down into a correct position; the other was removed, as were also the fragments that had been avulsed from the patella by the retinacula. The knee was immobilized for 6 weeks in a plaster cast extending from the groin to the malleoli. At clinical follow-up 3 years after the operation the patient was free from discomfort. There was a slight prominence corresponding to the tibial tubercle. The range of mobility of the knee was normal. The extension force of the knee and the circumference of the thigh were the same as on the uninjured side. Radiography showed a slightly enlarged tibial tubercle without fragmentation; its epiphyseal line had closed. The position of the patella was the same on both sides.

LOADING EXPERIMENTS

In order to demonstrate that the medial and lateral longitudinal patellar retinacula, apart from being tendons for the vastus medialis and the vastus lateralis, also constitute a direct fibrous connection between the patella and the tibia of sufficient strength to produce avulsion

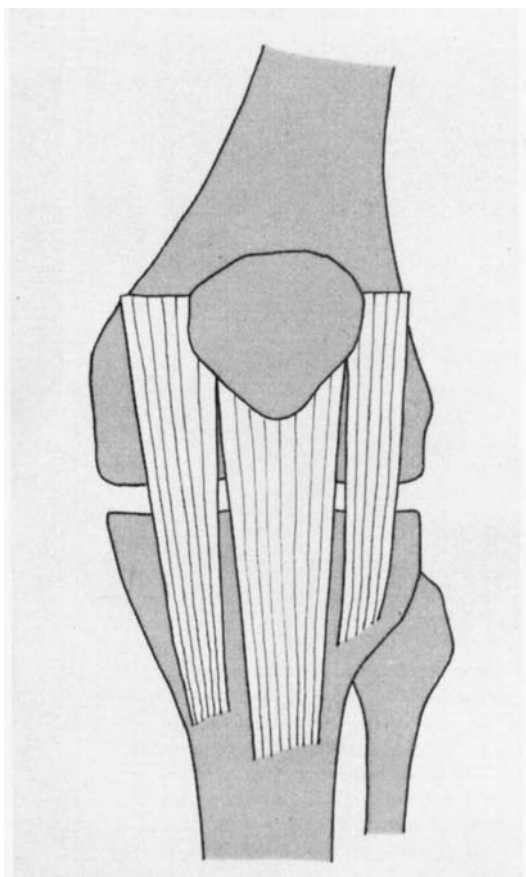


Figure 1. The medial and lateral longitudinal patellar retinacula, apart from being tendons for the vastus medialis and the vastus lateralis, respectively, also constitute a direct fibrous connection between the patella and the tibia.

fractures, the following experiments were carried out. One amputation specimen and four cadaver specimens were prepared and subjected to an increasing load according to the principle illustrated in Figure 6. The patellar ligament, whose borders can be easily identified, was cut through transversely, after which the only structures connecting the patella to the tibia were collagenous fibres belonging to the medial and lateral longitudinal patellar retinacula. One Kirschner wire was drilled through the patella and one through the tibia. Via these wires the specimen was tested in tension to failure on a modified standard material testing machine (Alwetron universal testing machine Model T-2000, Figure 7). The extension rate was 50 mm/min. The failure consistently occurred in

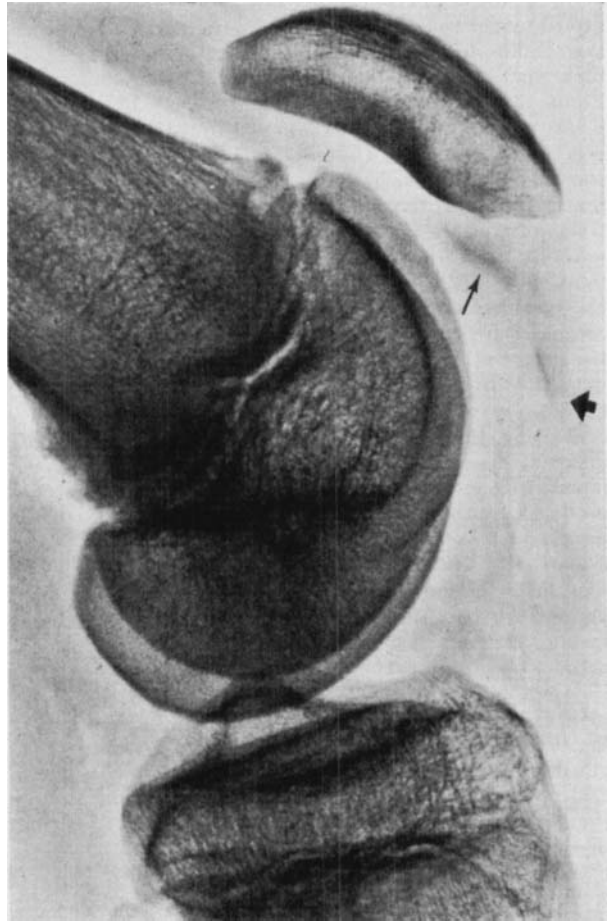
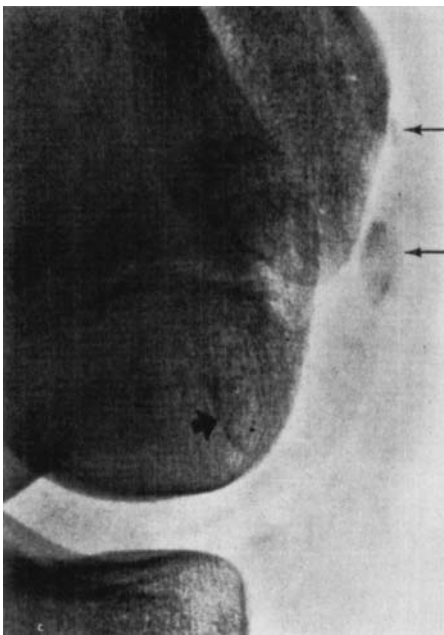


Figure 2. Oblique and lateral radiographs of the left knee immediately after injury. Thin arrows indicate fragments of bone avulsed from the patella by the lateral longitudinal patellar retinaculum, thick arrows a fragment avulsed by the medial longitudinal patellar retinaculum. The patella has been retracted proximally as a result of distal disinsertion of the patellar ligament.

the retinacula, never in the bone. The results are given in Table 1.

Table 1. Results of loading experiments.

Sex	Age (years)	Maximum load (Newton) at failure
M	38	1130
M	62	930
M	55	880
M	60	1400
M	62	1200

DISCUSSION AND CONCLUSION

If lateral radiographs in a case of traumatically produced patella alta reveal

bone fragments distal to the patella and there is no corresponding defect at the apex (cf. Figure 2), avulsion fractures produced by the longitudinal patellar retinacula should be suspected. Further information can then be obtained by oblique projections exposing the medial and lateral borders of the patella, and by a "sky-line" projection as in Figure 4. If the correct nature of the injury is not recognized from the start, the fragments might later be misinterpreted as loose bodies.

In the loading experiments the deformation rate was relatively slow. Using a more rapid rate, that would simulate an actual injury, the retinacula would prob-

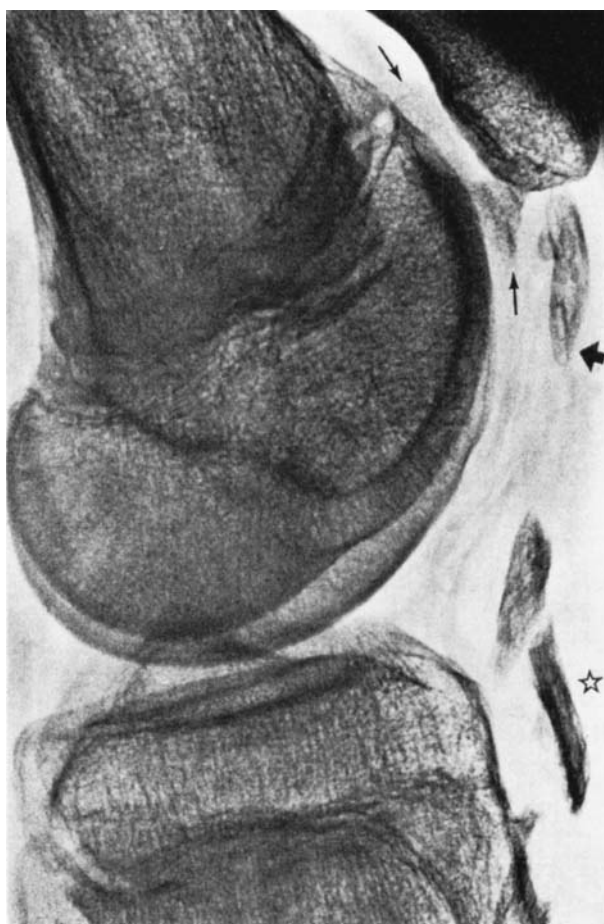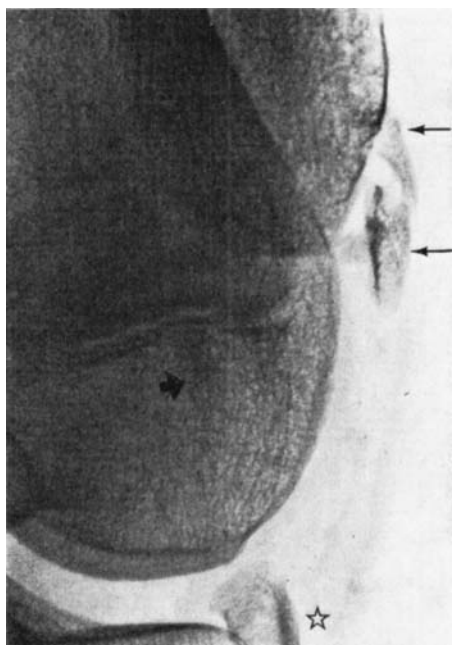


Figure 3. Oblique and lateral radiographs 5 months after injury. Thin arrows indicate pieces of bone formed from the fragments avulsed by the lateral longitudinal patellar retinaculum, thick arrows a piece of bone formed from the fragment avulsed by the medial longitudinal patellar retinaculum (compare with Figure 2). Asterisks indicate two pieces of bone formed at the distal end of the disinserted patellar ligament (compare with lateral view in Figure 2).

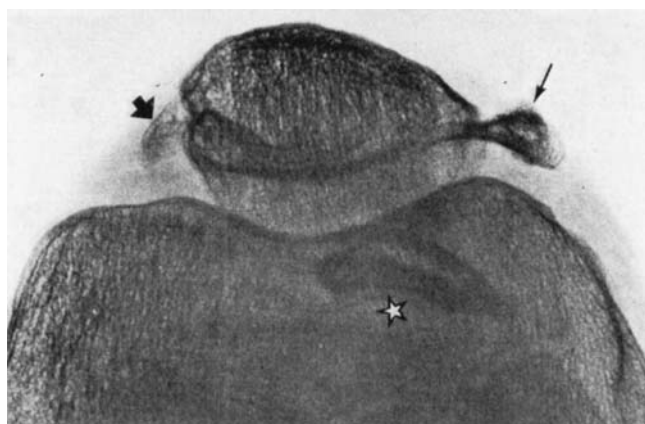


Figure 4. "Sky-line" view of the knee 5 months after injury. (For indications see text to Figure 3).

Figure 6. The principle for the loading experiments. After division of the patellar ligament, the only structures opposing distension of the specimen are those parts of the medial and lateral longitudinal patellar retinacula that are attached to the patella.

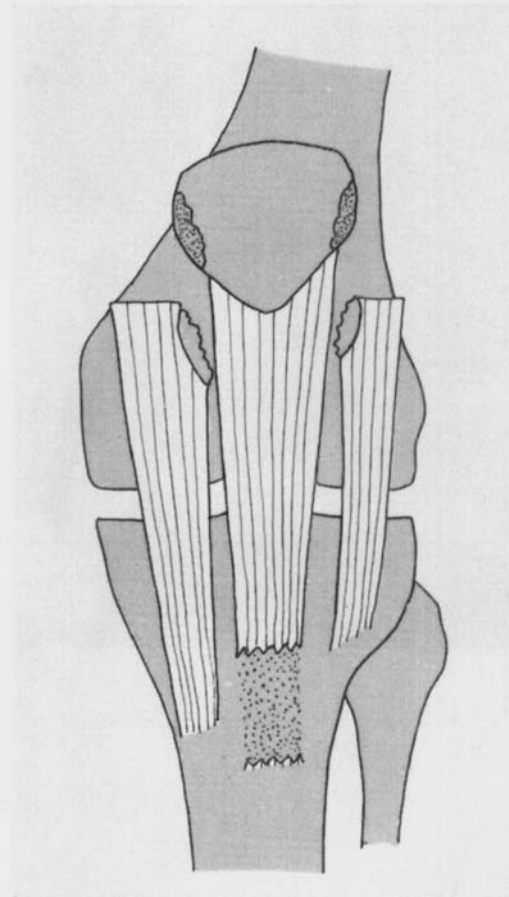


Figure 5. The lesion in the reported case: distal disinsertion of the patellar ligament and avulsion fractures of the patella produced by the medial and lateral longitudinal patellar retinacula.

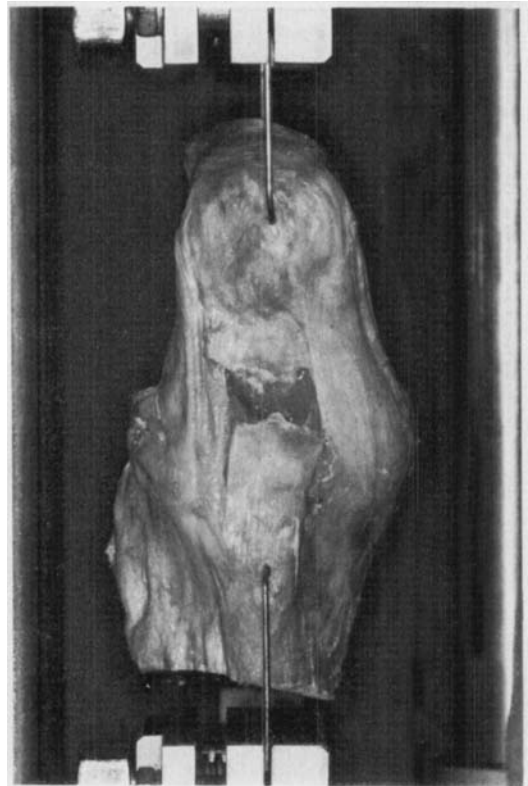
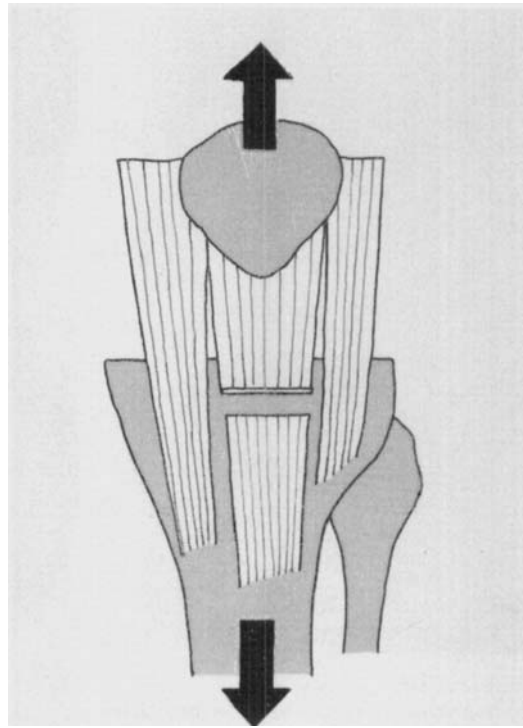


Figure 7. Cadaver specimen, prepared according to Figure 6, is being tested in tension to failure on an Alvetron testing machine.

ably have tolerated even more load before failure (cf. Noyes et al. 1974). The results of the loading experiments show that the medial and lateral longitudinal patellar retinacula are strongly attached to the patella and are thus capable of producing avulsion fractures when the extension apparatus of the knee is forcibly overloaded.

REFERENCES

- Anson, B. J. & Maddock, W. G. (1958) *Calander's surgical anatomy*, p. 1005. W. B. Saunders Company, Philadelphia and London.
- Noyes, F. R., DeLucas, J. L. & Torvik, P. J. (1974) Biomechanics of anterior cruciate ligament failure: An analysis of strain-rate sensitivity and mechanisms of failure in primates. *J. Bone Jt Surg.* **56-A**, 236-253.

Correspondence to: Lars Peterson, M.D., Department of Orthopaedic Surgery II, Sahlgren Hospital, S-413 45 Göteborg, Sweden.