

INTRAOSEOUS LIPOMA OF THE CALCANEUS

Report of a Case and a Short Review of the Literature

MIKKO POUSSA¹ & TEDDY HOLMSTRÖM²

¹ Department of Orthopedics and Traumatology, University Central Hospital, Helsinki, and ² Third Department of Pathology, University of Helsinki, Helsinki, Finland.

One case of an intraosseous lipoma of the calcaneus bone is presented together with a short review of the literature. Only 20 cases of tumors in the extremities have so far been published. The typical X-ray picture shows a cystic, sharply demarcated cavity, which macroscopically at operation is filled with yellowish, adipose tissue. In the present case and one previously published a central sclerotic mass was observed. The histological picture is typical, with mature adipose tissue mixed with a few degenerated bone trabeculae.

Key words: intraosseous lipoma; calcaneus

Accepted 20.v.76

Despite the large amount of adipose tissue in bone marrow, intraosseous lipomas are very rare tumors. Since the first report by Wehrsig in 1910 of a lipoma in the proximal part of the fibula, 20 cases of intraosseous lipomas of the limbs have been reported. For intraosseous lipoma, Dahlin (1967) has reported an overall incidence of one per 1,000 bone tumors. Periosteal lipomas are much more common, and if the tumor corrodes the underlying bone, the true point of origin of the lipoma is difficult to ascertain (Caruolo & Dahlin 1953).

Child reported the first case of intraosseous lipoma in the calcaneus bone in 1955 and Appenzeller & Weitzner reported an additional case in 1974.

We report one further case with emphasis on the typical X-ray and histological picture.

CASE REPORT

The patient, a 41-year-old female dentist, was admitted to hospital in 1973 when an X-ray, taken because of painful ankles, revealed a cyst in the left heel bone. She recalled a weak contusion trauma to both feet 20 years earlier. She had suffered from pain in the joints of her hands and feet for 10 years, but nothing specific was revealed in the examinations. In 1965 an arthrotomy was performed on her left knee joint; both menisci were ruptured and removed.

The physical examination for the present disease showed nothing abnormal and the laboratory analyses were all normal.

The X-ray showed a 2 × 2.5 cm, sharply demarcated cyst, with a 5 × 10 mm large sclerotic nidus in the center, in the collum of the calcaneus (Figure 1). The radiologic diagnosis was benign bone cyst.

Curettage of the lesion was performed on May 29, 1973, under general anesthesia. The specimen consisted of yellowish, adipose tissue with two harder fragments in the middle. The cyst was filled with spongy bone.

Histological examination revealed mature adipose tissue, in which a small amount of thin, often degenerated bone trabeculae could be found (Figure 2). In the middle of the tumor

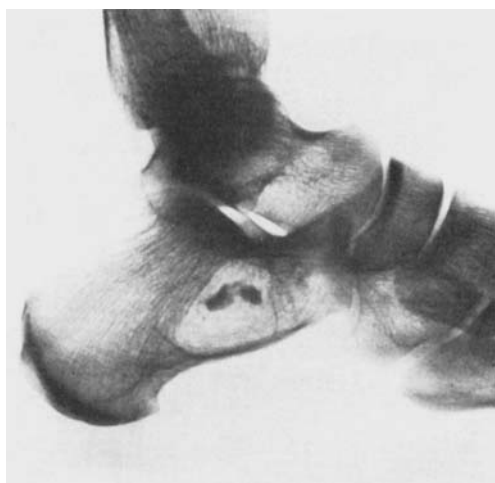


Figure 1. Lateral radiograph of left calcaneus. Note the sclerotic nidus in the center of the well circumscribed cyst.

irregular areas of cell-free, amorphous, calcified tissue were seen (Figure 3). Adjacent to these areas the tumor was rich in thin collagen fibers.

The number of blood vessels was not prominent. Hemosiderin was not present. No cellular atypia or other signs of malignancy could be detected. Both radiographic and histological findings were typical for intraosseous lipoma.

DISCUSSION

The most common location for intraosseous lipomas of the extremities is the metaphysis of the long bones. Table 1 summarizes the cases published so far. No predilection for age or sex is observed. The symptoms, if present, are nonspecific. Pain and swelling or both, especially after exercise, are the most common symptoms and have often been present for many years. In the case reported here, the patient was asymptomatic.

The radiographic picture of intraosseous lipoma is not specific. In fact almost all cases had been diagnosed as other benign cystic lesions of bone and even incorrect malignant diagnoses had

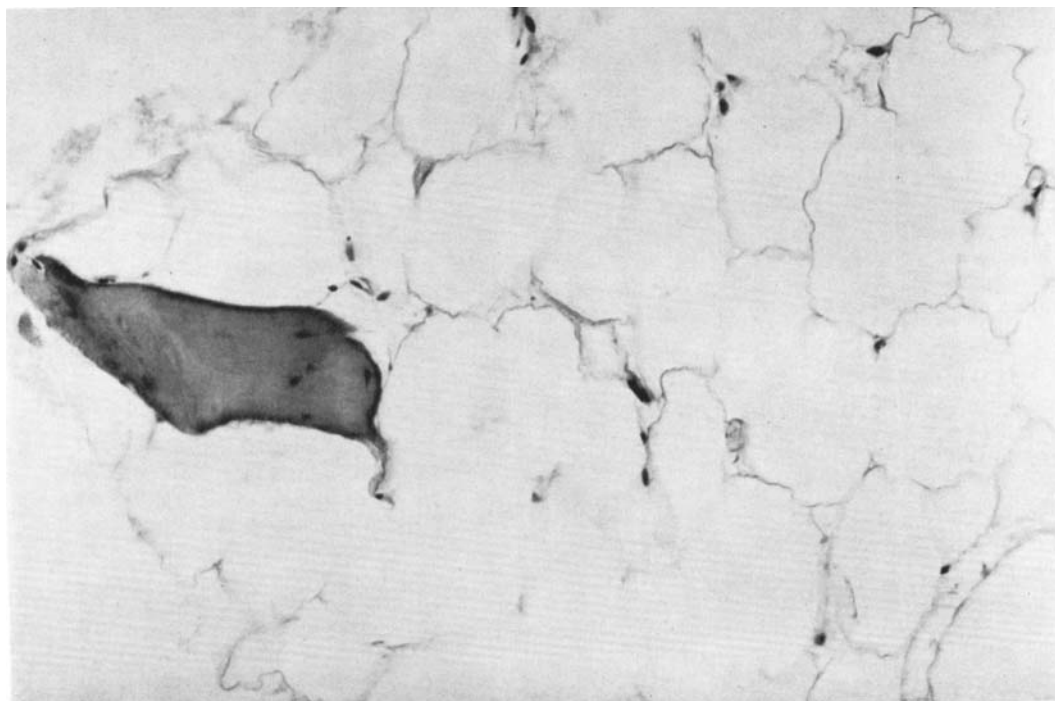


Figure 2. Photomicrograph showing mature adipose tissue and a thin, partly atrophic bone trabecula. (H & E, × 400).

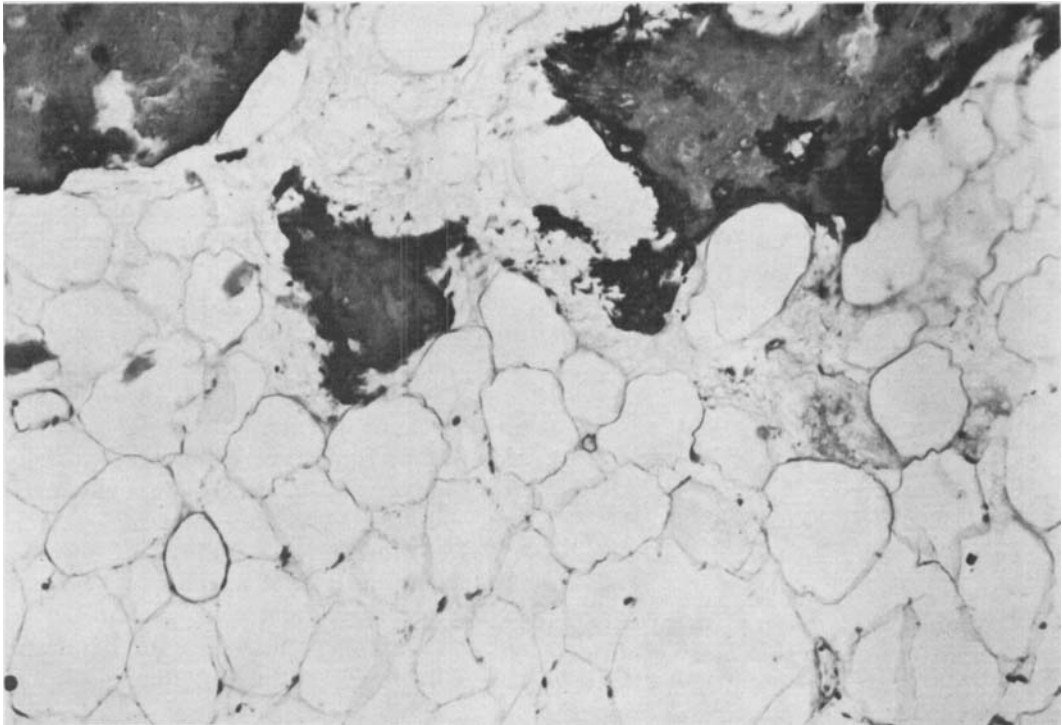


Figure 3. Photomicrograph from the central part of the tumor showing irregular, calcified, cell-free masses in mature adipose tissue. Note thin collagen fibers adjacent to the calcifications. H & E, $\times 180$.

Table 1. Locations of the intraosseous lipomas of the limbs reported in the literature.

Location	Number	Sex	Age (years)	Author and year
Proximal femur	1	Male	62	Dahlin 1967
Distal femur	2	?	?	Brault 1901
Proximal tibia	4	Female	58	Gennari & Bozzetti 1965
		Female	32	Mastromarino & Assennato 1957
		Male	21	Salzer & Salzer-Kuntschik 1965
		Male	30	Bagnoud et al. 1967
Distal tibia	2	Female	33	Hart 1973
		Male	30	Dickson et al. 1951
		Male	14	Mueller & Robbins 1960
Proximal fibula	2	Female	5 ½	Wehrsig 1910
		Female	57	Smith & Fienberg 1957
Distal fibula	3	Male	15	Peloux et al. 1965
		Female	20	Thevenot et al. 1965
		Male	14	Azizi 1968
Calcaneus	3	Male	22	Child 1955
		Male	59	Appenzeller & Weitzner 1974
		Female	41	Poussa & Holmström 1976
Proximal humerus	2	Male	56	Skinner & Fraser 1957
		Male	41	Kaganskii 1963
Proximal ulna	1	Male	44	Caruolo & Dahlin 1953
Distal phalanx, thumb	1	Female	70	Ackerman & Spjut 1962

been suggested (Caruolo & Dahlin 1953). The usual appearance is a radiolucent, well circumscribed, cystic lesion within the marrow cavity and expansion and subperiosteal bone formation are sometimes seen. Trabeculae, producing a loculated appearance, are seen in many of the lesions. In one previous case (Appenzeller & Weitzner 1974) a central, sclerotic nidus was demonstrated, and in the present case the X-ray picture is analogous.

In all cases reported, the histological picture is typical for lipoma. Mostly thin atrophied bone trabeculae are seen in the mature adipose tissue. In only two cases were the trabeculae missing (Caruolo & Dahlin 1953, Thevenot et al. 1965), and in the present as well as one previous case (Appenzeller & Weitzner 1974) a central area of calcified material is seen. Cellular atypism, cellularity or some other evidence of confusion with liposarcoma have not been reported, and the differential diagnosis between lipoma and liposarcoma should not be difficult.

The exact nature of intraosseous lipoma has been widely debated in the literature and the pathogenesis has been extensively discussed by Hart (1973). Most authors, however, agree upon a true benign neoplasm arising in the adipose tissue of bone medulla. Central calcification is most probably caused by hemorrhage that may have been traumatically induced in a pre-existing lipoma. In the present case, as well as in many previous cases (Mueller & Robbins 1960, Smith & Fienberg 1957, Bagnoud et al. 1967) the history of trauma is positive. Appenzeller & Weitzner (1974) also strongly support trauma as an etiological factor, although their own case is negative in that respect.

The therapy should be curettage and filling of the cavity with cancellous bone. More radical surgery is not needed and no recurrences have been reported to our knowledge.

REFERENCES

- Ackerman, L. V. & Spjut, H. J. (1962) Tumors of bone and cartilage. In: *Atlas of tumor pathology*, Section 2, fascicle 4, pp. 163-164. Armed Forces Institute of Pathology, Washington D.C.
- Appenzeller, J. & Weitzner, S. (1974) Intraosseous lipoma of os calcis. Case report and review of the literature of intraosseous lipoma of extremities. *Clin. Orthop.* **101**, 171-175.
- Azizi, D. (1968) Le lipoma intra-osseux: A propos d'un cas. *J. Chir. (Paris)* **96**, 557-562.
- Bagnoud, F., Thèvoz, F. & Taillard, W. (1967) Le lipoma intra-osseux, expression d'un infarctus chronique: A propos d'un cas. *J. Chir. (Paris)* **94**, 165-176.
- Brault, A. (1901) Des tumeurs. In: *Manuel d'Histologie pathologique*, p. 393. Cornil & Ranvier, Paris.
- Caruolo, J. E. & Dahlin, D. C. (1953) Lipoma involving bone and simulating malignant bone tumor: Report of a case. *Proc. Mayo Clin.* **28**, 361-363.
- Child, P. L. (1955) Lipoma of the os calcis: Report of a case. *Amer. J. clin. Path.* **25**, 1050-1052.
- Dahlin, D. C. (1967) *Bone tumors: General aspects and data on 3987 cases*, 2nd ed., pp. 110-113. Charles C Thomas, Springfield.
- Dickson, A. B., Ayres, W. W., Mason, M. W. & Miller, W. R. (1951) Lipoma of bone of intraosseous origin. *J. Bone Jt Surg.* **33-A**, 257-259.
- Gennari, L. & Bozzetti, F. (1965) Un raro caso di lipoma intramidollare del femore. *Tumori* **51**, 457-459.
- Hart, J. A. L. (1973) Intraosseous lipoma. *J. Bone Jt Surg.* **55-B**, 624-632.
- Kaganskii, V. E. (1963) Lipoma kosti. *Vopr. onkol.* **9**, 97.
- Mastromarino, R. & Assenato, G. (1957) Lipoma intraosseo. *Ortop. Traum. mot.* **25**, 1077-1084.
- Mueller, M. C. & Robbins, J. L. (1960) Intramedullary lipoma of bone. *J. Bone Jt Surg.* **42-A**, 517-520.
- Peloux, Y., Thevenot, P. & Bouffard, A. (1965) Le lipome intramédullaire osseux. *Pressé med.* **73**, 2057-2058.
- Salzer, M. & Salzer-Kuntschik, M. (1965) Zur Frage der sogenannten zentralen Knochenlipome. *Beitr. path. Anat.* **132**, 365-375.
- Skinner, G. B. & Fraser, R. G. (1957) Medullary lipoma of bone. *J. Canad. Ass. Radiol.* **8**, 19-21.
- Smith, W. E. & Fienberg, R. (1957) Intraosseous lipoma. *Cancer* **10**, 1151-1152.

- Thevenot, P., Peloux, Y. & Michelin, C. (1965) Wehrsig, G. (1910) Lipoma des Knochenmarks.
Le lipome intramédullaire osseux: A propos d'un deuxième cas observé au Dahomey. *Med. trop.* **25**, 745-748. *Z. Allg. Pathol.* **21**, 242-247.

Correspondence to: Teddy Holmström, M.D., Third Department of Pathology, Haartmaninkatu 3, SF-00290 Helsinki 29, Finland.