

PAIN IN OSTEOID OSTEOMA: HISTOLOGICAL FACTS

J. ESQUERDO, C. F. FERNANDEZ & F. GOMAR

Orthopedic Department and Pathology Department, Faculty of Medicine, Valencia, Spain.

Six cases of osteoid osteoma were studied histologically using the Gross technique. When the nidus is located centrally, it is reached by amyelinic fibers accompanying the vessel branches or as independent fibers. The pain is generally considered to reflect changes in vessel pressure and it could also be due to direct irritation of the nerve fibers included in or near the calcification focus.

Key words: osteoid osteoma, pain, innervation; painful bone tumors

Accepted 18.v.76

Since the first descriptions of osteoid osteoma (Jaffe 1935), pain has been noted as its most significant symptom. Nevertheless, painless osteoid osteoma does exist (Jaffe & Lichtenstein 1940, Sevitt & Horn 1954), particularly in children (De Wet 1967).

Sherman (1947), using the silver technique, tried to prove the existence of axons in the interior of the osteoid osteoma in the "nidus". Chandler & Kael (1950) found perivascular sympathetic nerve fibers in the compact trabeculae on the periphery of the nidus to be the cause of vasculomotor alterations but not to be transmitters of pain. Golding (1954) believed the pain to be of vascular origin due to intraosseous hypertension in the sclerotic bone.

Catto & Cairns (personal communication quoted by Byers 1968) were able to detect axons in the "nidus" using the Bielschowski technique. Sherman & McFarland (1965), in their histological study of 21 osteoid osteomas, found clear evidence of nerve fibers, which they interpreted as belonging to the autonomous

nervous system, in 15 of the cases. These fibers would be capable of transmitting changes in intraosseous pressure.

In order to confirm these findings and to search for new information we have studied all available osteoid osteomas using suitable histological techniques.

MATERIAL AND METHODS

Between 1970 and 1975, 14 osteoid osteomas and one osteoblastoma were treated in the Orthopedic Department of the Faculty of Medicine, Valencia.

The ages of the patients varied from 5 to 47 years old, being mainly between 5 and 15; eight were males and six females. The localizations of the tumors were: five in the femur, five in the tibia, two in the phalanx of the hand, one in the second metatarsal and one in the clavicle. The osteoblastoma was located in the 6th rib on the left side in a 16-year-old girl.

Local and regional pain existed in all cases; in six cases it was relieved by aspirin. The time period from the first symptom to the histological diagnosis ranged between 3 months and 4 years. The average period was 8 months.

The tumor was surgically removed in 13 of the cases. A single case was treated by "curettage". All cases were completely healed without

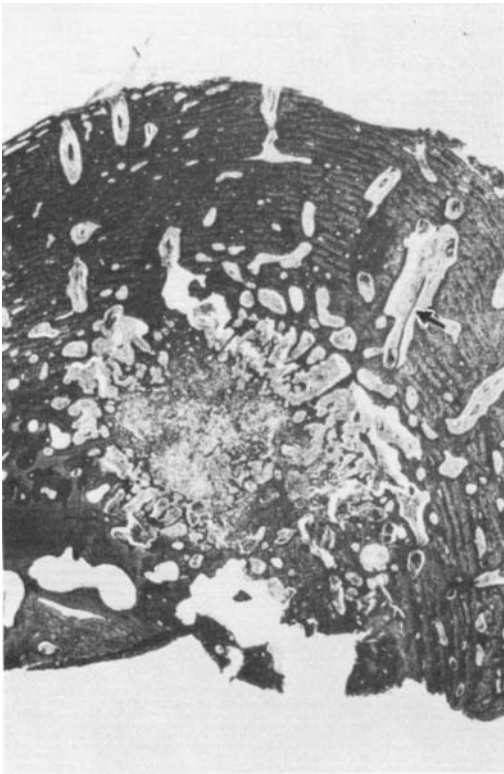


Figure 1A. Cross section of an osteoid osteoma in which the vascular channels penetrate the periosteum perpendicularly towards the "nidus". The arrow indicates the amyelinic fibers in one of these channels.

any complications, the pain vanishing altogether. The last six cases were examined with suitable silver techniques to demonstrate neurofibrils.

Cross sections 2-3 mm thick were fixed in a neutral solution of 10 per cent formaldehyde for a period of 7 to 14 days and decalcification with 7.5 per cent EDTA was carried out for 20 to 30 days. Complete decalcification was not considered necessary. Sections $12\ \mu$ thick were cut after freezing, then washed to remove the EDTA. They were placed in a neutral solution of 10 per cent formaldehyde for 2-4 days before dyeing with the Gross technique according to Ramon Y Cajal & Castro (1972).

RESULTS

The sections showed a perfect picture of osteoid cells and their canaliculi; the

ground substance and cellular nucleus were dyed a pale ochre color and the nerve fibers were dyed an intense black as were the calcium mass and granules that were later removed during the decalcification process.

Some cases showed bundles of amyelinic fibers, penetrating perpendicularly along the vessel spaces from the periosteum and through the reactive sclerotic cortex (Figure 1). The number of nerve fibers varied, but in all cases it was possible to find 5-10 amyelinic fiber bundles in the neighborhood of the vessels (Figure 2) branching off and going through the marrow spaces of the newly formed bone (Figure 3).

In the nidus, among osteoblasts and

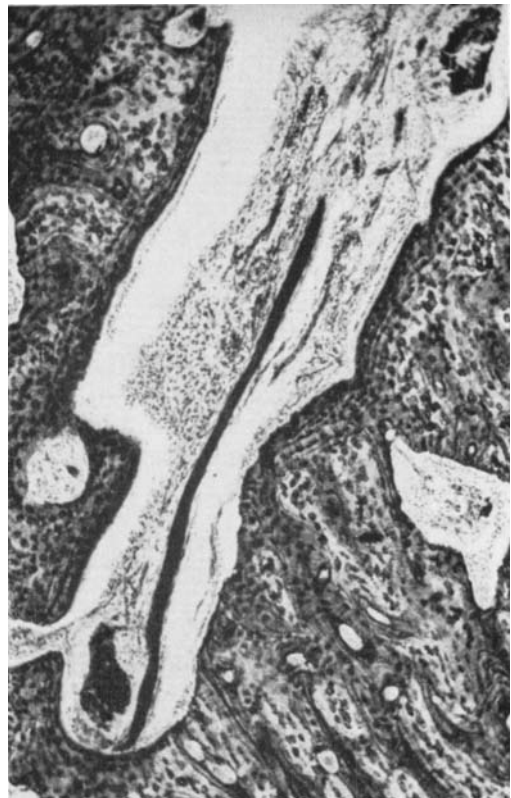

Figure 1B. A detail of the previous figure showing the dense grouping of amyelinic fibers near the vessels.

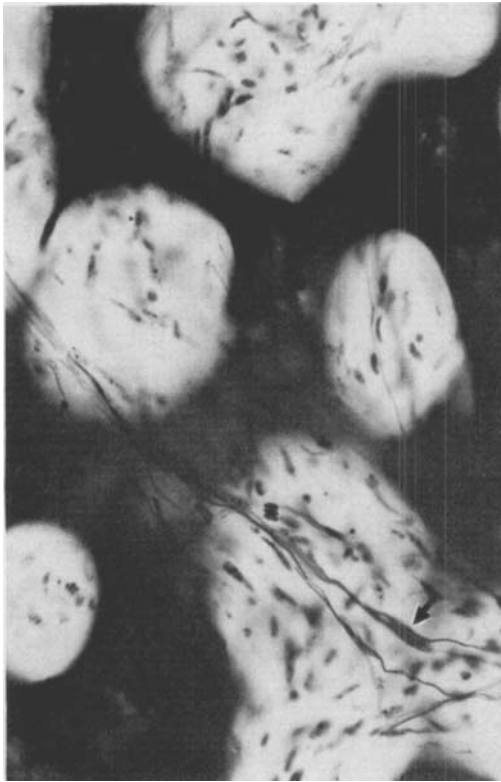

Figure 2 A. Osteoblastoma of the rib. There is an osteogenic reaction on the periphery with obvious amyelinic fibers going through the marrow spaces.

calcified osteoid we could identify a great number of isolated amyelinic fibrils and attached to them typical Schwann cells (Figure 2 A). It was not possible to identify nervous structures in the completely calcified nidus.

DISCUSSION

It is possible to detect innervation of benign osteogenic tumors (osteoid osteoma and osteoblastoma) with careful fixation techniques and decalcification and specific silver dyeing techniques of the Bielschowski type (Schulman & Dorfman 1970, Byers 1968).

The origin of the nerve fibrils de-

scribed possibly depends on their localization. If the nidus is located centrally, it is reached by fibril branches penetrating the bone with the nutrient artery and accompanying the vessel branches (paravascular fibrils) or spreading into the bone marrow as independent fibers. When the "nidus" is near the cortex or under the periosteum, the innervation comes from the fibrils following the haversian perivascular spaces and from the extrasosseous periostic fibers, as observed in three or four of our cases and according to Schulman & Dorfman (1970).

The etiology of this obvious innervation is unknown. Its distribution is similar to that of the glomus tumor.

The pain associated with osteoid osteoma is generally explained as due to

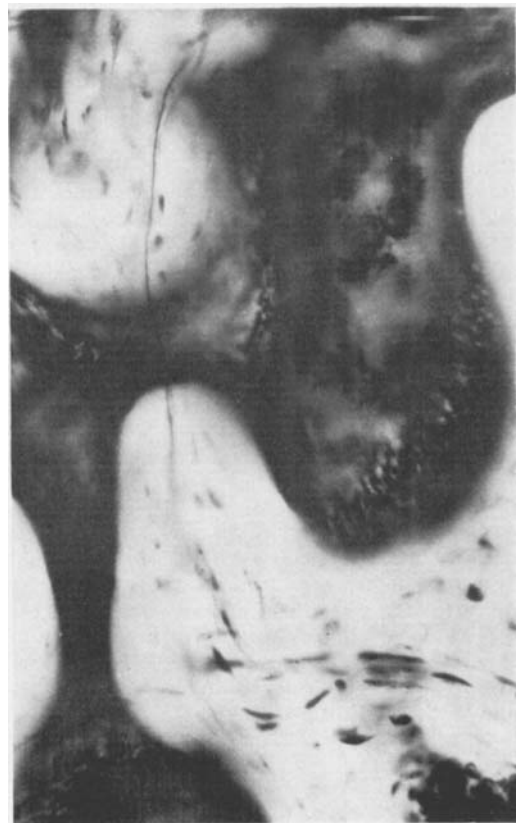

Figure 2 B. An isolated amyelinic fiber going through marrow spaces.

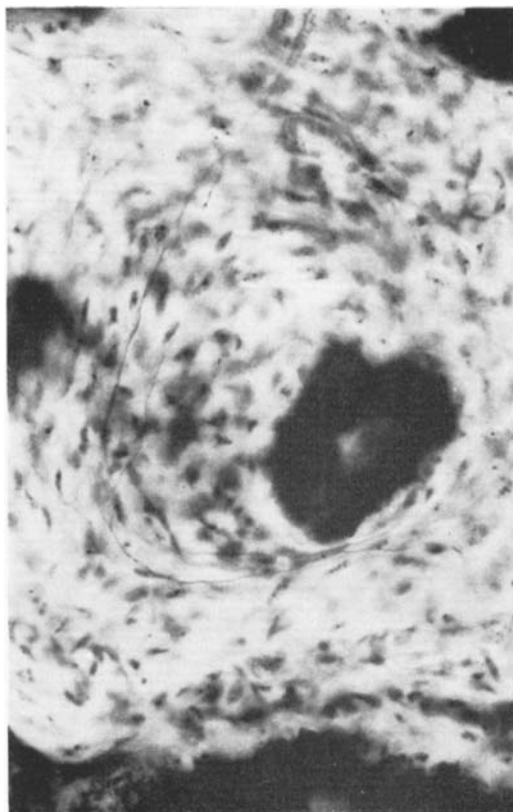


Figure 3A. Osteoid osteoma. In the "nidus" several amyelinic fibers are included in the fibrovascular tissue near the calcification focus.

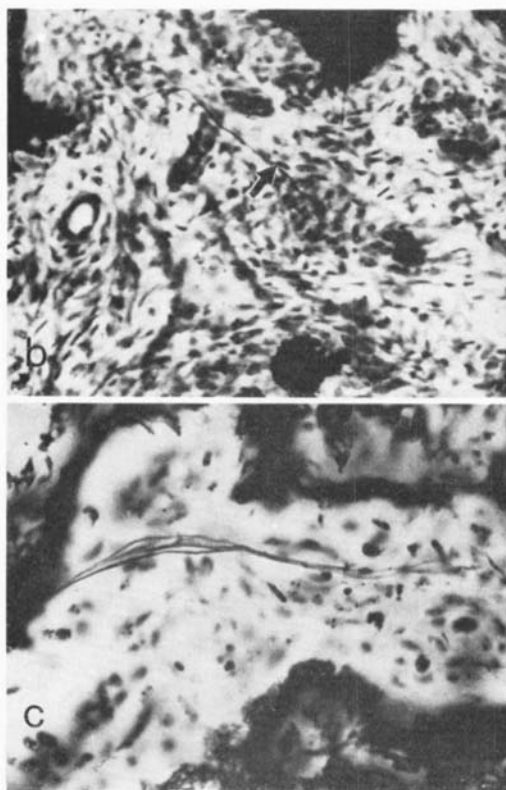


Figure 3B and C. Isolated fibers (arrow) or fibers in groups of 3-5 within the calcified material, only partially visible due to decalcification.

changes in the vessel pressure being registered by the abundant innervation present (Golding 1954, Sherman & McFarland 1965). Another explanation would be direct irritation of the nerve fibers included in or near the calcification focus.

REFERENCES

- Byers, P. D. (1968) Solitary benign osteoblastic lesions of bone. Osteoid osteoma and benign osteoblastoma. *Cancer* **22**, 43-57.
- Chandler, F. A. & Kael, H. I. (1950) Osteoid osteoma. *Arch. Surg.* **60**, 294-304.
- De Wet, I. S. Review of the literature with a report of five cases of osteoid osteoma. *S. Afr. J. Surg.* **5**, 13-24.
- Golding, J. S. E. (1954) The natural history of osteoid osteoma. *J. Bone Jt Surg.* **36-B**, 218-226.
- Jaffe, H. L. (1935) Osteoid osteoma. A benign osteoblastic tumor composed of osteoid and atypical bone. *Arch. Surg.* **31**, 709-728.
- Jaffe, H. L. & Lichtenstein, L. (1940) Osteoid osteoma. Further experience with this benign tumor of the bone. *J. Bone Jt Surg.* **22**, 645-682.
- Lichtenstein, L. (1972) *Bone tumors*, 4th ed., p. 89. Mosby Company, St. Louis.
- Ramon Y Cajal, S. & Castro, F. (1972) *Elementos de técnica micrográfica del sistema nervioso*. 2nd ed. p. 105. Salvat Edit., Barcelona.
- Schajowicz, F. & Lemos, C. (1970) Osteoid osteoma and osteoblastoma. *Acta orthop. scand.* **41**, 272-291.
- Schulman, L. & Dorfman, H. D. (1970) Nerve fibers in osteoid osteoma. *J. Bone Jt Surg.* **52-A**, 1351-1356.
- Sevitt, S. & Horn, J. S. (1954) A painless and

- calcified osteoid osteoma of the little finger. *J. path. Bact.* **67**, 571-574.
- Sherman, M. S. (1947) Osteoid osteoma. *J. Bone Jt Surg.* **29**, 918-930.
- Sherman, M. S. & McFarland, G. (1965) Mechanism of pain in osteoid osteoma. *Sth. Med. J. (Bgham, Ala)* **58**, 163-166.
- Souza Dias, L. & Frost, H. M. (1974) Osteoid osteoma—Osteoblastoma. *Cancer* **33**, 1075-1081.

Correspondence to: Professor F. Gomar, Colon, 31 Valencia, Spain.