

THE HALLUX AND RHEUMATOID ARTHRITIS

JOHN R. KIRKUP¹, EULER VIDIGAL¹⁻² & RICHARD K. JACOBY¹⁻²

¹ The Royal National Hospital for Rheumatic Diseases, and the Royal United Hospital, Bath; and the ² University Department of Medicine and Orthopaedics, Bristol Royal Infirmary, Bristol, Avon, England.

The purpose of this report is to consider involvement of the great toe by rheumatoid arthritis, defining significant deformities, describing clinical patterns and discussing the pathomechanics of these findings, in what is an ongoing disease. 200 consecutive patients admitted to hospital with classical or definite rheumatoid arthritis were screened for pain or deformity of the great toe. Feet that had undergone previous surgery or had other underlying pathology were excluded from the series. 194 feet were found to have hallucal involvement. Although hallux valgus was the commonest deformity it was found in combination with other significant deformities in many cases. Hallux rigidus was an important lesion in this series as was interphalangeal hyperextension. Other important lesions encountered were metatarsus primus varus and medial rotation of the toe; their relationship to hallux valgus is discussed.

Key words: hallux valgus; hallux rigidus; rheumatoid arthritis.

Accepted 14.vi.77

Foot disability in rheumatoid arthritis is common (Vainio 1956, Vidigal et al. 1975), and frequently involves the hallux early in the disease. Indeed symptoms in the first metatarso-phalangeal joint may precipitate local surgical intervention before the disorder's general nature is evident. This may result in complaints by the patient that surgery caused the arthritis, aggravated foot problems or contributed nothing towards their relief. This prompted an analysis of the significant hallucal deformities in a group of hospital patients with established rheumatoid arthritis. This paper does not discuss the treatment of individual conditions of the great toe because every patient requires a different programme of manage-

ment. The joints of the foot, knee and hip can dictate what sort of operation or conservative measure is necessary, not to mention the general medical state of the patient, so that any didactic statements about therapy would be misleading.

PATIENTS AND METHODS

Consecutive admissions to the rheumatology and orthopaedic wards were assessed for foot pain and deformity in the presence of "classical" or "definite" rheumatoid arthritis (Ropes et al. 1959). Out of 200 patients affected with the disease for more than a year (mean 12.9 years), significant findings involving the forefoot, hind-foot or both were observed in 104 patients.

Assessment of functional capacity (Steinbrocker et al. 1949), sites of pain, evidence of circula-

tory or neurological deficit, the presence of swelling, callosities, bursae, sinuses, nail changes and the state of footwear were made. With the patient supine and knee extended, angular relationships between the first metatarsal bone and phalanges were measured with a goniometer; similarly passive movements of the joints were estimated. Ideally observations should be made standing on a firm surface; in practice this is difficult and the supine examination was a compromise. In this position active movement cannot achieve the functional range possible when erect, thus passive estimations were necessary; for example, the normal hallux dorsiflexes to 90° or more when the phalanges are subjected to body-weight, yet supine, active contraction may achieve only 60° or less.

Radiographs and photos of the standing fore-foot display halluical deformities most clearly and are essential for measuring metatarsus primus varus accurately. Patients with valgus or varus hindfeet, or those who were unable to stand barefoot could not be recorded in this way. The relationship of the first metatarsal, the sesamoids and the remaining metatarsal heads was demonstrated in tangential partial weight-bearing radiographs (Dixon & Gheith 1973).

DEFORMITIES

The major deformities, as defined below, were hallux valgus (Figure 1a), hallux rigidus (Figure 1b), and "Chisel-toe" (Figure 1c). Less common and less disabling deformities were hallux elevatus (Figure 1d), interphalangeal claw toe, interphalangeal valgus (Figure 1a), interphalangeal fusion, hallux varus, and metatarso-phalangeal dislocation (Table 1).

Of 104 patients examined, four had undergone bilateral and four unilateral surgery of the hallux. Rejection of these, and a further foot subjected to ankle fusion and one affected by poliomyelitis left 100 patients with 194 feet for analysis. Bilateral deformity was recorded in 70 patients and unilateral deformity in 23. If one recalls the 12 feet excluded by previous surgery, we conclude that over 50 per cent of patients with rheumatoid arthritis may suffer from foot disability and of these approximately 90 per cent will manifest significant great toe deformity in one or both feet.

Hallux valgus

Deformity was considered significant when the proximal phalanx deviated laterally on the metatarsal at least 21° as measured by standing radiographs or photographs (Figure 1a), and involved 114 feet of which 99 exhibited a "bunion" as indicated by skin pressure signs of reddening and thickening: bursal formation with underlying bony hypertrophy characteristic of non-rheumatoid hallux valgus was unusual. Six feet with hallux valgus of 20° or less also displayed "bunion" formation whilst 15 feet with hallux valgus between 21° and 50° did not, being patients who walked little, wore soft slippers or individually cast seamless shoes. This would suggest that "bunion" formation is a function of tight footwear rather than the extent of deviation. Four feet with mild to moderate hallux valgus (15°, 19°, 25° and 38°) exhibited septic "bunions" with sinuses suggesting that patients with more severe deviation had learned how to select more suitable footwear.

Radiographic evidence of erosions and irregularity of the first metatarso-phalangeal joint were noted in 98 (86 per cent) of the 114 feet with hallux valgus (Table 2): of the toes without X-ray change, valgus varied from 25° to 63°.

Metatarsus primus varus

Divergence between the long axes of the first and second metatarsal of 10° or more (Figure 1a) is a well recognised association with hallux valgus of non-rheumatoid origin and we confirmed a similar association in rheumatoid patients with angles between 10° and 25° in 89 out of 100 feet with suitable radiographs. Significant metatarsus primus varus was observed in a few feet with hallux valgus of less than 20° but increasing severity of valgus was generally correlated with increasing metatarsal deviation (Figure 2). Of 47 toes with valgus exceeding 40°.

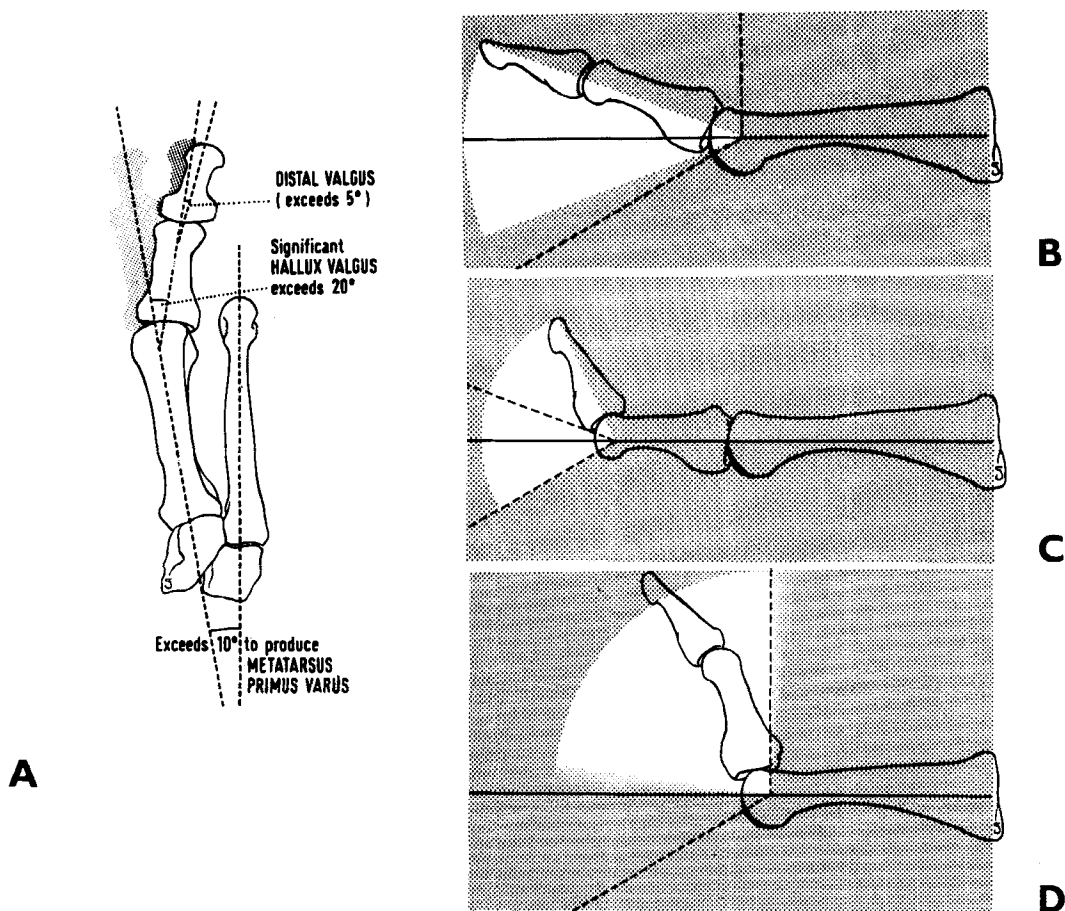


Figure 1. A. Diagram to show the angular relationships measured on weight-bearing radiographs of the foot.

B. Hallux rigidus—limited arc movement at the metatarso-phalangeal joint. The maximum dorsiflexion as defined is 20° (unshaded arc) whereas the normal range is shown by the interrupted line.

C. Chisel toe—the distal phalanx maintains an extended posture having an arc of dorsiflexion beyond 20° (interrupted line) at the interphalangeal joint.

D. Hallux elevatus—absent range of plantar flexion at the metatarso-phalangeal joint.

Table 1. Summary of the 266 deformities that were found in 194 feet.

Deformity	Bilateral	Unilateral	Total feet	Percentage of all the feet at risk
Hallux valgus	42	30	114	59
Hallux rigidus	24	7	55	28
Chisel toe	12	19	43	22
Hallux elevatus	6	8	20	11
Interphalangeal claw	3	7	13	7
Interphalangeal valgus	4	5	13	7
Interphalangeal fusion	1	2	4	2
Metatarsophalangeal dislocation	1	1	3	< 2
Hallux varus	0	1	1	< 1
No measured deformity	7	16	30	15

Table 2. Summary of the radiological findings in 194 feet.

Target Joint	Erosive changes on X-ray	
	Present	Absent
<i>Interphalangeal joint</i>	57	137
Interphalangeal deformity	29	40
Chisel toe	20	23
Interphalangeal valgus	8	5
Interphalangeal claw	1	12
Interphalangeal fusion	4	0
No interphalangeal deformity	28	97
<i>Metatarsophalangeal joint</i>	145	49
Metatarsophalangeal deformity	126	27
Hallux valgus	98	16
Hallux rigidus	45	10
Hallux elevatus	17	3
Hallux varus	1	0
No metatarsophalangeal deform.	19	22
<i>First metatarso medial cuneiform joint</i>	44	144
Hallux valgus	30	84
Metatarsus primus varus > 10°	30	70
Interphalangeal and metatarso-phalangeal joints combined	42	15
First metatarso medial cuneiform joint and metatarso-phalangeal joint combined	39	5
Interphalangeal, metatarso-phalangeal and first metatarso medial cuneiform joints combined	13	31
Ankle and/or tarsal changes	121	73

metatarsus primus varus was 10° or more in every case. It is debatable whether metatarsal deviation initiates hallux valgus or is a compensatory sequel to subluxation of the proximal phalanx, nevertheless if the first metatarsal deviates excessively from the second then structural changes at their bases are inevitable. In this series radiographic erosions, sclerosis or fusions affecting the first metatarso-medial cuneiform joint, the interval between the first and second metatarsal bases or between medial and intermediate cuneiforms were observed (Table 2) in 44 feet and compared where possible with the angle of metatarsus primus varus. The latter was significantly greater in those feet with radiographic disease of the metatarsal base than those without ($P < 0.01$), the mean angles of metatarsus primus varus being 15.5° and 12.7°, respectively, denoting that basal disease, if not the primary cause, at least contributes to the more severe degrees of metatarsal deviation and hence hallux valgus itself.

Hallux tortus

Medial twisting or rotation of the phalanges about the first metatarsal long axis has received little attention although Hardy & Clapham (1951) recognised its

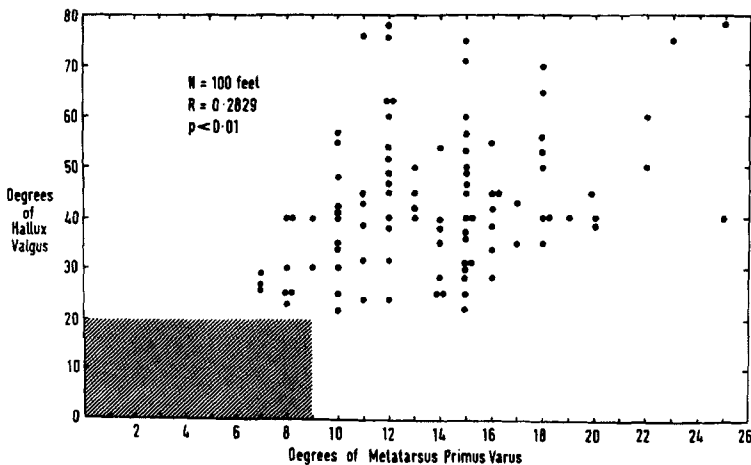


Figure 2. Graph showing the angle of hallux valgus plotted against the angle of metatarsus primus varus. The correlation is significant ($P < 0.01$). N = Number of X-rays. R = Correlation coefficient.

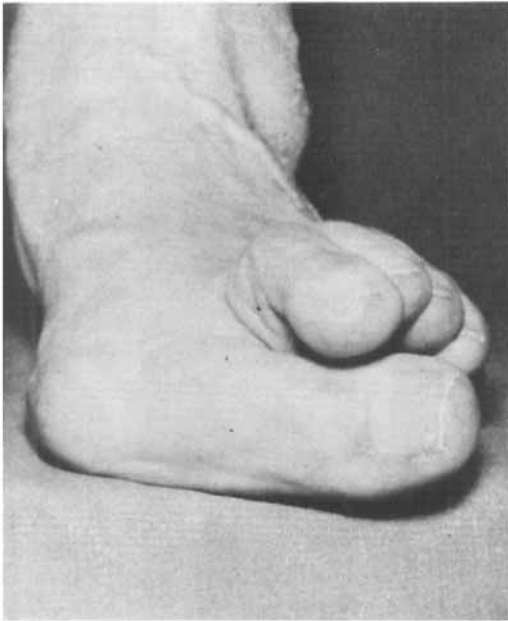


Figure 3. Hallux tortus. Medial rotation of the hallux in the presence of valgus deformity.

singular association with hallux valgus; however, they reported no accurate measurements to quantify the rotational displacement. In our patients, standing photographs taken of the toes end-on have been utilised to measure the angle made by the great-toe nail margin with respect to the plane of the floor (Figure 3), the nail normally being parallel to the floor. This angle was estimated to the nearest 5° and angles of 20° and above taken to

be significant although lesser degrees of rotation were uncommon without accompanying hallux valgus. Hallux tortus of more than 20° was always associated with hallux valgus (Figure 4). Not all valgus toes were twisted but of 42 toes with more than 40° hallux valgus, 36 (86 per cent) were rotated from 20° to 65°, many of which developed a characteristic callosity medial to the interphalangeal

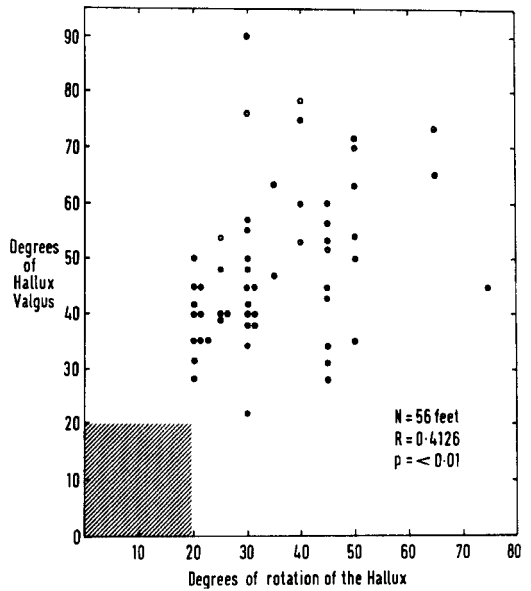


Figure 4. Graph showing the angle of hallux valgus plotted against the rotational angle of tortus. There is a positive correlation which is significant ($P < 0.01$). N = Number of feet measured, R = Correlation coefficient.

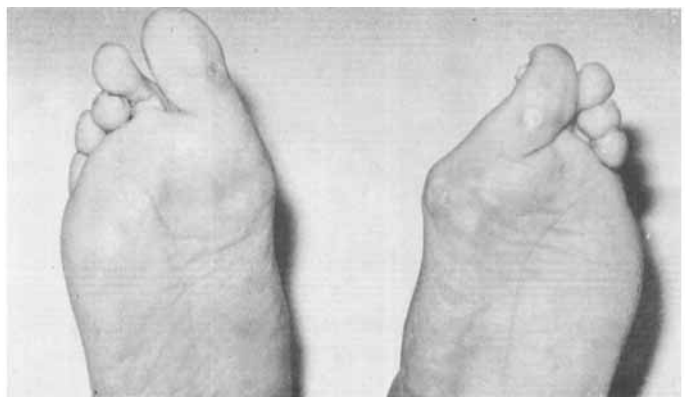

Figure 5. Hallux tortus. Plantar callosities are present under the medial aspect of the interphalangeal joint.

joint (Figure 5) a source of complaint in addition to their "bunion". Significant rotation was bilateral in 23 patients. In two the twist was reversed or lateral, one being a case of hallux varus and one of hallux elevatus. Lateral tortus was also recorded in another case of hallux varus, a sequel to excision arthroplasty for hallux valgus.

Hallux rigidus

Terminology with respect to mobility of the first metatarso-phalangeal joint is confusing for by definition rigidus implies complete fixity; nevertheless, this quality applies to those rheumatoid joints achieving bony fusion following severe and prolonged disease. However, in current practice hallux rigidus encompasses mobile yet restricted joints (Mercer & Duthie 1964) with absence or reduction of dorsiflexion as the essential indicator of disability. Bonney & Macnab (1952) emphasise that restriction of movement may not correlate with disability for this varies with age, sex, footwear, occupation, etc., and on interphalangeal joint mobility. In rheumatoid arthritis, we would add, halluceal function is also related to tarsal and ankle joint disease, for restriction of hindfoot dorsiflexion stresses a damaged great-toe during walking, and such stress increases as metatarso-phalangeal mobility diminishes. Vainio (1956) noted distal phalangeal hyperextension with associated callosities beneath the interphalangeal joint in rheumatoid patients when dorsiflexion of the proximal phalanx was 20° or less. Our experience demonstrates this to be far from universal and shows callosities present in many feet for other reasons; we do, however, accept Vainio's definition of hallux rigidus as 20° or less of passive dorsiflexion of the proximal phalanx on the first metatarsal. Vainio makes no comment on the plantar-flexion range and in noting general lack of attention to this Kessel & Bonney (1958), when dis-

cussing adolescent hallux rigidus, state that a good range of plantar-flexion was preserved in all their cases with an average of 50° ; the average dorsiflexion being only 5° . In our series, where dorsiflexion was 20° or less, a range of plantar-flexion was obtained in all but two cases: such patients are considered to have hallux rigidus (mobile) in contradistinction to a smaller group of patients with truly rigid or fused joints termed hallux rigidus (immobile). This terminology may appear tendentious but as demonstrated below the two groups differ in several respects.

Hallux rigidus (mobile). Forty-three feet of 30 patients came into this category; 26 feet displayed an accompanying hallux valgus, 28 feet showed radiological evidence of tarsal and/or ankle changes and 23 feet (53 per cent) developed hyperextension of the distal phalanx. Some cases of hallux rigidus displayed minimal or no radiological evidence of erosions in the metatarso-phalangeal joint and some possibly developed restricted movement before the onset of rheumatoid arthritis. Furthermore, some patients stated that their toes were stiff prior to and independent of the arthritis. However, in long-standing severe rheumatoid arthritis there is little doubt that the disease itself precipitates the ultimate complication of spontaneous joint fusion.

Hallux rigidus (immobile). The 12 feet in this group illustrate this latter statement for the mean duration of rheumatoid disease was 25.2 years against 12.4 years in the hallux rigidus (mobile) group. In addition, every foot demonstrated not only tarsal but ankle changes including several spontaneous fusions of these joints. These findings suggest that severe and prolonged disease were necessary preludes to metatarso-phalangeal joint fusion. A position of hallux valgus was present in 7 of the 12 feet, a similar proportion to the mobile group. Co-existent distal hyperextension was present in five feet, again much as in the mobile

group and thus one concludes that rheumatoid hallux rigidus is compensated by distal phalangeal hyperextension in approximately half the cases, less than might be anticipated. In the non-rheumatoid foot Fitzgerald (1969) has shown that after metatarso-phalangeal arthrodesis compensatory interphalangeal dorsiflexion does not occur and indeed mobility decreases as a sequel to the altered loading on the distal joint and intra-articular degenerative changes were accelerated. Six feet showed evidence of erosions at the first metatarsal-medial cuneiform joint.

Hallux flexus

Vainio (1956) considers this to be an extreme form of hallux rigidus where dorsiflexion is totally absent and the proximal phalanx is held plantar-flexed. Weight is not taken by the metatarsal head and instead is transferred to the distal phalanx resulting in callosities on its plantar surface. In conventional foot-

wear, however, the major symptom of pain follows friction between the shoe 'upper' and the dorsum of the metatarsal head exposed by the flexed phalangeal attitude.

In this series no toes were classified as hallux flexus, perhaps an indicator of its infrequency, although elsewhere we have observed this deformity in rheumatoid feet (Figure 6).

Chisel toe

Interphalangeal hyperextension alone or in association with hallux rigidus can be itself a source of symptoms particularly when dorsal subluxation of the distal on the proximal phalanx ensues. The "chisel toe" syndrome (Dixon 1971) is characterised by callosity formation on the plantar aspect (Figure 7a) and a skin furrow on the dorsal aspect of the interphalangeal joint associated with changes at the free nail margin resulting from collision between it and the overlying shoe (Figure 7b). Increasing hyperexten-

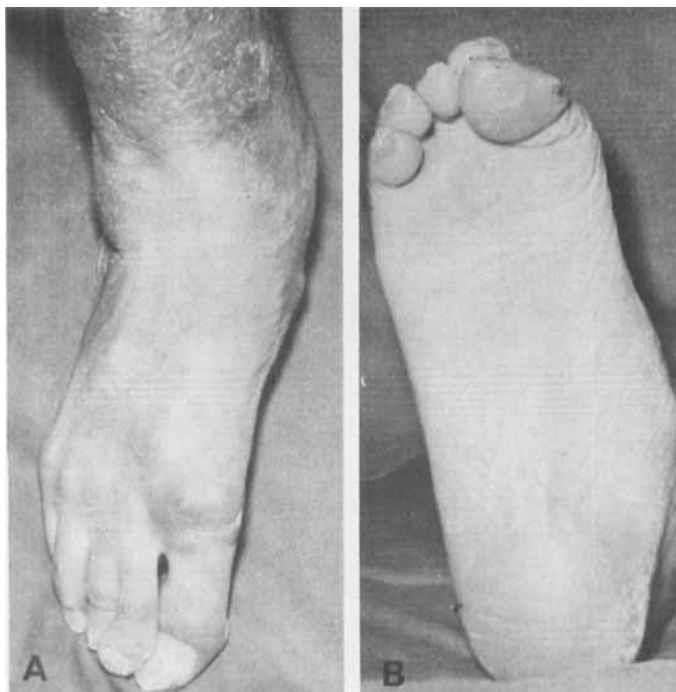


Figure 6. Hallux flexus.

A. Dorsal view showing callosity over the metatarso-phalangeal joint.

B. Plantar view showing callosity under the pulp of the great toe.

sion augments the probability of the nail cutting or chiselling through the shoe, hence the name: in other cases the thickened nail may damage the pulp leading to infection (Figure 7c).

Excess joint hyperextension is defined as dorsiflexion of 20° or more of the distal phalanx (Figure 1c), which in this series was noted in 83 feet, of which 43, involving 31 patients, were considered to be "chisel toes".

As few as 20 out of 43 "chisel toes" were found to have radiographic changes in the interphalangeal joint, namely erosions and juxta-articular cyst formation (Table 2): thus some 53 per cent of "chisel toes" have dorsal subluxation of the distal phalanx without significant joint damage (Figure 7d). Likewise, 32

out of 40 toes with simple hyperextension deformity lacked associated bone changes, indicating that subluxation is frequently related to factors other than interphalangeal joint destruction.

As has been suggested, hyperextension of the distal joint may compensate for hallux rigidus and indeed 14 "chisel toes" were so associated; however, this is only 25 per cent of the rigid halluces. Surprisingly, we found an association with hallux elevatus, there being five "chisel toes" among 20 feet with elevatus. Eight unilateral "chisel toes" displayed no demonstrable hyper-extension in the opposite toe whilst 20 were combined with hallux valgus (25° to 55°), somewhat fewer than expected and proportionately less than those associated with rigidus.

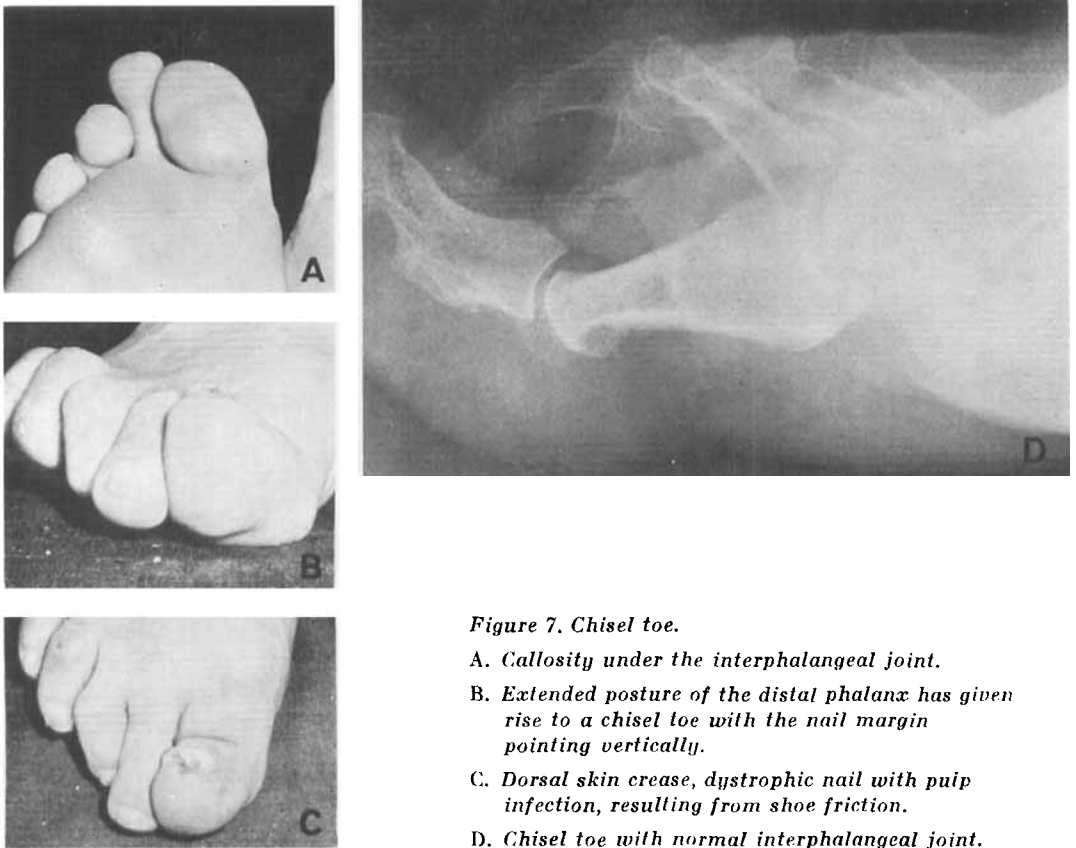


Figure 7. Chisel toe.

- A. Callosity under the interphalangeal joint.*
- B. Extended posture of the distal phalanx has given rise to a chisel toe with the nail margin pointing vertically.*
- C. Dorsal skin crease, dystrophic nail with pulp infection, resulting from shoe friction.*
- D. Chisel toe with normal interphalangeal joint.*

Figure 8. *Hallux elevatus and valgus.*

- A. Anterior view showing marked elevatus with packing of the lesser toes.
 B. Dorsal view showing severe valgus.
 C. Plantar view showing complete absence of the hallux from the plantar profile.

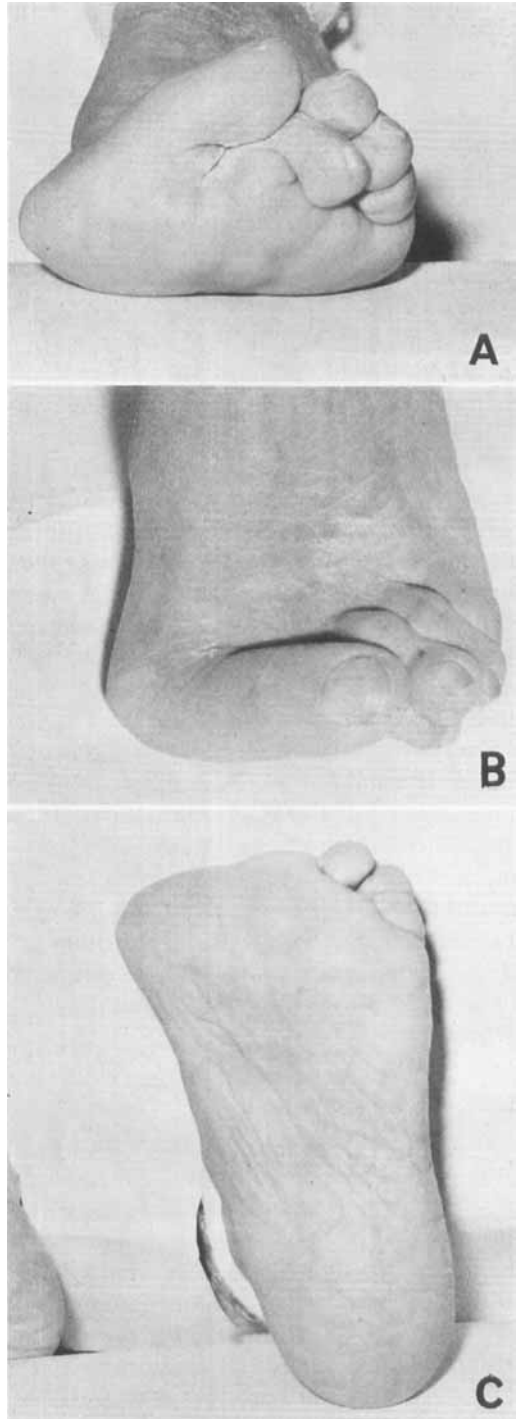
OTHER DEFORMITIES

Hallux elevatus

Elevatus is defined as inability to plantar-flex the proximal phalanx beyond neutral in the presence of dorsiflexion exceeding 20° (Figure 1d). In most instances dorsiflexion was 60° – 90° ; frequently the loss of plantar-flexion was severe with inability to achieve neutral by as much as 40° resulting in striking elevation of the proximal phalanx (Figure 8). As a consequence compensatory plantar-flexion of the distal phalanx might be expected with fixed interphalangeal clawing and dorsal callosity formation over the interphalangeal joint. However, out of 20 feet with hallux elevatus, only two toes were clawed at the distal joint; by contrast 15 interphalangeal joints were hyperextensible beyond 20° . Other co-existent problems included 12 feet with ankle or tarsal joint damage and 11 feet with hallux valgus: both these numbers were in proportion to the overall distribution. By our definition hallux rigidus cannot co-exist with elevatus.

Elevation of the proximal phalanx is said to compensate for depression of the metatarsal head which may be congenital or possibly in rheumatoid arthritis a sequel to bone destruction at the metatarsocuneiform level: the five feet with erosions at the metatarsal base were insufficient to support this possible mechanism. Radiologically rheumatoid damage of the metatarsophalangeal joint was recorded in 18 (90 per cent) of these feet, the interphalangeal joint was similarly affected in only three (15 per cent).

Hallux elevatus rarely caused com-



plaint of itself for associated and more symptomatic deformities were commonly present (Table 3).

Table 3. Deformities associated with hallux elevatus.

Deformity	Feet affected	Feet at risk	Association with hallux elevatus %
Isolated hallux elevatus	6	20	30
Hallux valgus with hallux elevatus	11	114	10
Chisel toe with hallux elevatus	5	43	12
Interphalangeal claw with hallux elevatus	2	13	15
Interphalangeal hyperextension with hallux elevatus	15	83	18

Interphalangeal claw

Inability of the distal phalanx to be dorsiflexed on the proximal with assumption of a flexed attitude between 10° and 30° was defined as clawing and affected 13 toes; six of these developed a symptomatic dorsal callosity over the interphalangeal joint. No less than 12 cases were combined with hallux valgus; however, the thirteenth was accompanied by 20° of medial tortus, a metatarsal head "bunion" and 12° of hallux valgus. Thus a strong association with hallux valgus and tortus is established. In addition, interphalangeal joint erosion and destruction was absent in 12 of the 13 cases, suggesting that rheumatoid disease at this level is an unimportant factor in the aetiology of this deformity. No attrition ruptures of extensor hallucis longus were seen and no significant neurological deficit demonstrated.

Interphalangeal valgus

Valgus deviation of the distal on proximal phalanx of more than 5° , measured by standing radiographs (Figure 1a), was observed in 13 feet achieving a maximum of 30° in two feet. Callosities of the "bunion" type were present on the medial aspect of this joint in three cases causing minor discomfort, and in five other cases concurrent "chisel toe" was a complicating factor. Curiously, accompanying hallux valgus was significant in one foot only. Erosive and destructive changes seen in the interphalangeal joint of eight

halluces indicate the importance of articular damage in establishing joint instability and hence deformity.

Interphalangeal fusion

Four toes fused spontaneously at the distal joint in the presence of disease of long duration and extensive radiological damage in the metatarso-phalangeal, tarsal and ankle joints of all cases. Hallux rigidus, including two metatarso-phalangeal joint fusions, was observed in all four and severe concurrent hallux valgus in three cases. One joint fused in 25° of dorsiflexion and the remainder in the neutral position. One first ray fused at the distal, proximal and basal metatarsal joints in addition to which the tarsus and ankle had fused creating a bony continuity from the distal phalanx to the proximal tibia thus eliminating functional mobility in the leg below the knee joint.

Dislocated first metatarso-phalangeal joint

Complete joint dislocation is rare in contrast to subluxation, whether valgus, tortus or elevatus. Three dislocated great toes were seen, all of which were displaced laterally between the first and second metatarsal heads, the proximal phalanx taking the sesamoids with it (Figure 9) and all ankylosed or fused in the dislocated position despite co-existing valgus and tortus deviation. No dorsal displacement was observed in contrast to

the common dislocation of the lesser toes onto the dorsum of metatarsal heads or necks.

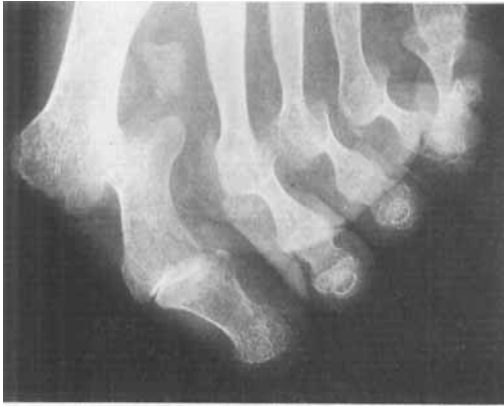

Figure 9. Metatarso-phalangeal dislocation. The sesamoid bones have maintained a normal anatomical relationship to the proximal phalanx.

Hallux varus

Deviation of the proximal phalanx medially from the metatarsal mid-line axis is relatively rare and even small degrees of varus are worthy of note. Of the two cases with this deformity, one deviated 20° and the other, a sequel to a Kellers arthroplasty, some 25° . As observed under hallux tortus, both were associated with lateral rotational changes of the order of 15° and 10° , respectively. In the toe not subjected to surgery, cystic change

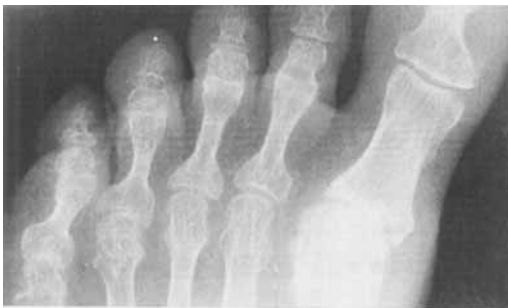

Figure 10. Hallux varus showing a cyst or geode near the medial edge of the metatarso-phalangeal joint.

was well marked in the base of the proximal phalanx at its medial corner suggesting that the varus position was a protective response to relieve pressure opposite the cyst (Figure 10). Lateral phalangeal rotation with hallux varus is the reverse of medial rotation commonly accompanying hallux valgus.

COMBINED DEFORMITIES

Of 194 feet at risk, 31 displayed no significant halluical deformity whilst the remaining 163 feet yielded a total of 266 deformities exclusive of metatarsus primus varus, hallux tortus, and interphalangeal hyperextension. Thus many feet manifested two deformities and indeed three were demonstrated in 15 feet, the ubiquitous hallux valgus being present in all of this latter group (Table 4).

Hallux valgus was observed in 60 per cent of the total feet, being noted in a similar percentage of feet with rigidus and elevatus. However, hallux valgus was seen in combination with only 47 per cent of "chisel toes" and most strikingly only 8 per cent of interphalangeal valgus. By contrast hallux valgus complicated 92 per cent of interphalangeal claw toes (Table 5).

Hallux rigidus involved 28 per cent of the total feet and affected a similar percentage of valgus and "chisel toes". Only one case of rigidus was combined with interphalangeal clawing and none were

Table 4. Triple deformities of the hallux.

Associated deformities	Number of feet involved
Valgus + rigidus + chisel toe	6
Valgus + rigidus + interphal. valgus	3
Valgus + elevatus + chisel toe	2
Valgus + elevatus + interphal. claw	2
Valgus + rigidus + interphal. claw	1
Valgus + chisel toe + interphal. fusion	1

Table 5. Deformities associated with hallux valgus.

Deformity	Feet affected	Feet at risk	Association with hallux valgus %
Isolated valgus	47	114	41
Rigidus with valgus	33	55	60
Chisel toe with valgus	20	43	47
Elevatus with valgus	11	20	55
Interphalangeal claw with valgus	12	13	92
Interphalangeal valgus with hallux valgus	1	13	8

Table 6. Deformities associated with hallux rigidus. The mobile and immobile types are combined.

Deformity	Feet affected	Feet at risk	Association with rigidus %
Isolated hallux rigidus	14	55	25
Hallux valgus with hallux rigidus	33	114	29
Chisel toe with hallux rigidus	14	43	33
Interphalangeal claw with hallux rigidus	1	13	8
Interphalangeal valgus with hallux rigidus	0	13	0

Table 7. Deformities associated with chisel toe.

Deformity	Feet affected	Feet at risk	Association with chisel toe %
Isolated chisel toe	8	43	19
Hallux valgus with chisel toe	20	114	18
Hallux rigidus with chisel toe	14	55	25
Hallux elevatus with chisel toe	5	20	25
Interphalangeal valgus with chisel toe	5	13	38

seen with interphalangeal valgus (Table 6).

"Chisel toes" were observed in 22 per cent of the feet at risk and complicated a similar percentage of valgus, rigidus and elevatus groups; its association with interphalangeal valgus was 38 per cent (Table 7).

DISCUSSION

To some observers the foregoing analysis may complicate what appear mundane problems of hallux valgus, hallus rigidus or bunions, often diminished by more important co-existent disabilities. This is

not our objective for we believe detailed consideration assists clarification and interpretation of the patient's symptoms promoting a rational approach to management, particularly operative treatment. Despite the protean nature of rheumatoid arthritis, undoubted patterns of incapacity and deformity are found suggesting causal factors which are helpful in prognostication.

Clearly these deformities are not specific to rheumatoid arthritis for similar if less disabling changes result from congenital, developmental, traumatic, metabolic and degenerative causes; moreover, one cannot assume absence of deformity prior to the onset of rheumatoid arthritis.

However, in this disease deformities are often multiple and complex, extremely painful and crippling, and commonly influenced by joint changes elsewhere in the foot and more proximally. When present pre-existing problems are aggravated by the disease and as a corollary these problems may determine the ultimate direction and type of rheumatoid deformity, e.g., the mobile flat foot becomes a stiff extremely valgus foot, or the hallux rigidus becomes more rigid and precipitates a "chisel toe".

Terminology

In the English literature, this subject is muddled in several ways particularly by confusion between anatomical terms and clinical descriptions, the former utilising the median limb axis and the latter

the median body axis as reference lines (Figure 11). Thus one arrives at the ambiguous proposition that relative overaction of the adductor hallucis muscle is a factor causing or aggravating hallux valgus; whereas adduction indicates medial and valgus indicates lateral deviation. Whilst the application of the median limb axis with pre- and post-axial margins to compare the human foot with other species is of considerable phylogenetic interest, it is irrelevant to patients who are not quadrupeds. Furthermore, one foot cannot function normally without its complementary fellow and therefore the mid-line between weight-bearing feet, that is the median body axis, is a logical reference line. Acceptance of this axis would necessitate revision of adductor hallucis as abductor hallucis and vice versa.

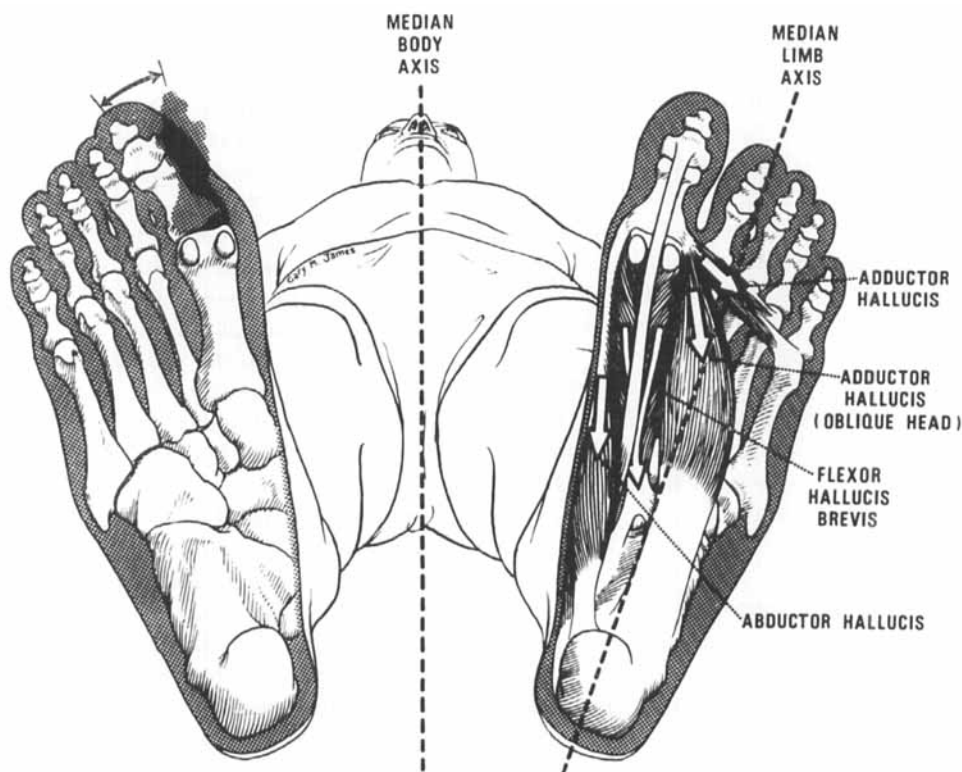


Figure 11. Diagram to show the inappropriate nomenclature of the so-called adductors and abductors of the hallux with reference to the median body axis and the median limb axis.

Clinical terminology itself is not without inexactitude: as mentioned earlier, hallux rigidus is commonly correlated with limited mobility rather than its literal meaning of complete rigidity, and hallux valgus denotes deviation in one plane despite displacement in the first ray being three dimensional. Moreover, these descriptions indicate one component only of the disordered anatomy and do not explain the actual aetiology, e.g. rheumatoid disease, or even suggest the joint pathology, e.g. arthritis or subluxation. One cannot easily discard the time-honoured phrase 'hallux valgus' despite its limitations and as a consequence there is a need for the terms 'elevatus' and 'flexus' to describe deformities which are often co-existent with hallux valgus or varus and yet in a plane at 90° from them. If one accepts the precision of these terms, it is reasonable to denote any accompanying rotational deformity. It is appropriate to use Latin terminology and we have suggested 'tortus' as the equivalent of 'twisted' without, however, indicating the direction of twist. In a particular case a full description might be 'hallux valgus, elevatus et tortus'. This precise if somewhat pedantic formula also hints at particular instability of the first metatarso-phalangeal joint suggesting to us the less precise yet accurate and possibly more acceptable 'hallux subluxans'. Alternatively in rheumatoid arthritis it is appropriate to say 'rheumatoid hallux' as indicative of a disease understood to cause complex deformity of all the joints of the first ray.

Functional consideration

Whilst the great toe is not so versatile as the thumb, its contribution to foot function is as vital as the thumb is to the hand. Analogies of structure between the two digits are obvious and it has been and remains tempting to emphasise similarity of function based on structural resem-

blance. As Wood Jones (1944) maintains, the foot is a specialised organ permitting man's erect posture and is in no way an imperfect hand.

Fundamentally, the great toe functions on terra firma, firstly to support body weight and assist balance; secondly to initiate propulsion by virtue of the powerful muscles attached to it. During walking the traction exerted by the forefoot requires friction between plantar surface and the sole of the shoe, and between shoe and the unyielding ground. In a temperate climate the shoe protects and necessarily encloses the foot submitting the hallux to additional medial and dorsal friction dependent on the rigidity and tightness of the shoe and the spread of the loaded foot. These two sources of friction, one inevitable and consequent on the erect posture under the influence of gravity and the other avoidable and dependent on footwear selection, must be clearly distinguished.

The dynamic gait of normal walking requires movement of all foot joints including those of the hallux which concurrently must take weight. The actual range of movement will depend on stride length and gait speed. In contrast, the disabled rheumatoid patient tends to use a 'static' gait because pain and joint disorganisation diminish and prevent movement accentuating the passive supportive role of the foot. In this situation the hallux is a forward extension of the foot platform, in which it may be isolated for the lesser toes are frequently subluxated or dislocated and thus not in contact with the ground. The actual degree of contact varies with heel height. Thus if the ankle is sufficiently plantar-flexed by raising the heel, the subluxated toes become weight-bearing with the penalty of increased thrust on the forefoot and painful shoe containment, in addition to sustaining the upward pressure from the ground. In practice the patient discovers a low heel is more comfortable though it

curtails markedly any remaining propulsive capacity in the hallux.

If there is a valgus attitude, and a large proportion of rheumatoid feet are so aligned, the weight is concentrated towards the medial foot margin and hence plantar and medial aspects of the hallux. In contrast the varus attitude produces abnormal loading of the lateral foot margin and elevation of the first metatarsal, which may fail to make ground contact causing compensatory plantarflexion of the hallux and occasionally hallux flexus deformity.

Thus the type and degree of great toe deformity can be determined by the attitude of the foot, which is dependent on pathology in the proximal joints of tarsus and ankle and which in turn may reflect changes yet more proximally, as for example, when genu valgum aggravates pes valgus, and external rotational hip contracture alters the attitude of the foot.

In summary, the factors contributing to great toe symptoms and deformity in the walking patient are primarily pre-existing deformity, the activity and extent of rheumatoid changes in the hallucal joints, ground friction and shoe friction. These are modified by body weight, heel height, the foot attitude determined by proximal disease and the lesser toe disposition. More remote factors are the presence of oedema, ischaemia, anaesthesia, poor muscular control, walking incapacity, upper limb inability to control sticks and crutches, the presence of other diseases and probably drug therapy, e.g., steroids and analgesics.

Pathological and clinical considerations

Early disease results in synovial swelling and joint effusions, unassociated with measurable deformity of the hallux as defined above, but nevertheless associated with acute symptoms as unyielding shoes precipitate containment friction and pressure. If synovial infiltration is temporary in nature, minimal or no per-

manent bone or joint changes follow. Persistent swelling, however, produces stretching of ligaments and joint capsules; and more chronic disease may invade cartilage and bone causing structural joint damage with resultant stiffness and deviation. If ligamentous laxity or stretching is the main feature, then deformity may still arise and indeed ultimately be severe due to the influence of weight-bearing and footwear. In many feet articular structural damage and ligamentous laxity coexist.

We postulate articular damage leads to ankylosis and ultimately induces fusion at the metatarsal base, rigidus and fusion at the metatarsal head and occasionally valgus but rarely fusion at the interphalangeal joint. Likewise ligamentous laxity with minimal cartilaginous destruction provokes varus of the metatarsal, valgus of the proximal phalanx and hyperextension of the distal phalanx. Therefore concurrent ankylosis and joint laxity produce combined hallux valgus with hallux rigidus, or hallux rigidus with 'chisel toe', or hallux valgus with hallux rigidus and 'chisel toe'.

It is of interest to compare the behaviour of the first with the lesser metatarso-phalangeal joints: 1) Whilst the lesser toes on occasion sublux laterally and in the case of the little toe medially, the pattern of dorsal subluxation leading to dorsal dislocation is common and usually symmetrical, contrasting with the uncertainty of hallucal behaviour which is often strikingly divergent between right and left great toes. 2) The common dislocation of the lesser toes contrasts with its rarity in the hallux. 3) Whilst fusion of the first metatarso-phalangeal joint is not common it is extremely rare in the lesser metatarso-phalangeal joints. 4) The second to fifth toes commonly develop claw and hammer deformities whilst this is seldom seen in the hallux. 5) Barefoot contact between the lesser toes and the ground is frequently lost

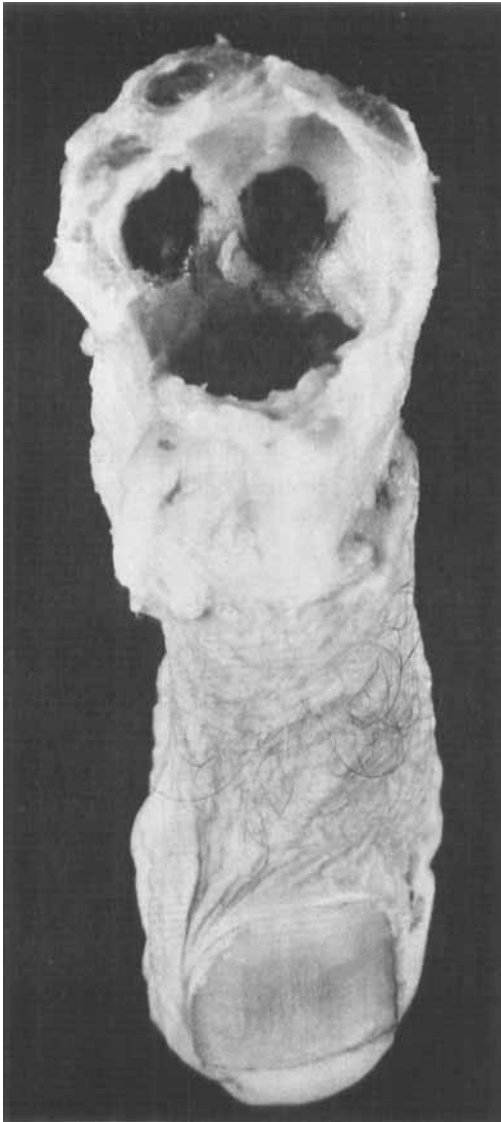


Figure 12. Photograph of a great toe with the soft tissue attachments to the proximal phalanx. The metatarsal head has been removed to show the spherical socket in which it lies, composed of the phalangeal base, sesamoid bones and the surrounding soft tissues. The cartilage surfaces have been coloured in order to highlight them.

due to dislocation but persists beneath the great toe even if grossly deformed, the one exception being hallux elevatus. One cannot escape the conclusion that the first metatarso-phalangeal joint is

not only more important functionally, more diverse pathologically and more disabling clinically, but fundamentally distinctive structurally from the other metatarso-phalangeal joints. We believe one important factor is the presence and contribution of the sesamoids beneath the first metatarsal head and most important is their close and strong musculo-ligamentous connections to the base of the proximal phalanx under most circumstances. Indeed we suggest that the sesamoids functionally extend the phalanx proximally creating a deep 'socket' for the 'ball' of the metatarsal head (Figure 12), which explains why dislocation is rare, for the articulation is virtually a 'captured joint'. Moreover, this capture enables alarming degrees of subluxation to develop and be maintained, e.g. 90° of hallux valgus, and dictates that although the sesamoids themselves may dislocate on the metatarsal head, the proximal phalanx adapts by rotating on its long axis medially with valgus and laterally with varus.

Hallux valgus. The strong tendinous and muscular attachments securing the sesamoids to the phalanx are also components in the muscle imbalance at the metatarso-phalangeal joint after and possibly before subluxation reaches 20°. The lateral half of flexor hallucis brevis and adductor hallucis secure a mechanical advantage which overcomes the medial half of flexor hallucis brevis and the abductor (Figure 11). Progressive hallux valgus may be encouraged by unsuitable footwear and metatarsus primus varus, if not initiated by them; also dislocation and lateral drift of the lesser toes leave space which the hallux can occupy. Metatarsus primus varus may be aggravated by severe valgus when the strong lateral muscles act on the phalanx and sesamoids which may push the metatarsal head medially; in particular, when the lateral sesamoid dislocates between the first and second metatarsal heads (Figure 13).

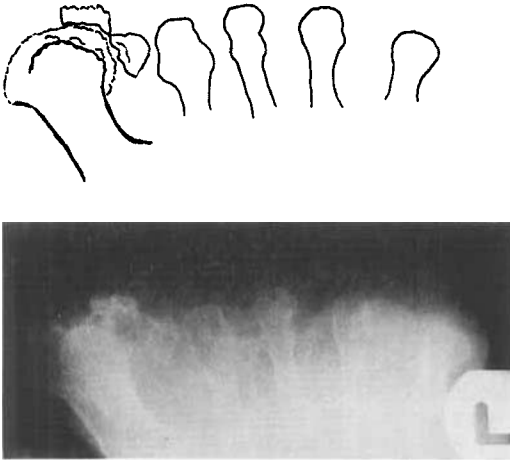


Figure 13. Tangential X-ray of the metatarsal heads in a patient with rheumatoid hallux valgus. The first web space is abnormally wide and the eroded sesamoid bones are dislocated between the first and second metatarsal heads.

Valgus may arrest at any stage, for example when joint destruction introduces concomitant rigidity with ankylosis, or the second and lesser toes are resistant to disease and maintain a lateral buttress. Valgus may diminish after dislocation ensues although the metatarsal head becomes more prominent (Figure 9). We believe that selection of suitable shoes will arrest hallux valgus in some feet.

'Chisel toe'. At surgical exploration we have failed to demonstrate attrition rupture of flexor hallucis longus in this syndrome. Possibly hyperextension of the distal joint is related to congenital ligamentous laxity, which is common enough in the general population, and aggravated by rheumatoid arthritis and by steroid therapy in some cases. Others develop compensatory distal hyperextension in the presence of hallux rigidus.

Hallux elevatus. More puzzling is the association of hyperextension of the proximal and of the distal phalanx in 15 (75 per cent) cases of hallux elevatus. We surmise the primary lesion is due to metatarso-phalangeal damage which ini-

tiates a protective posture in dorsiflexion enabling extensor hallucis longus to secure mechanical advantage, establishing a vicious circle of muscle imbalance on both this and the interphalangeal joint. The latter being generally free of disease readily adopts a hyperextended position and any attempt to flex it inevitably tends to flex the damaged proximal joint, causing pain and protective extensor spasm leading finally to persistent hallux elevatus.

Interphalangeal claw. To account for the mechanism of clawing, explanation of its association with severe hallux valgus and tortus accompanied by any undamaged interphalangeal joint is required. We suggest muscle imbalance at the interphalangeal joint develops in favour of flexor hallucis longus as a sequel to dislocation of the sesamoids and subluxation of the proximal phalanx laterally, compounded by medial rotation of the toe. The rotation hinders effective weight-bearing by the distal phalanx ensuring unhampered action of flexor hallucis longus and consequent clawing in what is virtually a valgus attitude promoted by dislocation of the second toes and no doubt ill-fitting footwear. Clawing is not uncommon in the general population, frequently being accompanied by depression of the metatarsal head and compensatory hyperextension of the proximal phalanx. Such a basis might account for the two feet deformed by elevatus additional to valgus and clawing.

Metatarso-phalangeal dislocation. Outside this series, dislocation of the proximal phalanx dorsally has been observed in two feet; in both cases the sesamoids were observed widely separated from the proximal phalanx accompanied by severe interphalangeal clawing. As far as lateral dislocation is concerned, radiographs of other toes in the series suggest a pre-dislocation position (Figure 14), and lead to the conjecture that erosive collapse of the medial phalangeal base at

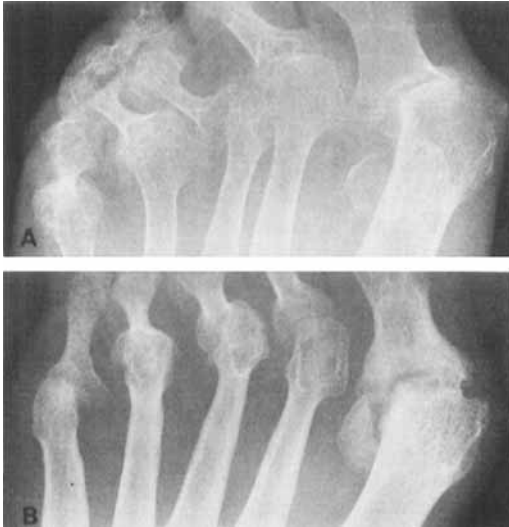

Figure 14. Predislocation.

A. Collapse of the medial corner of the proximal phalanx in progress.

B. Proximal phalangeal erosion with integrity of the medial corner of the phalanx preventing complete dislocation.

the attachment of abductor hallucis is a necessary prelude to dislocation perhaps hastened by previous valgus and tortus deviation. Such collapse is a sequel to severe joint destruction which probably facilitates the tendency to subsequent fusion. To emphasise a point already postulated, the sesamoids remain anatomically tied to, and thus functionally an extension of, the proximal phalanx forming a plantar ledge preventing dorsal dislocation on the metatarsal head but ensuring rotation additional to valgus (Figure 12).

We suggest that weight-bearing prevents plantar dislocation and assume that footwear stops medial dislocation.

REFERENCES

- Bonney, G. & Macnab, I. (1952) Hallux valgus and hallux rigidus. *J. Bone Jt Surg.* **34-B**, 366-385.
- Dixon, A. St. J. & Gheith, S. L. (1973) Tangential X-ray of the forefoot in rheumatoid arthritis. *Ann. rheum. Dis.* **32**, 92-93.
- Dixon, A. St. J. (1971) Personal communication.
- Fitzgerald, J. A. W. (1969) A review of the long-term results of arthrodesis of the first metatarsophalangeal joint. *J. Bone Jt Surg.* **51-B**, 488-493.
- Hardy, R. H. & Clapham, J. C. R. (1951) Observations on hallux valgus. *J. Bone Jt Surg.* **33-B**, 376-391.
- Kessel, L. & Bonney, G. (1958) Hallux rigidus in the adolescent. *J. Bone Jt Surg.* **40-B**, 668-673.
- Mercer, W. & Duthie, R. B. (1964) *Orthopaedic surgery*. Sixth edition, p. 937. Edward Arnold Ltd., London.
- Ropes, M. W., Bennett, G., Cobb, S., Jacox, R. & Jessar, R. A. (1959) Diagnostic criteria for rheumatoid arthritis: 1958 revision. *Ann. rheum. Dis.* **18**, 49-53.
- Steinbrocker, O., Traeger, C. H. & Batterman, R.C. (1949) Therapeutic criteria in rheumatoid arthritis. *J. Amer. med. Ass.* **140**, 659-662.
- Vainio, K. (1956) The rheumatoid foot; a clinical study with pathological and roentgenological comments. *Ann. Chir. Gynaec. Fenn.* Supplement 1.
- Vidigal, E., Jacoby, R. K., Dixon, A. St. J., Ratcliff, A. H. & Kirkup, J. (1975) The foot in chronic rheumatoid arthritis. *Ann. rheum. Dis.* **34**, 292-297.
- Wood Jones, F. (1944) *Structure and function as seen in the foot*. p. 1-2. Baillière, Tindall & Cox, London.

Correspondence to: Richard K. Jacoby, M.D., M.R.C.P., Torbray Hospital, Lawes Bridge, Torquay TQ 2 7AA, England.