

FRACTURE OF THE BODY OF THE TALUS

O. SNEPPEN, S. BACH CHRISTENSEN, O. KROGSØE & J. LORENTZEN

Department of Orthopaedic Surgery U, Rigshospitalet, and The Directorate of Employment Accident Insurance, Copenhagen, Denmark.

Fifty-one patients with fracture of the body of the talus were seen at follow-up examination an average of 23 months after treatment. Osteonecrosis had developed in 8 out of 17 patients with displaced shearing or crush fractures of the trochlea. Malunion as well as subluxation predisposed to osteoarthritis in the subtalar and talocrural joints. Thus, osteoarthritis was present in 9 out of 21 patients without malunion, in 8 out of 16 patients with malunion, and in 11 out of 14 with malunion as well as subluxation. Judging from the nature of the complaints, the difficulties in rehabilitation, and the disability assessment, the prognosis was fairly grave, also after the small, usually non-displaced fractures of the posterior and lateral tubercles. Out of 20 patients with fractures of this type only 6 obtained almost complete relief from their symptoms, only 8 could go back to their previous work on a full-time basis, and 11 were assessed to be 10 per cent or more disabled. Fractures in the posterior and lateral tubercles must therefore be interpreted as links in more extensive injuries involving the subtalar joint and possibly the talocrural joint with associated injuries to articular cartilage, joint capsules, and ligaments.

Key words: talus; fracture; osteoarthritis; osteonecrosis; avascular necrosis

Accepted 9.ii.77

The body of the talus is subjected to tremendous strain during walking and running, in connection with the acceleration and deceleration of the body mass (Weber 1966). Only certain non-physiological forces, e.g., pronounced caudal compression, during pronation and especially supination trauma, will injure the trochlea (Sneppen & Buhl 1974). In addition to its weightbearing function, the body of the talus is also the main component of the most important joints of the foot, the talocrural and the subtalar joints; in this capacity it is of decisive importance in the hinge movements and

rotation of the foot. Owing to its central functions, fractures of the talar body often involve appreciable disability, and this is further accentuated by the special vascularisation conditions which arise in certain regional injuries, involving a marked risk of avascular necrosis of the body (Haliburton et al. 1958, Larsson et al. 1961, Zifko & Wettig 1969, Mulfinger & Trueta 1970, Peterson et al. 1974).

A basic requirement for planning optimal treatment of fractures affecting the body of the talus is of course an adequate knowledge of the prognosis of the various types of fracture, including their relation

Table 1. Previous reports published of fracture of the body of the talus.

	No. of fractures without displacement	No. of fractures with displacement	Total
Schrock et al. (1942)	0	15	15
Kleiger (1948)	7	3	10
Coltart (1952)	15	7	22
Mindell et al. (1963)	3	7	10
Pennal (1963)	3	8	11
Kenwright & Taylor (1970)	4	2	6
Present material (1977)	21	30	51

to the occurrence of osteoarthritis and osteonecrosis. Such a selective prognostic evaluation can be made only on the basis of a large material of fractures after exclusion of cases with serious complicating associated regional injuries. However, fractures of the body of the talus are extremely rare, constituting only about 0.1 per cent of all fractures (Coltart 1952, Baltschew 1975). Consequently, the prognostic problems have so far been elucidated only on the basis of small series (Table 1) which do not fulfil the above-mentioned criteria.

With this background, it would seem of interest to study the prognosis of the various morphological types of fracture occurring in the body of the talus, on the basis of a major material having a sufficiently long follow-up period.

MATERIAL

The material is derived from the Directorate of Employment Accident Insurance, Copenhagen, where 218 cases concerning fractures of the talus were handled during the period 1945-1975. Of these fractures, 62 affected the body of the talus. This does not include cases of minor chip fractures or the osteochondritis-like trochlear injuries or ligamentous avulsion fractures whose prognosis differs essentially from that of other talar fractures.

In 28 cases there were associated injuries involving, in 25 cases, the same ankle and foot, viz. 21 fractures of the ankle, two of the calcaneus, and two of the metatarsal bones. In 11 cases the associated injury was of a serious nature and may have appreciably influenced the

prognosis. As the present study was intended to elucidate the prognosis of talar fracture alone, these 11 cases were excluded. This leaves 51 fractures of the body of the talus without serious associated injuries.

In all 51 cases, an orthopaedic assessment was available, based upon a clinical as well as a radiological examination. The orthopaedic assessments, X-ray films, and case records were reviewed by the authors and form the basis of the present publication.

In age the patients ranged from 17 to 64 years, mean age 36. The follow-up period from the time of the accident until the time of the final specialist examination, ranged from 9 to 76 months, mean 23 months.

In 32 of the 51 cases the fracture was due to falls from a height, while in eight cases there had been direct trauma; in five a distortion injury and in six cases traffic accidents.

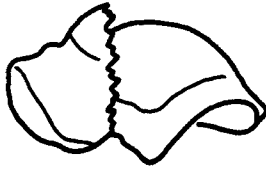
Figure 1 gives the morphology of the various types of fracture. The compression fractures in the trochlea (A) involved only the medial or lateral part of the trochlea and exclusively the talocrural joint. There were two main types of shearing fractures of the trochlea: a coronal (B) and a more or less sagittal (C) one. The coronal type could be mistaken for fracture of the talar neck, but it was situated more posteriorly, involving the trochlea, and therefore could entail incongruence in the talocrural joint, often blocking dorsiflexion of this joint (Figure 2). Both types of shearing fracture involved the talocrural as well as the subtalar joints. The same applied to the minor fractures affecting the posterior (D) or lateral (E) tubercle, marginal fractures not being included in the material, as already mentioned. Comminuted crush fractures (F) entailed fragmentation of the entire trochlea with massive incongruence in the talocrural as well as subtalar joints (Figure 3).

The relation of the fracture types to the occurrence of displacement of the fracture and to the occurrence of subluxation in the adjacent

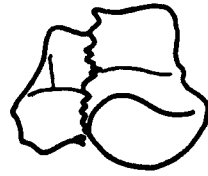
Types of fracture



A. Compression fracture



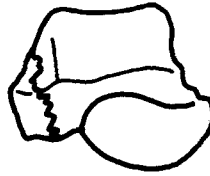B. Coronal shearing fracture



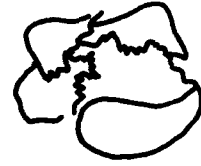C. Sagittal shearing fracture



D. Fracture in the posterior tubercle



E. Fracture in the lateral tubercle



F. Crush fracture

Figure 1.

joints is presented in Table 2. It will be seen that while a large number of the compression, shearing, and crush fractures were displaced and sometimes involved subluxation, the majority of the fractures affecting the posterior and the lateral tubercle were not displaced.

Initial treatment had been, in three cases,

open reduction and fixation, in six cases reduction and a plaster cast, and in the remaining 42 cases only a plaster cast and/or non-weight-bearing.

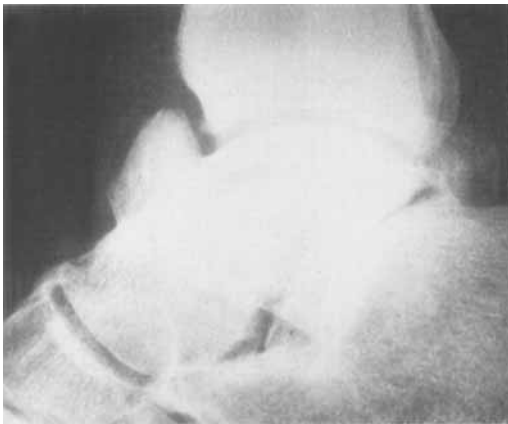

Figure 2. Coronal shearing fracture anteriorly in the trochlea showing severe malunion. Subtalar as well as talocrural osteoarthritis. Follow-up period 20 months.

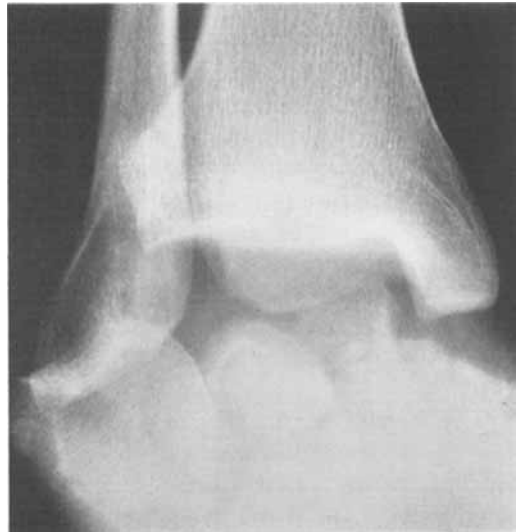

Figure 3. Crush fracture with severe fragmentation of the body.

Table 2. Type of fracture in relation to displacement and to subluxation in the subtalar and/or talocrural joints.

Type of fracture	Fracture without displacement	Fracture with displacement	Fracture with displacement and subluxation	Total
Compression	0	10	0	10
Shearing	4	3	10	17
Posterior tubercle	10	1	0	11
Lateral tubercle	7	1	1	9
Crush	0	1	3	4
Total	21	16	14	51

RESULTS

The most important complications, from the prognostic point of view, were avascular necrosis, malunion, and osteoarthritis in the talocrural and/or subtalar joint.

Avascular necrosis. In eight cases there was marked condensation of the trochlea. In seven of them, moreover, the trochlea was deformed by collapse; in two of the cases this deformity was very pronounced (Figure 4). Out of the eight cases of avascular necrosis, five occurred among the 13 displaced shearing fractures and three among the four crush fractures.

Malunion. Thirty fractures of the talar body were primarily displaced—16 slightly, while 14 showed marked malalignment with a break of 3 mm or more in the joint surface or with crushing and deformity of major parts of the body. In 9 of these 14 cases, an attempt at reduction had been made initially, but the displacement could be reduced to mild in only four of the cases. This left 10 cases with severe (Figure 2) and 20 with slight malunion.

Osteoarthritis. Twenty-eight patients developed osteoarthritis (Tables 3 and 4). This complication occurred with approximately the same frequency in all types of fracture except for those of the lateral tubercle which were followed by

osteoarthritis in only one case out of nine. It is worthy of particular note that among the 11 cases having fracture of the posterior tubercle eight were complicated by osteoarthritis. Relating the occurrence of osteoarthritis to malunion and to subluxation shows, as might be expected, that both predispose to osteoarthritis (Table 4).

Other complications. Bony ankylosis in the subtalar joint occurred during the healing of one crush fracture complicated by osteonecrosis. There were two cases of skin necrosis and infection, one involving osteitis and long-lasting fistula-

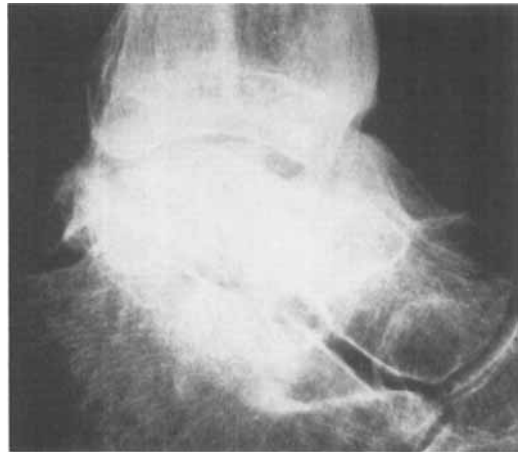


Figure 4. Coronal shearing fracture anteriorly in the body, complicated by osteonecrosis and severe deformity of the trochlea. Follow-up period 14 months.

Table 3. Occurrence of talocrural and subtalar osteoarthritis in relation to type of fracture.

Type of fracture	Talocrural osteoarthritis	Subtalar osteoarthritis	Talocrural and subtalar osteoarthritis	No osteoarthritis	Total
Compression	5	0	0	5	10
Shearing	3	1	7	6	17
Posterior tubercle	2	5	1	3	11
Lateral tubercle	0	1	0	8	9
Crush	1	0	2	1	4
Total	11	7	10	23	51

Table 4. Occurrence of osteoarthritis in relation to malunion or union in subluxation in the talocrural and/or subtalar joint.

	Osteoarthritis	No osteoarthritis	Total
Fracture united without displacement	9	12	21
Fracture united with displacement	8	8	16
Fracture united with displacement and subluxation	11	3	14
Total	28	23	51

Table 5. Subjective results.

Type of fracture	Complaints			Total
	Minor or none at all	Moderate	Severe	
Compression	5	1	4	10
Shearing	1	6	10	17
Posterior tubercle	3	5	3	11
Lateral tubercle	3	3	3	9
Crush	0	0	4	4
Total	12	15	24	51

tion. In three, non-union resulted from minor, mainly intra-articular bone fragments.

Secondary treatment

Because of secondary osteoarthritis and pain on weightbearing, fusion was performed in four cases, subtalar in three and talocrural in one. In three cases a non-united, partially free bone fragment was removed from the talocrural

joint. Nine patients were later fitted with orthopaedic footwear.

Subjective result

At the final follow-up examination 39 patients still had complaints, mostly in the form of pain in the ankle region and hindfoot on weightbearing. From Table 5 it is apparent that these complaints manifested themselves not only after major fractures, but to a large extent

Table 6. Influence of talar injury on occupational capacity.

Type of fracture	Back to previous work	Obtained lighter work	Not working	Total
Compression	5	2	3	10
Shearing	6	6	5	17
Posterior tubercle	4	5	2	11
Lateral tubercle	4	3	2	9
Crush	0	4	0	4
Total	19	20	12	51

Table 7. Disablement assessment.

Type of fracture	Disablement percentage				Total
	0	5-8	10-12	> 12	
Compression	2	5	1	2	10
Shearing	0	4	2	11	17
Posterior tubercle	0	5	6	0	11
Lateral tubercle	1	3	5	0	9
Crush	0	0	0	4	4
Total	3	17	14	17	51

also after the minor, mainly non-displaced fractures of the posterior and lateral tubercles.

Rehabilitation

The occupational situation of 39 patients was permanently altered by the talar injury, and as is shown in Table 6 there were considerable rehabilitation problems after fractures of the posterior and the lateral tubercles. Thus, out of 20 patients with injuries of this type, only eight were able to resume full employment in their previous occupation.

Disability assessment

One expression of the prognosis is the disablement percentage which is fixed in each case by the Directorate of Employment Accident Insurance and which forms the basis of the compensation. From Table 7, it can be seen that in the

various types of fracture the disablement percentage agreed with the subjective result and with the rehabilitation difficulties, as shown in Tables 5 and 6, respectively.

DISCUSSION

It is generally known that severe fractures of the body of the talus, including displaced shearing fractures and crush fractures, have a serious prognosis. Mindell et al. (1963) reported good results in only two out of seven displaced fractures of the talar body, three of which developed osteonecrosis. Coltart (1952) found osteonecrosis in five out of six displaced fractures of the body and reported a high incidence of post-traumatic osteoarthritis, especially in the subtalar joint. However, the results of the displaced intra-articular fractures appear to depend to some extent upon what degree of reduc-

tion is obtained (Coltart 1952, McKeever 1963, Kenwright & Taylor 1970).

As regards these severe fractures, the present study confirmed the previous results. We also found a high frequency of osteonecrosis, a high incidence of osteoarthrosis which definitely seems to depend upon malunion and subluxation (Tables 3 and 4), and a late result characterised by appreciable subjective complaints (Table 5) and rehabilitation difficulties (Tables 6 and 7). The treatment of these fractures should be according to the current lines (Watson-Jones 1962), but with great emphasis on an exact reduction and a stable fixation whenever possible, a procedure which often necessitates operation. Most authors have indicated a good prognosis in minor, mainly non-displaced fractures (Kleiger 1948, Mindell et al. 1963, Kenwright & Taylor 1970). Only Coltart (1952) mentioned an appreciable frequency of late subtalar osteoarthrosis following non-displaced fractures of the talus. The present study revealed a far more serious prognosis for the small, mainly non-displaced fractures of the posterior and lateral tubercles than has previously been assumed. This more serious prognosis was manifest, as regards fractures of the posterior tubercle, in a very high incidence of osteoarthrosis (Table 3), and in the case of both types of fracture, in severe complaints (Table 5), rehabilitation problems (Table 6), and a fairly high disability assessment percentage (Table 7).

In our opinion the majority of these fractures, fairly negligible *per se*, form a link in more extensive regional injuries involving the talocrural and especially the subtalar joint. Thus, at the time of the accident there has been subluxation, and the consequent articular injury bears the main responsibility for the grave long-term prognosis. We feel, therefore, that in treating fractures of the posterior and lateral tubercles it is important to aim at rapid normalisation of the func-

tion in the talocrural and subtalar joints. This is best obtained by fairly brief immobilisation which affords a possibility for the healing of the joint capsule and ligamentous structures. Thereafter, energetic active training of foot movement should be instituted. As these fractures invariably involve a weightbearing joint surface, the patients should not be allowed to bear weight on the foot until solid union of the fractures has been obtained.

REFERENCES

- Baltschew, G. (1975) Für und gegen Talektomie oder Arthrodesen bei schweren Talusfrakturen. *Beitr. Orthop.* **22**, 94-96.
- Coltart, W. D. (1952) Aviators astragalus. *J. Bone Jt Surg.* **34-B**, 545-566.
- Haliburton, R. A., Sullivan, C. R., Kelly, P. J. & Peterson, L. F. A. (1958) The extraosseous and intraosseous blood supply of the talus. *J. Bone Jt Surg.* **40-A**, 1115-1120.
- Kenwright, J. & Taylor, R. G. (1970) Major injuries of the talus. *J. Bone Jt Surg.* **52-B**, 36-48.
- Kleiger, B. (1948) Fractures of the talus. *J. Bone Jt Surg.* **30-A**, 735-744.
- Larsson, R. L., Sullivan, C. R. & Janes, I. (1961) Trauma, surgery and circulation of the talus—What are the risks of avascular necrosis? *J. Trauma* **1**, 13-21.
- McKeever, F. M. (1963) Treatment of complications of fractures and dislocations of the talus. *Clin. Orthop.* **30**, 45-52.
- Mindell, E. R., Cisek, E. E., Kartalian, G. & Dziob, J. M. (1963) Late results of injuries to the talus. *J. Bone Jt Surg.* **45-A**, 221-245.
- Mulfinger, G. L. & Trueta, J. (1970) The blood supply of the talus. *J. Bone Jt Surg.* **52-B**, 160-167.
- Pennal, G. F. (1963) Fractures of the talus. *Clin. Orthop.* **30**, 53-63.
- Peterson, L., Goldie, I. & Lindell, D. (1974) The arterial supply of the talus. *Acta orthop. scand.* **45**, 260-270.
- Schrock, R. D., Johnson, H. F. & Walters, C. H. (1942) Fractures and fracture-dislocations of the astragalus. *J. Bone Jt Surg.* **24**, 560-573.
- Sneppen, O. & Buhl, O. (1974) Fracture of the talus. *Acta orthop. scand.* **45**, 307-320.
- Weber, B. G. (1966) *Die Verletzungen des oberen Sprunggelenkes*. Hans Huber, Stuttgart.

Watson-Jones, R. (1962) *Fractures and joint injuries*. Livingstone, London.
Zifko, B. & Wettig, H. (1969) Behandlung und

Ergebnisse von Talusbrüchen und Talusverrenkungsbrüchen. *Arch. orthop. Unfall-Chir.* **65**, 65.

Correspondence to: Dr. O. Sneppen, Department of Orthopaedic Surgery U, Rigshospitalet, DK-2100 Copenhagen Ø, Denmark.