

PAPAIN-INDUCED CHANGES IN THE KNEE JOINTS OF ADULT RABBITS

T. HAVDRUP & H. TELHAG

Department of Orthopaedic Surgery, Malmö General Hospital (University of Lund),
Malmö, Sweden.

Rapidly progressing joint disease can be produced in the rabbit by intra-articular injection of concentrated papain. With the use of radioactive thymidine it is possible to demonstrate that the cartilage cells recover their ability to divide by mitosis at the same time as degenerative changes appear in the cartilage. Clusters of chondrocytes arise by mitosis of chondrocytes and not by a floating together of cartilage cells.

Key words: papain; cartilage; experimental osteoarthritis; mitoses; autoradiography

Accepted 22.xii.76

Experimental osteoarthritis can be induced in various ways. In recent years degenerative joint changes have been produced by excision of part of the joints (Hall 1969, Thompson & Bassett 1970), local traumatization of the joint cartilage (Bennet et al. 1932, Carlson 1957, Meachim 1963, Campbell 1969 and Lemperg et al. 1971), compression (Crelin & Southwick 1960, 1964, Ginsberg et al. 1969, Thompson & Bassett 1970) or immobilization of the joints (Evans et al. 1960, Hall 1963, 1964) or by dislocation of the patella (Bennet & Bauer 1937). By rendering a joint unstable (Marshall & Olsson 1971, Telhag & Lindberg 1972), it is possible to produce joint changes resembling those seen in human osteoarthritis (according to Collins 1949) with flaking, fibrillation and erosion of the articular cartilage.

Proteolytic enzymes release chondroitin sulphate from the protein-polysaccharide complex in the matrix. Papain is a proteolytic enzyme, and when given intravenously or intra-articularly in rabbits, it causes joint changes similar to those seen in human osteoarthritis (Murray 1964, Bentley 1971, Farkas et al. 1974).

It has been shown that when degenerative changes develop in the joint cartilage in man and in the rabbit, the chondrocytes recover their ability to synthesize DNA, i.e., to divide (Hulth et al. 1972, Telhag 1972). It has hitherto not been possible to demonstrate with certainty the presence of mitotic figures in normal joint cartilage in adult human beings or animals (Mankin 1963, 1964, 1968, Hulth et al. 1972, Telhag 1972, 1973).

The purpose of this investigation was to find out whether chondrocytes recover their ability to divide after intra-articular injection of papain, and to elucidate

Financial support was obtained from Herman Järnhardts Stiftelse, Alfred Österlunds Stiftelse and Ulla och Gustaf af Ugglas fond.

the histological development of papain-induced joint changes.

MATERIAL AND METHODS

The material consisted of 16 full-grown (grey Silver) rabbits with roentgenographically closed epiphyseal lines. They were caged under normal conditions and fed on normal diet. The animals weighed 2.010–2.960 g (mean 2.468). They were divided into two groups. The first group (12 animals) received 0.2 ml concentrated, sterile papain in the right knee joint, and the left served as a control. They were killed two at a time, 2, 3, 5 days and 1, 2 and 4 weeks after the injection of papain. The second group (4 animals) received 0.2 ml of a 20 per cent solution of concentrated, sterile papain in the right knee joint, and the left served as a control. They were also killed two at a time, 2 and 4 weeks after the injection of papain. Four hours before sacrifice, 40 μ Ci 3 H-thymidine was injected intra-articularly into both knee joints of the animals studied for 1, 2 and 4 weeks. The animals studied for 2, 3 and 5 days received two doses of 3 H-thymidine, each consisting of 40 μ Ci, intra-articularly into both knee joints, 24 and 18 hours, respectively, before sacrifice.

The animals were killed with an overdose of Nembutal i.v. (Abbott). None of the joints showed any signs of infection. Both knee joints were dissected and fixed in 10 per cent formalin solution. The patella, tibia and femur were dissected free and treated separately. The tibia and the femur were divided into two halves in the frontal plane with a circular saw. The pieces were decalcified in 50 per cent formic acid and 20 per cent sodium citrate. They were embedded in paraffin and cut into sections 5–7 μ thick.

The sections were stained with haematoxylin-eosin, safranin-O and according to van Gieson. Autoradiograms of routine histological sections were prepared from both knees according to the dipping method with Ilford K2 liquid emulsion. The autoradiograms were exposed for 3 weeks, after which they were developed in Gevaert X-ray developer G 230 and fixed in Gevaert X-ray fixer G 350. The sections were stained through the emulsion with Mayer's haematoxylin. As a rule, three autoradiograms from the tibia, femur and patella of both knee joints from each animal were examined.

RESULTS

The animals showed no signs of a generalized toxic reaction to the injection of

papain. In fact, the animals did not seem to spare the treated knee, and all of them survived the experimental period.

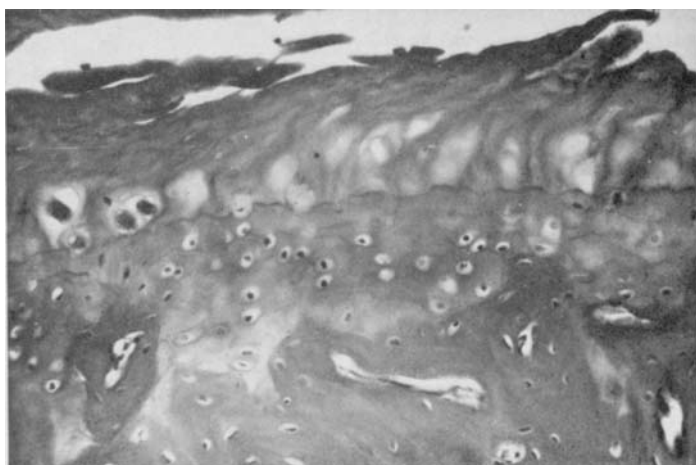
Histological examination

None of the left control knees showed any evidence of degeneration. In one of the animals, receiving concentrated papain, a little osteoblastic activity was seen at the margin. The sections stained with Safranin-O showed normal staining properties of the matrix except for three animals given concentrated papain and killed 2 weeks (1 rabbit) and 4 weeks (2 rabbits) later. In these animals the matrix had lost the staining properties seen in all the other animals.

Findings 2 days after injection of concentrated papain. At the margins there was slight proliferation of cells in and near the perichondrium and periosteum, but there were no signs of osteoblastic activity or new bone formation. The articular cartilage showed signs of degradation in both the animals. In one knee joint almost all the cartilage was necrotic. The degradation was reflected in death of cells, mostly in the columnar and transitional layers, whereas the superficial layer was normal. Thus, the cell nuclei stained weakly or not at all, and it was often difficult to distinguish the cell membrane from the surrounding matrix. No clusters were seen. In one animal there was flaking and fibrillation of the surface.

Findings 3 days after injection of concentrated papain. At the margins and in the tissue adjacent to the cruciate ligaments, there was proliferation of cells and the beginnings of osteoblastic activity in both animals. The degradation of the articular cartilage seemed to be more pronounced than at 2 days after the papain injection, with flaking of the superficial layer and fibrillation. The death of the chondrocytes could be seen down to the tidemark. No clusters were seen.

Figure 1. One week after injection of concentrated papain. The articular cartilage is almost totally necrotic. Single clusters, flaking and fibrillation.
Magnification $\times 7.2$.



Findings 5 days after injection of concentrated papain. The proliferation of cells at the margins and adjacent to the cruciate ligaments, and the osteoblastic activity, were still more pronounced. This was also true of the changes in the cartilage. Flaking of the superficial layer and fibrillation could be seen. Deeper down in the cartilage total necrosis was seen and only a few chondrocytes. Clusters were not seen.

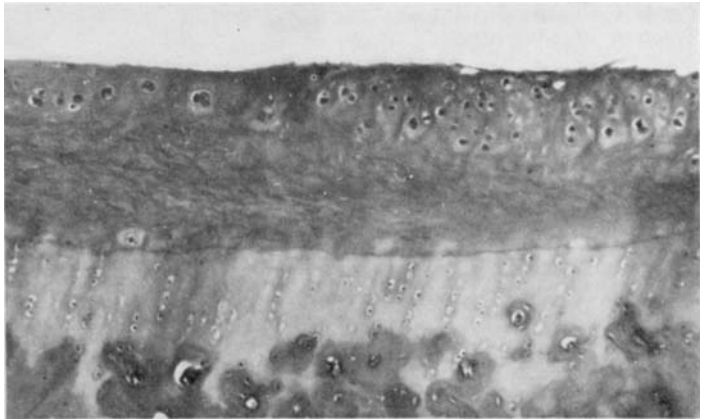
Findings 1 week after injection of concentrated papain. At the margins and to some extent in the tissues adjacent to the attachments of the cruciate ligaments, there was proliferation of cells in and near the perichondrium and periosteum. Furthermore, most of the specimens showed ingrowth of capillaries with osteoblastic activity, sometimes with signs of new bone formation. The articular cartilage almost always exhibited signs of degradation in both knee joints from each animal; in one knee joint almost the entire cartilage was necrotic. Degradation was reflected in the death of cells, mostly in the non-calcified layers of cartilage, and particularly so in the columnar layer. Thus, the cell nuclei stained only weakly or not at all, and it was often difficult to distinguish the cell membrane from the surrounding

matrix. In one of the two knees there were clusters of chondrocytes as well as flaking of the outer layer of the cartilage and fibrillation, sometimes down to the calcification line (Figure 1).

Findings 2 weeks after injection of concentrated papain. At the margins and at the attachments of the cruciate ligaments, granulation tissue had formed with abundant fibrous cells and vessels, and the osteoblastic activity with new bone formation was much more striking than that seen 1 week after the injection. In some of the specimens osteophytes had begun to form at the margins. The degradative changes had continued to progress. The articular cartilage showed severe changes, often with total necrosis of the cartilage and only a few chondrocytes. Clusters were seen only in occasional sections, as were flaking and fibrillation.

Findings 2 weeks after injection of 20 per cent papain. At the margins and at attachments of the cruciate ligaments, granulation tissue had formed and abundant osteoblastic activity was seen with new bone formation, and in some slides osteophytes had begun to form. The degradative changes of the cartilage were not as pronounced as when concentrated papain was injected. The changes were

Figure 2. Two weeks after injection of 20 per cent papain. The articular cartilage of the transitional and columnar layers is almost totally necrotic. Single clusters. Magnification $\times 2.8$.



mostly limited to the transitional and columnar layers (Figure 2), whereas they were not so pronounced in the superficial layer. On the other hand, flaking and fibrillation were seen, as were clusters.

Findings 4 weeks after injection of concentrated papain. Histologically, the formation of osteophytes at the margins as well as the subchondral osteoblastic activity were more prominent. Some specimens also showed new bone formation subchondrally, although no definite evidence of sclerosis was seen. The cartilage was often completely necrotic, far down in the columnar layer, in some areas down to the calcification line, and occasionally the calcified cartilage was changed. Flaking, fibrillation and clusters were rare. Living chondrocytes were sparse.

Findings 4 weeks after injection of 20 per cent papain. The proliferation of cells at the margins and at the attachments of the cruciate ligaments was still more pronounced than 2 weeks after the injection, as was also the osteoblastic activity. Subchondrally, new bone formation was seen, and at the margins formation of osteophytes had begun. The degradative changes of the cartilage were less than after the injection of concentrated papain. The articular cartilage was not totally necrotic but in some

places necrosis of the chondrocytes was seen. Big clusters as well as flaking and fibrillation were observed.

Autoradiographic evaluation

Specimens from 8 of the 16 control knees (left) showed fairly sparse thymidine labelled chondrocytes. All 8 belonging to group 1 (right knee joint injected with concentrated papain). In none of the control knees belonging to group 2 (20 per cent papain injected into the right knee joint) were any thymidine-labelled chondrocytes found.

In group 1 (concentrated papain) sparse labelled chondrocytes were found in the articular cartilage in two knees but there was only inconclusive evidence of this in the other four knees, when the animals were killed 2, 3 and 5 days after the injection. Seven days after the injection, one of the knee joints contained abundant labelled chondrocytes but the other contained fairly sparse labelled cells.

Fourteen days after the injection of concentrated and 20 per cent papain, rather abundant labelled chondrocytes were found, especially in the latter group where the cell necrosis was not so pronounced. In the group injected with concentrated papain and killed 4 weeks later, only sparse labelled chondrocytes were found.

The labelled chondrocytes were usually situated in the superficial and transitional layers but also in the columnar layer. Clusters with labelled chondrocytes were also seen.

DISCUSSION

The availability of an experimental model is valuable in the investigation of the pathophysiology of osteoarthritis and the evaluation of therapeutic methods.

It has been shown (Bentley 1971, Farkas et al. 1974) that degenerative and reparative changes resembling those in human osteoarthritis can be produced by intra-articular injection of papain. In the present investigation, the injection of concentrated papain caused rapidly progressing necrosis of the joint cartilage within 2 days, and after 4 weeks the non-calcified cartilage, and sometimes also the calcified layer, were so severely damaged that only occasional apparently viable chondrocytes were demonstrable. After the injection of 20 per cent papain, the changes in the articular cartilage were not so pronounced as when concentrated papain was injected, the changes being more of a degenerative nature. Like Bentley, we also found that chondrocytes in the deeper columnar layer were more affected than those in the superficial and transitional layers.

One week after the injection, the specimens showed abundant clusters of chondrocytes. With increasing time after the papain injection, the number as well as the clusters of chondrocytes decreased, being less pronounced after injection of 20 per cent papain. Especially at 4 weeks after injection of 20 per cent papain, big clusters were seen. Collins & McElligot (1960) found some evidence of proliferation of chondrocytes and clusters in osteoarthritis. Bentley (1971) described such clusters within 24 hours of an injection of papain into hip joints in the rabbit, but we could not find any clusters

until 1 week after the injection. Bentley assumed that clusters were due to an aggregation of chondrocytes, secondary to loss of matrix. He felt that this could explain the development of clusters in osteoarthritis. Farkas et al. (1974), on the other hand, found chondrocyte clusters with mitotic figures in the haematoxylin-eosin sections.

When degenerative changes of the articular cartilage are produced experimentally (Telhag & Lindberg 1972), mitosis of the chondrocytes is not seen until 5 days after the operation. Therefore, animals killed before 1 week were given 2 injections of tritiated thymidine.

It has been shown that clusters can take up radioactive thymidine in degenerative joint disease both in the rabbit and in man (Hulth et al. 1972, Telhag 1972). This was confirmed in the present investigation, in which it was shown that when degenerative changes of the cartilage occur the chondrocytes recover their ability to divide and, when situated in clusters, possess the ability to take up radioactive thymidine. This suggests that clusters arise from division, and not by "a floating together" of cartilage cells. Thus, any type of damage of the joint cartilage stimulates the S-phase of the mitotic cycle of the chondrocytes.

Mitosis of chondrocytes in the normal adult joint cartilage has hitherto not been demonstrated with certainty in animals or in man (Mankin 1963, 1964, 1968, Hulth et al. 1972, Telhag 1972, 1973). When concentrated papain was given in the right knee, we found some labelled cartilage cells in the control knees, which might possibly have been due to a minute portion of the papain having been transported there. This perhaps also explains the negative safranin-O staining in three of the control knees injected with concentrated papain. A technical fault can, however, not be excluded.

Bentley (1971) demonstrated formation of osteophytes resembling those seen

in human osteoarthritis after injection of papain. Such formation was verified in the present investigation. Four weeks after the injection of papain, the specimens exhibited incipient formation of osteophytes of the same appearance as those seen in human osteoarthritis according to Collins (1949), and in experimental osteoarthritis in the rabbit (Telhag & Lindberg 1972).

Many methods have been used for inducing osteoarthritic lesions in the joints. With papain, it is possible to produce advanced joint changes. In the present investigation, rapidly progressing changes in the articular cartilage were produced by the injection of concentrated papain. The changes produced in the articular cartilage seem to be of necrotic rather than of a degenerative nature. Papain, in lower concentrations, produces lesions more similar to those seen in human osteoarthritis thus also providing a possibility to study the earlier changes of degeneration and repair. Consequently, the method would appear to be useful for studying the metabolism of the joint cartilage in the early stages of joint disease.

REFERENCES

- Bennett, G. A., Bauer, W. & Maddock, S. J. (1932) A study of the repair of normal joints of adult dogs to surgically created defects of articular cartilage, "joint mice" and patellar displacement. *Amer. J. Path.* **8**, 499-523.
- Bennett, G. A. & Bauer, W. (1937) Joint changes resulting from patellar displacement and their relation to degenerative joint disease. *J. Bone Jt Surg.* **19**, 667-682.
- Bentley, G. (1971) Papain-induced degenerative arthritis of the hip in rabbits. *J. Bone Jt Surg.* **53-B**, 324-337.
- Campbell, C. J. (1969) The healing of cartilage defects. *Clin. Orthop.* **64**, 45-63.
- Carlson, H. (1957) Reactions of rabbit patellary cartilage following operative defects. A morphological and autoradiographic study. *Acta orthop. scand.*, Suppl. 28.
- Collins, D. H. (1949) *The pathology of articular and spinal diseases*. Williams and Wilkins Co., Baltimore.
- Collins, D. H. & McElligott, T. F. (1969) Sulphate ($^{35}\text{SO}_4$) uptake by chondrocytes in relation to histological changes in osteoarthritic human articular cartilage. *Ann. rheum. Dis.* **19**, 318-329.
- Crelin, E. S. & Southwick, N. O. (1960) Mitosis of chondrocytes induced in the knee joint articular cartilage of adult rabbits. *Yale J. biol. Med.* **33**, 243-244.
- Crelin, E. S. & Southwick, W. O. (1964) Changes induced by sustained pressure in the knee joint articular cartilage of adult rabbits. *Anat. Rec.* **149**, 113-133.
- Evans, E. B., Eggers, G. W. N., Butler, J. K. & Blumel, J. (1960) Experimental immobilization and remobilization of rat knee joints. *J. Bone Jt Surg.* **42-A**, 737-758.
- Farkas, T., Bihari-Varga, M. & Biró, T. (1974) Thermoanalytical and histological study of intra-articular papain-induced degradation and repair of rabbit cartilage. I. Immature animals. *Ann. rheum. Dis.* **33**, 385-390.
- Ginsberg, J. M., Eyring, E. J. & Curtiss, P. H. J. (1969) Continuous compression of rabbit articular cartilage producing loss of hydroxyproline before loss of hexosamine. *J. Bone Jt Surg.* **51-A**, 467-474.
- Hall, M. C. (1963) Cartilage changes after experimental immobilization of the knee joint of the young rat. *J. Bone Jt Surg.* **45-A**, 36-44.
- Hall, M. C. (1964) Articular changes in the knee of the adult rat after prolonged immobilization in extension. *Clin. Orthop.* **34**, 184-195.
- Hall, M. C. (1969) Cartilage changes after experimental relief of contact in the knee joint of the mature rat. *Clin. Orthop.* **64**, 64-70.
- Hulth, A., Lindberg, L. & Telhag, H. (1972) Mitosis in human osteoarthritic cartilage. *Clin. Orthop.* **84**, 197-199.
- Lempert, R., Boquist, L. & Rosenquist, J. (1971) Intracartilaginous defects in adult sheep. Histological, autoradiographical (^{35}S -sulphate), ultrastructural, microradiographical and fluorochromic studies. *Virchows Arch. path. Anat.* **354**, 1-16.
- Mankin, H. J. (1963) Localization of tritiated thymidine in articular cartilage of rabbits. III. Mature articular cartilage. *J. Bone Jt Surg.* **45-A**, 529-540.
- Mankin, H. J. (1964) Mitosis in articular cartilage of immature rabbits. A histologic stathmokinetic (colchicine) and autoradiographic study. *Clin. Orthop.* **34**, 170-183.
- Mankin, H. J. (1968) The effect of aging on articular cartilage. *Bull. N.Y. Acad. Med.* **44**, 545-552.
- Marshall, J. L. & Olsson, S.-E. (1971) Instability of the knee. A long-term experimental study in dogs. *J. Bone Jt Surg.* **53-A**, 1561-1570.

- Meachim, G. (1963) The effect of scarification on articular cartilage in the rabbit. *J. Bone Jt Surg.* **45-B**, 150-161.
- Murray, D. G. (1964) Experimentally induced arthritis using intra-articular papain. *Arthr. and Rheum.* **7**, 211-219.
- Telhag, H. & Lindberg, L. (1972) A method for inducing osteoarthritic changes in rabbits' knees. *Clin. Orthop.* **86**, 214-223.
- Telhag, H. (1972) Mitosis of chondrocytes in experimental "osteoarthritis" in rabbits. *Clin. Orthop.* **86**, 224-229.
- Telhag, H. (1973) DNA-synthesis in degenerated and normal joint cartilage in full-grown rabbits. *Acta orthop. scand.* **44**, 604-610.
- Thompson, R. C. J. & Basset, C. A. L. (1970) Histological observations on experimentally induced degeneration of articular cartilage. *J. Bone Jt Surg.* **52-A**, 435-443.

Correspondence to: Torsten Havdrup, M.D., Department of Orthopaedic Surgery, General Hospital, S-214 01 Malmö, Sweden.