

## MUSCLE BLOOD FLOW AFTER AMPUTATION WITH SPECIAL REFERENCE TO THE INFLUENCE OF THE AMPUTATION LEVEL

*Assessed by 133 Xenon and Histamine*

*An Animal Experiment*

CHR. HANSEN-LETH

The Department of Orthopaedic Surgery U, Rigshospitalet, Copenhagen, and  
The Orthopaedic Hospital, Copenhagen.

Amputation on rabbits was found to change the muscle blood flow (MBF) in the limb subjected to surgery as well as in the contralateral extremity, depending on the technique used for amputation and the level at which it was carried out. Amputation was immediately followed by a reduction in MBF in the stump. After amputation of the crus and knee disarticulation, the flow was normalized a few days later and exceeded the preoperative mean flow. After amputation of the femur such an increase in flow was not seen, but when osseous plugging of the medullary cavity was applied, the MBF in the stump was intensified even after amputation of the femur.

*Key words:* amputation; knee disarticulation; medullary plugging; muscle blood flow; myoplasty; 133 Xenon-clearance method

Accepted 25.ix.76

In a previous study (Hansen-Leth 1976) it was demonstrated that assessment of the muscle blood flow (MBF) by 133 Xenon and Histamine (Lindbjerg 1965) was a valuable means of evaluating the vascular changes in rabbits undergoing amputation. After amputation of the crus, an increased MBF was found in the amputation stump; if the stump was closed by myoplasty the flow was intensified and osseous plugging of the medullary cavity resulted in a further increase in MBF.

In this study MBF was measured after amputation of the crus and femur in order to investigate the influence of the

amputation level. Furthermore, amputation with myoplasty and osseous plugging of the medullary cavity was compared with knee disarticulation in order to establish whether MBF might be influenced by surgery on muscle and bone.

### MATERIAL AND METHOD

Twenty-one adult rabbits were subjected to amputation of the left hind leg. In nine cases amputation was performed on the crus, in six cases on a proximal site at the tibiofibular synostosis combined with myoplasty and osseous medullary plugging, and in three cases at a distal level at the transition between muscle and tendon of the triceps surae using myo-

plasty. Knee disarticulation was carried out in four animals; in two of these, disarticulation was combined with simultaneous partial resection of the femoral condyle; in a secondary stage the condyle was removed and the medullary cavity was exposed. In eleven animals, amputation of the femur was performed with myoplasty, three of these had been subjected to amputation of the crus prior to amputation of the femur. In four cases, amputation of the femur was combined with osseous plugging of the medullary cavity.

To investigate the influence of incisions into skin and muscle on the MBF, the crus and femur of five rabbits were incised and MBF subsequently measured. In a further five animals, the immediate changes in MBF after fracture of the crus were investigated.

Surgery was performed in sterile conditions while the animals were under Nembutal anaesthesia. After amputation through the bone, the muscles were joined over the stump; cortex from the removed bone was used for the medullary plugging. In the cases of knee disarticulation, the patellar ligament was sutured to the cruciate ligaments over the femoral condyle. In the fracture cases, the intermediate part of the crus was exposed, a partial osteotomy was performed and the bone was fractured. Healing was uncomplicated in 20 cases and a defect developed on the tip of the stump in one rabbit. After amputation of the crus the animals usually put weight on the stump, while after knee disarticulation of the femur the stump was immobilized with a flexion contracture in the hip.

After the operations, the MBF in quadriceps and triceps surae on both sides was determined by means of 133 Xenon and Histamine, thus agreeing with previous procedures (Hansen-Leth 1976). The calculated MBF was expressed in per cent of the normal blood flow in the muscles concerned, previously determined in 20 rabbits prior to operation. MBF was measured postoperatively on 121 occasions within periods of time from 1 hour up to 130 days after operation with a total of 375 single measurements.

## RESULTS

In agreement with findings in a previous study (Hansen-Leth 1976), the course of the clearance curves was in general monophasic, and the fall set in immediately after the depot had been established. In about one third of all the measurements, however, an initial sta-

tionary phase was seen, and measurements of the flow in the amputation stump also revealed that the rectilinear fall after 5 to 8 minutes was followed by a terminal rise in clearance.

It seems that MBF in the amputation stump generally was decreased one hour after operation (Figure 1). After amputation of the crus, the mean flow was 76 per cent of the preoperative flow and after amputation of the femur, it was 55 per cent.

Incision into skin, whether on the crus or femur, was also found to reduce the MBF in triceps surae (mean flow 65 per cent), and after incision into muscle the mean flow was 89 per cent. Immediately after fracture of the crus the mean flow was 108 per cent of the preoperative flow.

After *amputation proximally on the crus*, combined with medullary plugging, the flow in the stump was increased up to 270 per cent on an average, while *amputation distally on the crus*, with myoplasty, was followed by an increase up to a mean flow of 179 per cent in the second week after operation. After this period the flow was normalized.

After *disarticulation in the knee* an increase in MBF in the left quadriceps was seen from day 3 after the operation, and the flow was increased throughout the period of investigation (Figure 1). Partial resection of the femoral condyle did not change this reaction, MBF was increased as seen after disarticulation, and from 4 to 130 days postoperatively the mean flow was 140 per cent. After total removal of the femoral condyles, including opening of the medullary cavity, the flow was immediately reduced, but from day 3 it increased to a mean flow of 140 per cent and normalized again within a couple of weeks.

Figure 1 illustrates that *amputation of the femur* was followed by an initial reduction and a later normalization in MBF in the stump, and in contrast to findings after amputation on a more dis-

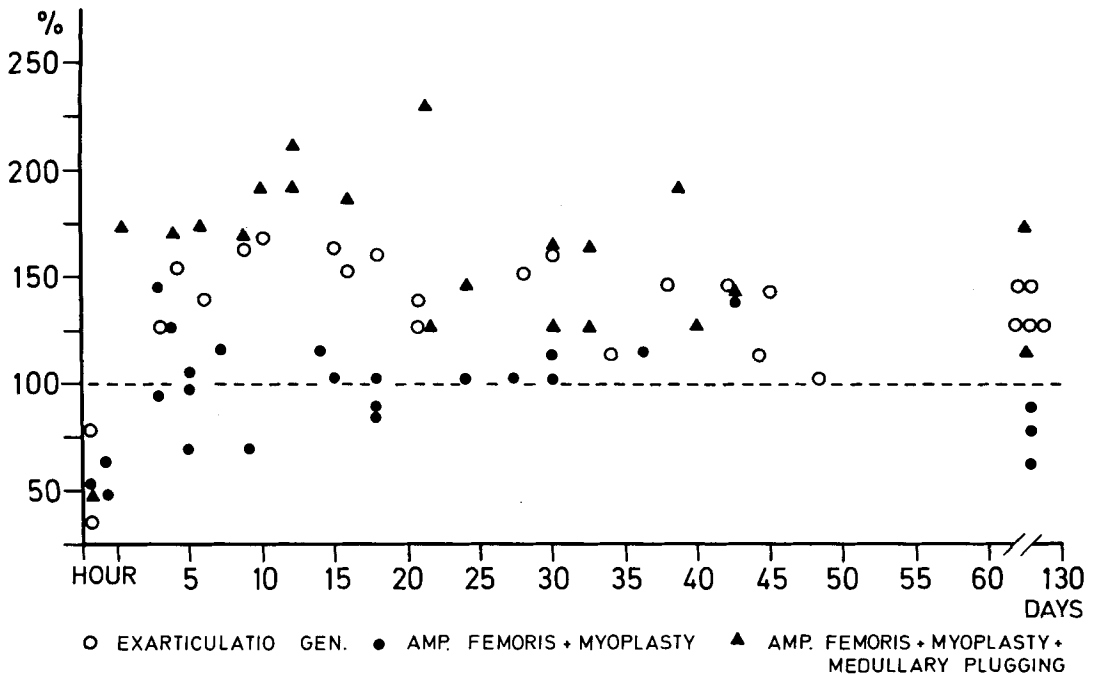


Figure 1. MBF in the amputation stump after knee disarticulation and after amputation of the femur with myoplasty and myoplasty combined with osseous medullary plugging from 1 hour to 130 days after operation.

tal level, the flow in the amputation stump was not increased. Similar changes were observed if amputation of the femur was preceded by amputation of the crus. In the three rabbits in question, the mean flow in the crus stump was 290 per cent, while in the femoral stump it was 110 per cent of the pre-operative flow.

If amputation of the femur were combined with osseous medullary plugging, the initial reduction in MBF in the stump rapidly turns into an increased perfusion (mean flow 164 per cent) which remains intensified up to 10 weeks after the operation (Figure 1).

After amputation of the crus and after incision on skin and muscle, the mean flow in the contralateral quadriceps was slightly increased. After knee disarticulation, the rise in flow in the ipsilateral quadriceps was followed by a uniform increase in MBF in the contralateral

quadriceps (mean flow 131 per cent), but after amputation of the femur, the mean flow in the contralateral quadriceps was not intensified (97 per cent). When amputation of the femur was combined with osseous medullary plugging, the increased MBF in the amputation stump was followed by an intensified flow in the contralateral quadriceps (mean flow 118 per cent). It appears, in general, that change in MBF in the ipsilateral quadriceps is followed by a uniform change in the flow in the contralateral quadriceps.

## DISCUSSION

In agreement with a previous investigation (Hansen-Leth 1976), it was demonstrated in this study that MBF in the amputation stump was reduced immediately after operation, which may be explained by an involuntarily provoked

spasm (Eriksen & Olerud 1966). The reduction in MBF in the crus stump was followed by a uniform decrease in flow in the contralateral triceps surae. A similar reaction was seen after incisions into skin and muscle while the MBF was not reduced after a fracture of the crus. It has been observed by several investigators that trauma to an extremity was followed immediately by an increased perfusion and a decreased flow in the contralateral extremity. Sandegård (1974) observed that repeated blows to the femur of dogs brought about an increase in MBF; conversely, there was no similar change in flow after a closed fracture of the femur. On the other hand, Wray (1964) observed in dogs that a closed fracture of the tibia was followed by an increased flow in the injured extremity and a reduced flow in the contralateral extremity. Periosteal stripping and drilling through bone was not found to result in a changed flow, whereas trauma on only muscle would result in an increased MBF.

Contrary to these findings, amputation brought about a decrease in MBF in the amputation stump, a reaction which must be of importance for the primary healing of the stump. The initial reduction was more marked after amputation of the femur than after amputation of the crus, and the following rise in flow, seen after amputation of the crus, was not seen after amputation of the femur. After knee disarticulation, a moderate though persistent rise in MBF occurred in the ipsilateral and the contralateral quadriceps. Resection of the femoral condyle had no influence on the flow.

It has been demonstrated in a previous study (Hansen-Leth & Reimann 1973) that the level at which amputation is performed may play a role in the vascular reaction to amputation. By arteriography, it has been demonstrated that after knee disarticulation, contrary to crus amputation, hypervascularization

did not occur, and a calibre decrease was found in the larger vessels. These phenomena were not influenced by resection of the femoral condyle. It was also observed by arteriography on live rabbits with amputations at different levels (Hansen-Leth & Karle 197-) that arteries would remain intact up to the level of amputation after amputation of the crus, while amputation of the femur would result in constriction of the femoral artery from the level of the hip joint. In a clinical trial performed by Erikson (1965), arteriography disclosed that the diameters of arteries supplying the amputation stump were more markedly reduced after amputation of the femur than after amputation of the crus.

According to these findings, the level at which amputation was performed was mainly responsible for the maintenance of the MBF in the amputation stump. Another factor of importance was the closure of the medullary cavity. It was observed in a previous study (Hansen-Leth 1976) that MBF increased to a greater extent after osseous medullary plugging than after closure by myoplasty. In agreement with this observation, MBF increased when amputation of the femur was associated with plugging of the medullary cavity. It has previously been shown that plugging of the medullary cavity might stimulate growth of bone (Trueta 1953), and Kellerová et al. (1970) demonstrated in a clinical trial that intensification of the vascularization of bone after fracture was followed by a rise in MBF. Hulth & Olerud (1962) are of the opinion that bone healing of the amputation stump is analogous with healing of a fracture. The findings obtained in this study are in agreement with this supposition.

It has previously been observed that immobilization of an extremity without any other intervention may cause changes in the vascular conditions. Imig et al. (1953) measured the flow directly

and observed that the arterial flow was intensified. Hulth & Olerud (1960) demonstrated, by way of arteriography on rabbits, that various types of immobilization, e.g., amputation of the crus might result in a hypervascularization in the limb concerned. Ferguson & Akahoshi (1960) declared that an extremity which had been immobilized for 6 weeks in a plaster splint would present dilation of vessels and hypervascularization but absence of atrophy of the muscles, as opposed to an extremity subjected to tenotomy or resection of nerves, in which case atrophy of the muscles would occur but not hypervascularization. In this study the femoral muscles, after amputation of the femur which involves immobilization of the femur stump, were found to be severely atrophied, while MBF in the stump was not increased.

It was observed in a previous study (Hansen-Leth 1976) that amputation of the crus intensified the MBF in the contralateral quadriceps, until it equalled the flow in the quadriceps on the side exposed to surgery. A similar increase in the flow in the contralateral quadriceps was also demonstrated after knee disarticulation, but not after amputation of the femur. An exception to this rule was that MBF in the contralateral quadriceps was also increased when amputation of the femur was combined with osseous plugging of the medullary cavity.

According to the findings in this study, the postoperative increase in MBF in the amputation stump depends on the amputation level. It is most pronounced after proximal amputation of the crus and is not seen after amputation of the femur. In agreement with a previous investigation (Hansen-Leth 1976), it has also been shown that osseous medullary plugging intensifies the flow in the amputation stump.

## REFERENCES

- Erikson, U. (1965) Circulation in traumatic amputation stumps. *Acta radiol. (Stockh.)*, Suppl. 238.
- Erikson, U. & Olerud, S. (1936) Healing of amputation stumps, with special reference to vascularity and bone. *Acta orthop. scand.* **37**, 20-28.
- Ferguson jr., A. B. & Akahoshi, Y. (1960) Vascular patterns in immobilized, denervated or devascularized rabbit limbs. *J. Bone Jt Surg.* **42-A**, 617-624.
- Hansen-Leth, C. & Reimann, I. (1973) Knee disarticulation—An experimental study. *Acta orthop. scand.* **44**, 75-86.
- Hansen-Leth, C. (1976) Muscle blood flow after amputation with special reference to the influence of osseous plugging of the medullary cavity—assessed by 133 Xenon and histamine. *Acta orthop. scand.* **47**, 613-618.
- Hansen-Leth, C. & Karle, A. (197-) Studies on amputation in rabbits by intracardial arteriography. Submitted for publication.
- Hulth, A. & Olerud, S. (1960) Disuse of extremities I. An arteriographic study in rabbits. *Acta chir. scand.* **120**, 220-238.
- Hulth, A. & Olerud, S. (1962) Studies on amputation stumps in rabbits. *J. Bone Jt Surg.* **44-B**, 431-435.
- Imig, C. J., Randall, B. F. & Hines, H. M. (1953) Effect of immobilization on muscular atrophy and blood flow. *Arch. phys. Med.* **34**, 296.
- Kellerová, E., Delius, W., Olerud, S. & Strøm, G. (1970) Changes in the muscle and skin blood flow following lower leg fracture in man. *Acta orthop. scand.* **41**, 249-260.
- Lindbjerg, I. F. (1965) Measurement of muscle blood-flow with 133 Xe after Histamine injection as diagnostic method in peripheral arterial disease. *Scand. J. clin. Lab. Invest.* **17**, 371-380.
- Sandegård, J. (1974) Vasodilation in extremity trauma. *Acta chir. scand.*, Suppl. 447.
- Trueta, J. (1953) The influence of the blood supply in controlling bone growth. *Bull. Hosp. Jt Dis.* **14**, 147-157.
- Wray, J. B. (1964) Acute changes in femoral arterial blood flow after closed tibial fracture in dogs. *J. Bone Jt Surg.* **46-A**, 1262-1268.