Acta orthop. scand. 49, 68–72, 1978

A ROENTGEN STEREOPHOTOGRAMMETRIC INVESTIGATION OF INNOMINATE OSTEOTOMY (SALTER)

LARS INGVAR HANSSON, TORD H. OLSSON, GÖRAN SELVIK & GÖRAN SUNDÉN

Departments of Orthopaedic Surgery and Diagnostic Radiology, Lund University Hospital, and Department of Anatomy, University of Lund, Lund, Sweden

The effect of the innominate osteotomy according to Salter was investigated by a roentgen stereophotogrammetric method in a 17-year-old girl with hip dysplasia as a part of the tricho-rhino-phalangeal (Giedion) syndrome.

The osteotomy resulted in a total rotation of 32° about an axis passing cranially to the pubic symphysis and the osteotomy. The acetabulum rotated 22° forwards about a transverse axis, 9° laterally about a longitudinal axis and 24° laterally about a sagittal axis. The acetabulum was translated 2 mm laterally along a transverse axis, 21 mm caudally along a longitudinal axis and 19 mm dorsally along a sagittal axis.

The position of the screw axis indicates that some motion also took place in one or both of the sacroiliac joints.

The correction as measured with the CE-angle was 25° which was almost the same as the correction about the sagittal axis. It is, however, noted that the CE-angle was also dependent upon the rotations about the transverse and longitudinal axes.

Key words: hip; osteotomy; pelvis; roentgen stereophotogrammetry; tricho-rhino-phalangeal syndrome

Accepted 19.ix.77

The principle of innominate osteotomy according to Salter is the redirection of the entire acetabulum in order to increase the joint stability and the contact surfaces between the femoral head and acetabulum (Salter 1961, 1969, Salter & Dubos 1974). The primary indication for this osteotomy is congenital dislocation of the hip with acetabular dysplasia but the method has been used for paralytic hip dislocation, Perthes' disease and certain types of fixed pelvic obliquity (Salter & Dubos 1974) and in acetabular dysplasia with osteoarthritis (Wedge & Salter 1974).

The degree of correction of the acetabulum has generally been estimated by determination of the CE-angle (Wiberg 1939) and has been correlated with the clinical improvement (Crellin 1974, Denton & Ryder 1974, Salter & Dubos 1974, Wedge & Salter 1974). However, in the innominate osteotomy according to Salter the acetabulum moves about an axis not identical with a sagittal axis. The orientation of the acetabulum in the AP-projection is therefore different pre- and postoperatively causing difficulties locating the same bases for the determination of the CE-angle. To obtain better information about this movement the translation and rotation of the acetabulum has been determined by a roentgen stereophotogrammetric method (Selvik 1974) using tantalum indicators above and below the osteotomy level.

CASE REPORT

The patient was a 17-year-old girl of short stature and with a radiological right-sided acetabular dysplasia (CE-angle – 3°) including deformation of the femoral head and neck with varus position (Figure 1). Roentgenological investigation showed general dysplastic deformations as in the tricho-rhino-phalangeal (Giedion) syndrome. During the previous 2 years there had been increasing disability in the right hip. Clinical examination showed normal movements in the hip but positive Trendelenburg's test. As operative procedure an innominate osteotomy on the right side according to Salter was chosen.

Operation

The operative procedure was performed according to the instructions for the operation of non-dislocated hips with acetabular dysplasia (Salter 1961, 1969, Tachdjian 1972, Salter & Dubos 1974, Wedge & Salter 1974). At the operation there was instability of the femoral head in relation to the acetabulum with a movement of about 0.5 cm without dislocation. The tendinous part of the iliopsoas muscle was divided and after that it was possible to open up the osteotomy enough to place and fix the triangular bone graft. The base was chosen according to Salter (1969) as the distance between the superior and inferior anterior iliac spines and measured about 3 cm. The length was estimated to be 5 cm resulting in an angular correction of about 30° with an anteriorly open angle.

After 6 weeks in a plaster spica the patient was mobilised. One year after the operation she has no complaints regarding her right hip and she has started to work again. Clinically there is now a negative Trendelenburg's test and the range of movement is almost normal. Postoperatively the right side is about 1 cm longer than the left side.

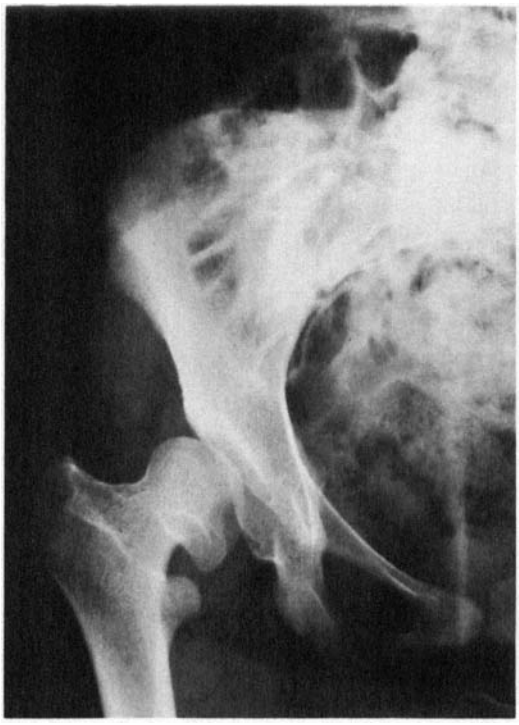

Figure 1. AP radiograph of the pelvis showing the dysplastic right hip.

Roentgen stereophotogrammetric method

The primary objective of roentgen stereophotogrammetry is to determine the three-dimensional coordinates of structures in the body (Selvik 1974, Olsson 1975, Olsson et al. 1976). Generally, there are no sufficiently distinct points in the body to allow identification with high accuracy in the two projections necessary for a three-dimensional reconstruction. Thus, radiopaque indicators, tantalum balls with a diameter of 0.8 mm, were introduced in each skeletal segment studied. Following the technique of Aronson et al. (1974), an indicator was placed in the tip of a needle and deposited during fluoroscopy in the bone into which the needle had been forced 1–2 mm. These tantalum markers serve as measurement points on the radiographs. To allow for a study in terms of three-dimensional rigid-body motion, three indicators were placed in the ilium and three in the segment caudally to the osteotomy.

Simultaneous exposures of the pelvis with two roentgen tubes on one film were made pre- and postoperatively. On each film, a calibration cage supplied with tantalum indicators, the mutual positions of which are known, was also double-exposed. The coordinates of the images of both patient and calibration indicators were then measured by means of an instrument for cartography. The information thus obtained was treated by means of a computer so that the three-dimensional positions of the indicators were determined in a laboratory coordinate system. This laboratory coordinate system is defined by the calibration cage markers, which are situated in two planes. The patient is investigated in such a position that the main axes of the body (transverse, longitudinal and sagittal axis) are parallel to those of the cage coordinate system (Olsson et al. 1976). Identical orientation of the patient at different examinations is not necessary.

In the subsequent analysis, the rigid-body

motion between the indicated segments was computed, and the results were visualized by computer drawings and on radiographs. The iliac indicators were taken as a reference. The rotations and translations of the caudal, acetabular segment in relation to the ilium were given in the coordinate system of the preoperative investigation. In this analysis, the reference segment at later investigations is calculated back to its position at the reference examination, which explains why identical orientation on different occasions is not needed.

Besides the rotation angles about the main axes, the total rotation and the position of an axis, called the screw axis of the movement, were calculated. The screw axis is the axis of rotation for a general rigid-body displacement which is the closest approximation to the uniquely defined axis of rotation in a pure rotatory movement. Using the screw-axis description, the rigid-body motion is a rotation about and a translation along the same axis. The position of the screw axis was related to frontal, lateral, and axial orthographic projections of the indicators, drawn by computer. To visualize it better it also was drawn on frontal and lateral radiographs, exposed with the central ray passing through the midpoint of the indicators in the caudal segment. The position of the axis was related to this midpoint but no correction was made for the radiograph being a central projection.

In contrast to the rotation angles, the translation varies over a segment if the motion is not a pure translation. As illustration, the translation was given for a point in the roof of the acetabulum, where one of the indicators was placed (Figures 2 and 3).

The precision of the method was earlier estimated to be approximately 0.2° for the rotations about and 0.1 mm for the translations along the three coordinate axes (Olsson 1975). In the present study two roentgen films were exposed at the postoperative investigations. Comparing the rotation angles and translations obtained from these two films no angle difference exceeded 0.1° and no translation difference exceeded 0.2 mm. The directions of the screw axes differed 0.2°, and their positions differed 0.1 mm.

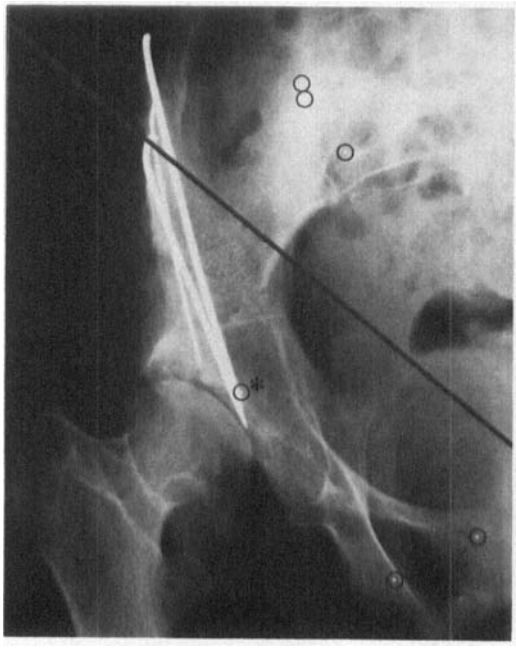

Figure 2. Right hip postoperatively. The indicators and the screw axis are marked, the acetabular indicator further marked with an asterisk. Frontal radiograph centred on the acetabular segment.

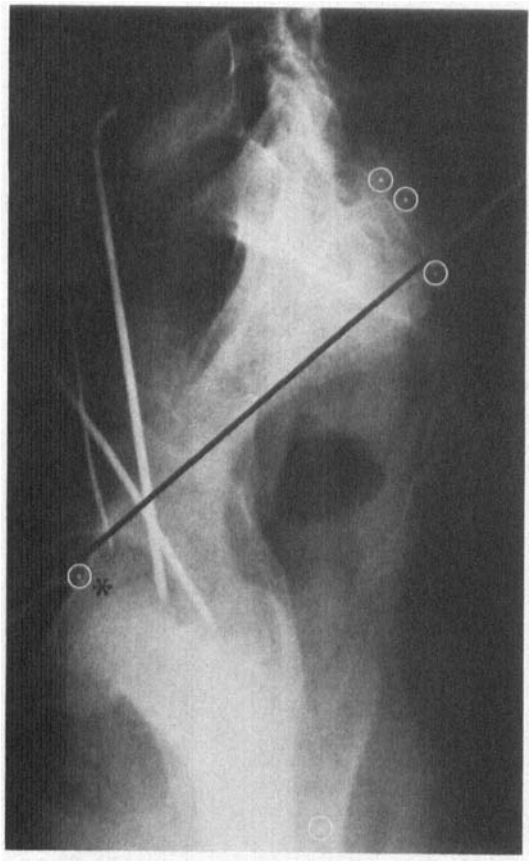

Figure 3. Lateral view of the pelvis with the patient supine and a horizontal central ray, centred on the acetabular segment. The symphyseal indicator cut; otherwise as in Figure 2.

RESULTS

The acetabulum rotated 22.3° forwards about a transverse axis (the cranial part moved forwards), 9.3° laterally about a longitudinal axis (the ventral part moved towards the right side of the patient) and 23.6° laterally about a sagittal axis (the cranial part moved towards the right) in relation to the right ilium. These rotations can also be expressed as a total rotation of 32.4° about the screw axis (Figures 2 and 3). It is found that this axis passes from the right, dorsal and cranial part of the pelvis to the left, ventral and caudal part, and it is noted that it passes cranially to the osteotomy and cranially to the pubic symphysis.

The indicator in the acetabulum (Figures 2 and 3) was translated 1.6 mm towards the right side of the patient along a transverse axis, 20.5 mm caudally along a longitudinal axis and 18.9 mm dorsally along a sagittal axis in relation to the right ilium. The translation along the screw axis was 4.8 mm in the upward direction.

DISCUSSION

The motion of the segment caudally to the osteotomy, including the acetabulum, was calculated in relation to the segment cranially to the osteotomy, but it was not known which of these segments was moving or if they both moved in opposite directions. If only the acetabulum had moved and the rest of the pelvis had constituted a rigid body the acetabulum should have rotated about an axis which passed through the pubic symphysis. As this was not the case (Figure 2) it is concluded that some motion also took place in one or both of the sacroiliac joints. This is indirect evidence that not only did the acetabulum move downwards, but that the ilium also moved upwards. This fact must be kept in mind when the operation is planned so it can be compensated for.

Concerning the size of the triangular bone graft, Salter (1969) has found that the length of the base is no problem as the distance between the superior and inferior anterior iliac spines increases with age and compensates for the increased demand in size. However, as small children have relatively greater joint instability it can be anticipated that the ilium probably also moves relatively more in relation to the transverse plane in younger than in older children. Thus the gained tilt of the acetabulum will be relatively less in younger children.

In this case the CE-angle was changed from −3° to 22° by the osteotomy, indicating a better covering by the acetabulum which has also been found in previous investigations (Crellin 1974, Denton & Ryder 1974, Salter & Dubos 1974, Wedge & Salter 1974). As mentioned above, the calculation of the CE-angle is difficult. However, the noted change is about 25°, which is the same as the rotation about the sagittal axis (24°). There is also a considerable rotation about the transverse axis (22°), which contributes to a better covering of the femoral head. The rotation of 9° laterally about the longitudinal axis will therefore, in this particular case, not affect the height of the acetabular edge seen in the AP-projection.

REFERENCES

Aronson, A. S., Holst, L. & Selvik, G. (1974) An instrument for insertion of radiopaque bone markers. *Radiology* **113,** 733–734.

Crellin, R. Q. (1974) Innominate osteotomy for congenital dislocation and subluxation of the hip. *Clin. Orthop.* **98,** 171–177.

Denton, J. R. & Ryder, C. T. (1974) Radiographic follow-up of Salter innominate osteotomy for congenital dysplasia of the hip. *Clin. Orthop.* **98,** 210–213.

Olsson, T. H. (1975) A roentgen stereophotogrammetric study of the kinematics of the spine. Thesis, Lund.

Olsson, T. H., Selvik, G. & Willner, S. (1976). Kinematic analysis of spinal fusions. *Invest. Radiol.* **11,** 202–209.

Salter, R. B. (1961) Innominate osteotomy in the treatment of congenital dislocation and subluxation of the hip. *J. Bone Jt Surg.* **43-B,** 518–539.

Salter, R. B. (1969) An operative treatment for congenital dislocation and subluxation of the hip in the older child. *Recent advances in orthopaedics*, Ed. Apley, A. G., pp. 325–360. Churchill, London.

Salter, R. B. & Dubos, J.-P. (1974) The first fifteen years' personal experience with innominate osteotomy in the treatment of congenital dislocation and subluxation of the hip. *Clin. Orthop.* **98,** 72–103.

Selvik, G. (1974) A roentgen sterophotogrammetric method for the study of the kinematics of the skeletal system. Thesis, Lund.

Tachdjian, M. D. (1972) *Pediatric orthopedics.* Saunders: Philadelphia, London, Toronto.

Wedge, J. H. & Salter, R. B. (1974) Innominate osteotomy: Its role in the arrest of secondary degenerative arthritis of the hip in the adult. *Clin. Orthop.* **98,** 214–224.

Wiberg, G. (1939) Studies on dysplastic acetabula and congenital subluxation of the hip joint. *Acta chir. scand.* **83,** Suppl. 58.

Correspondence to: Lars Ingvar Hansson, M.D., Department of Orthopaedic Surgery, Lund University Hospital, S-221 85 Lund, Sweden.