

ACTA ORTHOPAEDICA SCANDINAVICA
SUPPLEMENTUM NO. 174

From the Department of Orthopaedic Surgery, University of Lund, Sweden

Lateral Elbow Pain and Posterior Interosseous Nerve Entrapment

BY

CARL-OLOF WERNER

MUNKSGAARD . COPENHAGEN

ISBN 87-16-08359-8 ISSN 0300-8827
Printed in Sweden
Bröderna Ekstrands Tryckeri AB, Lund 1979

CONTENTS

| | Page |
|--|------|
| I INTRODUCTION | 5 |
| II MATERIAL | |
| Entrapment series | 6 |
| Autopsy series | 7 |
| Lateral epicondylitis series | 7 |
| III METHODS | |
| Clinical examination | 9 |
| Neurophysiological examination | 9 |
| Operative technique | 10 |
| Autopsy technique | 12 |
| Statistical methods | 13 |
| IV RESULTS | |
| 1. Preoperative observations | 14 |
| 2. Observations at surgery | 15 |
| 3. Postoperative observations | 19 |
| 4. Observations at surgery related to results of surgery | 26 |
| 5. Neurophysiological observations | 29 |
| 6. Autopsy observations | 30 |
| 7. Comparison of epidemiology and symptomatology in the entrapment and lateral epicondylitis series | 33 |
| V DISCUSSION | 36 |
| VI CONCLUSIONS | 48 |
| VII SUMMARY | 49 |
| VIII APPENDIX | |
| 1. Neurophysiological data | 52 |
| 2. Coded data in the entrapment series | 53 |
| 3. The questionnaire | 57 |
| IX ACKNOWLEDGEMENTS | 58 |
| X REFERENCES | 59 |

TABLES

| | |
|----------|---|
| Table 1 | Clinical signs in the entrapment series. |
| Table 2 | Results of decompression of the posterior interosseous nerve. |
| Table 3 | Clinical signs related to the final results. |
| Table 4 | Results of re-operations 12 months postoperatively. |
| Table 5 | The extensor carpi radialis brevis muscle in relation to the nerve related to the final results. |
| Table 6 | The edge of the superficial supinator muscle at intersection with the nerve related to the final results. |
| Table 7 | Dynamic compression and appearance of the nerve at intersection with the supinator edge related to the final results. |
| Table 8 | Comparison of the extensor carpi radialis brevis muscle, the superficial supinator muscle and the nerve in the entrapment and autopsy series. |
| Table 9 | Comparison of pain characteristics and previous therapy in the entrapment and lateral epicondylitis series. |
| Table 10 | Comparison with published series. |

FIGURES

| | |
|-----------|--|
| Figure 1 | Age and sex distribution in the entrapment series. |
| Figure 2 | Selection of the lateral epicondylitis series. |
| Figure 3 | Schematic drawing of the operative field and method of decompression. |
| Figure 4 | Entrapment site and line of incision. |
| Figure 5 | Subcutaneous fat placed over the decompressed nerve to prevent scar formation. |
| Figure 6 | Relation between the extensor carpi radialis brevis muscle and the nerve. |
| Figure 7 | Relation between the superficial supinator muscle and the nerve. |
| Figure 8 | Dynamic compression of the nerve by the supinator edge. |
| Figure 9 | Indentation of the nerve under the divided supinator edge. |
| Figure 10 | Indentation of the nerve under the divided supinator edge. |
| Figure 11 | Clinical signs before and after decompression of the posterior interosseous nerve. |
| Figure 12 | Results of decompression in relation to clinical signs. |
| Figure 13 | Effect of decompression on grip strength. |
| Figure 14 | Effect of decompression on grip strength in patients operated on the dominant side only. |
| Figure 15 | Results of decompression in relation to clinical signs and anatomy. |
| Figure 16 | Nerve alteration of the posterior interosseous nerve observed at autopsy. |
| Figure 17 | Microscopic appearance of the nerve alteration from figure 16. |
| Figure 18 | Enlargement of the upper right section of figure 17. |
| Figure 19 | Comparison of work in the entrapment and lateral epicondylitis series. |

(All figures have been arranged to show the same orientation, i.e. some have been reversed).

INTRODUCTION

Tennis elbow is often used as a popular term for pain in the lateral side of the elbow. Some authors use tennis elbow and epicondylitis as synonyms, there is, however, no general agreement about this. In this context tennis elbow will be used in the general sense including epicondylitis, painful annular ligament, entrapment and other possible causes of pain and tenderness in the lateral side of the elbow.

Writing about tennis elbow Winckworth (1883) stated:

"In the case of the posterior interosseous nerve (one of the main branches of the musculospiral) it passes through the substance of the supinator brevis muscle, where it would be all the more liable to become pinched by any unusual action of the muscular fibres." A number of recent authors have supported the idea that entrapment of the posterior interosseous nerve could be one cause of tennis elbow (Kopell and Thompson (1963), Capener (1966), Gianetti (1968), Roles and Maudsley (1972), Dewey (1973), Narakas (1974), Spinner and Spencer (1974), Comtet et al. (1976), Lister (1977), v. Torklus (1977), Schmitt and Biehl (1978)). Hagert et al. (1977) even distinguished lateral epicondylitis from entrapment of the posterior interosseous nerve as two different conditions causing pain.

The purpose of the present investigation was to further analyse the hypothesis that posterior interosseous nerve entrapment could be a cause of lateral elbow pain. To ascertain this the following investigations were carried out:

1. Patients with longstanding lateral elbow pain in whom entrapment of the posterior interosseous nerve was the suspected cause of pain were operated on by decompression of the nerve where it enters the supinator muscle and then subjected to a follow-up for two years. The preoperative symptoms and signs and observations at surgery were related to the results.
2. The topographical anatomy at the suspected entrapment site in the entrapment series was compared with observations at dissections in an unselected autopsy series.
3. The epidemiology and symptomatology in the entrapment series was compared with that in a series of lateral epicondylitis.

MATERIAL

Entrapment series

To select patients whose pain might be relieved by decompression of the posterior interosseous nerve the following qualifications were required:

1. Pain. Protracted pain in the lateral side of the elbow. Pain at work and at rest following exertion, and pain radiating proximally or distally from the elbow.
2. Tenderness. Tenderness on palpation over the posterior interosseous nerve where it passes under the upper edge of the superficial supinator muscle (Fig. 4).

To collect the maximal number of patients for this series orthopaedic and general surgeons, as well as general practitioners were encouraged to refer patients with longstanding therapy-resistant lateral elbow pain. Fourteen patients were selected from a three-year material of lateral epicondylitis (vide infra).

The entrapment series of 85 patients included 37 males, mean age 47 ± 9 years and 48 females, mean age 41 ± 9 years. Three males and two females were operated bilaterally making a total of 90 cases treated by nerve decompression.

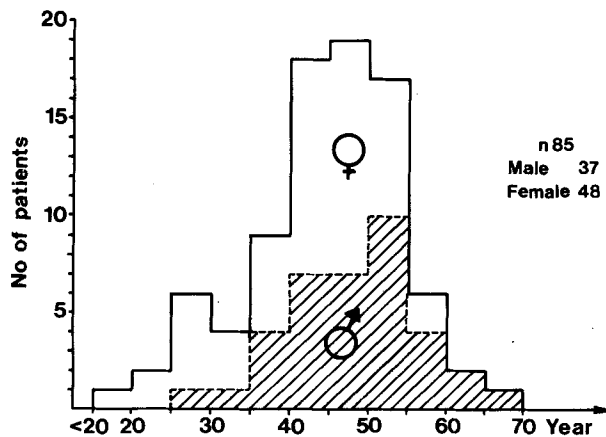


Fig. 1. Age and sex distribution in the entrapment series.

The preoperative duration of pain was 6-12 months in 3 patients; 1-2 years in 53 and more than 2 years in 29. All but 12 patients had previously been treated for lateral epicondylitis.

At the first visit 65 patients had pain only in the side of the dominant hand, 11 only

in the non-dominant side and 9 in both sides. Preoperative sickleave, mean 5 ± 3 months, was reported by 69 patients; the remaining patients had been able to work despite their symptoms.

In all but two patients the onset of pain was insidious. One patient (Case 22) had received a blow on the lateral side of the elbow and had thereafter increasing pain which made it difficult to work. Conservative treatment was without success. The other patient (Case 47) had sustained a Colles fracture seven months before decompression; there was no history of elbow trauma and electromyography confirmed the diagnosis of entrapment. All the patients were operated by the author at the Hand Surgery Unit of the Department of Orthopaedic Surgery, University Hospital of Lund.

Autopsy series

Dissections of the suspected entrapment site were performed in an unselected autopsy series of 60 individuals, 38 males, mean age 52 ± 15 years and 22 females, mean age 57 ± 11 years in the Departments of Pathology and of Forensic Medicine at the University Hospital of Lund. As far as could be gathered there was no history of elbow pain for these individuals.

Lateral epicondylitis series

An investigation was carried out of patients who according to the outpatient number register were treated for epicondylitis from 1972 through 1974 at the Department of Orthopaedic Surgery, University Hospital of Lund. During these three years 249 patients were on one or several occasions treated for epicondylitis; 234 lateral and 15 medial. To the 234 patients treated for lateral epicondylitis a questionnaire (Appendix 3) was sent in 1974 to those treated in 1972 and 1973, and in 1975 to those treated in 1974. Two patients had died and of the remainder 203 replied. A new examination was requested because of pain by 58 patients and of these 14 fulfilled the qualifications for entrapment and were included in the entrapment series (Fig. 2).

Two patients in addition were later subjected to decompression, one bilaterally. The follow-up time for these two was less than two years and they were therefore not included in the entrapment series. The above 16 (14+2) patients who underwent nerve decompression were excluded from the series of lateral epicondylitis which thus comprised 187 patients, 89 males, mean age 46 ± 10 years and 98 females, mean age 47 ± 9 years.

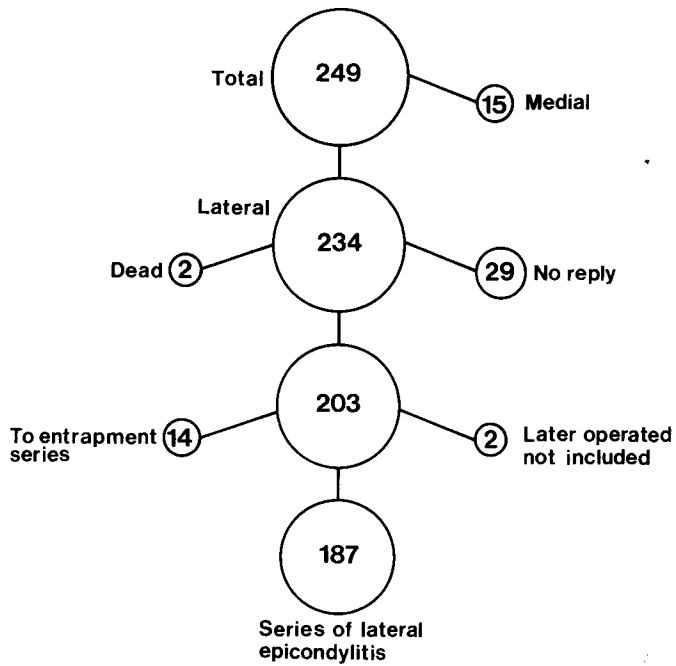


Fig. 2. Selection of the lateral epicondylitis series.

METHODS

Clinical examination

The patients were examined sitting at a table opposite the examiner, who noted:

- (1) Tenderness by gentle palpation over the lateral epicondyle.
- (2) Tenderness by gentle palpation over the posterior interosseous nerve where it passes through the supinator muscle 4-5 cm distal to the lateral epicondyle (Fig. 4).
- (3) Pain on active supination and pronation against resistance with the forearm in the neutral position and the elbow flexed 20°.
- (4) Pain on extension of the middle finger against resistance with the elbow fully extended (Roles and Maudsley 1972).
- (5) Grip strength in both hands (Thorngren and Werner 1979).

All examinations were performed by the author and carried out on both sides. The pain-free side served as control, except in nine patients with bilateral symptoms. The pain reaction in tests 1-3 was recorded as intense, slight or absent. The pain reaction in test 4 being difficult to qualify was recorded as present or absent.

To eliminate the supinating effect of the biceps muscle, extension of the elbow would have been preferable, but in this position it was found difficult to exclude rotation at the shoulder and therefore slight elbow flexion was used. Grip strength was used as an indirect measure of pain where no other explanation for a diminished grasping force could be found. All patients replied to the same questionnaire as used in the series of lateral epicondylitis. Before surgery was decided most patients were examined on two occasions and all were informed that the effect of the operation could not be predicted.

Neurophysiological examination

Neurophysiological examinations were made preoperatively in 25 arms in 24 patients.

- (1) The motor conduction velocity of the radial nerve was determined between a point proximal to the elbow and a point distal to the supinator muscle. Control determinations of motor conduction velocity were performed in 12 arms at approximately one year postoperatively.
- (2) Electromyographic recordings were performed from muscles innervated by the radial nerve from branches emerging proximal and distal to the supinator muscle.

The examinations were carried out at the Department of Clinical Neurophysiology, University Hospital of Lund. Adviser for interpretation of neurophysiological data: Ingemar Rosén.

Operative technique

After winding round the humeral shaft the radial nerve passes through the lateral inter-muscular septum into the anterior compartment in the arm where it lies in the interspace between the brachialis and brachioradialis muscles; more distally it is covered antero-laterally by the extensor carpi radialis longus muscle. The nerve branches into the posterior interosseous nerve and the superficial radial nerve. Below the elbow the posterior interosseous nerve is often crossed by a fascial extension from the extensor carpi radialis brevis muscle and thereafter it passes between the superficial and deep parts of the supinator muscle (Kaplan 1959, Roles and Maudsley 1972). The proximal edge of the superficial supinator muscle forms an arch (Frohse and Fränkel 1908, Spinner 1968), the arcade of Frohse. A few cm distally the nerve lies close to the dorso-lateral side of the radius, the so-called bare area (Spinner 1972).

The aim of the operation was to decompress the posterior interosseous nerve in that location where it might be compressed by static or dynamic forces through (1) the extensor carpi radialis brevis muscle where this muscle may have a fascial extension medially crossing and in direct contact with the nerve and (2) the edge of the superficial supinator muscle under which the nerve passes (Fig. 3).

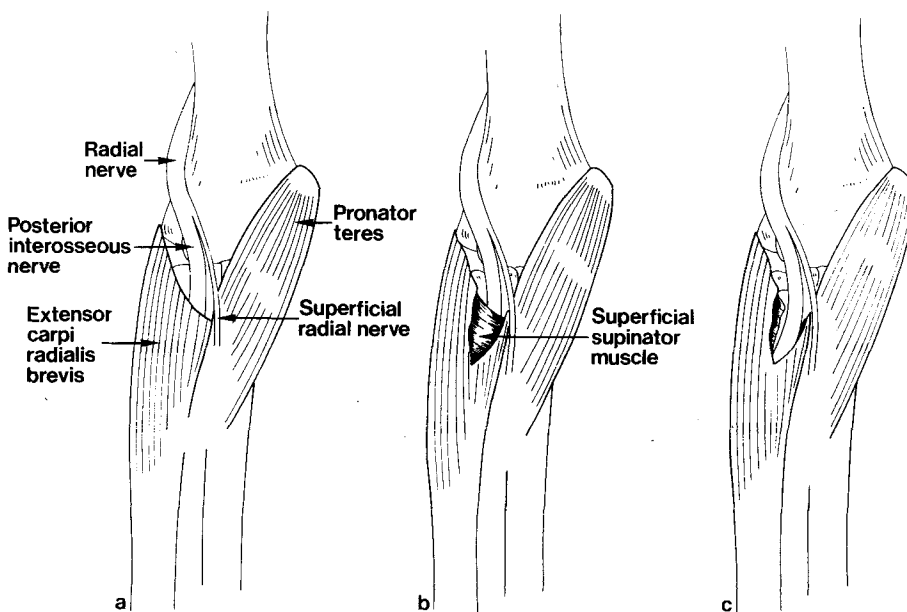


Fig. 3. Schematic drawing of the operative field and method of decompression. Anterior view of elbow. a) Extensor carpi radialis brevis crossing the posterior interosseous nerve by a fascial extension. b) Extensor carpi radialis brevis divided, the nerve passes beneath the edge of the superficial supinator muscle. c) Superficial supinator muscle divided, decompression completed.

The operations were performed as an out-patient procedure under brachial plexus block anaesthesia using 20 ml 2 per cent Carbocain with adrenalin (Bofors) and in a bloodless field. At the beginning of the series a lazy-S incision was used with dissection medial to the extensors of the forearm down to the nerve. This exposure was later changed to a straight dorso-lateral incision with dissection between the extensor carpi radialis longus and brevis muscles which gave easier access to the nerve (Fig. 4).

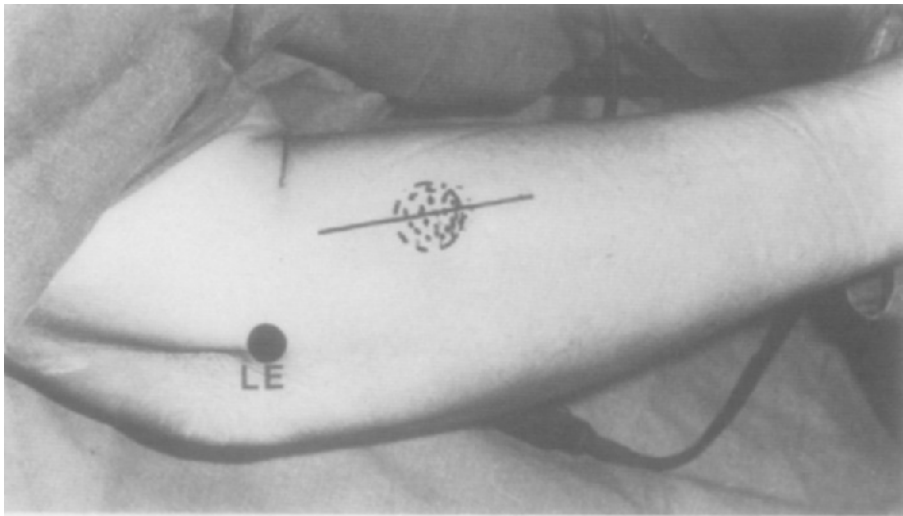


Fig. 4. Entrapment site and line of incision. The right forearm seen from the side. Dotted area: maximal tenderness over the nerve. LE: lateral epicondyle. Straight line: skin incision.

The appearance of the extensor carpi radialis brevis and superficial supinator muscles and their relation to the nerve was recorded as well as whether the nerve was compressed by either of these muscles on passive rotation of the forearm with the elbow extended (Roles and Maudsley 1972).

The nerve was decompressed by a 1-2 cm long incision through the muscles. The appearance of the nerve was then recorded. After decompression the tourniquet was released and a thorough haemostasis obtained. Only the skin was sutured. The arm was supported with a soft compression dressing and elevated for 2-3 hours. Dressings were removed at 7-10 days postoperatively.

At re-operations performed because of recurrences or lack of improvement from the primary operation the nerve was found to be surrounded by adhesions and scar tissue. In an attempt to minimize new scar formation subcutaneous fat, taken as a free fat transplant, (Langenskiöld and Kiviluoto 1976) was placed over the decompressed nerve. This procedure was used regularly at the primary operations from case 66 onwards (Fig. 5).

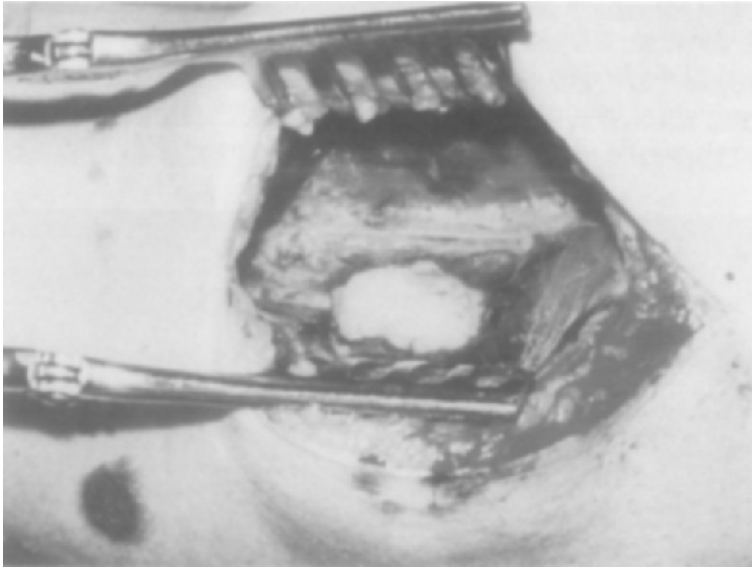


Fig. 5. Subcutaneous fat placed over the decompressed nerve to prevent scar formation. This procedure was used at re-operations and at the last 25 primary operations.

The operations were performed between January 1975 and September 1976. Convalescence of 1-2 months was regularly prescribed and prolonged when necessary to allow time for training and readaptation to work. The postoperative sickleave was 3 ± 2 months; in 61 cases 1-2 months. The patients were followed-up at 6 weeks and 6, 12 and 24 months postoperatively.

The patients were advised to change their method of working or seek employment with less demands on the arm especially with regard to rotatory movements. It seemed reasonable that even though the nerve had been decompressed, less strain on the arm would be favourable in the long run. Most patients preferred to continue at their previous work and only ten patients changed their type of work postoperatively.

Autopsy technique

Using the same approach as at operation dissections were performed on the right arm in all 60 individuals and on the left arm also in 30. The appearance of the muscles and their relation to the nerve were recorded as well as the appearance of the nerve. Histological examinations of the nerve were performed in two instances where the nerve showed a macroscopic alteration and in ten where it had a normal appearance. The histopathological work was done in collaboration with Arne Brun, neuropathologist at the Department of Pathology, University Hospital of Lund.

The specimens consisted of the nerve from 1.5 cm proximal to 1.5 cm distal to the supinator edge resting on a muscular bed. They were placed on cardboard, gently stretched and allowed to adhere to the cardboard. This was done in order to prevent wrinkling and undue shrinkage of the nerve. The point of intersection between the nerve and the supinator edge was indicated on the cardboard to direct later sampling. The specimens were then fixed in 10 per cent formaline for at least one week. Of those ten nerves with a normal appearance, five were sampled in transverse cuts, 5 mm apart including the point of intersection between the nerve and the edge of the superficial supinator muscle. The other five nerves and the two nerves with visible alterations were cut longitudinally with the intersection point in the centre. The samples were embedded in paraffin, cut in 5μ thick sections and stained with haematoxylin-eosine as well as with van Gieson for connective tissue.

Statistical methods

The Student's t-test and the Fisher-Irwin exact test were used. The p-values were indicated as follows:

xxx implies $p < 0.001$

xx $0.001 < p < 0.01$

x $0.01 < p < 0.05$

(-) $p > 0.05$

Statistical adviser: Klas Svensson, Department of Statistics, University of Lund.

RESULTS

I. PREOPERATIVE OBSERVATIONS (Table I)

a. Symptoms

By definition pain was the chief complaint. It was described by the patients as deep, aching, diffusely localized around the lateral side of the elbow and the dorsal side of the proximal forearm. The pain radiated distally toward the back of the hand and occasionally also proximally above the elbow. Pain usually began after one or two hours of work, increased in intensity and did not subside at rest. Pain at rest after exertion was the most characteristic finding and it often continued at night; 61 patients reported waking up at night because of pain. When pain was well established prolonged rest did not bring much relief. Analgetics were used during the day as well as at night by most patients. Besides pain, many patients complained of tiredness and a feeling of heaviness in the arm but in no case was there any history of paralysis in muscles innervated by the posterior interosseous nerve.

b. Signs

All cases had intense tenderness on palpation at the suspected entrapment site. Only gentle pressure was needed to demonstrate this and even if the area of tenderness was sometimes diffuse, the maximal tenderness was situated over the suspected entrapment site (Fig. 4). In one third of the cases the epicondyle was not tender. In most cases there was pain on active supination and pronation against resistance and through repeated rotatory movements it was often possible to elicit continuous pain.

The pain reaction on resisted supination was usually diffusely localized around the lateral side of the elbow and the proximal part of the forearm; the pain reaction on resisted pronation was more often centered over the lateral epicondyle. In one third of the cases it was not possible to elicit pain on resisted extension of the middle finger; when this test was positive the maximal pain was usually located over the lateral epicondyle. Because of previous hand or finger injuries the preoperative grip strength could not be used as an indirect measure of pain in 9 cases. Only 22 of the remaining 81 cases had values within ± 2 S D of normal.

Table I. Clinical signs in the entrapment series

| | Epicondylar tenderness | Tenderness over radial nerve | Pain on resisted supination | Pain on resisted pronation | Pain on resisted extension of the middle finger |
|---------|------------------------|------------------------------|-----------------------------|----------------------------|---|
| Intense | 35 | 90 | 51 | 41 | 67 (present) |
| Slight | 26 | - | 33 | 36 | |
| Absent | 29 | - | 6 | 13 | 23 |

2. OBSERVATIONS AT SURGERY

In 54 of the 90 cases the nerve was crossed by a fascial extension from the extensor carpi radialis brevis muscle where there was direct contact between the extension and the nerve; sometimes the extension formed a narrow arch (Fig. 6). There was no visible compression of the nerve by this extension during passive rotation of the forearm or volar flexion of the wrist; nor was there any sign of static compression such as an indentation at or under the intersection between the extension and the nerve.

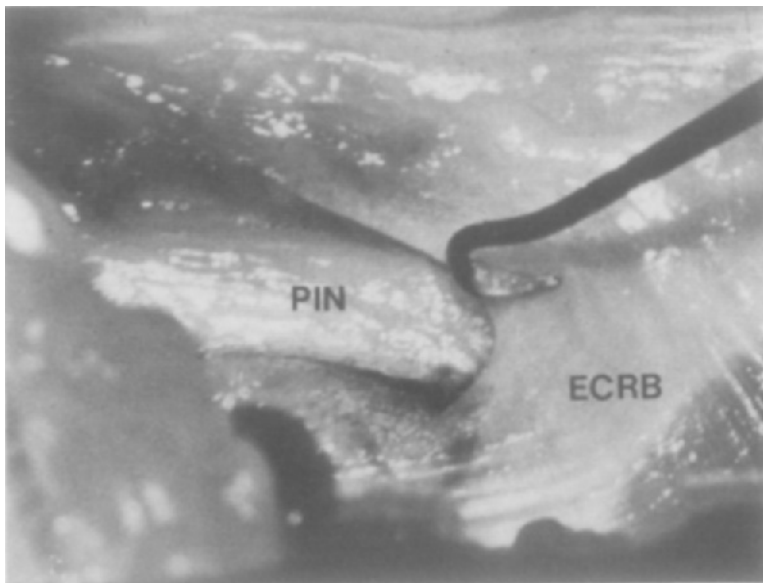
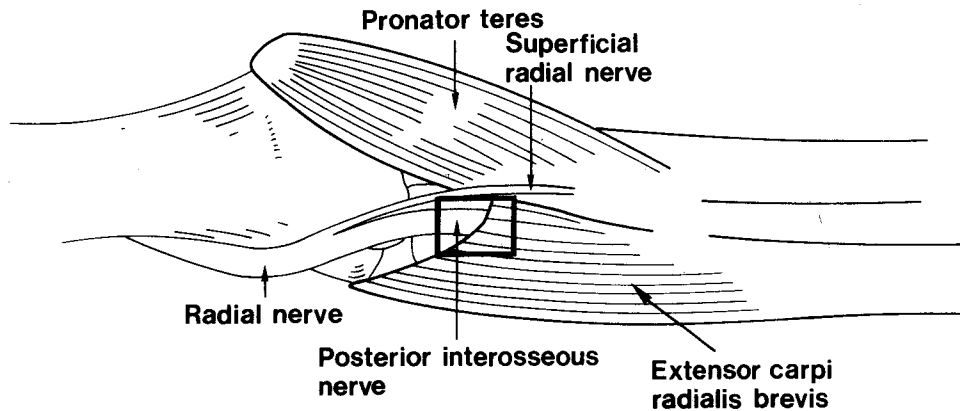


Fig. 6. Relation between the extensor carpi radialis brevis muscle and the nerve (Case 72). A sharp fascial extension from the extensor carpi radialis brevis muscle (ECRB) forming an arch (elevated by the hook) is seen crossing the posterior interosseous nerve (PIN). An extension from the extensor carpi radialis brevis crossing the nerve was observed in 54 of the 90 cases.

In 80 of the 90 cases the superficial portion of the supinator muscle had a well developed fibrous edge at intersection with the nerve (Fig. 7). In the remaining cases the edge was muscular or translucent membranous, referred to as "not fibrous" in the subsequent text.

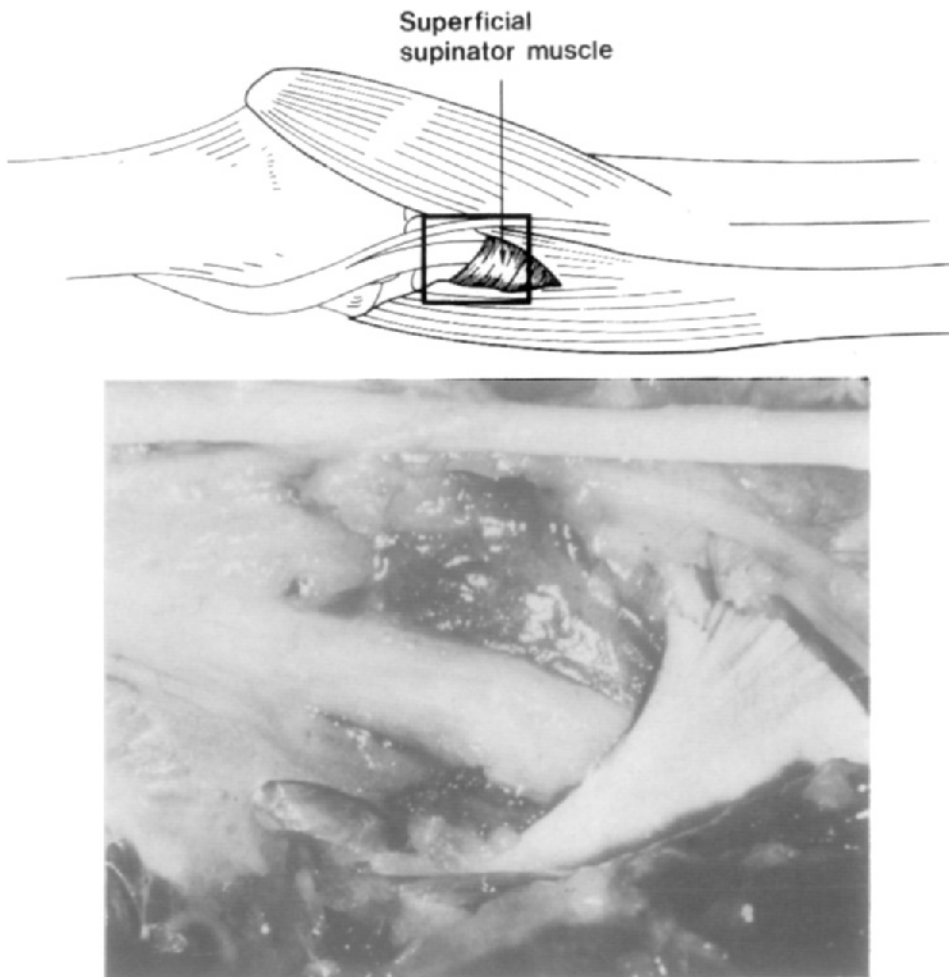


Fig. 7. Relation between the superficial supinator muscle and the nerve (Case 59). The posterior interosseous nerve passes under the edge of the superficial supinator muscle. This edge was fibrous at intersection with the nerve in 80 of the 90 cases. (The fascial extension from the extensor carpi radialis brevis muscle has been divided).

By passively pronating the forearm, thereby tensing the supinator, the nerve was observed to be compressed by the supinator edge in 83 cases (Fig. 8). In 78 of these cases the edge at intersection with the nerve was fibrous; in the remaining 5 it was recorded as membranous.

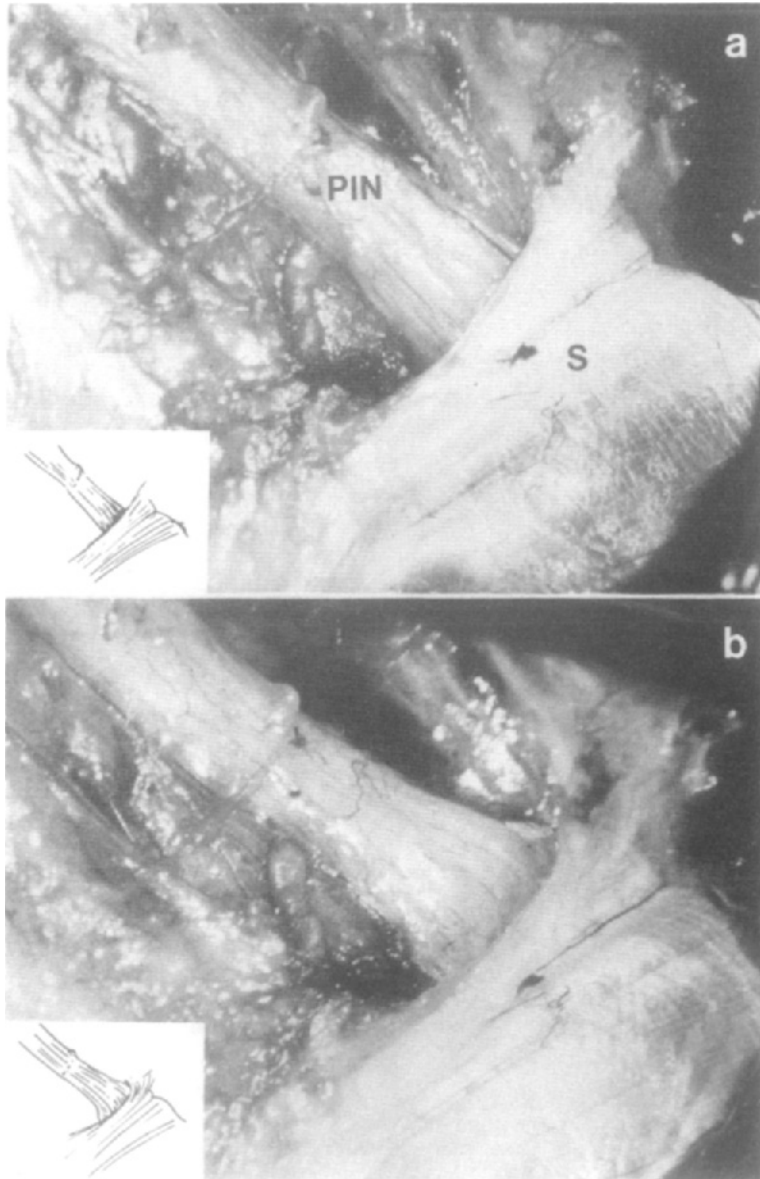


Fig. 8. Dynamic compression of the nerve by the supinator edge (Case 78). a) The posterior interosseous nerve (PIN) passes under a fibrous edge of the superficial supinator muscle (S). The forearm is in neutral position and the supinator is relaxed. No compression force is acting on the nerve. b) By passive pronation of the forearm the supinator is tensed and the edge compresses the nerve. Dynamic compression of the nerve was observed in 83 of the 90 cases.

After the supinator edge had been divided the nerve was inspected. In 74 of the 90 cases the nerve looked normal. In 16 cases there was an alteration of the nerve, i.e. an indentation often combined with some swelling proximally (Fig. 9 and 10). These nerve alterations were situated at or under the intersection between the supinator edge and the nerve.

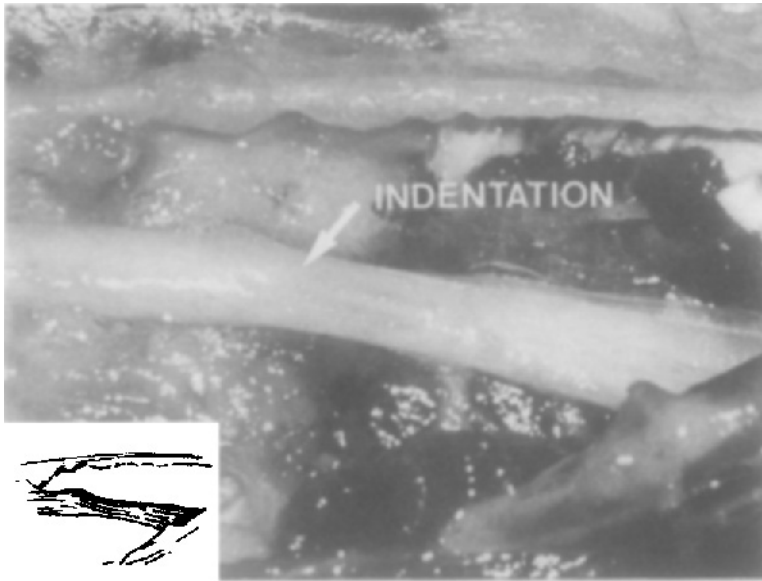


Fig. 9. Indentation of the nerve under the divided supinator edge (Case 71).

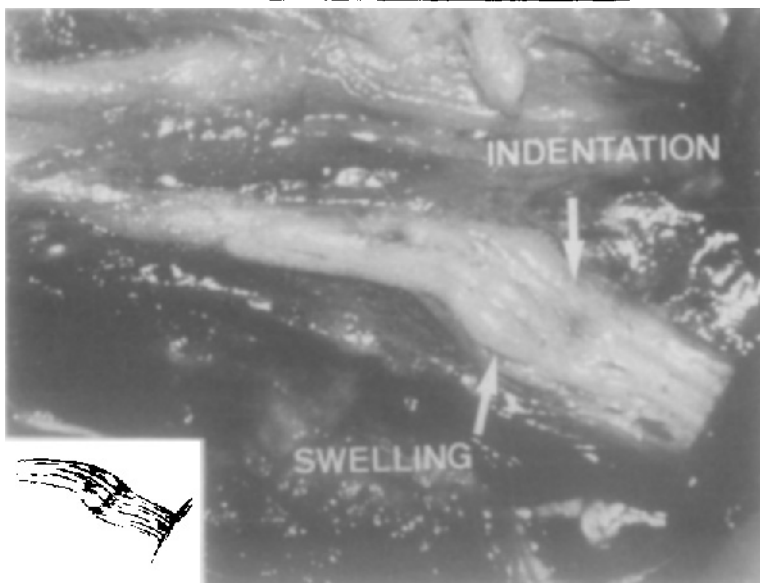


Fig. 10. Indentation of the nerve under the divided supinator edge (Case 62). Proximal to the indentation a swelling of the nerve can be seen.

3. POSTOPERATIVE OBSERVATIONS

Results of surgery (Table 2)

Although relief from pain at six weeks after surgery was reported in 34 cases, an accurate evaluation of the results of surgery was not considered meaningful before six months had elapsed and the patient had resumed work and had had an opportunity to use the operated arm under normal conditions. In most cases the improvement developed gradually (Fig. II). The results were classified as follows:

Excellent: Complete relief of pain.

Good: Occasional slight pain in connection with extra heavy work.

Fair: Improvement, essentially no pain at night and less pain at rest, discomfort at work on a more tolerable level.

Poor: No improvement.

The definitions are comparable with those used by Roles and Maudsley (1972) and Hagert et al. (1977). In practice the distinction between "excellent" and "good" was negligible and these two groups are therefore referred to as "good" in the subsequent text. The results 24 months postoperatively are referred to as the final results.

Table 2. Results of decompression of the posterior interosseous nerve

| | Months postoperatively | | |
|-----------|------------------------|----|----|
| | 6 | 12 | 24 |
| Excellent | 45 | 61 | 64 |
| Good | 15 | 9 | 9 |
| Fair | 16 | 7 | 7 |
| Poor | 14 | 13 | 10 |

Three cases (43, 66 and 75) were not examined two years postoperatively; at the one year control the results were good. These three patients wrote or telephoned that they were still free from pain after two years; the observations at the one year control were therefore recorded as unchanged at two years.

Those cases having achieved a good result after one year continued to be free from pain with one exception; Case 88 had a recurrence of pain following trauma.

The results were all good in the 14 cases selected from the three-year epicondylitis material. Good results were recorded one year postoperatively also in those two patients from the same material who were subjected to decompression at a later date (not included in the present series).

Bilateral decompressions were performed in five of the nine patients with bilateral symptoms and signs of entrapment initially and in addition in seven patients later on. In three patients (Case 7, 31 and 48) symptoms developed on the contralateral side 1-3 years after the first operation.

Clinical observations related to the results of surgery (Table 3, Fig. 11, 12 and 15)

The results of surgery were better when the epicondyle was not tender (27/29 v. 46/61, $p < 0.05$) and when there was no pain on resisted extension of the middle finger (22/23 v. 51/67, $p = 0.061$). There was no difference in results whether or not there was pain on resisted supination or pronation. Pain on supination and pronation was often combined with epicondylar tenderness but the results of surgery were better when pain on rotation was combined with a nontender epicondyle (22/23 v. 39/52, $p = 0.051$) (Fig. 12). Pain on resisted extension of the middle finger was related to epicondylar tenderness (57/61 v. 10/29, $p < 0.001$). There were equally good results when the middle finger test was negative as when a positive middle finger test was combined with a nontender epicondyle (22/23 v. 9/10) (Table 3 and Fig. 15).

Table 3. Clinical signs related to the final results

| Observations | | n | Results | | |
|---|---------|----|---------|------|------|
| | | | Good | Fair | Poor |
| Epicondylar tenderness | Intense | 35 | 25 | 3 | 7 |
| | Slight | 26 | 21 | 2 | 3 |
| | Absent | 29 | 27 | 2 | - |
| Tenderness over entrapment site | Intense | 90 | 73 | 7 | 10 |
| | Slight | - | - | - | - |
| | Absent | - | - | - | - |
| Pain on resisted supination | Intense | 51 | 41 | 2 | 8 |
| | Slight | 33 | 27 | 4 | 2 |
| | Absent | 6 | 5 | 1 | - |
| Pain on resisted pronation | Intense | 41 | 30 | 4 | 7 |
| | Slight | 36 | 33 | 2 | 1 |
| | Absent | 13 | 10 | 1 | 2 |
| Pain on resisted extension of the middle finger | Present | 67 | 51 | 6 | 10 |
| | Absent | 23 | 22 | 1 | - |

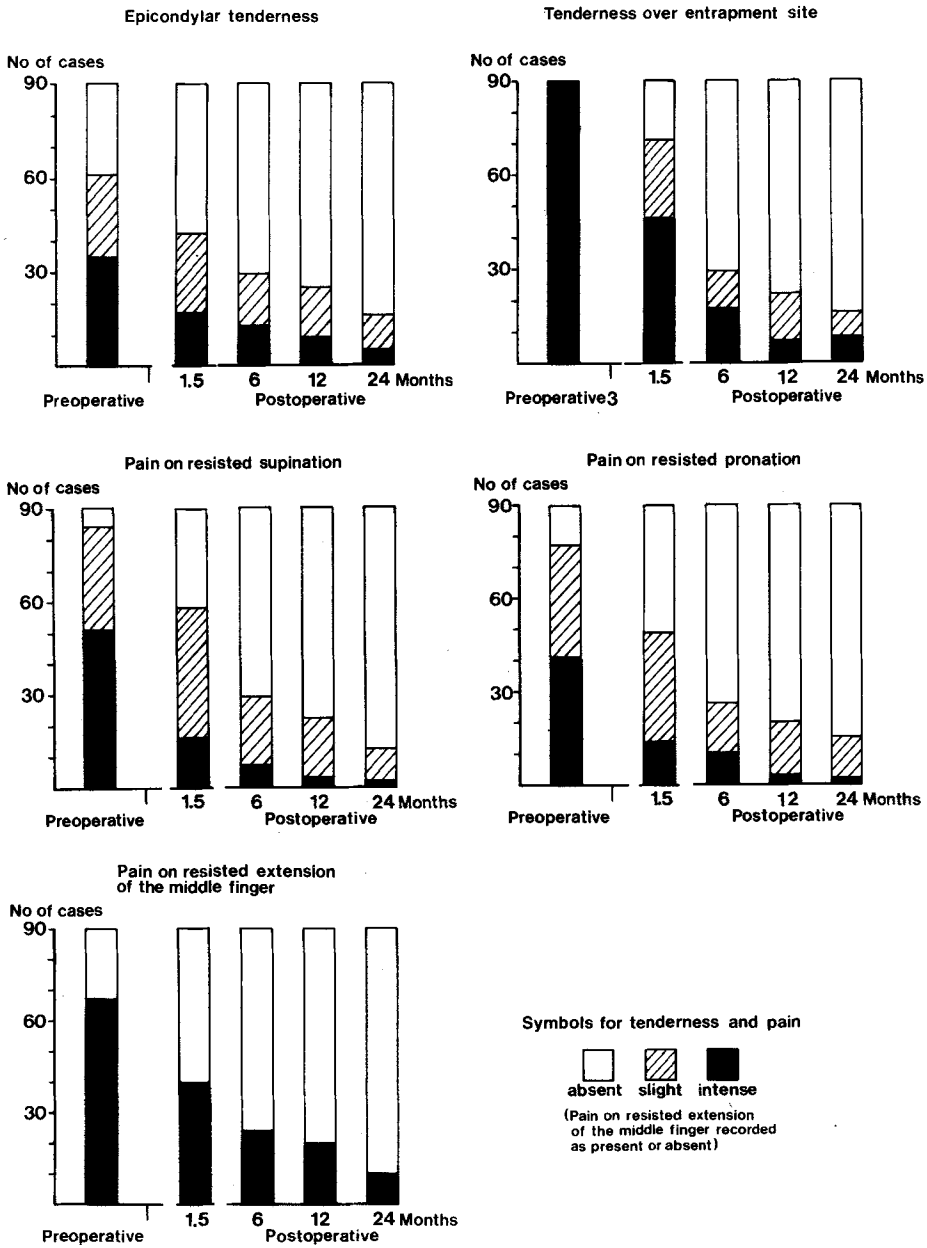


Fig. II. Clinical signs before and after decompression of the posterior interosseous nerve.

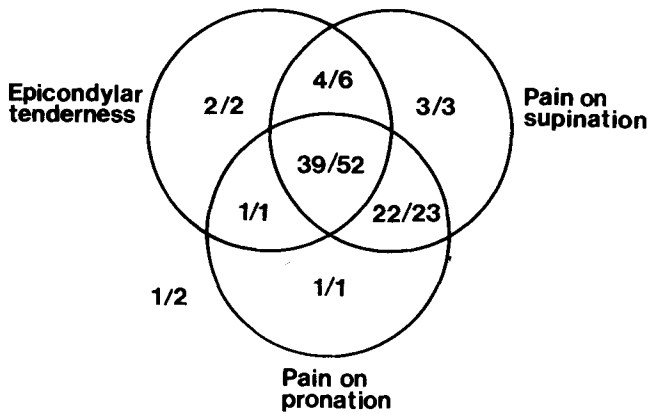


Fig. 12. Results of decompression in relation to clinical signs.

The results were better when pain on rotation was combined with a nontender epicondyle. Number of good final results as numerator, number of observations as denominator.

Good results were related to increased grip strength (Fig. 13). 24 months postoperatively 64 of the 81 cases tested had values within normal ± 2 S D compared with only 22 preoperatively.

A similar relationship between normalisation of grip strength and good results was observed when the dominant/non dominant hand value was measured (Fig. 14).

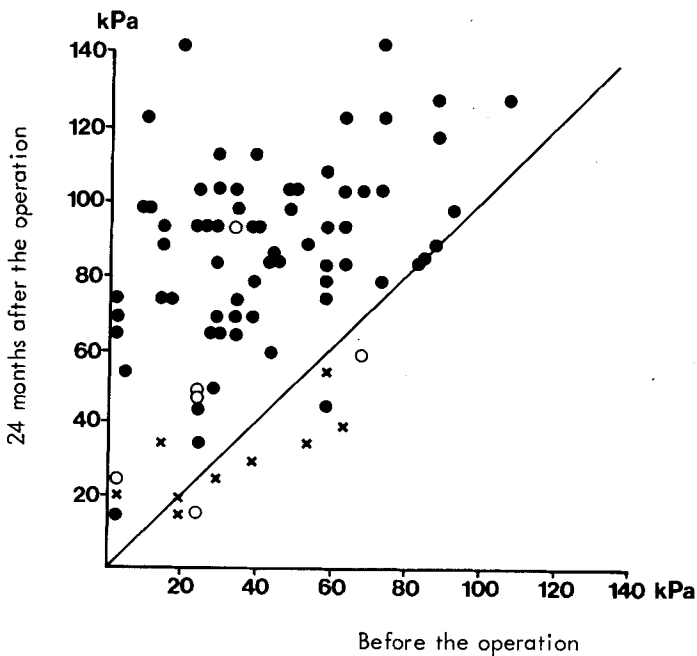


Fig. 13. Effect of decompression on grip strength. The grip strength was measured by the method described by Thorngren and Werner (1979) and expressed as kilo pascal. The symbols refer to the final result of the operation: symbols ● = good ○ = fair X = poor.

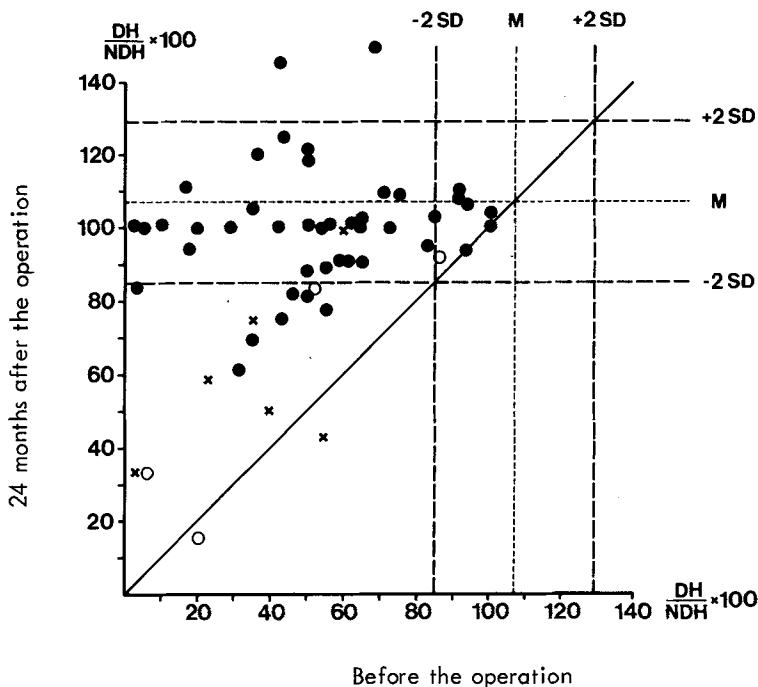


Fig. 14. Effect of decompression on grip strength in patients operated on the dominant side only. The normal value for grip strength of the dominant/non dominant hand $\times 100$ was found to be 107 ± 11 by Thorngren and Werner (1979); this value has been indicated in the graph ± 2 S D. The symbols are the same as those used in Fig. 13 and refer to the final results of the operation as being good, fair or poor.

Complications

Wound infection did not occur in this series. Motor weakness did not occur following the primary operations but did occur in 6 of the 15 re-operations. All recovered within 4-8 weeks.

Further surgical treatment during the follow-up

(1) Re-operations (Table 4)

Re-operations were performed in 15 cases, two patients were re-operated bilaterally.

(a) In six cases there was a recurrence, one patient had two recurrences (Case 56), after 8 ± 3 months during which time the patients had resumed full-time work. One of the recurrences occurred following trauma (Case 88); in the others no such explanation was found. The recurrence following trauma occurred in a 25-year-old woman where the result of decompression was good at the one year control. Some weeks later she sustained a heavy blow over the operated area following which she developed continuous pain.

Neurophysiological investigation which had been performed before the first operation was repeated after the recurrence but the findings on both occasions were considered normal. Having tried conservative treatment without success she was re-operated three months later. No explanation for the recurrence was observed at surgery and she then made a full recovery. In the other cases adhesions and scar tissue surrounding the nerve were found. After neurolysis the nerve was covered with subcutaneous fat. Five of the six cases, re-explored because of recurrence, improved fully.

(b) Re-operations were performed 8 ± 3 months after the initial operation in nine cases, that had not improved. The nerve was released from adhesions and covered with subcutaneous fat; two of the nine cases improved fully.

Table 4. Results of re-operations 12 months postoperatively

| Cause of re-operation | n | Final results | | |
|-----------------------|----|---------------|------|------|
| | | Good | Fair | Poor |
| Recurrence | 6 | 5 | - | 1 |
| No improvement | 9 | 2 | 1 | 6 |
| n | 15 | 7 | 1 | 7 |

(2) Operations for lateral epicondylitis

Surgery for lateral epicondylitis was performed in nine cases using the Hohman (1936) procedure 11 ± 4 months after decompression of the posterior interosseous nerve. In four cases the symptoms and signs had changed and there was pain only at work and tenderness over the epicondyle but not over the nerve as previously. There was complete relief from pain following this surgery in three of these cases.

In five cases there was tenderness over the epicondyle as well as over the nerve; the maximal tenderness was situated over the epicondyle. There was no definite relief from pain following this further surgery in four of these cases.

(3) Operations for other nerve entrapments

Three operations for a carpal tunnel syndrome (Case 42, 49 and 52) and two for a pronator syndrome (Case 4 and 79) were performed 2-3 years after decompression of the posterior interosseous nerve on the same side. At the time of this surgery the results of the former operation were good in four and fair in one case. Neurophysiological examinations did not confirm the diagnosis but the symptoms and signs were convincing. The results were good in four cases; in one of the pronator syndromes (Case 79) the result was considered fair six months postoperatively.

Effect of placing fat over the decompressed nerve

No recurrences, apart from the one following trauma (Case 88), occurred after fat was regularly used to cover the decompressed nerve at the primary operations (last 25 cases), which might suggest that this procedure was of value in preventing the development of adhesions that might cause compression of the nerve. At re-operation in Case 88 the fat pad was found to be in the same location where it was placed during the primary operation. This fat pad was covered by a thin fibrous sheet.

It was easy to dissect the fat free from the nerve. Histological examination of this fat pad compared with subcutaneous fat from the same patient showed only slight changes with somewhat broader fibrous septa. In the other re-operated cases, where fat to cover the explored nerve was not used initially, adhesions that might have caused compression were observed around the nerve. In the patient where recurrences occurred twice (Case 56), fat to cover the released nerve was used at the first re-operation. At the second re-operation a thin adherence was found at the proximal intersection between the nerve and the fat pad but there was no obvious sign of nerve compression. The nerve was dissected free and a new fat pad placed in position, following which the patient recovered fully.

4. OBSERVATIONS AT SURGERY RELATED TO RESULTS OF SURGERY

(a) The extensor carpi radialis brevis muscle (Table 5)

Pain on resisted extension of the middle finger was reported by Kopell and Thompson (1963) and Roles and Maudsley (1972) to be a sign of entrapment of the posterior interosseous nerve. The nerve was supposed to be compressed by a fascial extension from the extensor carpi radialis brevis muscle during this manoeuvre.

In the present investigation there was no relation between preoperative pain on extension of the middle finger and observations of a fascial extension or arch from the extensor carpi radialis brevis crossing the nerve. In 39 of 67 cases where the middle finger test was positive there was an extension compared with the 15 of 23 cases where the test was negative (Fig. 15). Convincing compression of the nerve by this extension, if present, on passive rotation of the forearm or wrist flexion was not observed and there were no nerve alterations observed at or under it. There was no difference in results after decompression whether or not the nerve was crossed by the extensor carpi radialis brevis.

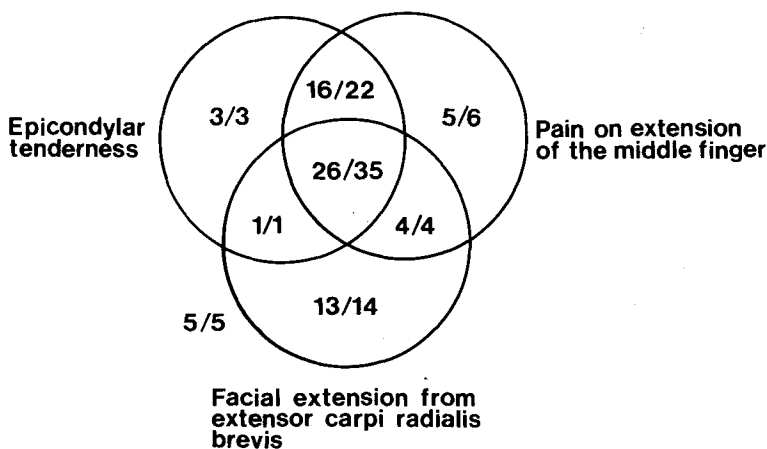


Fig. 15. Results of decompression in relation to clinical signs and anatomy. Pain on resisted extension of the middle finger was related to epicondylar tenderness rather than to the presence of a fascial extension from the extensor carpi radialis brevis muscle crossing the posterior interosseous nerve. Number of good final results as numerator, number of observations as denominator.

Table 5. The extensor carpi radialis brevis muscle (ECRB) in relation to the nerve related to the final results.

| Fascial extension from ECRB crossing the nerve | n | Results | | |
|--|----|---------|------|------|
| | | Good | Fair | Poor |
| Absent | 36 | 29 | 3 | 4 |
| Present | 54 | 44 | 4 | 6 |
| n | 90 | 73 | 7 | 10 |

(b) The superficial supinator muscle (Table 6)

When the edge of the superficial supinator muscle was fibrous at intersection with the nerve the results after decompression were better ($p < 0.001$) than when the edge was not fibrous, i.e. muscular or translucent membranous.

Table 6. The edge of the superficial supinator at intersection with the posterior interosseous nerve related to the final results.

| Supinator edge | n | Results | | |
|----------------|----|---------|------|------|
| | | Good | Fair | Poor |
| Not fibrous | 10 | 3 | 1 | 6 |
| Fibrous | 80 | 70 | 6 | 4 |
| n | 90 | 73 | 7 | 10 |

(c) The posterior interosseous nerve (Table 7)

Compression of the nerve on passive pronation of the forearm, thereby passively tensing the supinator, was related to a well developed fibrous edge on the superficial supinator. When the nerve had a normal appearance the results of surgery were better where the nerve was squeezed by the edge of the superficial supinator on passive pronation of the forearm than where it was not ($p < 0.001$). Where nerve alterations, as indentations of the nerve, were observed the results of surgery were less favourable ($p < 0.05$).

Table 7. Dynamic compression and appearance of the nerve at the intersection with the supinator edge related to the final results.

| Compression | Appearance | n | Supinator edge | | Results | | |
|-------------|------------|----|----------------|---------|---------|------|------|
| | | | Not fibrous | Fibrous | Good | Fair | Poor |
| No | Normal | 7 | 5 | 2 | - | 3 | 4 |
| Yes | Normal | 67 | 4 | 63 | 62 | 2 | 3 |
| Yes | Alteration | 16 | 1 | 15 | 11 | 2 | 3 |
| n | | 90 | 10 | 80 | 73 | 7 | 10 |

In conclusion the best results of decompression were obtained where the nerve looked normal and dynamic compression by the edge of the superficial supinator muscle occurred on passive pronation of the forearm.

5. NEUROPHYSIOLOGICAL OBSERVATIONS (Appendix I).

(a) Preoperative observations

The neurophysiological examinations performed in 25 of the 90 cases operated showed:

(1) In 13 cases the motor conduction velocity in the radial nerve across the supinator muscle was slow, below -S D as compared with normal values 65.8 ± 5.9 m/sec (Rosén and Werner, in manuscript).

(2) In 8 cases there was a slight increase in the size of the motor unit potentials in the extensor digitorum communis and extensor indicis proprius muscles which are innervated by the posterior interosseous nerve distal to the suspected entrapment site. In one case similar findings were noted in the extensor carpi radialis longus but not in the brachioradialis muscles. In 3 cases EMG recordings from the muscles innervated proximal to the suspected entrapment site could not be performed because of severe pain reactions; positive EMG findings were recorded from the extensor digitorum communis and the extensor indicis proprius muscles in one of these. In the remainder the motor unit potentials from the muscles innervated proximal to the entrapment site were normal. Denervation activity was not observed in any case.

(b) Relation to occurrence of nerve alterations

In 4 of the 25 cases examined obvious nerve alterations were observed. In 3 of these 4 cases the conduction velocity was slow; in one case electromyography showed in addition slight changes of motor unit potentials in muscles innervated distal to the supinator muscle.

(c) Relation to results of surgery

Good results were achieved in 11 of the 13 cases where the neurophysiological examinations showed some decrease of motor conduction velocity and in 7 of the 8 cases where the EMG recordings from distal forearm muscles showed slight changes in motor unit potentials. Good results were, however, also achieved in 7 of 8 cases where the neurophysiological examination was considered normal.

(d) Postoperative observations

There was a decrease (≥ 5 m/sec) of conduction velocity in 2 of the 12 cases that were re-examined one year postoperatively. In Case 12 the result of surgery was poor; in Case 85 it was good.

In another 3 cases the conduction velocity had increased (≥ 5 m/sec); in the remainder there was no definite change. The results of surgery were good in 9 of these 10 cases.

6. AUTOPSY OBSERVATIONS

In those 30 individuals where bilateral dissections were performed the topographical anatomy was identical on both sides except in two individuals where the extensor carpi radialis brevis had a fascial extension that crossed the posterior interosseous nerve in the right arm but not in the left. In another six individuals the edge of the superficial supinator at intersection with the nerve was slightly more fibrous in the right arm than in the left. Since there were no main differences between the two sides the observations concerning the right arm only are referred to in the subsequent text.

The distance from the tip of the lateral epicondyle to the intersection between the posterior interosseous nerve and the proximal edge of the supinator muscle was 4.7 ± 0.5 cm. In two thirds of the arms there was a fascial extension from the extensor carpi radialis brevis muscle crossing the nerve and equally often the edge of the superficial supinator was fibrous at intersection with the nerve (Table 8).

Compression of the nerve by the supinator edge on passive pronation of the arm, often observed at surgery, could only occasionally be demonstrated. This probably depended on post mortem rigidity.

In 58 of the 60 individuals the nerve had a normal appearance. In one individual a nerve alteration was observed bilaterally; there was an indentation under the supinator edge and a swelling proximally (Fig. 16). Microscopical examination of the nerve alteration from the right arm in this individual, shown in Fig. 17 and 18, revealed an elongated area of loosening in which the myelinated fibres were separated and partly replaced by connective tissue. There was an increase in both collagenous fibrils and fibroblasts and also in Schwann cells. There were a few macrophages but no inflammatory cells. The epineurium showed only a slight fibrous thickening.

A slight indentation of the nerve under the supinator edge was observed bilaterally in another individual and similar though less pronounced microscopical changes were observed.

Except for a questionable fibrous thickening of the epineurium there were no microscopical alterations in the ten nerves where the gross appearance was considered normal.

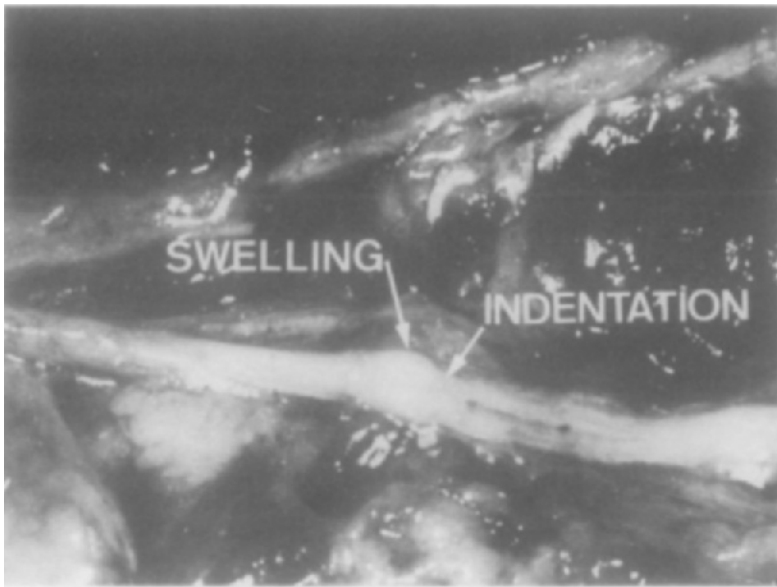


Fig. 16. Nerve alteration of the posterior interosseous nerve observed at autopsy. Proximal to the indentation, situated at intersection with the edge of the superficial supinator (divided), there is a swelling of the nerve. The microscopic appearance is shown in Fig. 17 and 18.

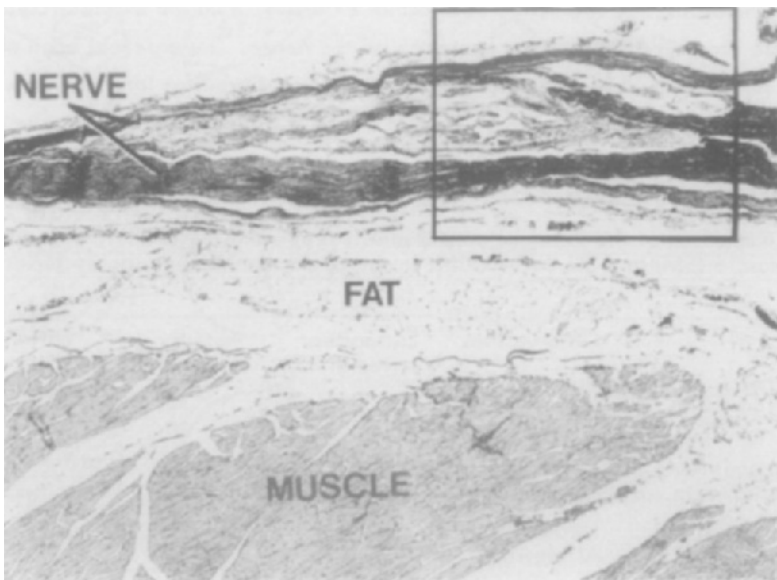


Fig. 17. Microscopic appearance of the nerve alteration shown in Fig. 16. Longitudinal section of the nerve that rests on a fascia under which there is fat and muscle tissue. There is a longitudinal split in the nerve with a thin fascicle toward the surface of the preparation. The cavity is partly filled with mesenchymal tissue. Haematoxylin-Eosin x 25.

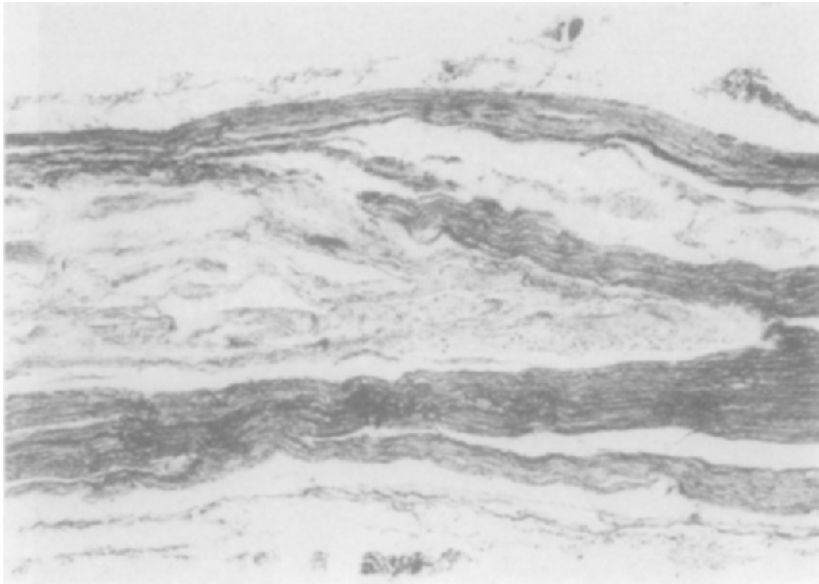


Fig. 18. Enlargement of upper right section of Fig. 17. Haematoxylin-Eosin x 65.

A comparison between the anatomy in the entrapment and autopsy series showed no difference concerning the incidence of a fascial extension from the extensor carpi radialis brevis muscle crossing and in direct contact with the nerve. The proximal edge of the superficial supinator muscle was significantly more often fibrous at intersection with the nerve in the entrapment series. There was also a higher incidence of gross nerve alterations in the entrapment series (Table 8).

Table 8. Comparison of the extensor carpi radialis brevis muscle (ECRB), the superficial supinator muscle (SM) and the nerve (PIN) in the entrapment* and autopsy series.

| | Observations | Entrapment series (n 85) | Autopsy series (n 60) | Difference |
|-------------------------------------|--------------|--------------------------|-----------------------|------------|
| Extension from ECRB crossing PIN | Absent | 34 | 20 | |
| | Present | 51 | 40 | (-) |
| Edge of SM at intersection with PIN | Not fibrous | 9 | 21 | |
| | Fibrous | 76 | 39 | xxx |
| Appearance of PIN | Normal | 71 | 58 | |
| | Alteration | 14 | 2 | x |

* Observations in the entrapment series accounts for the primary operated arm in patients operated bilaterally.

7. COMPARISON OF EPIDEMIOLOGY AND SYMPTOMATOLOGY IN THE ENTRAPMENT AND LATERAL EPICONDYLITIS SERIES

Most patients were between 35 and 60 years old with a slight overrepresentation of females in both series. The females in the entrapment series were younger compared with the males in the entrapment series and the females in the epicondylitis series.

Occupation and symptoms (Fig. 19).

As many different occupations were represented in both series the patients were questioned as to their own opinion regarding their type of work, occurrence of rotatory movements at work and relationship between work and symptoms. There was some overrepresentation of heavy work and a great overrepresentation of much rotatory movements in the entrapment series. A considerable number of patients in both series felt that there was a relation between their work and symptoms and some had already changed their occupation because of symptoms; the incidence was higher in the entrapment series.

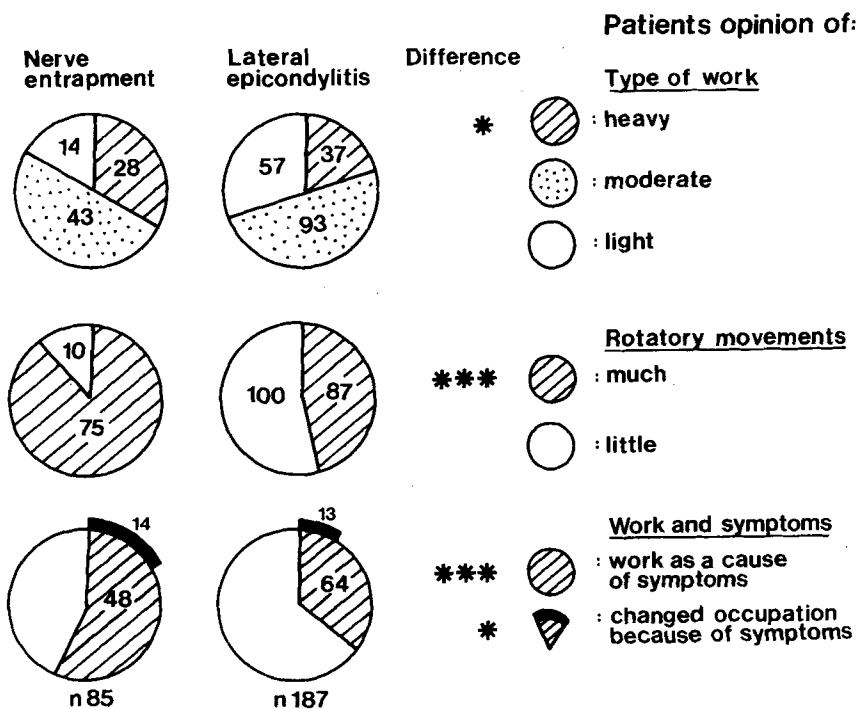


Fig. 19. Comparison of work in the entrapment and lateral epicondylitis series.

Pain characteristics and previous therapy (Table 9)

All patients in the entrapment series complained of pain at work as well as at rest after exertion and the majority also had pain at night often disturbing sleep. One fourth of the patients in the epicondylitis series reported previous or present pain not only at work but also at rest and a few had pain also at night.

Local steroid injections had been given to 68 of the 73 patients in the entrapment series who were previously treated for lateral epicondylitis, mean 6 ± 5 injections; some improvement from the injections was reported by 12 patients only. In comparison 173 patients in the epicondylitis series had been treated similarly, mean 3 ± 2 injections; good and lasting effect from the injections was reported by 61 patients and improvement by 72.

Fourteen patients in the entrapment series and 17 in the epicondylitis series, with a pre-operative duration of symptoms of one year or more, were previously operated for lateral epicondylitis; one patient in the latter series bilaterally. All operations in the entrapment series and 13 in the epicondylitis series were performed by the Hohman (1933) procedure; in 5 cases in the latter series the method described by Garden (1961) had been used.

Ten operations for other nerve entrapments in the upper extremity were previously performed on 8 patients in the entrapment series. In all but one case the previous operations were carried out on the same arm as was later operated on for posterior interosseous nerve entrapment.

In the epicondylitis series 3 patients were previously operated for nerve entrapments.

In conclusion the patients in the entrapment series had a higher incidence of rotatory movements at work, their pain characteristics were more severe and there was a high incidence of previous surgery for other nerve entrapments usually in the same arm where decompression of the posterior interosseous nerve was later performed.

Table 9. Comparison of pain characteristics and previous therapy in the entrapment and lateral epicondylitis series.

| Compared data | Series | | Difference |
|--|----------------------|--------------------------|------------|
| | Entrapment (n 85) | Epicondylitis (n 187) | |
| <u>Pain characteristics</u> | | | |
| Pain at work | 85 | 187 | (-) |
| Also at rest | 85 | 47 | xxx |
| Also at night | 61 | 12 | xxx |
| <u>Previous therapy</u> | | | |
| <u>I For lateral epicondylitis</u> | | | |
| a. Local steroid injections | | | |
| Patients treated | 68 | 173 | |
| Elbows treated | 71 | 194 | |
| Mean number of injections/elbows treated | 6 ± 5 | 3 ± 3 | xxx |
| Range of injections | 1-25 | 1-20 | |
| Unsatisfactory results/patients | 56 | 40 | xxx |
| b. Surgery in cases with duration of symptoms > 1 year | | | |
| Number of operations | 14 | 18 | x |
| Unsatisfactory results | 14 | 5 | xxx |
| <u>II Surgery for other nerve entrapments</u> | | | |
| Operated patients | 8 | 3 | xx |
| Number of operations | 10 | 3 | xxx |
| Carpal tunnel syndrome | 5 | 1 | xx |
| Cubital tunnel syndrome | 5 | 2 | x |

DISCUSSION

Peripheral entrapment neuropathies are mostly seen in the upper extremity; the carpal tunnel syndrome and the cubital tunnel syndrome being the most frequent and best known. Anatomical factors such as narrow passages through fibrous or osseofibrous tunnels, fibrous or muscular bands, where a nerve can be subjected to mechanical irritation predispose entrapment (Kopell and Thompson 1963).

The possibility that entrapment of the posterior interosseous nerve could be the cause of lateral elbow pain has recently been supported by Roles and Maudsley (1972) and Hagert et al. (1977).

In planning the present investigation, the criteria for selecting the patient material were mainly based on the concepts of entrapment neuropathies by Kopell and Thompson (1963). Like the series of Roles and Maudsley (1972) and Hagert et al. (1977) there was a slight overrepresentation of females. In comparison, the carpal tunnel syndrome is far more common in females (Phalen 1966, 1972, Hybbinette and Mannerfelt 1975) and in the cubital tunnel syndrome there is an overrepresentation of males (Hagström 1977, Lugnegård et al. 1977, Thomsen 1977).

Effect of entrapment

The effect of entrapment varies depending on the type of nerve engaged and on the degree of compression. Entrapment of a predominantly sensory nerve such as the median nerve in the carpal tunnel may, besides pain, also cause paresthesia and cutaneous sensory loss. Entrapment of a predominantly motor nerve may cause paralysis. In non-paretic cases entrapment of a motor nerve may cause diffusely localized dull aching pain (Kopell and Thompson 1963). Motor nerves contain not only larger efferent fibres which are myelinated but also many thin myelinated and non-myelinated afferent fibres of muscular and extramuscular origin (Matthews 1972). Many of these fibres are nociceptive and are presumably responsible for the intense pain observed in the present series.

Depending on the degree of compression, entrapment of the posterior interosseous nerve may cause pain or paralysis (Hagert et al. 1977, Lister 1977). Compression causing paralysis of the distally innervated muscles has been reported in several papers. Lipomas are the most common cause of compression but fibrous bands, often confined to the supinator edge, have also been reported (Goldman et al. 1969, Bronisch 1971, Bryan et al. 1971, Comtet et Chambaud 1975, Overgaard Nielsen 1976, DeZanche et al. 1978). In several cases of posterior interosseous nerve paralysis, pain in the proximal forearm preceding paralysis and/or local tenderness over the nerve has been reported (Guillain and

Courtellemont 1905, Woltman and Learmonth 1934, Hobhouse and Held 1936, Weinberger 1939, Richmond 1953, Campbell and Wulf 1954, Kruse 1958, Whiteley and Alpers 1959, Bowen and Stone 1966, Mulholland 1966, Sharrard 1966, Marmor et al. 1967, Bronisch 1971, Löser et al. 1972, Millender et al. 1973, Comtet and Chambaud 1975, Benini and DiMartino 1976, Overgaard Nielsen 1976). Personal experience of five cases of posterior interosseous nerve paralysis revealed a lipoma squeezing the nerve from below upwards towards the superficial supinator edge in four and a neurofibroma in one. In four of these cases there was a history of pain at rest. The nerve was tender in four cases at the same site as in the arms operated on in the present series. The epicondyle was not tender in any of the cases but pain could be elicited on active supination against resistance in three.

There is, thus, some evidence that similar symptoms and signs as well as location of entrapment as in the present series may be found in cases where compression of the posterior interosseous nerve caused paralysis.

Entrapment diathesis

"It would not be surprising to find a patient with not only median and ulnar nerve entrapment, but also with simultaneous radial nerve involvement" (Spinner and Spencer 1974). Buchthal et al. (1974) found clinical and electrophysiological evidence of ulnar nerve entrapment at the elbow in 18 of 117 patients with carpal tunnel syndrome. It has been reported that compression of proximal nerve roots may increase the sensitivity to peripheral nerve entrapments (Upton and McComas 1973).

The higher incidence of previous surgery for other nerve entrapments in the entrapment series compared with the epicondylitis series was unexpected. The question arises if the diagnoses had been misinterpreted in the cases where previous surgery for other entrapments had been performed as they in all but one case were confined to the same arm where decompression of the posterior interosseous nerve was later carried out. The symptoms of the carpal and cubital tunnel syndrome are, however, well known and not located at the lateral side of the elbow so a misinterpretation of the diagnosis does not seem probable. Perhaps there may be a general diathesis for entrapment neuropathies in some persons.

During the follow-up, surgery for other nerve entrapments was performed in five patients in the entrapment series. At the time for this further surgery four of the five patients were free and one partially free from the pain for which decompression of the posterior interosseous nerve had been performed. In comparison, no patient in the epicondylitis series was operated on for an entrapment disorder during the follow-up period. Electrophysiological examinations were interpreted as normal in the three cases later

operated on for a carpal tunnel syndrome as well as in the two for a pronator syndrome. Sensory nerve conduction velocity is claimed to be highly sensitive in carpal tunnel syndromes (Buchthal et al. 1974) but a normal finding does not rule out the diagnosis (Spinner and Spencer 1974, Lister 1977). Because electrophysiology did not confirm the diagnosis of carpal tunnel syndrome, the operations were delayed at least six months. Since the symptoms progressed, the patients requested surgery and postoperatively they all experienced relief from pain and paresthesia. In the pronator syndrome electrophysiological examinations may aid in the diagnosis but normal findings should not deter from exploration (Spinner 1972). This is in agreement with observations in other cases of this disorder where preoperative conduction velocities were found to be normal in resting position of the arm but sometimes, ^{Lakewicz} increased during active maximal pronation of the forearm (Rosén and Werner, unpublished data).

Entrapment neuropathies, especially the carpal tunnel syndrome, may be found in connection with systemic diseases such as diabetes mellitus and rheumatoid arthritis. There are a few cases of posterior interosseous nerve paresis reported in connection with rheumatoid arthritis (Marmor et al. 1967, Chang et al. 1972, Millender et al. 1973, Marshall and Murray 1974). In the present series one patient had rheumatoid disease, but systemic diseases were not found among the others.

Tennis elbow and entrapment

As opinions are varied concerning the pathogenesis of tennis elbow pain, various surgical procedures have been tried in cases not responding to conservative treatment (Hohman 1933, Garden 1961, Goldie 1964, Bosworth 1965, Gardner 1970, Boyd and McLeod 1973 and others).

Good results from decompression of the posterior interosseous nerve in resistant tennis elbow were reported in 5 of 10 cases by Capener (1966) in 35 of 38 by Roles and Maudsley (1972), and in 20 of 21 by Dewey (1973). As Narakas (1974) combined nerve decompression with local surgery for epicondylitis, an evaluation of the role of entrapment in his series is not possible. Hagert et al. (1977) regarded epicondylitis and posterior interosseous nerve entrapment as "two different disorders, which have nothing to do with each other, and which should therefore not be mixed up".

The selecting criteria in the present series were chosen with regard to entrapment as the probable cause of pain and no consideration was given to coexisting signs of epicondylar tenderness. In 73 of 85 patients, the symptoms had previously been interpreted as epicondylitis, resistant to different modes of conservative treatment, including surgery in 14 cases. It was, however, not possible to claim that the diagnoses were altogether

misinterpreted, as a tender epicondyle is the main sign of epicondylitis. On the other hand, there was no convincing evidence that epicondylitis could be cured by decompression of the posterior interosseous nerve. Roles and Maudsley (1972) reported relief of epicondylar tenderness within a few days after decompression. In the present series the results of surgery were better in cases where the epicondyle was not tender preoperatively which supports the statement of Hagert et al. (1977) that epicondylitis and posterior interosseous nerve entrapment are different disorders. To distinguish between the two conditions may however not always be easy.

Fourteen patients in the entrapment series were selected from a material of 203 patients treated at our department for lateral epicondylitis 1972-1974. All fourteen fully recovered after decompression of the posterior interosseous nerve. An additional two patients from this material were subjected to decompression at a later date. The results were good one year postoperatively.

Based on the number of patients requiring decompression, the approximate incidence of entrapment in this epicondylitis material was calculated as 8 per cent. These entrapment cases were selected from the 58 patients of totally 203 who requested a new examination because of pain and the calculated figure is thus rough and may be discussed. In estimating the incidence of entrapment in an average patient material of tennis elbow one has to consider that patients with this disorder were also treated by general practitioners and surgeons outside our department during 1972-1974. An approximate incidence of posterior interosseous nerve entrapment in the tennis elbow syndrome might therefore be around 5 per cent.

Occupation and entrapment

Overexertion on pronation and supination may produce tennis elbow pain (Goldie 1964, Capener 1966, Gardner 1970, Priest 1976).

The type of occupation seemed important in the present entrapment series. Most patients reported much rotatory movement at work and the incidence was significantly higher compared with that in the epicondylitis series. Occupations entailing repetitive pronation and supination were also reported by Roles and Maudsley (1972) and Hagert et al. (1977). Similar occupational movements have been considered important to elicit the symptoms of the pronator syndrome (Solnitzky 1960, Morris and Peters 1976) a disorder that in many ways may be compared with posterior interosseous nerve entrapment. Also in the carpal tunnel syndrome, strenuous use of the hand may aggravate the symptoms (Tanzer 1959, Phalen 1966, 1972, Birkbeck and Beer 1975).

More than half of the patients in the entrapment series and one third of those

in the epicondylitis series considered that there was a relationship between their occupation and symptoms. It seems probable that rotatory forearm strain can elicit both conditions. Epicondylitis and posterior interosseous nerve entrapment causing pain might therefore occur in the same arm as was suggested by Hagert et al. (1977).

Bilaterality

Bilateral decompressions were performed in five patients and in an additional seven at a later stage. The dissection study showed equal findings pertaining to the topographical anatomy on both sides. Similar observations of almost identical anatomy bilaterally have been reported concerning the topographical anatomy where the median nerve passes through the pronator teres muscle at the elbow (Beaton and Anson 1939). Assuming local anatomy to be equal bilaterally and important in peripheral nerve entrapments, symptoms from both sides are to be expected in some patients. Work load can explain that the dominant hand side was mostly involved in the present series as well as in the series of Roles and Maudsley (1972) and Hagert et al. (1977). A similar overrepresentation of symptoms from the dominant hand side and also frequent bilateral symptoms are reported in the carpal tunnel syndrome (Phalen 1966, 1972, Hybbinette and Mannerfelt 1975). In the cubital tunnel syndrome there is a less pronounced overrepresentation of symptoms from the dominant side and the condition is only occasionally bilateral (Hagström 1977, Thomsen 1977).

Pain characteristics

By definition all patients in the entrapment series had pain at rest, brought on by work, and the incidence of pain after exertion was significantly higher compared with that in the epicondylitis series. Similar pain characteristics, aching pain in the forearm that increased during work and then continued afterwards, have been reported in the pronator syndrome (Seyffarth 1951).

Pain at night was reported by Hagert et al. (1977). Most of their patients woke early in the morning because of pain. In the present investigation, pain at night was interpreted as protracted pain at rest. Pain is not unusual in ulnar nerve entrapment at the elbow (Hagström 1977, Lugnegård et al. 1977) and characteristic in the pronator syndrome (Seyffarth 1951, Solnitzky 1960, Morris and Peters 1976) but nocturnal pain or discomfort, characteristic of the carpal tunnel syndrome, is rare in these disorders. Different pain characteristics in different entrapment disorders may be due to different entrapment mechanisms. Mechanical as well as ischemic factors are considered important in producing the lesions in nerve compression, for reviews see Gilliat (1975) and Lundborg (1975). Sunderland (1976), who discussed the different opinions, using the carpal tunnel

syndrome as a model, stated that "those who seek a common pathogenesis for all compression lesions will search in vain, unless, of course, their efforts are directed at the molecular level".

Radiating pain is a common symptom in nerve entrapments (Kopell and Thompson 1963, Lister 1977). Roles and Maudsley (1972) and Hagert et al. (1977) reported radiating pain and in the present series all patients complained of distal, and some also of proximal, radiating pain. This symptom, however, may occur in epicondylitis (Goldie 1964, Tupper 1971, Lister 1977) and a history of radiating pain may therefore be a clue to the entrapment diagnosis but does not exclude the possibility of epicondylitis.

Nerve tenderness at the entrapment site is often found in peripheral entrapment neuropathies (Kopell and Thompson 1963). "La douleur de l'irritation névritique est presque toujours une douleur locale perçue au point même où s'exerce la pression sur la nerf." (Tinel 1915). Tenderness over the entrapment site has been reported in the pronator syndrome (Seyffarth 1951, Morris and Peters 1976), in ulnar nerve entrapments at the elbow (Hagström 1977, Thomsen 1977), and may be present in the carpal tunnel syndrome (Phalen 1966). It was considered an important sign by Roles and Maudsley (1972) and Hagert et al. (1977) in posterior interosseous nerve entrapment.

Local nerve tenderness over the suspected entrapment site was used as a qualifying criterion in the present investigation. The exact mechanism of sensitization of the pain afferents is unknown. One possible explanation is that there is an increased activation of pain afferents at the entrapment site due to iterated mechanical nerve irritation. Another explanation is local intraneural sprouting due to compression injury (Spinner and Spencer 1974). A further possible explanation is that there is a transient mechanical blockade of large myelinated afferents that normally counteract the effects of the pain afferents (Melzack and Wall 1965). A study by Rosén and Werner (in manuscript) supports the notion that transient blocking of large myelinated nerve fibres may occur in the posterior interosseous nerve during active supination.

The forearm extensors may be tender in epicondylitis but maximal tenderness is located over the epicondyle (Goldie 1964). Local nerve tenderness, therefore, seems to be a relevant sign in diagnosis of posterior interosseous nerve entrapment.

Pain on supination against resistance is reported to be a sign of posterior interosseous nerve entrapment (Hagert et al. 1977, Lister 1977). In the present series pain on resisted supination was found preoperatively in most cases; it was intense in 51 cases. In cases with preoperative pain on supination, but no epicondylar tenderness, the results of surgery were good. The superficial supinator edge was at surgery often observed to squeeze the

nerve on passive tensing of the supinator by pronation of the forearm. A similar compression of the nerve might well be the cause of pain on resisted supination and might explain the role played by repetitive rotatory movements at work. Pain on supination may also be present in epicondylitis (Tupper 1971, Priest 1976). Personal observations have shown that pain can be elicited on resisted supination in patients with signs of epicondylitis but without tenderness over the nerve. Pain on supination, therefore, has to be interpreted with care, not overestimating its value as an indicator for entrapment.

Pain on pronation occurs in epicondylitis (Goldie 1964). Intense pain on pronation was combined with epicondylar tenderness in a proportion of .9 in the present investigation. Pain on pronation without epicondylar tenderness is more difficult to explain. Perhaps passive tension of the supinator muscle, producing compression of the nerve similar to that observed at surgery, might account for the pain reaction in some cases.

Pain on resisted extension of the middle finger is claimed to indicate entrapment of the posterior interosseous nerve (Kopell and Thompson 1963, Roles and Maudsley 1972, Lister 1977). When this test is performed the nerve is suggested to become compressed by the fascial extension from the extensor carpi radialis brevis muscle. In the present investigation, pain during this test was related to epicondylar tenderness rather than to the presence of such a fascial extension crossing and being in direct contact with the nerve. Furthermore, the results after decompression were better where there was no pain on performing the test. There was, thus, no evidence to support the value of this test in the diagnosis of posterior interosseous nerve entrapment.

The entrapment site

Adhesions binding down the nerve over the radial head (Roles and Maudsley 1972), the medial fascial extension from the extensor carpi radialis brevis muscle crossing the nerve (Kopell and Thompson 1963, Gianetti 1968, Roles and Maudsley 1972, Comtet et al. 1976, Lister 1977), and the edge of the superficial supinator muscle under which the nerve passes (Kopell and Thompson 1963, Capener 1966, Gianetti 1968, Roles and Maudsley 1972, Spinner 1968, 1972, Comtet et al. 1976, Hagert et al. 1977, Lister 1977), have been implicated as a cause of entrapment of the posterior interosseous nerve.

Adhesions binding down and compressing the nerve were not observed in this investigation.

There was no convincing evidence that the extensor carpi radialis brevis muscle caused entrapment. The number of good results was equal whether or not there was a medial fascial extension from this muscle crossing the nerve and there was no difference in the

occurrence of such an extension in the entrapment series compared with the normal anatomy in the autopsy series.

A recurrent branch from the posterior interosseous nerve, emerging after the nerve has passed beneath the extensor carpi radialis brevis, then travelling to the epicondyle and carrying sensory fibers from the common extensor origin at the epicondyle, has been described (Kopell and Thompson 1963). Compression acting on this branch when the extensor tightens has been suggested to provoke epicondylar pain. Such a branch was not observed at operations or dissections in the present investigation.

"Compression of the posterior interosseous nerve becomes a distinct possibility when a fibrous arch of Frohse is present" (Spinner 1968).

When the superficial supinator muscle presented a fibrous edge at intersection with the nerve, the results after decompression were usually good. As reported by Spinner from autopsy studies (Spinner 1968), a great variety of fibrosity was found in the present investigation. The registrations at dissections were made using the same criteria for "fibrousness" as in the operated series. There was a significantly higher incidence of a fibrous edge of the superficial supinator in the entrapment series compared with the autopsy series. A fibrous supinator edge at intersection with the nerve thus seems to be an important anatomic factor.

The nerve

On the whole, the nerve had a normal macroscopic appearance even when the extensor carpi radialis brevis as well as the supinator muscles had sharply defined edges. In 16 of the 90 cases there was evidence of static nerve compression as indentations of the nerve. This incidence was definitely higher in the entrapment series as compared with the autopsy series. The nerve alterations were situated at or under the edge of the superficial supinator muscle in both series.

Roles and Maudsley (1972) usually found no obvious nerve alterations. Narakas (1974) reported anatomic signs of compression in 15 of 18 cases. Hagert et al. (1977) reported a tumour-like swelling of the nerve, proximal to the supinator edge in one case and impressions into the nerve in 34 of 50 cases. The high number of nerve alterations observed by Hagert et al. may to some extent be explained by the fact that also borderline alterations were included (personal communication). In the present series only obvious alterations were recorded as positive. Nerve alterations are reported to be rather frequent in ulnar nerve entrapments at the elbow (Wilson and Krout 1973, Hagström 1977, Thomsen 1977), though there are exceptions (Lugnegård et al. 1977). In the carpal tunnel syndromes, nerve alterations are frequently observed (Tanzer 1959, Phalen 1966, 1972, Hybbinette and Mannerfelt 1975).

Nerve enlargement due to increase in connective tissue has been observed at autopsy in the ulnar nerve at the elbow and the median nerve under the retinaculum in the carpal tunnel in individuals without known entrapment disorders (Neary et al. 1975). The histological examination of the nerve alterations found in two individuals in the present autopsy series showed regressive changes as loosening of nerve tissue and reactive fibrosis, both cellular and collagenous. The few macrophages and absence of inflammatory cells in combination with loss of parenchyma indicated that the lesions were old or had developed slowly. The tissue response was that of a terminal phase with formation of a scar. Even if the etiology could not be deduced from the microscopic picture nothing contradicted the possibility that the lesions were caused by trauma such as mechanical irritation from intermittent or static compression. This might have been inflicted by the edge of the superficial supinator muscle crossing the nerve right over the site of the lesion. As the nerve alterations in the entrapment series had a similar appearance and were at the same location they may have been of the same nature, viz. a permanent nerve injury. This might explain why good results were achieved in only 11 of the 16 cases where nerve alterations were observed.

In experimental studies Rydevik and Lundborg (1977) found that especially the epineural vessels are susceptible to compression which may result in oedema and fibrosis. Perhaps internal neurolysis should have been performed in the cases with obvious nerve alterations (Curtis and Eversman 1973) in spite of the risk of subsequent fibrosis (Rydevik et al. 1976).

Dynamic compression

Visible compression of the nerve by the fascial extension from the extensor carpi radialis brevis muscle on passive forearm rotation or wrist flexion, was not observed in this investigation.

On the other hand, visible nerve compression by the edge of the superficial supinator muscle occurred in most cases on passive pronation of the forearm. When the nerve had a normal appearance and compression was observed, the results of decompression were generally good. In seven cases where compression was not observed, fair or poor results only were achieved. The question arises if active supination could produce a similar compression at the same site. Investigation of pressure conditions under the supinator edge during passive pronation and active supination has recently been carried out. Active supination was produced by tetanic stimulation of the radial nerve at the spiral groove level. On passive pronation of the forearm, compression of the nerve was observed and in this position an increase of pressure was recorded. On active supination, the recorded increase of pressure was about five times greater. There is good reason to believe that the dynamic compression, observed in most cases in the present series, corresponds to a considerable increase of pressure during active supination. Intermittent dynamic compression

of the posterior interosseous nerve by the edge of the superficial supinator muscle seems, therefore, be the probable cause of local nerve irritation and pain.

A similar mechanism has been suggested as a cause of ulnar nerve entrapment at the elbow. Elbow flexion decreases the available space for the ulnar nerve in the cubital tunnel and causes compression of the nerve by the aponeurosis that bridges the two heads of the flexor carpi ulnaris muscle (Osborne 1957, 1970, Feindel and Stratford 1958, Vanderpool et al. 1968, Apfelberg and Larson 1973); the intraneural pressure in the nerve increases during flexion (Pechan and Julies 1975). Based on these observations, nerve decompression by dividing the aponeurosis without additional transposition of the nerve has been performed with good results (Vanderpool et al. 1968, Osborne 1970, Wilson and Krout 1973, Thomsen 1977). Similar dynamic compression may be of importance in the carpal tunnel syndrome and in the pronator syndrome. Both wrist flexion and extension increase the pressure in the proximal part of the carpal tunnel (Tanzer 1959). On passive tensing of the pronator teres I have observed that compression of the median nerve occurred by anomalous fascial bands at surgery for the pronator syndrome. This may explain why pain is elicited on forearm pronation against resistance in this disorder (Solnitzky 1960, Kopell and Thompson 1963, Spinner and Spencer 1974, Lister 1977).

Neurophysiology and diagnosis

Neurophysiological investigations concerning posterior interosseous nerve entrapment as the cause of lateral elbow pain have been scanty.

Delay in motor latencies was found in "some" cases by Roles and Maudsley (1972); in two cases a reversion to normal latency was recorded postoperatively. Electromyographic evidence of the diagnosis was reported in 7 of 9 cases by Roles and Maudsley (1972); in 9 of 12 cases by Narakas (1974). Van Rossum et al. (1978) found no electrophysiological evidence of entrapment in ten cases of resistant tennis elbow; no mention was made as to the presence or absence of signs of nerve entrapment. Schmitt and Biehl (1978) reported a decreased motor conduction latency in one case following nerve decompression.

In the present investigation routine, neurophysiological examination showed some decrease of motor conduction velocity in the radial nerve across the suggested entrapment site in 13 of the 25 cases examined, and electromyographic changes in muscles innervated distal to the entrapment site in 8. Even though there was complete relief of pain in most cases with positive electrophysiologic findings, equally good results were obtained where findings were interpreted as normal.

A normal electrophysiologic finding, therefore, does not exclude the entrapment diagnosis. However, a decrease of the conduction velocity may support the diagnosis and positive electromyographic findings may be observed in one of three cases. A neurophysiological

examination may also reveal signs of cervical rhizopathia and thereby be of help in excluding cases where the nerve injury is situated more proximally.

Because of the limited value of routine electrophysiological examinations a more elaborate investigation was started in 1976 by Rosén and Werner (in manuscript). Patients selected for nerve decompression using the same criteria as those in the present investigation were examined concerning motor conduction velocity of the radial nerve across the suggested entrapment site on active, maximal supination of the forearm against a measurable resistance. In addition EMG analysis of different motor unit potentials from muscles innervated proximally and distally to the supinator muscle was performed. The observations were then compared with those in a control material of volunteers. When active supination was applied, there was a difference in the occurrence of latency prolongation between the patients and the control. Moreover, a quantification of the electromyographic observations showed a higher incidence of neurogenic changes among the patients. The study, therefore, supported the entrapment diagnosis. It also demonstrated that a more elaborate neurophysiological examination may be of value in the diagnosis.

Results of surgery

The final results were good in 73 of the 90 cases in the present series. The results are similar to those of Roles and Maudsley (1972) and Hagert et al. (1977) (Table 10). The outcome of good results compared well with those reported in ulnar nerve entrapment at the elbow (Wilson and Krout 1973, Hagström 1977, Lugnégård et al. 1977). The higher incidence of good results after surgery for the carpal tunnel syndrome (Hybbinette and Mannerfelt 1975) may be due to a different entrapment mechanism in this disorder.

Table 10. Comparison with published series.

| | Roles and Maudsley (1972) | Hagert, Lundborg and Hansen (1977) | Present series |
|-----------------------------|------------------------------|---------------------------------------|-------------------|
| Patients | 36 | 48 | 85 |
| Cases | 38 | 50 | 90 |
| Mean age | 45 | 44 | 44 |
| Female proportion | .6 | .6 | .6 |
| Epicondylar tenderness | 1.0 | .4 | .7 |
| Nerve tenderness | 1.0 | 1.0 | 1.0 |
| Positive middle finger test | 1.0 | .6 | .7 |
| Results | | | |
| Excellent | .47 | .66 | .71 |
| Good | .45 | .18 | .10 |
| Fair | .05 | .12 | .08 |
| Poor | .03 | .04 | .11 |

The improvement usually developed gradually but when relief from pain was achieved, it lasted, except in six cases where recurrences occurred. Five of the recurrences recovered after re-operation. Recurrences were not reported by Roles and Maudsley or Hagert et al. Adhesions were interpreted as the probable cause of recurrence as well as the cause of failure in at least 2 of the 9 cases, re-operated because of failure to improve and thereafter recovering.

Fat to cover the dura in intervertebral disc surgery has been reported to minimize scar formation and facilitate re-operations (Langenskiöld and Kiviluoto 1976). In the last 25 cases where fat to cover the nerve was used, the only recurrence was after trauma, which might suggest that fat to cover the released nerve was of value.

Some of the 17 fair and poor cases were probably misinterpreted as nerve entrapments; most probably those 7 cases where no compression was observed at surgery on pronation of the forearm. In 5 of the 17 cases, however, there were signs of compression in the form of indentations of the nerve and in another case electrophysiological evidence of the diagnosis. Therefore, the diagnosis was probably accurate in 6 of the 17 fair and poor cases.

Perhaps some of the "good" cases in the long run would have recovered without decompression, though it is impossible to judge which.

CONCLUSIONS

Lateral elbow pain may be caused by dynamic compression of the posterior interosseous nerve and can be relieved by decompression of the nerve where it enters through the supinator muscle.

Local tenderness over the entrapment site, the intersection between the nerve and the proximal edge of the superficial supinator muscle and pain on resisted supination of the forearm support the diagnosis. Pain on resisted extension of the middle finger seems unreliable for the diagnosis.

Routine electrophysiological examinations are of limited diagnostic value; some decrease of motor conduction velocity may be observed in half of the cases and slight EMG changes in one of three.

A fibrous edge on the superficial supinator muscle at intersection with the nerve is an important anatomic etiologic factor; on passive pronation of the forearm, compression of the posterior interosseous nerve by this edge is often observed at surgery, and good results from decompression are related to this observation. The presence of a fascial extension from the extensor carpi radialis brevis muscle crossing the nerve seems to be unimportant.

When nerve alterations, as indentations of the nerve, have developed, the prognosis of decompression is relatively poor.

Relief from pain after decompression usually develops gradually.

Recurrences due to scar formation may perhaps be prevented by placing a subcutaneous fat pad over the decompressed nerve.

SUMMARY

The purpose of the present investigation was to analyse the hypothesis that posterior interosseous nerve entrapment could be a cause of lateral elbow pain. To ascertain this the following investigations were carried out:

- (1) Patients with longstanding lateral elbow pain in whom entrapment of the posterior interosseous nerve was the suspected cause of pain were operated on by decompression of the nerve where it enters the supinator muscle and then subjected to a follow-up for two years. The preoperative symptoms and signs and observations at surgery were related to the results.
- (2) The topographical anatomy at the suspected entrapment site in the entrapment series was compared with observations at dissections in an unselected autopsy series.
- (3) The epidemiology and symptomatology in the entrapment series was compared with that in a retrospective series of lateral epicondylitis.

Material

- (1) The entrapment series consisted of 85 patients of whom five were operated bilaterally making a total of 90 cases of primary nerve decompressions. All patients had protracted lateral elbow pain at work and at rest following exertion and tenderness on palpation over the posterior interosseous nerve where it passes under the upper edge of the superficial supinator muscle. 73 patients had previously been treated for lateral epicondylitis, in 14 instances including surgery.
- (2) The autopsy series consisted of 60 individuals.
- (3) The series of lateral epicondylitis consisted of 187 patients from a three-year epicondylitis material.

Methods

- (1) The clinical examination included evaluation of epicondylar tenderness, tenderness over the suspected entrapment site, pain on resisted supination and pronation of the forearm, pain on resisted extension of the middle finger and measurement of the grip strength.
- (2) Neurophysiological examinations were made in 25 cases preoperatively and in addition the nerve conduction velocity was controlled in 12 of these cases one year post-operatively.

(3) Operative technique. The operations were carried out under brachial plexus anaesthesia and in a bloodless field. The decompression consisted of a division parallel to the nerve of (i) the fascial extension from the extensor carpi radialis brevis muscle crossing and in direct contact with the nerve, if present, and (ii) the proximal edge of the superficial supinator muscle under which the nerve passes. A subcutaneous fat pad was placed over the decompressed nerve at the last 25 primary operations and in 15 re-operated cases to prevent scar formation around the nerve.

(4) Autopsy technique. The same approach used at operations was used at the autopsy dissections. The right arm was dissected in all 60 individuals and the left one also in 30. A neuropathologist examined two nerves where alterations were observed and ten nerves where the macroscopical appearance was considered normal.

(5) Data for comparison of epidemiology and symptomatology were collected from records and a questionnaire.

Results

(1) Preoperative observations. Tenderness over the lateral epicondyle was found in 61 of the 90 cases. By definition all had tenderness over the suspected entrapment site. There was pain on resisted supination of the forearm in 84, on resisted pronation in 77 and on resisted extension of the middle finger in 67 of the 90 cases. The majority showed a diminished grip strength in the hand of the affected side.

(2) Observations at surgery. The extensor carpi radialis brevis crossed the nerve by a fascial extension in 54 of the 90 cases and the edge of the superficial supinator was fibrous at intersection with the nerve in 80 cases. The nerve was compressed by the supinator edge on passive forearm pronation in 83 cases and had a normal appearance in 74; in 16 there were visible nerve alterations as indentations often combined with some proximal swelling situated at intersection with the supinator edge.

(3) Postoperative observations. Relief from pain usually developed gradually. At six months 60, at one year 70 and at two years 73 of the 90 cases were classified as good. Re-operations were performed in 6 cases because of recurrences and in 9 cases where there was no improvement as a result of the primary operations; 5 of the recurrences and 2 of the others recovered after the re-operations. The use of a fat pad to protect the nerve seemed to reduce recurrences. During the follow-up, surgery for epicondylitis (Hohman procedure) was performed in 9 cases and surgery for other nerve entrapments in 5.

(4) Observations at surgery related to results of surgery. The presence of a fascial extension from the extensor carpi radialis brevis muscle crossing the nerve did not influence the results. On the other hand the presence of a fibrous edge on the superficial supinator muscle at intersection with the nerve was related to good results. Results were good in

62 of 67 cases where the supinator edge during passive pronation of the forearm caused compression of a nerve that appeared normal. In 16 cases where nerve alterations as indentations of the nerve had developed the results were good in 11.

(5) Neurophysiological observations. Preoperatively, some decrease of conduction velocity was recorded in 13 of the 25 cases examined; in 8 there were slight changes of motor unit potentials in distal forearm muscles. The results of surgery were equally good whether or not there was an electrophysiological abnormality. There was a decrease of conduction velocity in 2 and an increase in 3 of the 12 cases re-examined one year post-operatively; the remainder showed no definite change.

(6) Autopsy observations. The topographical anatomy at the suspected entrapment site was similar in both arms in the 30 individuals examined bilaterally. In two individuals nerve alterations were observed. Histological examination showed regressive changes that might have been caused by mechanical irritation from the overlying supinator edge. Comparison of the topographical anatomy between the two series showed no difference in the incidence of a fascial extension from the extensor carpi radialis brevis muscle crossing and in direct contact with the posterior interosseous nerve. The proximal edge of the superficial supinator muscle was significantly more often fibrous at intersection with the nerve in the entrapment series. There was also a higher incidence of visible nerve alterations in the entrapment series.

(7) Comparison of epidemiology and symptomatology in the entrapment and lateral epicondylitis series. Rotatory movements at work were reported significantly more often in the entrapment series. Many patients in both series claimed that there was a relation between their pain and work. Previous steroid injections and surgery for epicondylitis were reported significantly more effective in the epicondylitis series. Previous surgery for other nerve entrapments had significantly more often been performed in the entrapment series.

(8) The role of entrapment in tennis elbow. Based on the number of cases requiring decompression of the posterior interosseous nerve in a series of 203 patients treated for lateral epicondylitis, the incidence of posterior interosseous nerve entrapment was estimated to be around 5 per cent in the tennis elbow syndrome.

Appendix 1. Neurophysiological data.

| No | MCV | EMG | | MCV | Nerve | Result | No | MCV | EMG | | MCV | Nerve | Result |
|----|------|-------|---------------------------------|------|-------|--------|----|------|---------|-------------------------|------|-------|--------|
| | | Preop | Conclusion | | | | | | Muscles | Postop | | | |
| 2 | 57,5 | N | BR:N EIP:N | - | N | G | 72 | 64,0 | P | ECR:N EDC:P EIP:P | - | N | G |
| 6 | 88,0 | N | S:N ECR:N EDC:N EPL:N | - | N | G | 76 | 71,0 | P | ECR:N EDC:P EIP:P | - | N | G |
| 7 | 69,0 | N | BR:N EIP:N | - | N | G | 78 | 78,5 | P | EDC:P EIP:P | - | N | G |
| 10 | 54,5 | N | BR:N ECR:N EDC:N EPL:N | - | N | G | 79 | 74,0 | N | ECR:N EDC:N | 75,0 | I | G |
| 12 | 54,5 | P | S:N ECR:N EDC:P EPL:P | 45,0 | N | P | 80 | 61,5 | P | ECR:N EDC:P | 61,5 | N | G |
| 20 | 60,0 | N | ECR:N EPL:N EIP:N | - | N | G | 81 | 59,0 | N | EDC:N | 62,0 | N | G |
| 27 | 72,5 | N | BR:N ECR:N EDC:N EPL:N | 68,0 | N | P | 82 | 56,0 | N | EDC:N | 61,0 | N | G |
| 35 | 51,5 | N | BR:N EIP:N | - | I | G | 83 | 63,0 | N | ECR:N EDC:N | 59,0 | N | G |
| 42 | 58,0 | N | ECR:N EDC:N EPL:N | - | N | G | 84 | 55,0 | P | ECR:N EDC:P | 72,0 | N | G |
| 47 | 45,0 | P | BR:N ECR:P EIP:P | - | N | G | 85 | 58,0 | P | ECR:N EDC:P | 51,0 | I | G |
| 69 | 52,0 | N | BR:N ECR:N EIP:N | 78,5 | N | F | 86 | 55,0 | N | ECR:N EDC:N | 57,0 | N | G |
| | | | | | | | 87 | 71,5 | N | ECR:N EDC:N | - | N | G |
| | | | | | | | 88 | 61,0 | N | ECR:N EDC:N | 61,0 | N | G |
| | | | | | | | 89 | 56,0 | N | ECR:N EDC:N | - | I | G |

Abbreviations:

No: Case number.

MCV preop: Preoperative motor conduction velocity of the posterior interosseous nerve.

EMG: Electromyographic findings. N = normal, P = pathological. Investigated muscles. BR = brachioradialis, S = supinator, ECR = extensor carpi radialis longus, EDC = extensor digitorum communis, EPL = extensor pollicis longus, EIP = extensor indicis proprius.

MCV postop: Motor conduction velocity one year postoperatively.

Nerve: Macroscopic appearance of the posterior interosseous nerve. N = normal, I = indentation.

Results: Final results of surgery. G = good, F = fair, P = poor.

Appendix 2. Coded data in the entrapment series.

KEY

A - Case number

(n) after/before: figure indicates case number in patient operated on opposite side later/previously and included.
X: Later operated on opposite side but not included.

B - Age and sex (M = male; F = female)

C - General data

a: Operated side: Dominant = 1; Non dominant = 2
b: From three year epicondylitis material = 1
c: Previously not diagnosed or treated for epicondylitis = 1
d: Type of work: Light = 1; Moderate = 2; Heavy = 3
e: Rotatory movements: Little = 1; Much = 2
f: Previously changed work because of symptoms = 1
g: Relation between work and symptoms (patients opinion) = 1
h: Played tennis or squash = 1
i: Diminished grip strength due to previous injury = 1
j: Duration of symptoms: 1 = 1/2-1 year; 2 = 1-2 years; 3 = > 2 years
k: Pain also at night = 1

D - Previous treatment (for lateral epicondylitis a-d; surgery for other entrapments e-f)

a: Number of local steroid injections
b: Effect of steroid injections: 1 = None; 2 = Some but insufficient; 3 = Good
c: Other conservative treatment = 1
d: Surgery = 1
e: Cubital tunnel syndrome = 1
f: Carpal tunnel syndrome = 1

E - Preoperative observations (a-d Absent = 0; Slight = 1; Intense = 2)

a: Epicondylar tenderness
b: Tenderness over the entrapment site
c: Pain on resisted pronation
d: Pain on resisted supination
e: Pain on resisted extension of the middle finger: Absent = 0; Present = 1

F - Observations at surgery and further surgery

a: Nerve: Appearance normal, compression on pronation not observed = 0; Appearance normal, compression observed = 1; Alteration, compression observed = 2
b: Extension from extensor carpi radialis brevis crossing the nerve: Absent = 0; Present = 1
c: Edge of superficial supinator at the intersection with the nerve: Not fibrous = 1; Fibrous = 2
d: Re-operations: Recurrence = 1; Not improved = 2
e: Later surgery for lateral epicondylitis = 1
f: Later surgery for other nerve entrapment: Carpal tunnel syndrome = 1; Pronator syndrome = 2

G - Postoperative observations (G:1,5 = At 1,5 months; G:6 = At 6 months; G:12 = At 12 months; G:24 = At 24 months)

a: Epicondylar tenderness (a-d Absent = 0; Slight = 1; Intense = 2)
b: Tenderness over entrapment site
c: Pain on resisted pronation
d: Pain on resisted supination
e: Pain on resisted extension of the middle finger: Absent = 0; Present = 1
f: Final result of surgery: Excellent = 1; Good = 2; Fair = 3; Poor = 4

H - Grip strength (in the hand of the operated side)

a: Preoperatively
b: 1,5 months postoperatively
c: 6 months postoperatively
d: 12 months postoperatively
e: 24 months postoperatively

\pm SD = 1; -SD - -2 SD = 2; < -2 SD = 3
Previous hand injury = X

I - Change in grip strength (INCREASE)

a: 1,5 months postoperatively
b: 6 months postoperatively
c: 12 months postoperatively
d: 24 months postoperatively

$n = \frac{\text{actual} - \text{preop}}{\text{expected mean}}$ in $\text{kp}/\text{cm}^2 \times 10$

| A | B | C | D | E | F | G:1,5 | G:6 | G:12 | G:24 | H | I |
|--------|-----|--------------|----------|-------|--------|--------|--------|--------|--------|-------|------|
| | | abcde fghijk | abcdef | abcde | abcdef | abcdef | abcdef | abcdef | abcdef | abcde | abcd |
| 1 | 45M | 11-32-1--2- | 32---- | 22001 | 102--- | 200013 | 100012 | 100011 | 000001 | 33221 | 0224 |
| 2 | 50M | 11-22-1--21 | 41----- | 12111 | 112--- | 120112 | 100101 | 100001 | 000001 | 22211 | 1233 |
| 3 | 49F | 1-13211-131 | ----- | 22111 | 202--- | 121114 | 000001 | 000001 | 000001 | X | X |
| 4 | 50F | 1--22-----21 | 211--1 | 12221 | 102--2 | 111113 | 121113 | 001101 | 000001 | 32222 | 2233 |
| 5 | 45M | 2--22-----31 | 62-1-- | 02220 | 112--- | 000002 | 000001 | 000001 | 000001 | 11111 | 2222 |
| 6 | 19F | 1-111--1-31 | ----- | 02111 | 102--- | 000001 | 000001 | 000001 | 000001 | 32111 | 1435 |
| 7X | 48F | 1-132-1--2- | ----- | 02220 | 112--- | 000003 | 000001 | 000001 | 000001 | 33333 | 1222 |
| 8 | 53M | 21-22-1--21 | 411---- | 22221 | 102--- | 000003 | 000001 | 000001 | 000001 | 32211 | 5999 |
| 9 | 42M | 1-132-1-12- | ----- | 12221 | 0112-- | 011103 | 022204 | 111114 | 222214 | X | X |
| 10 | 47M | 11-2211--31 | 81-1-- | 02220 | 111--- | 021103 | 022003 | 010102 | 010002 | 21111 | 1111 |
| 11 | 37F | 1--3211--31 | 101----- | 02221 | 202--- | 011102 | 001102 | 000001 | 000001 | 33211 | 0245 |
| 12 | 51M | 1--32-1--21 | 1011---- | 22221 | 10221- | 112114 | 110014 | 010014 | 021104 | 33333 | 0000 |
| 13X | 44F | 11-22-1--21 | 31----- | 12221 | 111--- | 121113 | 000002 | 000001 | 000001 | 33111 | 2879 |
| 14 | 50F | 11-22-1--21 | 31----- | 02221 | 112--- | 022113 | 000001 | 000001 | 000001 | 21111 | 2465 |
| 15 | 32F | 11-12-----31 | 21----- | 22221 | 2121-- | 221113 | 221113 | 222214 | 000001 | 33231 | 1417 |
| 16(53) | 48M | 2--32-1--2- | 31----- | 12211 | 1121-- | 000001 | 122114 | 110002 | 000001 | 31311 | 8068 |
| 17 | 45F | 1--32-1--2- | 91-1-- | 22121 | 1112-- | 221214 | 222214 | 221014 | 221114 | 33333 | 1322 |
| 18 | 41M | 1--22-----21 | 511---- | 22121 | 112--- | 020002 | 010001 | 000001 | 000001 | 31111 | 6667 |
| 19 | 52M | 1--22-----31 | 311---- | 12220 | 112--- | 121113 | 001003 | 001001 | 000001 | 33311 | 0166 |
| 20 | 31F | 1--2211--21 | --1---- | 12221 | 112--- | 022213 | 122203 | 000001 | 000001 | 33332 | 0001 |
| 21 | 47F | 11-22-1-131 | 101----- | 22211 | 102-1- | 211113 | 101002 | 101012 | 000001 | X | X |
| 22 | 56F | 1--22-1-11- | 51----- | 12120 | 102--- | 021103 | 000002 | 110002 | 100002 | X | X |
| 23 | 46F | 1--22-----31 | 2511---- | 22221 | 001--- | 222214 | 222214 | 221114 | 221114 | 33333 | 0000 |
| 24 | 28F | 2--32-1--21 | 311---- | 12011 | 011--- | 120113 | 010003 | 011103 | 021114 | 22233 | 0000 |
| 25(73) | 35M | 1--22-1--2- | 31----- | 02121 | 1021-- | 010003 | 021104 | 000001 | 000001 | 33321 | 1268 |
| 26 | 22F | 1-11111--2- | ----- | 02120 | 102--- | 000001 | 000001 | 000001 | 000001 | 32122 | 7977 |
| 27 | 43F | 1--21-----21 | 151-1-- | 22021 | 001-1- | 220114 | 222214 | 211114 | 011104 | 33333 | 0000 |
| 28 | 32M | 1--32-1--2- | 41----- | 22221 | 2022-- | 221114 | 122114 | 221214 | 211114 | 33333 | 0000 |
| 29(65) | 51F | 1--21-1--21 | 101----- | 12221 | 2111-- | 022213 | 000001 | 210104 | 121114 | 22133 | 0200 |
| 30 | 40F | 1--22-----21 | 511---- | 22021 | 112--- | 210002 | 000001 | 000001 | 000001 | 21111 | 5444 |

| A | B | C | D | E | F | G:1,5 | G:6 | G:12 | G:24 | H | I |
|--------|-----|---------------|----------|-------|--------|--------|--------|--------|--------|-------|------|
| | | abcde | abcde | abcde | abcde | abcde | abcde | abcde | abcde | abcde | abcd |
| 31X | 47F | 11-22-1--31 | 621--- | 22221 | 1122-- | 222213 | 222214 | 011102 | 000001 | 33322 | 2276 |
| 32 | 36F | 21-32----21 | 31----- | 12121 | 102--- | 001213 | 001001 | 100001 | 000001 | 21111 | 2547 |
| 33 | 38M | 1--22-1--21 | 621--- | 12121 | 102--- | 011103 | 000001 | 000001 | 000001 | 33321 | 0259 |
| 34 | 28F | 11-11-----2 | 31----- | 22221 | 112--- | 002212 | 000002 | 000001 | 000001 | 31111 | 5458 |
| 35(89) | 23F | 1-122-----21 | ----1- | 02111 | 212--- | 000001 | 000001 | 000001 | 000001 | 32111 | 5567 |
| 36 | 35M | 1--32-1--21 | 211----- | 22011 | 112--- | 010002 | 000001 | 000001 | 000001 | 32111 | 5988 |
| 37 | 45F | 11-2211--41 | 10211-1 | 22211 | 112--- | 110003 | 201113 | 201013 | 100002 | 33111 | 0766 |
| 38 | 44F | 1--22--1-21 | 211----- | 22121 | 112--- | 010002 | 000001 | 000001 | 000001 | 32111 | 4767 |
| 39(78) | 44M | 1--3211--21 | 911----- | 12221 | 112--- | 120012 | 000001 | 100011 | 000001 | 33231 | 0557 |
| 40 | 41F | 1--22-----41 | 511----- | 22221 | 112--- | 222213 | 000001 | 000001 | 000001 | 32111 | 5888 |
| 41 | 42M | 1--32-----21 | 211----- | 12121 | 112--- | 101113 | 000001 | 000001 | 000001 | 33332 | 2345 |
| 42 | 46F | 11-12-----31 | 611--- | 02110 | 102--1 | 021103 | 000001 | 000001 | 000001 | 21111 | 5775 |
| 43 | 48F | 1--22-----21 | 102----- | 12111 | 102--- | 000001 | 000001 | 000001 | 000001 | 11111 | 0000 |
| 44 | 41F | 1--22-----21 | 311--- | 02111 | 102--- | 021102 | 010102 | 000001 | 000001 | 33311 | 3354 |
| 45 | 53M | 1--32-1--31 | 2011--- | 22111 | 102--- | 122113 | 122114 | 111104 | 011104 | 33333 | 0022 |
| 46 | 54F | 1--3211--31 | 25111-- | 22221 | 1122-- | 222214 | 222214 | 222214 | 222214 | 33333 | 0000 |
| 47 | 52F | 1-122-----11 | --1----- | 02120 | 112--- | 121113 | 010002 | 000001 | 000001 | 33221 | 1468 |
| 48X | 48F | 1--32-1--41 | 211--- | 22221 | 1122-- | 222214 | 221114 | 000001 | 000001 | 32211 | 1275 |
| 49 | 34F | 1-112--1121 | ----- | 12221 | 102--1 | 121203 | 000001 | 000001 | 000001 | X | X |
| 50 | 50M | 1--11-----2 | 211----- | 22221 | 102--- | 021103 | 000001 | 000001 | 000001 | 21111 | 0333 |
| 51X | 41M | 1--32-1--31 | 411--1- | 02110 | 102--- | 120102 | 010001 | 000001 | 000001 | 21111 | 1111 |
| 52 | 40F | 1--1211--41 | 611--- | 22221 | 212-11 | 221113 | 100102 | 100012 | 100013 | 32113 | 4763 |
| (16)53 | | 1 | - | 02111 | 1022-- | 021002 | 021013 | 021104 | 020003 | 31131 | 5616 |
| 54 | 64M | 1--21-----2- | 211--- | 02110 | 112--- | 020002 | 010002 | 000001 | 000001 | X | X |
| 55 | 35M | 1--2211-131 | 811--- | 12001 | 112--- | 120002 | 100003 | 000001 | 100012 | X | X |
| 56 | 40F | 1--22-----12- | --1----- | 12110 | 1021-- | 022202 | 000001 | 121113 | 000001 | X | X |
| 57 | 29F | 2-132-----21 | --1-1- | 02111 | 112--- | 010012 | 000101 | 000101 | 000001 | 33333 | 0111 |
| 58 | 58M | 1--12-----21 | 52----- | 02120 | 112--- | 020203 | 000001 | 000001 | 000001 | 13111 | 0122 |
| 59X | 55M | 1--32-1--41 | 20111-- | 02010 | 112--- | 021103 | 000001 | 000001 | 000001 | 33222 | 1333 |
| 60 | 44F | 1--22-1--3- | 32----- | 12111 | 001-1- | 120213 | 201113 | 110113 | 100003 | 23232 | 0000 |

| A | B | C | D | E | F | G:1,5 | G:6 | G:12 | G:24 | H | I |
|--------|-----|--------------|----------|-------|---------|--------|--------|--------|--------|-------|------|
| | | abcde fghijk | abcdef | abcde | abcdef | abcdef | abcdef | abcdef | abcdef | abcde | abcd |
| 61 | 55M | 1-122--12- | ----1- | 02110 | 112--- | 020003 | 000001 | 000001 | 000001 | X | X |
| 62 | 28M | 1--32-1--21 | 611--- | 22111 | 212-1- | 020002 | 110112 | 000101 | 000001 | 22221 | 0004 |
| 63 | 47M | 21-3211--31 | 321--- | 22011 | 112-1- | 020102 | 211113 | 000001 | 000001 | 23333 | 0000 |
| 64 | 40F | 1--1211-13- | 2211-- | 12221 | 012--- | 102214 | 221114 | 102114 | 100003 | X | X |
| (29)65 | 2 | 2 | 41 | 22221 | 111---- | 222203 | 000001 | 000001 | 000001 | 33311 | 0044 |
| 66 | 39F | 1--32-1--21 | 22----1 | 02100 | 102--- | 021003 | 000001 | 000001 | 000001 | 33111 | 0776 |
| 67 | 40F | 1-112-1--21 | ----- | 02000 | 212---- | 020004 | 010003 | 010003 | 110003 | 33333 | 1211 |
| 68 | 45F | 2--32-1--2- | 101----- | 22211 | 112--- | 221113 | 011113 | 001112 | 111103 | 33332 | 0003 |
| 69 | 47F | 1--22-----31 | 41----- | 22211 | 002-1- | 111114 | 201114 | 110114 | 010003 | 33333 | 0100 |
| 70X | 47M | 2--2211--31 | 8111-- | 22101 | 102--- | 221014 | 000001 | 100011 | 000001 | 33111 | 1645 |
| 71 | 52F | 2--32-----2- | 41----- | 12121 | 202--- | 020002 | 000001 | 000001 | 000001 | 12111 | 0000 |
| 72 | 40M | 1--11-1--3- | 41----- | 02110 | 112--- | 011102 | 000001 | 000001 | 000001 | 33111 | 2999 |
| (25)73 | 2 | 2 | 31 | 22111 | 202-1- | 000001 | 200012 | 100001 | 101002 | 32322 | 2134 |
| 74 | 36F | 2--22-----21 | 21----- | 02120 | 112--- | 000001 | 000001 | 000001 | 000001 | 31111 | 4778 |
| 75 | 54M | 1--22--1-2- | 621---- | 22211 | 202---- | 111113 | 100002 | 000001 | 000001 | 33211 | 0244 |
| 76 | 43M | 1--12--1-3- | 31----- | 22211 | 102--- | 211113 | 100001 | 100001 | 000001 | 33111 | 0856 |
| 77 | 50F | 2--22-----21 | 61----- | 12210 | 102--- | 120003 | 010001 | 000001 | 000001 | 22121 | 1423 |
| (39)78 | 2 | 2 | 31 | 22221 | 112--- | 111113 | 000001 | 000101 | 000001 | 33211 | 0458 |
| 79 | 29F | 1--22-1--2- | 11----- | 02121 | 212--2 | 011112 | 000002 | 001003 | 000002 | 33332 | 2334 |
| 80 | 67M | 1--11-----21 | 41----- | 02121 | 102--- | 010102 | 010001 | 000001 | 000001 | 32111 | 5777 |
| 81 | 45M | 1--2211--31 | 51----- | 22111 | 112--- | 111113 | 000001 | 000001 | 000001 | 33333 | 0443 |
| 82 | 59M | 1--32-1--2- | --1---- | 02020 | 102--- | 010102 | 000001 | 000001 | 000001 | 21111 | 2244 |
| 83 | 58F | 1--22-1--21 | ----- | 12221 | 112--- | 110113 | 100113 | 000001 | 000001 | 11111 | 0010 |
| 84 | 53M | 1--32-1--31 | 31-1-- | 12221 | 102--- | 000103 | 000001 | 000001 | 000001 | 33333 | 0122 |
| 85 | 51M | 1--22-1--21 | ----- | 12011 | 212--- | 110102 | 000001 | 000001 | 000001 | 12111 | 0123 |
| 86 | 62M | 1--22-----21 | 811---- | 02120 | 112--- | 011103 | 001002 | 000002 | 000001 | 33331 | 0359 |
| 87 | 50M | 1--32-1--2- | 22----- | 22221 | 112--- | 111103 | 000113 | 011113 | 000001 | 33322 | 2454 |
| 88 | 27F | 1-122-----11 | ----- | 02010 | 112--- | 010002 | 000001 | 000001 | 000002 | 33322 | 3487 |
| (35)89 | 2 | 2 | - 11 | 12221 | 212--- | 000001 | 000103 | 000001 | 000001 | 33311 | 0177 |
| 90 | 39F | 1--21-----21 | 21----- | 02000 | 112--- | 000001 | 000001 | 110002 | 100002 | 33111 | 0522 |

Appendix 3. The questionnaire.

The questions, which were answered by marking "yes" or "no", except no.3, were as follows:

1. Are you right or left handed.
2. Have you or have you had trouble from your right elbow, left elbow, both elbows.
3. What is your occupation.
4. Do you consider your work to be strenuous, medium or light.
5. Does rotation at the elbow and wrist occur to a great extent or to a slight extent while working.
6. Have you changed your occupation because of elbow pain.
7. Do you consider your pain to have been brought on by your work.
8. Do you take part in such sporting activities as tennis, squash or badminton.
9. Does your elbow still trouble you.
10. Do you consider this trouble to be severe, mild or insignificant.
11. How long has your elbow troubled you: less than 6 months, between 6 months and 1 year, between 1 year and 2 years, more than 2 years.
12. How many cortison injections have you had in the treatment of your right elbow, left elbow.
13. What in your opinion was the effect of the cortison injection: very good (became painfree), good (very little pain), mild effect (slight improvement but still painful) or short effect (that lasted at most 2-4 weeks).
14. Have you had any other treatment in the form of shortwave, heat, rest, etc.
If the answer is yes, on how many occasions.
15. How long have you been on sick leave because of your elbow pain during the last 2 years:
not at all, less than 1 month, 1-2 months, 2-6 months, more than 6 months.
16. Have you had or do you have pain only on strenuous work, pain also at rest, pain at night.
If yes, is sleep disturbed by pain.

The questionnaire sent to patients in the three year material of lateral epicondylitis was completed with: Do you because of present pain want a new examination.

ACKNOWLEDGEMENTS

I wish to express my gratitude to:

Ingrid Larsson for typing the manuscript,
David Haffajee and Gillian Sjö Dahl for revising the language,
Karin Nilsson, Jan Strömblad and the Photographic Department for help with the
illustrations,
and many of my colleagues for valuable advice and criticism.

Financial support was obtained from the Swedish Medical Research Council (project B79-17X-02031-13A), The Foundation for the Assistance of Cripples in Skåne and the Alfred Österlund Foundation.

REFERENCES

- Apfelberg, D.B. and Larson, S.J. (1973) Dynamic anatomy of the ulnar nerve at the elbow. *Plast. Reconstr. Surg.* 51, 76-81.
- Beaton, L.E. and Anson, B.J. (1939) The relation of the median nerve to the pronator teres muscle. *Anat. Rec.* 75, 23-26.
- Benini, A. and DiMartino, E. (1976) Die Schädigung des Ramus profundus nervi radialis (Supinator Syndrom). *Schweiz. Med. Wschr.* 106, 639-643.
- Birkbeck, M.Q. and Beer, T.C. (1975) Occupation in relation to the carpal tunnel syndrome. *Rheum. Rehab.* 14, 218-221.
- Bosworth, D.M. (1965) Surgical treatment of tennis elbow. *J. Bone Joint Surg.* 47-A, 1533-1536.
- Bowen, T.L. and Stone, K.H. (1966) Posterior interosseous nerve paralysis caused by a ganglion at the elbow. *J. Bone Joint Surg.* 48-B, 774-776.
- Boyd, H.B. and McLeod, A.C. (1973) Tennis elbow. *J. Bone Joint Surg.* 55-A, 1183-1187.
- Bronisch, F.W. (1971) Zur Pathogenese und Therapie der nichttraumatischen Lähmung des Ramus profundus n. radialis. *Nervenarzt* 42, 32-35.
- Bryan, F.S., Miller, L.S. and Panijayanond, P. (1971) Spontaneous paralysis of the posterior interosseous nerve. A case report and review of the literature. *Clin. Orthop.* 80, 9-12.
- Buchthal, F., Rosenfalck, A. and Trojaborg, W. (1974) Electrophysiological findings in entrapment of the median nerve at wrist and elbow. *J. Neurol., Neurosurg. Psychiat.* 37, 340-360.
- Campbell, C.S. and Wulf, R.F. (1954) Lipoma producing a lesion of the deep branch of the radial nerve: Case report. *J. Neurosurg.* 11, 310-311.
- Capener, N. (1966) The vulnerability of the posterior interosseous nerve of the forearm. A case report and an anatomical study. *J. Bone Joint Surg.* 48-B, 770-773.
- Chang, L.W., Gowans, J.D.C., Granger, C.V. and Millender, L.H. (1972) Entrapment neuropathy of the posterior interosseous nerve. A complication of rheumatoid arthritis. *Arthritis Rheum.* 15, 350-352.
- Comtet, J. and Chambaud, D. (1975) Paralysie "spontanée" du nerf inter-osseux postérieur par lésion inhabituelle. Deux observations. *Rev. Chir. Orthop.* 61, 533-541.
- Comtet, J., Chambaud, D. and Génety, J. (1976) La compression de la branche postérieure du nerf radial. Une étiologie méconnue de certaines paralysies et de certaines épicondylalgies rebelles. *Nouv. Presse Med.* 5, 1111-1114.
- Curtis, R.M. and Eversmann, W.W. (1973) Internal neurolysis as an adjunct to the treatment of the carpal tunnel syndrome. *J. Bone Joint Surg.* 55-A, 733-740.
- Dewey, P. (1973) The posterior interosseous nerve and resistant tennis elbow. *J. Bone Joint Surg.* 55-B, 435.
- De Zanche, L., Negrin, P., Fardin, P. and Carteri, A. (1978) Paralysis of the deep branch of the radial nerve due to entrapment neuropathy. *Eur. Neurol.* 17, 56-59.
- Feindel, W. and Stratford, J. (1958) The role of the cubital tunnel in tardy ulnar palsy. *Canad. J. Surg.* 1, 287-300.
- Frohse, F. and Fränkel, M. (1908) Die Muskeln des menschlichen Armes. In: *Handbuch der Anatomie des Menschen*. Ed. K.v. Bardeleben. Bd. 2.2:11:A. Gustav Fischer, Jena.

- Garden, R.S. (1961) Tennis elbow. *J. Bone Joint Surg.* 43-B, 100-106.
- Gardner, R.C. (1970) Tennis elbow: Diagnosis, pathology and treatment. Nine severe cases treated by a new reconstructive operation. *Clin. Orthop.* 72, 248-253.
- Gianetti, J.F. (1968) The anatomy of the radial nerve at the elbow and its relationship to tennis elbow. *J. Bone Joint Surg.* 50-A, 843.
- Gilliat, R.W. (1975) Peripheral nerve compression and entrapment. In: Eleventh symposium on advanced medicine. Ed. A.F. Lant. Pitman Medical, London, 144-163.
- Goldie, I. (1964) Epicondylitis lateralis humeri (Epicondylalgia or tennis elbow). A pathogenetical study. *Acta Chir. Scand. Suppl.* 339.
- Goldman, S., Honet, J.C., Sobel, R. and Goldstein, A.S. (1969) Posterior interosseous nerve palsy in the absence of trauma. *Arch. Neurol.* 21, 435-441.
- Guillain, G. and Courtellemont (1905) L'action du muscle court supinateur dans la paralysie du nerf radial. Pathogénie d'une paralysie radiale incomplète chez un chef d'orchestre. *Presse Med.* 1, 50-52.
- Hagert, C.G., Lundborg, G. and Hansen, T. (1977) Entrapment of the posterior interosseous nerve. *Scand. J. Plast. Reconstr. Surg.* 11, 205-212.
- Hagström, P. (1977) Ulnar nerve compression at the elbow. Results of surgery in 85 cases. *Scand. J. Plast. Reconstr. Surg.* 11, 59-62.
- Hobhouse, N. and Heald, C.B. (1936) A case of posterior interosseous paralysis. *Br. Med. J.* 1, 841.
- Hohman, G. (1933) Das Wesen und die Behandlung des sogenannten Tennisellenbogens. *Munchen. Med. Wschr.* 80, 250-251.
- Hybbinette, C.H. and Mannerfelt, L. (1975) The carpal tunnel syndrome. A retrospective study of 400 operated patients. *Acta Orthop. Scand.* 46, 610-620.
- Kaplan, E.B. (1959) Treatment of tennis elbow (epicondylitis) by denervation. *J. Bone Joint Surg.* 41-A, 147-151.
- Kopell, H.P. and Thompson, W.A.L. (1963) Peripheral entrapment neuropathies. William and Wilkins Company, Baltimore.
- Kruse, F.Jr. (1958) Paralysis of the dorsal interosseous nerve not due to direct trauma. *Neurology* 8, 307-308.
- Langenskiöld, A. and Kiviluoto, O. (1976) Prevention of epidural scar formation after operations on the lumbar spine by means of free fat transplants. *Clin. Orthop.* 115, 92-95.
- Lister, G. (1977) *The Hand: Diagnosis and indications.* Churchill Livingstone, Edinburgh, London and New York.
- Lugnegård, H., Walheim, G. and Wennberg, A. (1977) Operative treatment of ulnar nerve neuropathy in the elbow region. *Acta Orthop. Scand.* 48, 168-176.
- Lundborg, G. (1975) Structure and function of the intraneural microvessels as related to trauma, edema formation and nerve function. *J. Bone Joint Surg.* 57-A, 938-948.
- Löser, R., Prill, A., Rittmeyer, K. and Sollman, H. (1972) Das nicht traumatische Supinatorlogensyndrom des N. radialis und seine Abgrenzung zum cervicalen Wurzelreizsyndrom. *Z. Neurol.* 201, 337-347.
- Marmor, L., Lawrence, J.F. and Dubois, E.L. (1967) Posterior interosseous nerve palsy due to rheumatoid arthritis. *J. Bone Joint Surg.* 49-A, 381-383.
- Marshall, S.C. and Murray, W.R. (1974) Deep radial nerve palsy associated with rheumatoid arthritis. *Clin. Orthop.* 103, 157-162.
- Matthews, P.B.C. (1972) *Mammalian muscle receptors and their central actions.* Edward Arnold (Publishers) Ltd London.

- Melzack, R. and Wall, P.D. (1965) Pain mechanisms: A new theory. *Science* 150, 971-979.
- Millender, L.H., Nalebuff, E.A. and Holdsworth, D.E. (1973) Posterior interosseous-nerve syndrome secondary to rheumatoid synovitis. *J. Bone Joint Surg.* 55-A, 753-757.
- Morris, H.H. and Peters, B.H. (1976) Pronator syndrome: clinical and electrophysiological features in seven cases. *J. Neurol. Neurosurg. Psychiat.* 39, 461-464.
- Mulholland, R.C. (1966) Non-traumatic progressive paralysis of the posterior interosseous nerve. *J. Bone Joint Surg.* 48-B, 781-785.
- Narakas, A. (1974) Epicondylite et syndrome compressif du nerf radial. *Med. et Hyg.* 32, 2067-2070.
- Neary, D., Ochoa, J. and Gilliat, R.W. (1975) Sub-clinical entrapment neuropathy in man. *J. Neurol. Sci.* 24, 283-298.
- Osborne, G.V. (1957) The surgical treatment of tardy ulnar neuritis. *J. Bone Joint Surg.* 39-B, 782.
- Osborne, G.V. (1970) Compression neuritis of the ulnar nerve at the elbow. *Hand* 2, 10-13.
- Overgaard Nielsen, H. (1976) Posterior interosseous nerve paralysis caused by fibrous band compression at the supinator muscle. A report of four cases. *Acta Orthop. Scand.* 47, 304-307.
- Pechan, J. and Julis, I. (1975) The pressure measurement in the ulnar nerve. A contribution to the pathophysiology of the cubital tunnel syndrome. *J. Biomech.* 8, 75-79.
- Phalen, G.S. (1966) The carpal-tunnel syndrome. Seventeen years' experience in diagnosis and treatment of six hundred fifty-four hands. *J. Bone Joint Surg* 48-A, 211-228.
- Phalen, G.S. (1972) The carpal-tunnel syndrome. Clinical evaluation of 598 hands. *Clin. Orthop.* 83, 29-40.
- Priest, J.D. (1976) Tennis elbow. The syndrome and a study of average players. *Minnesota Med.* 59, 367-371.
- Richmond, D.A. (1953) Lipoma causing a posterior interosseous nerve lesion. *J. Bone Joint Surg.* 35-B, 83.
- Roles, N.C. and Maudsley, R.H. (1972) Radial tunnel syndrome. Resistent tennis elbow as a nerve entrapment. *J. Bone Joint Surg.* 54-B, 499-508.
- Rydevik, B., Lundborg, G. and Nordborg, C. (1976) Intraneural tissue reactions induced by internal neurolysis. An experimental study on the blood-nerve barrier, connective tissues and nerve fibres of rabbit tibial nerve. *Scand. J. Plast. Reconstr. Surg.* 10, 3-8.
- Rydevik, B. and Lundborg, G. (1977) Permeability of intraneural microvessels and perineurium following acute, graded experimental nerve compression. *Scand. J. Plast. Reconstr. Surg.* 11, 179-187.
- Schmitt, O. and Biehl, G. (1978) Das Supinator-Tunnel-Syndrom als Differentialdiagnose zur Epicondylitis radialis. Elektromyographische Diagnostik und Verlauskontrolle. *Z. Orthop.* 116, 840-846.
- Seyffarth, H. (1951) Primary myosis in the m. pronator teres as a cause of lesion of the n. medianus (The pronator syndrome). *Acta Psychiatr. et Neurol. Suppl.* 74, 251-254.
- Sharrard, W.J.W. (1966) Posterior interosseous neuritis. *J. Bone Joint Surg.* 48-B, 777-780.
- Solnitzky, O. (1960) Pronator syndrome: compression neuropathy of the median nerve at level of pronator teres muscle. *Georgetown Med. Bull.* 13, 232-238.

- Spinner, M. (1968) The arcade of Frohse and its relationship to posterior interosseous nerve paralysis. *J. Bone Joint Surg.* 50-B, 809-812.
- Spinner, M. (1972) Injuries to the major branches of peripheral nerves of the forearm. W.B. Saunders Comp. Philadelphia, London, Toronto.
- Spinner, M. and Spencer, P.S. (1974) Nerve compression lesions of the upper extremity. A clinical and experimental review. *Clin. Orthop.* 104, 46-67.
- Sunderland, S. (1976) The nerve lesion in the carpal tunnel syndrome. *J. Neurol. Neurosurg. Psychiat.* 39, 615-626.
- Tanzer, R.C. (1959) The carpal-tunnel syndrome. A clinical and anatomical study. *J. Bone Joint Surg.* 41-A, 626-634.
- Thomsen, P.B. (1977) Compression neuritis of the ulnar nerve treated with simple decompression. *Acta Orthop. Scand.* 48, 164-167.
- Thorngren, K.G. and Werner, C.O. (1979) Normal grip strength. *Acta Orthop. Scand.* in press.
- Tinel, J. (1915) Le signe du "fourmillement" dans les lésions des nerfs périphériques. *Presse Med.* 47, 388-389.
- Tupper, J.W. (1971) Experiences with epicondylitis. In: *Symposium on the hand*, 3. Ed. L.M. Cramer and R.A. Chase. C.V. Mosby Co. St. Louis, 234-238.
- Upton, A.R.M. and McComas, A.J. (1973) The double crush in nerve entrapment syndromes. *Lancet* 359-362.
- Vanderpool, D.W., Chalmers, J., Lamb, D.W. and Whiston, T.B. (1968) Peripheral compression lesions of the ulnar nerve. *J. Bone Joint Surg.* 50-B, 792-803.
- van Rossum, J., Buruma, O.J.S., Kamphuisen, H.A.C. and Onvlee, G.J. (1978) Tennis elbow - a radial tunnel syndrome? *J. Bone Joint Surg.* 60-B, 197-198.
- Weinberger, L.M. (1939) Non-traumatic paralysis of the dorsal interosseous nerve. *Surg. Gynec. Obstet.* 69, 358-363.
- Whiteley, W.H. and Alpers, B.J. (1959) Posterior interosseous nerve palsy with spontaneous neuroma formation. *Arch. Neurol.* 1, 226-229.
- Wilson, D.H. and Krout, R. (1973) Surgery of ulnar neuropathy at the elbow: 16 cases treated by decompression without transposition. Technical note. *J. Neurosurg.* 38, 780-785.
- Winkworth, C.E. (1883) Lawn-tennis elbow. *Br. Med. J.* 708.
- Woltman, H.W. and Learmonth, J.R. (1934) Progressive paralysis of the nervus interosseus dorsalis. *Brain* 57, 25-31.
- von Torklus, D. (1977) Bedeutung und Therapie des Supinator-Syndroms bei der Epicondylitis radialis. *Orthop. Praxis* 4, 282-283.



