

PROCEEDINGS OF THE SCANDINAVIAN ORTHOPAEDIC ASSOCIATION 39th Assembly

Odense, Denmark, June 1978

MEASURES AGAINST SUPERFICIAL WOUND INFECTION AND DEEP SEPSIS IN TOTAL HIP ARTHROPLASTY

Knud Jørgensen

Odense Hospital, Odense, Denmark

From 1968 to 1974, 240 Charnley type total hip arthroplasties were carried out in a conventional operating theatre. From 1974 to 1978, 576 hips were operated upon in a clean-air room using the same technique. The first 603 hips were analysed in detail in order to find the characteristics of the risk groups. Diagnosis, age, prior hip operation, the presence of urogenital infection, preoperative sedimentation rate and weight were examined. There was no difference as regards these parameters between those with and those without infection. The same was found in an analysis of the number of blood transfusions, operation time, wound drainage and the surgeon's experience. There were 28 hips with superficial wound infection. Two patients developed haematoma. At present 816 hips have been operated upon. Deep sepsis occurred in nine cases of which three were operated upon in the clean-air room.

DEEP INFECTION AFTER TOTAL HIP REPLACEMENT

Olav Reikerås & Arne Rugtveit

Kronprinsesse Märthas Institutt, Oslo, Norway

We have reviewed 523 total hip replacement operations with a mean follow-up period of 4.1 years. All operations were performed in a conventional operating room, but great attention was paid to hygienic principles. Two deep infections occurred postoperatively, and there were six late infections 1 to 4 years after the operation. Four of these were low-grade *staph. albus* infections with loosening of the prosthesis. The two youngest patients – 29 and 33 years – both with Bechterew's disease developed virulent infection 2

and 3 years, respectively, after the operation. One was infected with β -haemolytic streptococcus after an erysipelas of the leg; the other was infected with *staph. aureus* 1½ weeks after extraction of a molar tooth. We suggest that the infections may have been caused by haematogenous seeding. The pathogenesis of late infection may be endogenous as well as exogenous.

McKEE-FARRAR ARTHROPLASTY – SUCSESSES AND FAILURES

Jan Thorblad & Bengt Tillberg

University Hospital, Linköping, Sweden

A follow-up study was made of 299 hips, in patients 36–92 years old (average 67), operated on at the Orthopaedic Hospital, Härnösand, Sweden, 1969–73 and fitted with a McKee-Farrar prosthesis. The patients were examined every third month during the first year and then once each year up to 8 years (average 5 years). The status was assessed with regard to pain, walking capacity and mobility, using Charnley's classification.

Complications during operation occurred in 1 per cent (two femoral fractures and one cardiac arrest). The postoperative mortality rate within 6 weeks was 2 per cent. Thrombosis occurred in 20 patients and there were four deaths due to pulmonary embolism. Postoperative dislocation occurred in one patient. 24 patients (8 per cent) developed superficial infection, and 11 (3 per cent) persistent deep infection after the operation or during the following 40 months. The prosthesis became dislodged in 37 patients (12.5 per cent) between 3 and 84 months postoperatively.

Pain was relieved dramatically after operation, and mobility improved. Pain tended to recur, however, and after 5 years only half of the patients were free from pain. Walking capacity became impaired with the return of pain but mobility was affected to a lesser degree.

NINE YEARS' EXPERIENCE WITH TOTAL HIP REPLACEMENT WITH SPECIAL REGARD TO LOOSENING AND INFECTION
Imre Gabor & Olav Reikerås
Sophies Minde Orthopaedic Hospital, Oslo, Norway

We started in 1969 to use Weber's and in 1973 Ring's hip prosthesis. Both have a high frequency of loosening; up until now 50 and 10 per cent, respectively. Between 1970 and 1976, 55 patients with loose prostheses were reoperated on and fitted with a new prosthesis. The result is good in 44 and unsatisfactory in 11 patients; but 10 of these were fitted with the Weber prosthesis.

Between 1969 and 1973 there was an infection rate of 8 per cent. From 1 January 1974, operating routines based on strict aseptic principles were introduced. There has since been no instance of deep infection.

The 30 patients who developed deep infection in the earlier period were treated mainly by removal of the prosthesis and bringing the infection under control. Seven of the 30 patients have had new hip prostheses inserted 1 to 7 years after the primary prosthesis was removed. These seven patients have been observed for a period of between $\frac{1}{2}$ and $3\frac{1}{2}$ years; all are well with no evidence of infection.

274 TOTAL HIP REPLACEMENTS WITH CHRISTIANSEN'S TRUNNION BEARING PROSTHESIS. COMPLICATIONS AND SOCIAL ASPECTS

Rolf Hagen

Martina Hansens Hospital, Sandvika, Norway

During a $4\frac{1}{2}$ year period from 1.11.73 to 1.5.77, 277 arthroplasties (215 unilateral and 31 bilateral) were performed. Eighty-seven per cent of the patients were over 60 years. There were no post-operative deaths; nine died from other diseases and three were excluded (mean follow-up $2\frac{1}{2}$ years). Forty-five patients had previously been operated on in the same hip.

The operations were performed in a regular operating room and the posterior approach without detaching the trochanter was used. No general prophylactic antibiotics were administered but gentamicin cement was used from 1.1.76. Thrombosis prophylaxis comprised Macrodex® peroperatively and during the 1st day, early mobilization and Marevan® perorally from the 1st day.

The complications are listed in Table 1. Twelve patients required reoperation.

Table 1. Complications in 274 arthroplasties (243 patients) using Christiansen's prosthesis

	No.	Per
		cent
<i>Early</i>		
Haematoma	7	2.5
Haematoma with dropfoot	1	0.4
Haematoma with superficial infection	3	1.1
Infection, superficial	2	0.7
Infection, deep	1	0.4
Pneumonia	3	1.1
Dropfoot	1	0.4
Thrombosis	3	1.1
Dislocation	2	0.7
	23	8.4
<i>Late</i>		
	No.	Per cent
Loose femoral component	6	2.18
Loose acetabular component	1	0.36
Osteomyelitis	3	1.1
Reaction from implanted material?	2	0.7
Dislocation	1	0.36
	13	4.7

MECHANICAL LOOSENING OF THE FEMORAL HEAD PROSTHESIS IN TOTAL HIP REPLACEMENT ACCORDING TO CHARNLEY

Åke S. Carlsson & Carl-Fredrik Gentz

Malmö General Hospital, Malmö, Sweden

Loosening was defined as the development of a zone of demarcation between metal and cement at the proximal and lateral border of the stem of the prosthesis, but zones less than 1 mm were disregarded. The demarcation was found in 103 out of 288 (36 per cent) non-infected, low friction arthroplasties. The occurrence of zones became more frequent as the years passed, and they were significantly more common in men. A previous operation was followed by a significantly increased risk of loosening. Absence of cement medially at the femoral calcar or elsewhere around the prosthesis seemed to be of greater importance than the position of the prosthesis. The body weight did not differ between patients with and without a zone of demarcation. Pain on walking was found in 7 per cent of the patients without and in 23 per cent in patients with a demarcation. The difference is significant. With increasing width of the zone, there was a significantly increasing proportion of painful hips.

ECTOPIC BONE FORMATION FOLLOWING LOW FRICTION ARTHROPLASTY OF THE HIP AD MODUM CHARNLEY

C. Kromann-Andersen, E. Frigaard, F. Borch Jensen, D. Zdravkovic, K. Hougaard & T. Scherff Sørensen

Odense University Hospital, Odense, Denmark

Three hundred and nine patients with 365 operated hips were examined for the presence of ectopic bone formation. Assessment was made by studying ordinary X-rays in the a-p projection and the patients were divided into four groups according to the degree of severity (from none to bridged ectopic bone formation between acetabulum and femur). Charnley's classification concerning pain, walking ability and range of motion was used to evaluate the clinical importance of ectopic bone. The average observation time was 4 years and 4 months.

Ectopic bone formation occurred more frequently and was more marked in men than in women. The frequency of the occurrence of ectopic bone formation increased with time. Ectopic bone formation may restrict the range of motion. In bilaterally operated hips there was usually a similar amount of ectopic bone formation on both sides.

PROBLEMS WITH THE GREATER TROCHANTER IN CHARNLEY TOTAL HIP ALLOPLASTY

T. Scherff Sørensen, Kj. Hougaard, D. Zdravkovic, F. Borch Jensen, E. Frigård & C. Kromann-Andersen

Odense Hospital, Odense, Denmark

To be published in Acta.

THE PRIMARY COMPLICATIONS OF TOTAL HIP REPLACEMENT

S. Rosendahl & H. Galatius
Hvidovre Hospital, Denmark

One hundred and forty-seven total hip replacements were reviewed. The patients were 17–85 years old with a mean age of 70 years. The Stanmore prosthesis was used and the operation was performed through a posterior approach. No infections occurred. All patients received prophylactic antibiotic treatment with methicillin at the beginning of the operation and with dicloxacillin 5 days postoperatively. The operating room was disinfected with alcohol before surgery; the air in the operating theatre did not contain microorganisms before the operation, as demonstrated by sedimentation plates.

Ten postoperative dislocations were registered.

One patient died 13 days after surgery from pulmonary embolism, and a further four patients had thrombophlebitis but recovered within 1 week.

COMPLICATIONS AFTER TOTAL HIP REPLACEMENT

Johannes Yde

Hjørring Hospital, Hjørring, Denmark

One hundred and sixty-three total hip replacements according to Charnley were performed on 145 patients during the years 1974–1977. Seventy-five were operated on in an ordinary operating theatre and 88 in a clean-air box.

Peroperatively one fracture of the femoral shaft and six stem perforations of the shaft were encountered.

Complications during the first 3 months comprised five deep venous thromboses and one death from pulmonary embolism. There were two dislocations, both treated by closed reduction followed by traction, but no primary infections were recorded.

Complications occurring more than 3 months postoperatively were 37 hips with tenderness over the trochanter region. There was no relation to radiographic findings such as a broken wire, fibrous union or proximal migration of the greater trochanter. Twelve hips had a radiolucent line between the femoral prosthesis and the cement. Three had fractures of the cement without subjective symptoms, and two sustained a fracture of the femoral shaft and were treated by internal fixation with plates and screws. No patients developed deep infection.

POSTOPERATIVE COMPLICATIONS AFTER 605 CHARNLEY TOTAL HIP REPLACEMENTS

E. Dyreborg, J. Jørgensen, P. Krogh, E. K. Petersen, R. Rohr & C. Schlanbusch
University Hospital of Odense, Denmark

There was one fatal complication in the series. It was not possible to identify groups with a high risk of cardiopulmonary complications. Among the patients with preoperative cardiopulmonary illness, we found postoperative complications in 13 per cent, compared with 21 per cent among the remaining patients. Early mobilization led to a significant fall in the incidence of deep vein thrombosis and pulmonary embolism from 20 to 5 per cent. Six per cent developed urinary infection postoperatively, due either to a previous urinary infection or to the use of a postoperative indwelling catheter. Patients treated previously for

bleeding from a duodenal ulcer had a high risk of postoperative gastrointestinal complications.

PROPHYLAXIS AGAINST THROMBO-PHLEBITIS AND THROMBOEMBOLIC COMPLICATIONS IN TOTAL HIP ALLOPLASTY

T. Scherff Sørensen & K. Lund
Odense Hospital, Odense, Denmark

To be published in Acta

PREOPERATIVE REDUCTION OF WEIGHT IN HIP ALLOPLASTY

Vagn Højksjaer Larsen
Odense University Hospital, Odense, Denmark

During the period 1 April 1975 to 31 March 1977, 411 patients were admitted for treatment of coxarthrosis. Height and weight were registered in 395. Two hundred and fifty-two were considered overweight (normal weight plus 10 per cent). One hundred and thirty overweight patients were offered operation, provided their weight could be normalized. In 73 per cent the weight was reduced to normal. The reduction in weight was achieved by reducing the quantity of food in 94 per cent, change of diet in 88 per cent, and regular check-ups at the general practitioner in 42 per cent. Three per cent needed hospitalization during weight reduction. If the attempted reduction in weight amounted to less than 15 kg, this could be achieved within a year. The average weight loss was 8.6 kg.

VALUE OF EPICUTANEOUS TESTS FOR ALLERGY TO METALS IN IMPLANTATION SURGERY

T. Silvennoinen, E. Karaharju, P. Slätis & M. Hannuksela
Surgical Hospital, Helsinki, Finland

Two hundred and fifty-eight patients who were to have a metallic implant (endoprosthesis, AO plate or Küntscher nail) were patch-tested for cobalt, chrome, nickel and iron allergy. Four patients showed severe allergy before surgery. The incidence corresponds to recorded figures of the frequency of metal allergy in the Finnish population.

A series of 50 of these patients, without previous allergy, all treated with hip endoprostheses at least 1 year previously were selected for a second patch test. The second test was supplemented with radiographs and clinical examination. Three of the patients had developed allergy to the metals tested; two of these showed signs of loosening of their prostheses. The small

numbers do not warrant conclusions on the interaction between metal allergy and loosening.

METAL SENSITIVITY IN PATIENTS WITH METAL-TO-PLASTIC TOTAL HIP ARTHROPLASTIES

Åke S. Carlsson & Bertil G. Magnusson
Malmö General Hospital Malmö, Sweden

To be published in Acta.

RESURFACING ARTHROPLASTY OF THE HIP AD MODUM WAGNER

K. Aalto, P. Slätis & E. Karaharju
Surgical Hospital, Helsinki, Finland

Thirty Wagner resurfacing arthroplasties were performed on 28 patients. Mean age was 66 years; three patients were under 30. The indication for operation was degenerative arthritis in 26 cases and rheumatoid arthritis in four cases. A trochanteric osteotomy had previously been performed on three hips. Radiologically, the arthrosis was severe in 18 cases. The main complaints were pain and restricted walking ability.

The patients were allowed out of bed on the 3rd postoperative day. Slight ectopic ossification was recorded in three cases. No infection or fracture of the femoral neck was encountered. Painless walking was achieved in most cases. The overall mobility score of the hip, graded according to d'Aubigné-Postel, increased from 107 to 172 degrees.

PEROPERATIVE VARIATIONS IN BLOOD PRESSURE DURING CEMENTING OF TOTAL HIP ALLOPLASTIES AD MODUM CHARNLEY

K. Lund & T. Scherff Sørensen
Odense Hospital, Odense, Denmark

The drop in blood pressure, during the cementing of the acetabular and the femoral components in 402 hip joints, was estimated retrospectively and related to the preoperative blood pressure level, the peroperative loss of blood and the technique used for reducing the pressure in the medullary cavity of the femur during insertion of the cement.

SOCIO-MEDICAL EVALUATION OF THE PATIENT'S LIFE AFTER CHARNLEY HIP ALLOPLASTY

C. Kromann-Andersen & K. Jørgensen
Odense University Hospital, Odense, Denmark

Three hundred and ten patients were examined with reference to their socio-medical conditions

pre- and postoperatively. Operation on the hip did not allow any of the preoperatively retired patients to return to work. Moreover 22 per cent of the preoperatively able-bodied patients were given a pension on socio-medical grounds, the majority because of the operated hip. Other variations in the patients' occupational and pension status depended entirely on age group. The patients' level of activity was assessed by a questionnaire and they were divided into five groups ranging from patients requiring nursing care to persons with physically active spare-time interests. This was compared with the patients' preoperative situation.

We concluded that operation on the hip quite unequivocally improved the possibility of physical activity, as 75 per cent of the patients had normalized their life, and 50 per cent were able to enjoy physically demanding spare-time interests.

A COMPARISON BETWEEN THE SURGEONS' EVALUATION OF THE RESULT AFTER TOTAL HIP ARTHROPLASTY AND THE PATIENT'S EVALUATION OF HIP PAIN AND MOBILITY

Knud Jørgensen

Odense Hospital, Odense, Denmark

Our evaluation was made 2 and 5 years after operation, according to the Charnley numerical classification. The results are satisfactory.

A questionnaire to 309 patients enquired about pain and mobility (no pain, less pain, more pain, improved or impaired mobility). Ninety-five per cent had no pain or less pain after operation; 87 per cent had improved mobility.

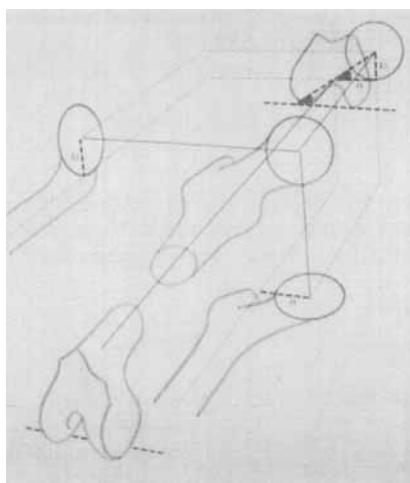
The Charnley classification was simplified in order to make it comparable with the patient's evaluation. There was an excellent agreement. We asked if the operation came up to expectations; 91 per cent answered yes. Finally we asked if the patients would recommend the operation to other persons with hip disease; 95 per cent answered yes. Conclusion: Our evaluation corresponds with that of the patients.

ROENTGENOGRAPHIC DETERMINATION OF THE ROTATION POSITION OF THE FEMORAL PORTION OF THE HIP PROSTHESIS

Olof Norman

General Hospital, Lund, Sweden

The position of the femoral component of the hip prosthesis with regard to rotation can be



illustrated by measuring the anteversion angle. The author's method is based on defined frontal and true lateral views and graphic-geometric calculation. The shape of the neck can be disregarded and therefore the method is suitable for all the different types of prostheses. The patient can remain in the resting position and no co-operation is required, allowing for the method to be used pre-, per- and postoperatively.

One can also derive ample information from conventional frontal and oblique lateral views, provided one knows the orientation of the femur, which is why, without moving the leg, we take an additional lateral film of the knee for assessing rotation.

MOVEMENT BETWEEN BONE AND BONE CEMENT-PROSTHESIS AFTER ARTHROPLASTY DETERMINED WITH ROENTGEN STEREOPHOTOGRAMMETRY

Halldór Baldursson, Lars Ingvar Hansson, Tord H. Olsson & Göran Selvik

University Hospital of Lund and University of Lund, Lund, Sweden

To be published in Acta.

CHARNLEY TOTAL HIP ARTHROPLASTY AS TREATMENT FOR CONGENITAL HIP DYSPLASIA AND DISLOCATION

K. Lund & N. Termansen

Odense Hospital, Odense, Denmark

To be published in Acta.

PROSPECTIVE MULTICENTER STUDY OF
KNEE ARTHROPLASTIES

*Göran Bauer, Kaj Knutsson & Anders Lindstrand
Lindstrand*

University Hospital, Lund, Sweden

Thirty-five departments of orthopaedic surgery are participating in a prospective study of knee arthroplasties. Data are computerized and

presented twice yearly. 1774 arthroplasties have been registered from October 1975 through March 1978. The incidence of deep infection, loosening, wear and fracture of the endoprosthesis in patients followed up for at least 1 year is shown here.

One third of the complications were due to deep infection and two thirds to endoprosthesis problems. Patient and surgeon were satisfied with the 1-year result in 78 per cent of the cases.

Diagnosis	Prosthesis	No.	Prosthesis		
			No. of complications	Reinserted	Removed
Osteoarthritis	Hinged	29	7	4	2
	Non-hinged	23	3	1	—
	Double unicondylar	18	1	1	—
	Unicondylar	133	9	5	2
Rheumatoid arthritis	Hinged	56	8	2	2
	Non-hinged	58	4	1	1
	Double unicondylar	82	6	2	2
	Unicondylar	21	2	2	—
Total		420	40 (= 10%)	18 (= 4%)	9 (= 2%)

FUNCTIONAL STATUS AFTER MARMOR
KNEE ARTHROPLASTY STUDIED BY
MEANS OF ISOMETRIC MUSCLE
STRENGTH MEASUREMENTS AND GAIT-
ANGLE DIAGRAM TECHNIQUE

*A. Wigren, K. Kolstad, K. Öberg, L.-O. Nordesjö, P. Berg & L. Lamoreux**

University Hospital, Uppsala, Sweden and Berkley,* California

From amongst a large group of patients in whom arthroplasty of the knee had been performed, seven underwent a special gait analysis by means of an exoskeletal goniometric system, where the gait was represented by an angle diagram depicting the movements of the hip and knee. The results were compared with a clinically adapted scoring system for pain, gait and mobility and with measurements of isometric muscle strength. The examinations were performed preoperatively and 8–12 months postoperatively. The gait-angle diagram illustrated well the operative results and corresponded with the clinical findings. The muscle strength in all knees was reduced by at least 75 per cent preoperatively in comparison with a normal material, and was still unchanged one year postoperatively in spite of the absence of pain, an increase in walking distance and mobility, and a marked improvement in gait as demonstrated by the objective gait analysis.

PRECAUTIONS AND INTENSIVE
TREATMENT IN KNEE ARTHROPLASTY

Anders Wigren

University Hospital, Uppsala, Sweden

In a series of 100 Marmor knee arthroplasties 75 per cent were knees with rheumatoid arthritis. The same orthopaedic surgeon evaluated all patients preoperatively, and performed the arthroplasty. Preoperative examination of the respiratory and urinary tracts and the skin often led to treatment of manifest or latent infection before operation. The patients were nursed in a specially clean ward. A strict operative routine was followed. The operation was performed in epidural anaesthesia in an ordinary operating theatre using antibiotic prophylaxis. Both compartments were replaced in 90 per cent of the arthroplasties. The wound was attended to by the orthopaedic surgeon. Prophylactic treatment against thrombosis consisted of active movements and elevation of the foot of the bed. All wounds healed primarily. Duration of hospitalization was about 2 weeks. There was no operative mortality, no secondary operations for primary complications, no signs of deep venous thrombosis, no infection and no loosening of the prosthesis. The orthopaedic surgeon has been responsible for the ambulant care of the patients, and in the case of any urgent problems examination has been

performed without delay. The length of the observation period is 6 months to 2½ years.

PRIMARY COMPLICATIONS AFTER MARMOR RESURFACING ARTHROPLASTY

K. Rechnagel

Frederiksborg County Hospital, Hillerød, Denmark

During 1976–77, 90 knee arthroplasties *ad modum* Marmor were performed. Primary complications have been rare and of little significance. Delayed healing has been the commonest complication. No infections and no loosening occurred.

Sixty-four knees have no pain, 23 are almost pain-free, and 3 have some pain. In these three cases one of the hinge prostheses should have been used. As a rule the mobility has not been increased, but in one case of rheumatoid arthritis an ankylosed knee gained a motion of 0/70 degrees.

The resurfacing technique is applicable even in elderly patients and in those in a poor physical condition. The complications seem to be of little significance as regards the end result, and revisions are possible should they be found necessary.

ICLH ARTHROPLASTY OF THE KNEE JOINT: RESULTS AND COMPLICATIONS

Gunnar B. J. Andersson & Peter Herberts
Sahlgren Hospital, Gothenburg, Sweden

Sixty-six knees operated on with the ICLH prosthesis have been followed prospectively at regular intervals for a period of from 1 to 5 years.

The results were good with respect to pain, which disappeared or was alleviated in all but six knees. The functional improvement was less dramatic largely due to the fact that other weight-bearing joints were diseased in all but three patients.

The complications included two deep infections after revision, four cases of loosening, and three cases of instability and deformity. All poor results were in patients with complications. All complications could be traced to inability to position the prosthesis accurately or correct the deformity at the time of the operation.

CORRELATION BETWEEN POSITION OF DUOCONDYLAR PROSTHESIS AND FUNCTION OF THE KNEE JOINT

Ian F. Goldie, Christina Raner & Jan Cappelen-Smith

Sahlgren Hospital and Östra Hospital Gothenburg, Sweden

Between 1972 and 1976, 51 knee joints in 40 patients have been reconstructed with the St.

Georg sledge prosthesis. The patients were followed up in May 1978 with regard to the clinical condition as well as the position of the prosthesis at radiological examination. A comparison was made between the position of the prosthesis and the function of the knee joint. Six patients (eight knee joints) had died. Of the remaining 34 patients, 25 had satisfactory radiological examinations carried out. The clinical impression was that a good relationship existed between the position of the prosthesis and the joint function, i.e. good position = good function. The numerical evaluation as presented in a visual analogue disclosed, however, that surprisingly many knee joints without pain and with excellent function did not have as good a position of the prosthesis as was expected.

LATERAL DISLOCATION OF THE PATELLA FOLLOWING GUEPAR ALLOPLASTY OF THE KNEE

N. Fredensborg, U. Klaumann & O. Sneppen
Rigshospitalet, Copenhagen, Denmark

To be published in Acta as part of:

LATERAL DISLOCATION OF THE PATELLA FOLLOWING MARMOR AND GUEPAR ALLOPLASTY OF THE KNEE

O. Sneppen, N. Fredensborg, A. Karle & U. Klaumann

JOINT DEBRIDEMENT FOR OSTEO-ARTHRITIS OF THE KNEE

Olav Reikerås

Kronprinsesse Märthas Institutt, Oslo, Norway

Osteoarthritis of the knee with normal alignment, but with osteocartilaginous excrescences, has been treated by debridement of the joint. Through a medial parapatellar arthrotomy all compartments of the knee are inspected, degenerated articular cartilage is shaved off, osteocartilaginous excrescences and torn menisci are removed and a limited synovectomy is done, if indicated.

In the years 1967–1976 33 knees in 31 patients have been operated on. The age ranged from 47–79 years, with a mean of 57 years. They have been followed up for from 1½–11 years, with a mean of 5.4 years. Assessment was made with regard to relief from pain and improvement in movement and function. The result was found to be good/satisfactory in 85 per cent and poor in 15 per cent. We also found that a good result may be maintained over a prolonged period. We conclude that debridement of the joint is a reliable method of treatment for osteoarthritis of the knee if indicated.

DIAGNOSIS OF DEEP INFECTIONS FOLLOWING TOTAL HIP REPLACEMENT

Åke Carlsson

Allmänna Hospital, Malmö, Sweden

Diagnostic difficulties in patients with delayed infection are usually only encountered where raised temperature and other more general symptoms of infection are lacking. Months or years after the operation pain on walking develops slowly, and pain can be induced by passive rotation of the hip.

Postoperatively, the erythrocyte sedimentation rate increases but returns in uncomplicated cases to the preoperative level within 3 months, whereas in patients who later on develop deep infection, the ESR, markedly increased already during the early postoperative period, never returns to normal. An ESR above 40 mm more than 3 months after the operation strongly indicates a deep infection in patients with osteoarthritis. In rheumatoid disease the ESR is of little value and one must depend on other diagnostic means. It is recommended that the ESR should be included in the routine procedure of every patient visit after total joint replacement.

ANTIBIOTIC TREATMENT IN PATIENTS WITH INFECTED TOTAL HIP ARTHROPLASTY

Lars Lidgren

University Hospital, Lund, Sweden

Fifty patients with infected Charnley total hip arthroplasties have been treated with antibiotics without extracting the prosthesis. There were 47 periods of treatment with antibiotics for more than 3 months, and 48 periods without antibiotic treatment. The antibiotic treatment was able to greatly reduce the pain. The erythrocyte sedimentation rate was significantly lowered in the treated group compared with the group without antibiotic treatment. Roentgenological investigations were performed, without additional clinical information, and showed that the X-ray changes were not progressing in half of the periods with antibiotics compared with one sixth of the periods without antibiotics. In patients with infected total hip arthroplasty and advanced age or medical contraindication for reoperation, long-term antibiotic treatment can dampen the infection.

REOPERATION OF HIP ARTHROPLASTIES WITH GENTAMICIN CEMENT

Göran Josefsson, Lars Lindberg & Åke Carlsson
Gävle, Lund and Malmö, Sweden

One hundred and forty-two hip arthroplasties were reoperated upon because of suspected deep infection. Seventy-seven with confirmed deep infection were selected for analysis - 58 after direct exchange and 19 after a two-step exchange. Thirty-five have been followed up for more than 2 years. Sixty hips are classified as healed, 4 as doubtful and 13 as infected (4 have been reoperated on a second time). At present there is no demonstrable difference in results after direct exchange and after two-step exchange of the infected total hip prosthesis.

SPECIFIC PROPERTIES OF GENTAMICIN-PALACOS R

R. Helmut Wahlig

Medical Research, Department of Chemotherapy, E. Merck, Darmstadt, W. Germany

Comparing different antibiotics and bone cements, Palacos R with gentamicin proved to be the most suitable as far as release of antibiotic is concerned. Leaching of gentamicin was observed for more than 5 years. In tissue samples from the vicinity of the implanted cement in patients, high concentrations (4-36 µg/g) were found for up to 3½ years.

BACTERIAL FLORA IN INFECTED TOTAL HIP ARTHROPLASTIES

Lars Lindberg & Karl Kamme

General Hospital, Lund, Sweden

The bacteriology of 77 deep infections in total hip arthroplasties was investigated with a special technique. Seventeen were caused by *Staph. epid.*, 13 by *Staph. aureus*, 7 by *Propionibacterium acnes*, 8 by different anaerobic cocci and 11 by other microbes. Twenty-one of the infections were caused by a mixed flora whereas anaerobes were found in 9 cases.

DIAGNOSIS AND TREATMENT OF INFECTED KNEE ARTHROPLASTIES

Jens Langer Andersen

Lund General Hospital, Lund, Sweden

In 71 knee arthroplasties with a hinge joint prosthesis (66 Guepar, 5 Shier) superficial infection or delayed wound healing developed after 15 of the operations, and deep infection was suspected in 21 cases. The diagnosis of deep infection has been confirmed by laboratory in-

vestigations, bacteriology and X-ray. In cases of spontaneous fistulation and in cases with fast progression of X-ray changes we have found indications for reoperation. In seven cases the prosthesis has been removed and a new prosthesis inserted using gentamycin bone cement. One year after reoperation two cases have become reinfected, and five are without signs of infection.

DEMANDS ON RESOURCES AND COSTS IN THE HOSPITAL CARE OF SOME TYPICAL ORTHOPAEDIC PATIENTS

Kurt Kolstad & Anders Wigren
University Hospital, Uppsala, Sweden

To be published in Acta.

ARTHROSCOPY OF THE KNEE JOINT

Odd Haerum

County Hospital, Kristiansand, Norway

A series of 123 patients with knee joint lesions has been studied with the arthroscopy technique.

In the period from 1.2.77 to 1.6.77, 40 knee joints were examined. There were 12 misinterpretations (31 per cent). The second part of the material, which includes 83 knee joints, was examined in the period from 1.6.77 to 20.5.78. Only eight misinterpretations were made, a failure rate of 10.5 per cent. If we include 27 knee joints that were only arthroscopied and the findings regarded as normal, the misinterpretation rate drops to 7.2 per cent.

It is concluded that arthroscopy is a useful tool in the diagnosis of knee joint injuries and a safe method of diagnosing injuries of the menisci; unnecessary arthrotomies may be avoided and misinterpretation is significantly reduced with increasing experience with the arthroscopy technique.

ARTHROSCOPY OF THE KNEE JOINT USING THE DYONICS NEEDLESCOPE

Villiam Damholt & Espen Berntsen
Odense Hospital, Odense, Denmark

At the Department of Orthopaedic Surgery, arthroscopy of 236 knee joints using the Dyonics Needlescope (standard model) has been performed. An antero-lateral approach under general anaesthesia was routinely employed. No complications were observed. In assessing the value of arthroscopy, the clinical diagnosis, the arthroscopic findings and the findings at operation have been compared.

In 167 knees with primary indication for surgery, arthroscopy refuted the clinical diagnosis in 13 cases. Of the remaining 154, the clinical

diagnosis was correct in 114 cases (74 per cent), whereas arthroscopy yielded 140 correct pre-operative diagnoses (91 per cent). In 69 knees without primary indication for surgery, arthroscopy revealed 22 cases suitable for surgery (32 per cent), while in 47 cases the diagnosis was corrected, supplemented or confirmed.

INTRA-ARTICULAR SHAVING OF PATELLAR CHONDROMALACIA

Kari Aalto & Kalevi Österman

Helsinki University Central Hospital, and Orthopaedic Hospital of the Invalid Foundation, Helsinki, Finland

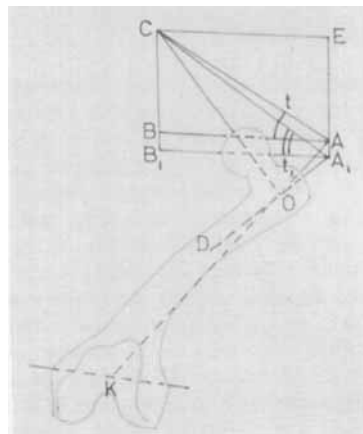
A new film of the indications for and the operative technique in the treatment of patellar chondromalacia using the Dyonics intra-articular patellar shaver is presented.

ROENTGENOGRAPHIC DETERMINATION OF ROTATIONAL DISPLACEMENT IN FRACTURES OF THE FEMUR

Olof Norman

General Hospital, Lund, Sweden

The anteversion angle of the femoral neck can be used to elucidate the relationship between the proximal and distal parts of the femur. Comparison with the healthy side will give the degree of rotation. The method of measurement can be used also if the leg is fixed in traction or in plaster of Paris. In this measurement I have, in agreement with most authors, made use of the short femoral axis (D-O-A₁) but since the topographic anatomy is disarranged by a fracture, the calculation should be made with the aid of the long axis (K-O-A) according to the anatomical definition. This requires knowledge of the position of point 9 which, however, does not exist, as the



axes of the neck and the shaft do not meet. I have therefore chosen to locate the junction at the level of the lower margin of the lesser trochanter in the "frontal" view.

ROTATIONAL DEFORMITY AFTER FEMUR FRACTURE IN CHILDREN – A 10-YEAR FOLLOW-UP STUDY

Lars Ingvar Hansson & Olof Norman
General Hospital, Lund, Sweden

Femur diaphysis fracture in children is usually treated by traction. Some shortening at healing is desirable as this is compensated for by growth stimulation during the following years. Faulty angle position is largely corrected during the remaining growth period. However, there is some doubt about whether a rotational deformity is corrected in this period.

Nineteen children (2 to 14 years of age) with femur diaphysis fracture during the period 1967 to 1970 were subjected to bilateral determination of anteversion angles according to Norman on two to three occasions during the following 6 to 10 years. The primary anteversion angle determination showed that the femur fracture usually heals with a rotational deformity (maximum 20 degrees) compared with the nonfractured side.

Later anteversion determinations showed a normalization compared with the healthy side. This suggests that a rotational deformity is spontaneously corrected. This tendency is greatest in children with a fracture at an early age, and is most marked during the years immediately following fracture.

THE IMPORTANCE OF ROTATIONAL DEFORMITIES IN THE DEVELOPMENT OF ANGLE DEFORMITIES AFTER FRACTURE

Gunnar B. J. Andersson, Roland Örtengren & Björn Henriksson
Sahlgren Hospital and Children's Hospital, Gothenburg, Sweden

The importance of rotational deformities in the development of angular deformities after fractures for long bones is not always recognized. A geometrical model has been developed to permit calculation of the residual angular deformity as a function of a rotational deformity and of the obliquity of the fracture. Already at rotational deformities of 4 degrees and obliquities of 10, 20, 30, and 45 degrees, angular deformities occur of 0.7, 1.5, 2.3, and 4.0 degrees, respectively. When the rotational deformity is 24 degrees and the obliquity of the fracture 45 degrees the residual angular deformity will be as much as 22.6 degrees. The model was validated using supracondylar

fractures of the humerus. When correcting angular deformities by means of rotational osteotomies estimates of the necessary corrections can be made.

RESULTS OF TALUS-CALCANEUS OSTEOTOMY IN RELAPSING OR INCORRIGIBLE CLUB-FEET

Åke Hjelmstedt & Bo Sahlstedt
Academic Hospital, Uppsala, Sweden

To be published in Acta.

ASPECTS OF ANATOMY AND TREATMENT OF VERTICAL TALUS (CONGENITAL CONVEX PES VALGUS)

Åke Hjelmstedt, Bo Sahlstedt & Klas Buring
Academic Hospital, Uppsala and Sundsvall Hospital, Sundsvall, Sweden

Six feet with this deformity were examined by simultaneous arthrography of the ankle and the talonavicular joints. The arthrograms showed some flattening of the posterior part of the trochlea and flattening of the dorsal facet of the talar head. The anterior subtalar joint was visualized in five of the six feet.

Conservative treatment should be instituted immediately after birth. If this fails to give correction in a few months – which is often but not always the case – the treatment should be discontinued until about 9 months of age.

The operative procedures should be based on the arthrographic findings. The equinus deformity should be corrected by lengthening of tendo Achillis and lengthening of other tendons might also be necessary. Open reduction of the navicular should be done in the case of slight-to-moderate dysplasia. If, however, the dysplasia is pronounced, correction can be achieved either by excision of the navicular or by wedge osteotomy of the talar neck. The latter procedure was used successfully in three feet.

INTERCONDYLAR Y-SHAPED FRACTURES OF THE HUMERUS

Vappu Uuspää
Orthopaedic Hospital of the Invalid Foundation, Helsinki, Finland

One hundred and fifty-eight patients aged 15–90 with 159 intercondylar Y-shaped fractures were treated in the Clinic for Orthopaedics and Traumatology, Helsinki University Central Hospital, during the period 1960–72. Two thirds of the 91 female patients were 55–90 years of age. Almost half of the male patients were aged 15–35 years. According to the Riseborough-Radin

classification there were 24 cases of type I, 44 cases of type II, 44 cases of type III, and 27 cases of type IV. One fracture in four was open. Four primary nerve injuries were noted. Eighty patients were treated conservatively and 78 operatively. Sixteen patients had signs of postoperative infection and 9 cases of pseudarthrosis were noted.

SUPRACONDYLAR FRACTURES OF THE HUMERUS IN CHILDREN: A LONG-TERM FOLLOW-UP STUDY OF 107 CASES

Veijo Vahvanen & Kari Aalto

Aurora Children's Hospital, Helsinki, Finland

Published in *Acta (Acta orthop. scand.* **49**, 225–233, 1978).

LATE RESULTS AFTER SEVERELY DISPLACED SUPRACONDYLAR FRACTURES OF THE HUMERUS: VERTICAL EXTENSION VERSUS CLOSED REDUCTION

Jens Lund-Kristensen & Ole Vibild

Copenhagen Municipal Hospital, Bispebjerg, Denmark

Out of 43 children with grossly displaced supracondylar fractures of the humerus, 23 were treated with vertical extension using a Kirschner wire, 17 with manipulative reduction and plaster and 3 were operated on. The functional results were equal in the first two groups. As regards varus deformity the results were better after vertical extension than after closed reduction.

SUPRACONDYLAR FRACTURES OF THE HUMERUS

H. Hansen & A. Andersen

Aalborg Hospital, Denmark

In the 5-year period 1972–1976, 45 children aged 4–12 years were treated for supracondylar fractures of the humerus at the Orthopaedic Department, Aalborg Hospital. Forty-three were followed up in 1978. Of these, 20 had been treated with manual reduction and plaster cast, 17 with olecranon traction and 6 with open reduction and pinning.

Olecranon traction gave satisfactory results, better than those after manual reduction and plaster cast (especially in cases with marked dislocation) and equal to open reduction and pinning. The functional results were good.

There were a few cases with pronounced varus ($>10^\circ$) at the elbow. There were no cases of Volkmann's contracture, and no permanent nerve damage.

NEUROLOGICAL EXAMINATION IN SUPRACONDYLAR FRACTURES OF THE HUMERUS

Thomas Dolk, Urban James & Hallbus S. Mattsson

Regional Hospital, Örebro, Sweden

In a series of 96 patients with supracondylar fracture of the humerus, 10 obvious nerve injuries occurred (five medianus, four radialis and one Volkmann). Only two of these were diagnosed before treatment. Two were observed after open reduction and six during traction.

Primary neurological findings were normal in 46 but were not stated in 39 records. A suspected but transient nerve lesion was often associated with circulatory insufficiency. It was thus often difficult to tell if a neurological deficit was due to trauma or treatment.

"MY HAND" – a minimal hand neurological examination – now used in our treatment programme for supracondylar fractures indicates spontaneous hand position, distribution of sweat secretion, sensibility of digital pulpa of index and little fingers, ability to close the hand and ability to spread the fingers. Adequate primary hand neurological examination is too often neglected. We recommend "My Hand" as a simple screening test in all upper limb injuries.

SUPRACONDYLAR FRACTURES OF THE HUMERUS IN CHILDREN

Kjell Bertheussen & Jans Kramhøft

Frederiksborg County Hospital, Hillerød, Denmark

Thirty-nine children were treated for severely dislocated supracondylar fracture of the humerus. In 30 cases vertical traction with an AO or Ormandy screw in the olecranon was used. The fracture was reduced under general anaesthesia and retained with vertical traction and soft tissue lateral traction on the humerus. Traction was maintained for 2–3 weeks; thereafter a plaster splint was applied for 1–2 weeks. Five patients needed more than one reposition; in two cases the traction was removed after a few days and a plaster used. Five patients primarily had no palpable pulse distally and one showed signs of temporary nerve damage. Four patients demonstrated radial nerve palsy after the reposition, all with total remission. No other complications were observed. We find this to be a safe and satisfactory method of treatment for this difficult fracture.

OPEN REDUCTION OF SUPRACONDYLAR FRACTURES OF THE HUMERUS IN CHILDREN

Børge Krebs
Svenborg, Denmark

Twenty-three children were operated on because of supracondylar fracture of the humerus. The operative procedure was in all cases open reduction and fixation with Kirschner wires. The children were aged between 4 and 13 years at the time of operation. Twelve patients were operated upon immediately and 11 after an average of 5 days. Mean observation time was 51 months.

The patients were examined and evaluated according to the classification described by Flynn et al. (1974). In 16 children the result was "excellent", in six "good" and in one "not acceptable". In two cases there were minor postoperative complications but there were no serious complications.

SURGICAL AND CONSERVATIVE TREATMENT OF SUPRACONDYLAR FRACTURES OF THE HUMERUS IN CHILDREN

P. Ottsen & J. Evaldsen
Århus County Hospital, Århus, Denmark

During the period 1967–1977, 107 children were treated for dislocated supracondylar fracture of the humerus, and 80 of these patients (75 per cent) were seen at a follow-up examination. Average observation time was 5½ years. Thirty patients were treated by open reduction and osteosynthesis (pinning with two crossed K-wires). In 50 patients closed reduction was carried out, in 29 with additional traction from the olecranon. At the follow-up one operated and five conservatively treated patients had valgus or varus angulation of more than 10°. Only four patients had limitation of elbow movement of more than 10°. The radiographs showed accelerated bone maturity and bone growth in both groups. No epiphysiodesis was found. There was no significant difference concerning angulation and/or elbow movement in the conservatively versus operatively treated groups. No complications due to open reduction and fixation were found.

It is concluded that osteosynthesis is a safe way of handling this fracture. The average period of hospitalization was reduced from several weeks to a few days.

CAPUT FIXED SLIDING NAIL FOR TREATING EPIPHYSIOLYSIS CAPITIS FEMORIS

Lars Ingvar Hansson, Gunnar Ordeberg, Anders Stenström & Karl-Göran Thorngren
University Hospital, Lund, Sweden

Various types of nails, screws, pins and bone pegs have been used in treating epiphysiolysis capitis femoris. They have caused peroperative complications, increased faulty position of caput femoris, and postoperative complications, bone resorption around the osteosynthesis material and growth in length of collum femoris. This, in some instances, has resulted in a new dislocation of caput femoris. Early closure of the growth zone has also been recorded.

Since 1975, a new type of sliding nail (modified Rydell nail) has been used in 25 cases (49 hips) with epiphysiolysis capitis femoris. The nail is placed in a drilled hole and fixed in caput femoris. In four cases of acute slipping repositioning was complete before osteosynthesis. In one case with a faulty position, wedge osteotomy was performed at the same time in collum femoris. Postoperative examinations have shown the nail to be drawn in in relation to the femur diaphysis owing to the continued growth in length of collum femoris. This indicates intact circulation in caput femoris. After wedge osteotomy in collum femoris, an avascular necrosis developed, and no growth ensued. Two cases showed a wide resorption zone around the nail, but normal growth of collum femoris. In two cases, the nails were extracted with a special instrument after growth had ceased.

DIAGNOSIS OF TRAUMATIC GROWTH DISTURBANCE WITH RÖNTGEN STEREOPHOTOGRAMMETRY

Lars Ingvar Hansson, Stefan Aronsson, Birger Bylander & Göran Selvik
General Hospital, and Lund University, Lund, Sweden

If the growth region in children is fractured, the primary diagnosis and treatment is important, as is also continued examination with regard to growth disturbance that could result in anisomelia or faulty angulation. Recent studies have shown difficulties in using Salter's classification for the demonstration of possible growth disturbance after a fracture through the growth region.

A prospective study determined the growth conditions after a fracture through the growth region using the röntgen stereophotogrammetric method. Tantalum balls were implanted in the metaphysis and the bone epiphysis on both the fractured side and the healthy side. The growth pattern was

determined in six cases with fracture, in the distal femur (3), proximal tibia (2), and distal tibia (1), with various types of injury according to Salter (I-IV). In all cases, a considerable growth disturbance was demonstrated, with cessation of growth rate in three and obvious asymmetrical growth in three.

This study shows that a growth disturbance can be demonstrated during the first months after the accident. The degree of growth disturbance and the occurrence of asymmetric growth can be determined during the following period. This method allows an early diagnosis of the growth disturbance after a physal injury and thus the introduction of early surgical treatment.

HEALING OF LARGE SURGICAL DEFECTS OF THE EPIPHYSEAL PLATE: AN EXPERIMENTAL STUDY

Kalevi Österman

Orthopaedic Hospital of the Invalid Foundation, Helsinki, Finland

Growth capacity and regeneration of the epiphyseal plate was studied by creating a large defect in the central part of the distal epiphyseal plate of the rabbit femur. A bone bridge was prevented by using a free fat tissue transplant to fill the surgical defect. The results, which were recorded by X-ray, tetracycline labelling and histology, show that most of the longitudinal growth of the bone can be preserved if bone bridge formation between the epiphysis and metaphysis is prevented. Regeneration of the growth plate is observed as well.

The results are in accordance with earlier experimental studies and clinical observations and support the view that removal of large bone bridges between the epiphysis and the metaphysis in young patients can restore a considerable amount of the longitudinal growth of a tubular bone.

TREATMENT OF DEFORMITIES IN EPIPHYSEAL INJURIES

Kalevi Österman

Orthopaedic Hospital of the Invalid Foundation, Helsinki, Finland

Deformities caused by epiphyseal injuries depend on the site and size of the epiphyseo-metaphyseal bone bridge that typically can provoke progressive angulation or shortening. Deformities of the articular surface and asymmetric growth of parallel bones must also be considered.

Operative treatment is suggested as follows: Removal of the bone bridge is the method of choice in cases of progressive deformity. Repeated

corrective osteotomies, epiphyseodesis of the opposite side and lengthening or shortening procedures are needed as supplementary treatment. An observation period of 2-4 years after epiphyseal injuries is recommended.

INJURIES OF EPIPHYSEAL PLATES. ANATOMY, PATHOPHYSIOLOGY AND CLASSIFICATION OF INJURIES

S. Ryöppy

Children's Hospital, University of Helsinki, Finland

A knowledge of the structure and nutrition of the growth plate is of primary importance both in planning treatment and in evaluating the risk of growth disturbances. Germinal cells, which are responsible for longitudinal growth, are supplied with blood via vessels from the epiphyseal side. These vessels are vulnerable in intraarticular epiphyses even in the case of simple epiphyseal separation. The zone with hypertrophied cartilage cells contains relatively little matrix, making it the weakest point in the plate. The separation caused by shearing or avulsion takes place almost invariably through this plane. Splitting and crushing may cause a fracture through the plate or crushing of the cartilage cells. The risk of growth disturbances and the requirements as regards the precision of the reduction depend on the type of injury. The Salter-Harris classification, based on the pathology of growth plate injuries, has proved the most practical for general use.

MECHANISMS IN SPONTANEOUS CORRECTION OF ANGULAR DEFORMITIES FOLLOWING FRACTURES IN CHILDREN

S. Ryöppy

Children's Hospital, University of Helsinki, Finland

The remodelling of post-traumatic deformities during growth is controlled by the same factors which determine the final shape of the skeleton. Extrinsic factors include gravity, acceleration and deceleration forces and forces due to the action of muscles.

Local resorption and apposition of bone in the region of the fracture has generally been considered the most important factor in the correction of angular deformities. Relatively small forces can modify epiphyseal growth. The general principle of correction is that the plane of the epiphyseal plate aligns perpendicularly to the resultant of the compressive forces. This alignment is caused by alteration of the direction of growth. In angular deformities an asymmetric

stimulation of growth can be demonstrated. Recent studies have shown that this process is of primary importance in the correction of angular deformities in bones exposed to compressive forces.

Because several questions concerning the remodelling process in different situations are still open, only rough predictions for expected corrections can be made in clinical practice.

GROWTH REMODELLING OF FEMORAL SHAFT FRACTURES

A. Alho, T. S. Raugstad & K. Hvidsten
Haukeland Hospital, University of Bergen, Bergen, Norway

The following conclusions are drawn on the basis of previous reports and our own preliminary results. *Ad latus* dislocation has no clinical importance. Axial dislocations of less than 15–20° are remodelled satisfactorily; sagittal deformities more so than frontal ones, and varus more than valgus. Coxa valga and coxa vara also tend, to some degree, to correct themselves. Due to stimulation resulting in overgrowth, a shortening of 0 to 2 cm is acceptable. Extensive trauma, instability, repeated reductions, and operation stimulate the overgrowth. Reports concerning the spontaneous correction of rotary deformities are scanty due to technical difficulties, but seem to indicate that some remodelling takes place. Our own preliminary results using the Dunlap-Rippstein method of measuring the CCD and antetorsion angle show that the problem can, to a considerable degree, be eliminated by careful positioning of the fracture.

DIPHOSPHONATE (EHDP) COMBINED WITH SURGICAL REMOVAL OF ECTOPIC BONE IN MYOSITIS OSSIFICANS PROGRESSIVA

Tor Hierton, Holm Holmsen & Sverker Ljunghall
University Hospital, Uppsala, Sweden

Published in *Acta (Acta orthop. scand.* **50**, 33–38, 1979).

EFFECT OF MSH ON GROWTH AND REMODELLING OF LONG BONES

K-G. Thorngren, L. I. Hansson & A. Stenström
University Hospital, Lund, Sweden

Melanocyte stimulating hormone (MSH) from the pituitary has previously not been shown to exert any physiological effects in mammals. The effect of MSH on longitudinal bone growth and remodelling has not been investigated previously.

During studies of the effect of hypophyseal hormones in regulation of skeletal growth and remodelling, MSH has now been found to influence bone tissue. The cortical bone remodelling along the femur diaphysis was studied both in normal, hypophysectomized and hormone-treated hypophysectomized rats. In normal rats a low periosteal and endosteal apposition was found. In hypophysectomized rats there was an increased periosteal resorption and an increased endosteal apposition. Administration of α -MSH to hypophysectomized animals decreased the periosteal resorption, but had no effect on the endosteal apposition. Administration of growth hormone (GH) to hypophysectomized rats decreased the periosteal resorption to the same degree as MSH. The endosteal apposition was not changed. Thyroxine in low doses resulted in some decrease in the periosteal resorption, but in higher doses thyroxine instead increased the resorption, i.e. increased the effect of hypophysectomy. Endosteally no effect was found. Adrenocorticotrophic hormone (ACTH) did not influence the periosteal resorption and had only a minor effect endosteally. α -MSH did not influence the longitudinal bone growth in hypophysectomized rats, whereas GH and thyroxine stimulated the longitudinal bone growth. Thus, MSH was found to have a growth-hormone-like effect on cortical bone remodelling, but no influence on the longitudinal bone growth in hypophysectomized rats. Further investigations are in progress. These results might lead to a synthetic bone stimulating substance for clinical use.

SECRETION OF CALCITONIN IN RELATION TO TRAUMA

Arne Ekeland & Kaare M. Gautvik
Rikshospitalet, Oslo, Norway

Specimens of a thyroid medullary carcinoma (MCT) were transplanted beneath the kidney capsule in young Wag/Rij rats. The concentration of calcitonin (CT) in plasma collected during the operation was significantly higher ($2\alpha < 0.05$) than in the controls (Figure 1). As MCT produces CT, the transfer of the tumour tissue may be the source of the increased plasma CT. However, another explanation may be that the surgical trauma causes this rise in plasma CT.

In order to test this possibility, a standardized mid-diaphyseal femoral fracture was made in adult Wag/Rij rats. Twenty-five minutes after the fracture, CT in plasma was significantly higher ($2\alpha < 0.01$) than CT in plasma collected before the fracture. In Wag/Rij rats of the same age with a transplanted MCT and a high circulating level of

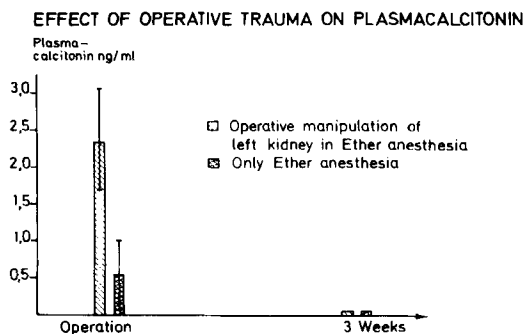


Figure 1. Median with 25 and 75 percentiles in seven operated rats and five controls. After 3 weeks, CT < 0.05 ng/ml in both groups.

CT, femoral fractures did not change the plasma concentration of the hormone.

In conclusion, plasma concentration of CT increases following trauma in normal rats.

EFFECTS OF OXYTETRACYCLINE ON THE MECHANICAL PROPERTIES OF BONE AND SKIN IN YOUNG RATS

Lars B. Engesaeter

Rikshospitalet, Oslo, Norway

Published in *Acta (Acta orthop. scand.* **49**, 529-534, 1978).

THE RESULTS OF OPEN REPOSITION OF LATE DIAGNOSIS CONGENITAL HIP DISLOCATIONS

Flemming Jørgensen & Erik Hørlyck

Orthopaedic Hospital, Århus, Denmark

At the Orthopaedic Hospital in Århus, in the period from 1948 to 1972, open reposition of 159 hips with late diagnosis congenital hip dislocation was performed. There were 129 patients, 30 of whom were operated bilaterally. Eighty-nine per cent of the patients were girls.

The surgical procedure comprised capsuloplasty, after removal of obstructing substances in the acetabulum. Subtrochanteric derotation osteotomy was performed at the same operation in cases of anteversion of more than 40 degrees.

Re-examination of 88 patients showed excellent X-ray results in 67 per cent of the cases (Severin's groups I and II). Arthrotic changes occurred in 32 per cent. Ninety per cent had normal or slightly reduced activity, 75 per cent had no substantial pain and almost normal mobility. Increasing hip disability is, however, to be expected with increasing age.

STANDARDIZED TEMPORARY PROSTHESIS WITH TOTAL CONTACT SOCKET FOR BELOW-KNEE AMPUTEES

Björn M. Persson

General Hospital, Lund, Sweden

Immediate fitting of geriatric patients after amputation has now been replaced by early fitting in most clinics. The tulip limb is constructed to be a one-size ready made device with a total contact socket for early training and testing, which can be carried out by the physiotherapists. The total contact socket is achieved by evacuation of air from a plastic bag, containing plastic balls, which has been wrapped around the stump after removal of the plaster shell 2 weeks after the amputation. The first clinical series with this so-called Tulip limb (Lic, Sweden) comprises 30 patients who used the limb for 12 days. The device was found to be well tolerated.

THE UNNA PASTE BANDAGE AFTER AMPUTATION

Tor Hierton

Academic Hospital, Uppsala, Sweden

In the treatment of chronic leg ulcers the Unna Paste Bandage is well known. However, its use after amputation surgery seems to be new. My interest in the method was directed by Ghiulamila (Albany Medical Center, New York) in 1973. I have used it for almost 5 years after lower limb amputations and would like to recommend that it be used routinely. It is a light and flexible but inextensible dressing which prevents oedema and maintains the stump shape. When used for early prosthetic fitting it acts as an inner liner for the temporary plaster or plastic socket to which a pylon is attached. In this respect the semi-rigid dressing has many advantages not found in the plaster technique of IPOPF.

ORTHOPAEDIC REHABILITATION AFTER OPEN FEMORAL FRACTURE AND ARTERIAL INJURY

Film (16 mm English text)

T. Hierton, A. Wigren & L. Marsh

University Hospital, Uppsala, Sweden

Primary treatment after a gun shot injury was successful as far as saving the limb was concerned. However, malunion with varus deformity, shortening, loss of sensation distally and restricted foot mobility caused permanent disability. Functional improvement was obtained after BK amputation, semi-rigid postoperative dressing with Unna Paste Bandage and early fitting with a PTB prosthesis.

The film shows the effectiveness of the Unna Paste Bandage in maintaining the shape of the stump and preventing oedema. From a bio-mechanical point of view it was necessary to align the prosthetic shank in valgus. This allowed the patient when walking to use an ordinary angle of adduction in his hip joint.

TIBIAL OSTEOSYNTHESIS WITH THE LANE PLATE AND WITH AO COMPRESSION OSTEOSYNTHESIS. A COMPARISON

Jacob H. Kjaer, Esben Møller, Ove Rasmussen & Claus Kromann-Andersen
Århus Community Hospital and Odense Hospital, Denmark

One hundred and seventy-seven tibial fractures osteosynthesized with Lane plates and 116 tibial fractures treated with AO compression osteosynthesis were compared with regard to complications and healing.

There were no definite differences between the two groups as regards primary wound infections whereas there was a two to three times higher frequency of osteitis in the AO group. The frequency of skin necrosis was the same in both groups and there was no marked difference between the two groups as regards healing. A somewhat higher frequency of refractures was found in the Lane group.

ANTIBIOTIC PROPHYLAXIS IN COMPOUND AND CLOSED FRACTURES. A CONTROLLED STUDY

Bo R. Bergman
Östra Hospital, Gothenburg, Sweden

To be published in Acta.

THE FREQUENCY OF OSSEOUS COMPLICATIONS IN TIBIAL SHAFT FRACTURES TREATED BY INTERNAL COMPRESSION OSTEOSYNTHESIS

K. D. Kristensen
Hjørring Hospital, Hjørring, Denmark

Ninety-two tibial shaft fractures in 90 patients over the age of 15 were treated by compression osteosynthesis according to the AO method, but using plates and screws of vitallium. Fifteen fractures (14 patients) are excluded, because they have not been followed at least 12 months. The frequencies of osseous complications in the remaining 77 fractures, 39 per cent comminuted and 30 per cent open fractures, were:

Osteitis	1.3%
Delayed osseous healing necessitating secondary operation	2.6%
Loosening of screw (no secondary operation)	5.2%
Loosened screw + refracture	1.3%
Bent plate	1.3%
Plate fractures	1.3%
Refracture after removal of plate (new relevant traumas)	4.8%

OSTEOGENIC ACTIVITY OF FREE PERIOSTEAL AND OSTEOPERIOSTEAL GRAFTS AND THEIR USE IN THE TREATMENT OF INFECTED PSEUDARTHROSES OF LONG BONES

V. Ritsilä, M. Poussa & L-E. Laurent
Orthopaedic Hospital of the Invalid Foundation, Helsinki, Finland

Earlier studies have shown that free periosteal grafts from the tibia transplanted into muscle in rabbits and employed in fusion of scoliotic spines have a strong osteogenic capacity. Experience revealed that osteoperiosteal grafts were more easily handled than bare periosteal grafts. Therefore the effect of the cortical bone attached to the periosteum was evaluated. Experimentally it was found that in 6-week-old rabbits periosteum alone and 100 μ thick osteoperiosteum had almost equal osteogenic properties, whereas 200 μ thick osteoperiosteum was inferior to both.

In humans a thin osteoperiosteal graft from the healthy tibia was transplanted into 15 infected pseudarthroses of the contralateral femur and lower leg. At the same time reconstruction of the soft tissue defects was performed. Immobilization in plaster was continued until consolidation was established, in the majority of cases within 2-4 months.

RELIEF OF SUDECK'S POSTTRAUMATIC SYNDROME BY FASCIOTOMY

Einar Sudmann
University of Tromsø, Tromsø, Norway

Distal fasciotomy on the volar aspect of the forearm or the ventral aspect of the lower leg gave rapid relief from pain at rest in eight out of nine patients operated on. These eight patients all became symptom-free except one, in whom the normal function of a preoperatively stiff hand could only partly be restored. In contrast, two out of three patients treated with physiotherapy alone ended up with a painful paretic leg and a useless stiff and painful hand.

On the basis of clinical observations of 12 consecutive patients it is suggested that the flexor

retinacula of the wrist and the extensor retinaculum of the lower leg may constitute a pathogenic factor in Sudeck's posttraumatic syndrome of the hand or foot.

OSTEOSYNTHESIS OF FRACTURE OF THE FEMORAL NECK WITH FOUR AO COMPRESSION SCREWS

Henning Paaby, Uffe Niebuhr-Jørgensen, Torben Johansen & Leif Thuesen

Central Hospital, Nykøbing F., Denmark

To be published in Acta.

PHYSIOLOGICAL WEIGHT RELIEF DURING THE TIME BEFORE FRACTURE UNION FOLLOWING INTERNAL FIXATION OF UNSTABLE TROCHANTERIC FRACTURES

J. Steen Jensen & Erik Jansen

Gentofte Hospital, Hellerup, Denmark

To be published in Acta.

THE MORTALITY AFTER HIP FRACTURES

J. Steen Jensen & Erik Tøndevold

Gentofte Hospital, Hellerup, Denmark

Published in Acta (*Acta orthop. scand.* **50**, 161-168, 1979).

THE SOCIAL PROGNOSIS AND THE CONSUMPTION OF RESOURCES FOLLOWING HIP FRACTURES

J. Steen Jensen, Erik Tøndevold & P. Hove Sørensen

Gentofte Hospital, Hellerup and Frederiksborg County Hospital, Hillerød, Denmark

To be published in Acta.

DISTAL FEMORAL FRACTURES. AN 8-YEAR STUDY

Lars Kolmert & Krister Wulff

University Hospitals, Malmö and Lund, Sweden

One hundred and thirty-five patients with 137 fractures were treated in the period 1969-1976. Pathological and osteochondral fractures and fractures in children were excluded. The frequency study showed one peak in the age group 16-25 years, usually involving violent trauma; another peak was seen in the age group 66-75 years where many had osteoporosis. Classification into supracondylar (extra-articular), biocondylar and unicondylar fractures was made. A fall at ground level was the cause in 88 and traffic accidents in 30 patients. Sixty-five per cent had predisposing local or general osteoporosis (earlier fracture,

gonarthrosis or coxarthrosis, ethylism, epilepsy, hemiplegia, polio etc).

Eighty-nine were conservatively and 48 surgically treated. Angle plates, rushpins and screws were the most frequently used methods of fixation. Only plates gave osteosyntheses stable enough for immediate postoperative training. This method gave good results in young patients with normal bone. The other methods needed supplementary external stabilization with traction or plaster.

The results were graded according to pain, mobility, limp and diminished limb length. Excellent and good results were obtained in 65 per cent both in the operated and the conservatively treated groups. Indications differ however.

FRACTURES OF THE CALCANEUM

P. Slätis, O. Kiviluoto, S. Santavirta & E. Laasonen

Surgical Hospital, Helsinki, Finland

Sixty-seven patients with 86 fractures of the calcaneum were re-examined 2 to 5 years after the accident. Forty-seven patients had multiple injuries. Mean age was 39 years and men outnumbered women by 3 : 1. The posterior subtalar joint of the calcaneum was involved in 73, with dislocation and/or comminution in 63; ten fractures were compound. The fractures of the calcaneum were treated predominantly by support, elevation and exercises, or by reposition of the fracture with a Steinmann pin and incorporation in plaster. At follow-up, only 28 patients were symptom-free. Ten patients had subsequently been treated with a subtalar or triple arthrodesis, only one of which was entirely painless with a good functional result. Analysis of the series revealed that the functional result corresponded with the severity of comminution and the depression of the posterior subtalar joint, that functional treatment gives slightly better results than immobilization in plaster, that attempts to reduce the depressed fracture with a Steinmann pin usually fail, and that painful abutment of the peroneal tendons is frequent, especially in fractures with a depressed subtalar joint.

RUPTURE OF THE LATERAL LIGAMENTS OF THE ANKLE. A CONTROLLED CLINICAL TRIAL

Tore Grønmark, Odd Johnsen & Odd Kogstad

Telemark Central Hospital, Skien, Norway

To be published in Acta.

EXTERNAL FIXATION OF UNSTABLE PELVIC FRACTURES

Erik B. Riska, Henrik von Bonsdorff, Sirkka Hakkinen, Heikki Jaroma, Olli Kiviluoto & Timo Paavilainen

University of Helsinki, Helsinki, Finland

Hoffman's external fixation was used in 56 cases to stabilize unstable pelvic fractures in patients with multiple injuries. Under general anesthesia three Hoffmann's screws were fixed to the iliac crest, and the dislocated pelvis was reduced and fixed with one single tie bar.

The reduced position was maintained in 48 out of 51 cases. A good position was achieved in 30 cases. In 16 cases a residual dislocation of less than 1.5 cm was noted at the radiographic examination after the reduction. The position was maintained in these cases too. In three cases a minor redislocation was noted later.

Few complications could be attributed to the method of external fixation. The iliac crest was fractured in one case, infection was noted in one case, and there was one case of exostosis of the iliac crest.

Forty-three patients were symptom-free as regards the pelvis at the time of the last follow-up examination, whereas five patients had residual pains and three diffuse symptoms. The method is simple but needs two surgeons at the time of reduction and fixation of the pelvis.

OPERATIVE CONTROL OF MASSIVE HEMORRHAGES IN COMMUNUTED PELVIC FRACTURES

Erik B. Riska, Henrik von Bonsdorff, Sirkka Hakkinen, Heikki Jaroma, Olli Kiviluoto & Timo Paavilainen

University of Helsinki, Helsinki, Finland

In 42 patients, massive hemorrhages following comminuted pelvic fractures were treated by direct operative intervention through middle line, Pfannenstiel's, anterior iliac crest-femoral, or posterolateral approaches, or using a combination of these. The superior and inferior gluteal, pudendal and obturator arteries were the usual sources of the bleeding. Bleeding from the pelvic bone tissue was of minor importance.

The first step in the procedure was removal of blood clots and hematomas. Local tamponade was applied and in severe cases compression of the abdominal aorta was indicated for short intervals. All big arteries and veins which were bleeding were ligated or reconstructed.

An average of 9 units of blood was given to each patient before surgery and 30 units during or

after the procedure. To all 42 patients, a total of 1640 units of blood was given, every sixth unit as fresh blood. This necessitated a very good blood bank service.

There were 12 deaths, but only three were attributable to the massive hemorrhage from the pelvic region. The remaining deaths were caused by concomitant injuries.

These results support the view that massive hemorrhages in pelvic fractures should be treated by direct surgical intervention.

STABILITY AFTER COMPRESSION OF PELVIC FRACTURES WITH THE HOFFMANN INSTRUMENT

Ian F. Goldie, Björn Gunterberg & Pär Slätis
Sahlgren Hospital, Gothenburg, Sweden and
Surgical Hospital, Helsinki, Finland

Published in *Acta (Acta orthop. scand.* **49**, 278-286, 1978).

BRIEF OUTLINE OF TREATMENT OF PELVIC FRACTURES

Ian F. Goldie
Sahlgren Hospital, Gothenburg, Sweden

Pelvic fractures are sustained when violent forces hit the body. Of all fractures 3 per cent are pelvic. In two-thirds of all pelvic fractures other serious injury is present. The mortality rate is at present 10 per cent. The treatment is both general and local.

The *general* treatment should be directed against bleeding, complications from the urinary tract and respiration. Bleeding occurs from large vessels and from the fracture surfaces. Rupture of the urethra must be diagnosed and precautions against DIC must be taken at an early stage.

The *local* treatment depends on which zone is fractured. Non-weight-bearing zones can be treated conservatively with bed-rest, traction or early mobilization. Weight-bearing zones should preferably be treated by fixation with screws, plate and screws, wires or external fixation.

PELVIC INSTABILITY AFTER FRACTURE AND PARTURITION

Gert Walheim
Karolinska Hospital, Stockholm, Sweden

A new method has been developed to measure movements in the pelvis. A pin is inserted on

either side of the symphysis pubis with two transducers connected to an XY-recorder. Movements registered in fresh cadavers ranged from 0.0–0.5 mm and in patients with suspected pelvic instability from 1.5–10 mm. In such cases temporary external fixation with the Hoffmann instrument can be of great help in confirming diagnosis.

ACETABULAR FRACTURES

Allan J. Aho, U. Isberg, K. Katevuo & S. Einola
University of Turku, Turku, Finland

To be published in Acta.

FRACTURES OF THE THORACOLUMBAR (Th₁₂-L₁) SPINE

M. Härkönen, P. Lepistö, L. Keski-Nisula, T. Paakkala, H. Päätiälä & P. Rokkanen
University of Tampere, and Tampere Central Hospital, Tampere, Finland

Out of 149 patients treated for fractures of the thoracolumbar spine, 101 were followed up after an average of 5 years. The mean age of the patients was 47 years. Fractures of Th₁₂-L₁ constituted the largest group of fractures of the spine. Over half the fractures were sustained in the home or during leisure hours. Almost two-thirds were wedge fractures. One patient died of other injuries, three developed paraplegia and six developed other neurological symptoms. The treatment was mainly conservative. The patients were mobilized after 15 days on average. No neurological or radiological impairment was observed. Two-thirds of the patients considered the end result to be at least good. 90 per cent of the patients maintained their working capacity. Degenerative changes already present impair the end results.

POSTERIOR FUSION OF THE LUMBOSACRAL SPINE. Evaluation of the operative results and the influencing factors.

T. Tunturi, M. Kataja, L. Keski-Nisula, M. Lapinsuo, P. Lepistö, T. Paakkala, H. Päätiälä & P. Rokkanen

University of Tampere and Central Hospital, Tampere, Finland

To be published in Acta.

LOW BACK PAIN – SICK-LEAVE AND WORKING ENVIRONMENT

Jan Hansson, Alf Nachemson & Birgitta Vällfors
Sahlgren Hospital and Lundby Hospital, Gothenburg, Sweden

Fifty patients, employed full-time and aged between 16 and 65, who had been reported sick to the National Health Insurance Service, Gothenburg, due to low back disorder, were selected at random and subjected to a clinical examination at home. This has given us information about the patients' medical and social conditions on the day of illness. The intention of the examination was to survey the working environment and its eventual influence on low back disorders.

Of the 50 patients, 40 per cent showed no objective signs of low back disorder, but some complained of pain especially when under stress. Thirty-six per cent were of the opinion that poor working conditions had prevented them from returning to work. There was no difference with regard to psycho-social factors and work conditions between those with and those without objective findings. However, patients without objective symptoms had more frequent short sick-leave periods due to back pain.

FRACTURES OF THE CERVICAL SPINE

M. Härkönen, L. Keski-Nisula, P. Lepistö, T. Paakkala, H. Päätiälä & P. Rokkanen
University of Tampere, and Central Hospital of Tampere, Tampere, Finland

Sixty-seven out of 119 patients with fractures of the cervical spine were followed up for an average of 5 years and 5 months. The mean age of the patients was 39 years. Motorcar drivers and passengers constituted the largest group (51). Thirty-six patients had sustained fractures of more than one cervical vertebra. Neurological symptoms were observed in 59 cases; 19 of them had tetraplegia. The average duration of hospital treatment was 37 days. Intensive care was given in 24 cases. Skull traction was used in 71 cases for an average of 38 days. Anterior fusion was performed on 13 patients. Five of them had dislocated fracture of the vertebral body and five had luxation. Nineteen patients died of their injuries and seven became permanently disabled. Half the patients had no pain and one-third had no symptoms.

POSTERIOR FUSION IN INSTABILITY OF THE CERVICAL COLUMN IN RHEUMATOID ARTHRITIS AND FRACTURES

Ian F. Goldie, Bo Althoff, Carl-Axel Carlsson & Claes von Essen
Sahlgren Hospital, Gothenburg, Sweden

Since 1972, 39 patients have been treated with posterior fusion of the cervical column: in 29 cases – 17 rheumatoid patients, 9 trauma and 3 os odontoideum – a high fusion has been carried out. The technique of fusion involved the fixation of the atlas to the axis by a wire running around the posterior arch of the atlas and fixed over a rush-pin drilled transversely through the spinal process of the axis. The occiput has not been involved except in three cases in which a vertical dislocation of the odontoid process into the skull had occurred. In the remaining 10 cases – 2 rheumatoids and 8 trauma – fusion has been carried out at a lower level.

At follow-up with an observation time of more than 1 year it was found that the clinical function was in all cases most satisfactory and radiological examination with provocation of the cervical column in flexion and extension showed that complete stability had been obtained.

FRACTURES IN PATIENTS WITH RHEUMATOID ARTHRITIS

Håkan Brattström
University Hospital, Lund, Sweden

Patients with rheumatoid arthritis usually have osteoporotic bones, a condition often aggravated by steroid treatment. This means that even a very minor trauma during everyday activities or during treatment (surgery under anaesthesia or physiotherapy) may cause a fracture. The diagnosis of these fractures may be missed, because of lack of adequate trauma and the fact that the patient as well as the staff are used to the patient always having some degree of pain. The osteoporotic bone and the tendency for these patients to get stiff during external fixation call for unconventional treatment of the fracture.

TORQUE STRENGTH OF EXPERIMENTAL FRACTURES TREATED BY PLATE FIXATION WITH AND WITHOUT COMPRESSION

T. Holmström, P. Slätis, E. Karaharju & P. Paavolainen
Surgical Hospital, Helsinki, Finland

Transverse osteotomy was performed on both tibiofibular bones in 70 rabbits. The right side

was stabilized with a commercial DPC plate using compression, the left side with a similar plate without compression. In 20 animals both fractures healed uneventfully, and these formed the series. No essential difference in healing pattern was observed macroscopically, radiographically or microscopically between fractures treated with compression and those treated without. Torque strength was measured 3, 6, 9, 12 and 24 weeks after osteotomy. In both groups strength initially increased, approaching normal values during the first 9 weeks; after this the torque strength gradually decreased. The increase in strength reflected the formation of new bone in the fracture area, the subsequent decrease, porotic transformation of the bone under the rigid plate. There was no difference in torque strength between the plated fractures treated with and without compression.

A BIOCHEMICAL STUDY OF THE STRENGTH OF IMPLANTS OF THE JEWETT AND McLAUGHLIN TYPE

J. Steen Jensen
Gentofte Hospital, Hellerup, Denmark

To be published in Acta.

FIBRE METAL PROSTHESIS IN SEGMENTAL REPLACEMENT OF LONG BONES IN BABOONS AND HUMANS

Gunnar B. J. Andersson, André Gaechter, Jorge Galante & William Rostoker
Sahlgren Hospital, Gothenburg, Sweden; Rush-Presbyterian, St Luke's Medical Center, Chicago; Gothenburg and University of Illinois, Circle Campus, Chicago, USA

Forty-three resections of major segments of long bones have been performed on 38 baboons, and the defect replaced by sintered titanium fibre metal prostheses. Satisfactory bridging of the prosthesis with bone occurred when autologous bone was grafted. Endosteal bone ingrowth occurred readily into the pores of the titanium fibre composite. The bone was mature and no fibrous tissue membrane was observed between bone and metal. No abnormal tissue reactions were seen. Similar prostheses have been used to replace resected segments for long bones in patients with tumors or loss of bone due to trauma. The results so far are satisfactory.

GAS TENSIONS AND INTRAOSSEOUS PRESSURE IN THE LONG BONES OF THE ANESTHETIZED DOG

Erik Tøndevold, Jørgen Eriksen & Erik Jansen
Gentofte Hospital, Hellerup, Denmark

The influence of the mean arterial blood pressure and arterial gas tensions upon the intra-medullary pressure in the epiphysis, metaphysis and diaphysis were investigated. It was found that the normal range of medullary pressure was 15–30 mmHg, and this remained constant as long as the mean arterial pressure exceeded 80 mmHg. When the arterial pressure was below this limit, a decrease in medullary pressure down to 4–6 mmHg was measured.

Among the blood gases only oxygen had any influence on the medullary pressure. When arterial oxygen tension was below 100 mmHg a significant decrease was found in the medullary pressure in all parts of the long bones. Carbon dioxide, pH and standard bicarbonate concentration had no influence upon medullary pressure.

INTRAOSSEOUS PRESSURE, BONE DENSITY AND ROENTGENOLOGICAL AND CLINICAL FINDINGS IN PRIMARY OSTEOARTHRITIS OF THE HIP JOINT

Niels B. Termansen & P. Stubbe Teglbjerg
Odense University Hospital, Odense, Denmark

In 108 patients with primary osteoarthritis of the hip joint the intraosseous pressure of the femoral head and the greater trochanter was measured prior to total hip reconstruction. The intraosseous pressure of the femoral head (mean 49.6 mmHg) was significantly higher than that of the greater trochanter (mean 31.6 mmHg), with a positive correlation between the two. A considerable variation was found in the pressures of the femoral heads with a distribution not differing significantly from a normal distribution. There was a slight positive correlation between intraosseous pressure and mean arterial blood pressure, but intraosseous pressure was not influenced by sex and age. No association was found between the intraosseous pressure of the femoral head and the severity of osteoarthritis as judged by roentgenological and clinical criteria or between intraosseous pressure and bone density of the femoral head.

The results of this investigation do not support the hypothesis of intraosseous hypertension as a pathogenetic factor in primary osteoarthritis.

OSTEOARTHRITIS OF THE HIP: EPIDEMIOLOGY AND CLINICAL ROLE

Knud Jørring
Hvidovre Hospital, Denmark

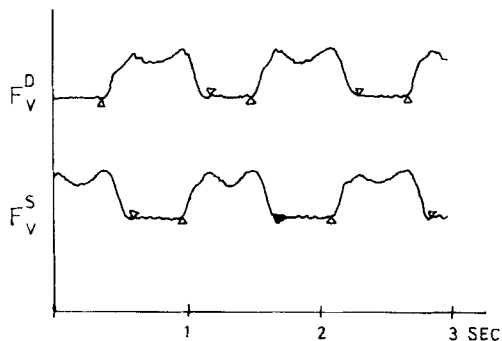
Among 6321 patients who had undergone X-ray examination of the colon 4.7 per cent were found to have radiological osteoarthritis of the hip. The female : male ratio was 3 : 2.

A follow-up was made of the patients with radiological osteoarthritis of the hip; one-half had no complaints or only mild ones. In keeping with the fact that osteoarthritis was more severe in the women than in the men, the women fared the worse. They had more often to apply for disablement pension, had more severe pain, and were more handicapped in activities of daily living.

THE NORMAL GAIT: MEASUREMENT OF FORCES AND THE TIME RELATIONS TO FOOT-TO-GROUND FORCES

Erik Jansen, Jens Erik Pedersen & Knud Jansen
Gentofte Hospital, Hellerup, Denmark

An instrumented treadmill has been used to measure the foot-to-ground forces for each foot during continuous walking. Using an electronic computer the heel-on (in the figure indicated by Δ) and toe-off (in the figure indicated by ∇) is calculated. In this way swing phase, stance phase and stride length are determined. By comparing the vertical force of the left foot and the right foot right and left step and double support times can be calculated. In a series of 14 normal persons walking with an increasing speed of 2 to 6 km/h a linear increase in stride length was found. In the same study it was found that stance phase decreases, swing phase increases and double support times increase.



ELBOW CRUTCHES – A NEW DESIGN TO AVOID PRESSURE ON THE PALM AND ALLOW A NORMAL GAIT

Bent Barfod

Århus Hospital, Århus, Denmark

To be published in Acta.

NINE REIMPLANTATIONS

T. Barfred & J. Pless

Odense Hospital, Odense, Denmark

Starting reimplantation less than a year ago we decided that our indications should be: (1) amputation of a thumb (2) amputation of 2 or more fingers (3) amputation of a large part of the hand or whole hand (4) a fairly tidy lesion and (5) age below 50.

Nine patients (8 men and 1 woman) were treated for: subtotal amputation of the thumb (1), total amputation of the thumb (4), amputation of a part of the hand (2) and amputation of 3 fingers (2). We had three failures. One was a tidy thumb amputation in a 55-year-old man. Another failure was a severely torn thumb which survived 3 days and the third was a tidy amputation of 3 fingers in a young girl. Part of the reason for the latter failure was insufficient shortening of the bone. The indications seem reasonable for starting a reimplantation programme.

CENTRALIZED ORTHOPAEDIC ONCOLOGY-TUMOUR SUSPECTED – WHAT WAS THE FINAL DIAGNOSIS?

Anders Rydholm & Björn M. Persson

University Hospital, Lund, Sweden

Orthopaedic oncology in Sweden is centralized to four hospitals. The southern region comprises 1.5 million inhabitants and is served by Lund. Orthopaedic surgeon, pathologist, cytologist, oncologist and diagnostic radiologist examine once a week patients referred because of suspicion of a malignant tumour. Through 1974–76, 381 cases were evaluated. Skeletal sarcoma was diagnosed in 16 cases. In nine patients with myeloma and 24 with cancer metastasis the skeletal destruction was the first sign of malignant disease. Among the other skeletal lesions one half were benign tumours or tumour-like lesions. In the other half were 16 skeletal infections.

Soft tissue sarcomas were diagnosed in 31 patients. In a further 20 cases of soft tissue sarcomas the patients were referred to us with the

diagnosis already made. Among the other soft tissue lesions one half were benign tumours.

Sarcoma in the locomotor system is rare and centralized care of these patients is therefore important. Radical surgical therapy is easier if the tumour has not been previously exposed. This means that patients with a suspected tumour should be referred for evaluation by a specialist team of orthopaedic oncologists, preferably before a biopsy has been performed. The result of such a policy is described.

PATHOLOGICAL FRACTURES. A REVIEW

Erkki V. S. Koskinen

Central University Hospital, Helsinki, Finland

Pathological fractures are most often due to metastatic cancer from the breast, lung, kidney, etc. The fracture treatment is palliative, its aim being to achieve stability of the bone with the aid of osteosynthesis or endoprosthesis, relieving pain, giving mobility and facilitating the general nursing. Sixty per cent of 45 patients were rapidly released from confinement to bed. Only 14 per cent were alive after 1 year. Reliable prognosis appears difficult in individual cases.

Other common causes of pathological fracture are: myeloma, benign fibrocystic tumours or tumour-like states, and occasionally primary bone tumours such as giant cell tumour and osteogenic sarcoma. A pathological fracture may be the first sign of a tumour.

PATHOLOGICAL FRACTURES IN BENIGN BONE TUMOURS AND TUMOUR-LIKE CONDITIONS IN CHILDREN

A. Alho & T. S. Raugstad

Haukeland Hospital, University of Bergen, Bergen, Norway

During the 5-year period 1972–76, a survey was made of the frequency of pathological fractures in children in a region with 350,000 inhabitants. Fifteen patients with bone tumours presenting as pathological fractures were admitted to the central institutions. During the same period, five new cases of osteogenesis imperfecta with fracture were found. Most of the tumours were unicameral bone cysts. In addition, two eosinophilic granulomas, three non-ossifying fibromas and one fibrous dysplasia were diagnosed. When the radiological diagnosis of a benign condition was made with certainty, the treatment was ex-

pectant, in order to determine the optimal time for treatment, or to decide on non-treatment. If the least doubt existed, a biopsy was taken close to the normal bone and far from the fracture.

PATHOLOGICAL FRACTURES FOLLOWING KIDNEY TRANS- PLANTATION

Rolf Hagen

Martina Hansens Hospital, Sandvika, Norway

Bone necroses, pathological fractures and probable affections of the epiphyseal growth plates have been recognized in association with corticosteroid therapy after kidney transplantations. The risk of developing these lesions seems to correlate with the total steroid dose. A subchondral fracture through osteonecrotic cancellous bone of the femoral head may be detected at an early stage by tomography and is called the crescent sign.

SPONTANEOUS FRACTURES IN THE HIP AND SHOULDER JOINTS

Stefan Haraldsson

University Hospital, Reykjavik, Iceland

A 30-year-old man with a spontaneous subchondral fracture in the femoral head was treated with bone nails introduced through the articular cartilage. Four months later the fracture healed and function was restored.

A 40-year-old female had a hydatid cyst in the humerus with destruction of the proximal half of the humerus and a spontaneous fracture. An earlier solution to such a problem resulted in the author's design of a "muscle-sling" humeral prosthesis (*Acta orthop. scand.* **40**, 225, 1969) for reconstruction of the proximal half of the humerus and the shoulder joint.

A 24-year-old man had a spontaneous fracture in a juvenile cyst engaging the collum, caput and trochanter major in the femur. The destruction was too extensive for reconstruction of bone. A Moore arthroplasty was performed with cementation of the prosthesis to the femur. At follow-up 5 years postoperatively the patient was back to full-time work without signs of recurrence.