

PROCEEDINGS OF THE SWEDISH ORTHOPAEDIC ASSOCIATION

Stockholm, May 25-26, 1978

EDITOR: PETER HERBERTS

GUEST LECTURE:

THE ROLE OF THE RESURFACING
ARTHROPLASTY IN THE TREATMENT OF
OSTEOARTHRITIS OF THE HIP
S. David Stulberg

Department of Surgery (Orthopedics),
Chicago, Ill., USA

The Resurfacing Arthroplasty was developed to avoid the femoral stem problems of the conventional THR — loosening and breakage. Patients most suitable for a Resurfacing Arthroplasty are those "at risk" as regards loosening or breakage of the stem of a conventional femoral component or with a greater than usual risk of developing an infection.

Absolute contraindications are active infection or marked loss of bone stock from the femoral head and/or neck. Relative contraindications are extensive avascular necrosis, open femoral epiphysis, severe leg-length discrepancy, neuromuscular abnormality or acetabular protrusion.

Advantages are elimination of femoral stem problems, not having to invade the medullary canal, and the opportunity to perform salvage procedures.

Results are equal to those with the conventional THR.

Disadvantages are the need to vigorously ream the acetabulum; possibly increased heterotopic bone formation; the need for more postoperative physical therapy; the potential risk of component loosening and femoral neck fractures; and a somewhat more demanding surgical technique.

AUTO-TRACTION® IN THE TREATMENT
OF LOW BACK PAIN AND SCIATICA: A
MULTICENTRE, CONTROLLED STUDY OF
82 PATIENTS

*U. Larsson, U. Chöler, A. Lidström, G. Lind,
A. Nachemson, B. Nilsson & J. Roslund*

Departments of Orthopaedic Surgery at Malmö,
Gothenburg, Skövde, Danderyd and Nacka
Hospitals, and at Karolinska Hospital, Stockholm

Patients with low-back pain and sciatica were randomly allocated to two equal treatment groups: 1) Auto-traction with Lind's multiplane table, and 2) Brace. Treatment was given by six orthopaedic surgeons who had received 5 days training in Auto-traction. Each patient received up to three treatments, all within 5 days. After 1 week, 15 per cent of the Auto-traction group had recovered completely; a further 27 per cent were rid of either low-back pain or sciatica. Thus, a total of 42 per cent of the group benefited greatly from the Auto-traction. These results are significantly better than for the brace method (only one patient was rid of back pain and one of sciatica). Two weeks later the difference between the two groups had decreased but was still statistically significant. After 3 months there was no difference between the groups with regard to the number of patients with residual symptoms.

Comment (G. Lind): The 1 week available for the treatment may not have been long enough to obtain a cure in some cases. The orthopaedic surgeons applying the Auto-traction had not received the full course of treatment, and lacked experience.

AUTO-TRACTION® IN THE TREATMENT OF CHRONIC LOW BACK PAIN AND SCIATICA

Gertrud A. M. Lind & Gert G. Walheim
 Department of Orthopaedic Surgery, Karolinska Hospital, Stockholm

Ninety consecutive patients received Auto-traction by Lind on her multiplane table during a hospital stay of about 15 days. Clinical symptoms and signs were evaluated by Walheim.

A. 1. Low back pain and sciatica of 1–30 years standing (69 patients)

<i>Physician's evaluation:</i>	On discharge:	No symptoms 63%	Improvement 21%	Total 84%
	Six months later:	No symptoms 75%	Improvement 12%	Total 87%

Patient's evaluation: Total on discharge 89%, 6 months later 86%.

2. Low back pain only (7 patients): Roughly the same results as above.

3. Low back pain and sciatica, previously operated upon (7 patients)

<i>Physician's evaluation:</i>	On discharge:	No symptoms	Improvement	Total
		4 patients	1 patient	5 patients
	Six months later:	No symptoms	Improvement	Total
		3 patients	1 patient	4 patients

B. First-time low back pain and sciatica, onset within 2–12 months (selected group — 14 patients)

<i>Physician's evaluation</i>	On discharge:	No symptoms	Improvement	Total 83%
	Six months later:	No symptoms	1 patient	Total 100%

The patients were instructed as regards "spinal hygiene". 54% showed no decrease in activity level at work, 35% were "back conscious", 6% showed moderate and 5% severe decrease in activity level at work (3% during leisure).

Conclusion: Applied by an experienced physician, Auto-traction, using Lind's multiplane traction table, resulted in a significant improvement in a majority of the patients.

AUTO-TRACTION® IN THE TREATMENT OF CHRONIC LOW BACK PAIN AND SCIATICA: EFFECT ON NEUROLOGICAL SYMPTOMS

Gertrud A. M. Lind

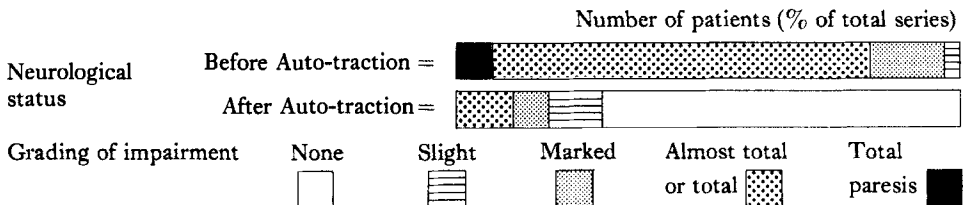
Department of Orthopaedic Surgery, Karolinska Hospital, Stockholm

Ninety consecutive patients with chronic low back pain and sciatica were given Auto-traction treatment on the multiplane table during a hospital stay of about 15 days. Seventy-eight patients had neurological signs (severe in 73 per

cent); four others had L5/S1 syndromes, two with total foot paresis. Myelography was positive in 35 out of 47 cases. In 73 per cent of cases *neurological symptoms* had regressed completely on discharge or at the 6-month follow-up. In 7 per cent slight and in 10 per cent marked neurological impairment persisted.

Recovery of sensation presented the same pattern.

Conclusion: Auto-traction produced complete or partial regression of symptoms in a greater proportion of cases and more rapidly than reported for surgery or other forms of treatment for low-back pain and sciatica.



ACUTE LOW BACK PAIN IN INDUSTRY: A CONTROLLED PROSPECTIVE STUDY WITH SPECIAL REFERENCE TO THERAPY

M. Bergquist-Ullman, U. Larsson & A. Nachemson

A controlled study of 217 patients with low back pain was carried out at a large industrial plant. The effect of a Back School was evaluated and compared with physical therapy and a placebo. The effect of the various therapies was evaluated by comparing 1) the duration of symptoms following the first treatment, 2) the sick-leave period during the current episode of pain and 3) the number and duration of symptoms and the total number of days absent from work in a period of 1 year owing to relapses of pain.

The duration of symptoms following the first treatment was significantly shorter in the Back School group (14.8 days) and the physiotherapy group (15.8 days) compared with the placebo group (28.7 days). Significantly more patients with a shorter duration of sick-leave were observed in the Back School group. The number and duration of symptoms and absences from work owing to relapses of pain did not differ in any of the therapy groups. Patients given the Back School or physiotherapy have a shorter period of pain than patients given "placebo" therapy. The Back School also reduces the average sick-leave during the corresponding pain period.

DENERVATION OF THE INTERVERTEBRAL JOINTS TREATMENT FOR LUMBAGO AND SCIATICA

Olov Lindahl

Department of Orthopaedic Surgery, Regional Hospital, Linköping

The actual source of the pain in lumbago and sciatica remains largely obscure: the herniated disc has not provided the explanation that was expected of it. Rees in Australia considers that the cause usually lies in pathological alterations in the intervertebral joints. He reports that all but 2 out of 1000 consecutive cases of sciatica were cured after resection of branches of the posterior ramus nerve innervating the intervertebral joints. In the remaining two cases relief was obtained after extirpation of the sequestered fragments of a herniated disc.

This method has been adopted at the Linköping University Hospital but with Shealy's modification, in which an electrode is used first for location and then for denervation by coagulation.

The cure rate in 90 patients with long-standing severe postoperative lumbago and sciatica was just under 20 per cent. While this figure is by no means as impressive as that reported by Rees, it does represent a promising result. The surgical method provides interesting information on the route followed by the pain: it seems that it need not be an anatomic one.

PHALEN & DICKSON'S SYNDROME — A FOLLOW-UP

E. Spangfort, J. Sevastikoglou & S. Aaro
Department of Orthopaedic Surgery, Huddinge University Hospital, Karolinska Institutet, Stockholm

The disabling condition caused by simultaneous contracture of the lumbar and hamstring muscles — lumbo-ischio-crural contracture (LIC-contracture) — was described in German literature as "Hüft-Lenden-Streck-Steife", and primarily associated with tumours, inflammation, and disk herniations in the lower back. In 1961, Phalen & Dickson published a series of cases in which the LIC-contracture was caused by spondylolisthesis in adolescence. A number of reports of this syndrome is now available, but experience with surgical treatment is still limited.

At this department ten patients with Phalen & Dickson's syndrome were examined 1.5 to 14 years after operation — 8 girls and 2 boys, mean age at operation 14 years (12–17 years). The operations were anterior fusion (8), laminectomy and posterior fusion (1), and in one case laminectomy without any relief, and after 4 months anterior fusion followed by complete recovery. There were no surgical complications in this series. The result of operation was satisfactory in all cases.

ESTIMATION OF VERTEBRAL ROTATION IN STRUCTURAL SCOLIOSIS BY COMPUTERIZED TOMOGRAPHY (C.T.)

Stig Aaro & Mats Dahlborn

Department of Orthopaedic Surgery, Huddinge University Hospital, Karolinska Institutet, Stockholm

The vertebral rotation has been evaluated in scoliotic patients by a whole body C. T. scanner, using a Δ -Scan 50 FS system (Ohio-Nuclear, Inc.). The operating factors were 140 kV and 20 mA and the slice thickness was 13 mm. Mean absorbed dose 10 mGy per slice.

Measurements were made on the vertex vertebra. The vertebral rotation in the transversal plane was defined as the angle between the line from the posterior central point of the vertebral foramen to the front midpoint of the body and the line from the same point of the vertebral foramen to the midpoint of the vertebral body.

After a short course of instruction, measurements were performed by ten radiologists on five different patients. The variance of the 50 estimations was 1.55°.

The derotatory effect of the Boston brace and the Harrington procedure have been studied by this method in two small series of cases.

SCINTIGRAPHIC AND THERMOGRAPHIC STUDIES OF THE THORAX IN IDIOPATHIC THORACIC SCOLIOSIS

J. A. Sevastikoglou, M. Dahlborn, E. Elmstedt, S. Aaro & R. Levander

Departments of Orthopaedic Surgery and Diagnostic Radiology, Huddinge University Hospital, Karolinska Institutet, Stockholm

To test the hypothesis that scoliosis may be due in some cases to asymmetric growth of the ribs, scintigraphy of the thorax with ^{99m}Tc-MDP was performed in five girls with thoracic scoliosis. No difference in the isotope uptake was observed between the spinal segments, suggesting that there may be no vertebral growth disturbance. A difference in isotope uptake between left and right sided costosternal junctions of the ribs was found in every case; in four of the girls the higher activity was located in the ribs of the concavity. The small number of observations allows no statistical conclusions.

In seven girls with scoliosis the colour-isothermogram of the body was asymmetric both from the front and from the back. No correlation was found, however, between the thermographic image and the characteristics of the scoliosis.

CHOICE OF TREATMENT IN SUBCUTANEOUS ACHILLES TENDON RUPTURE

Lars Nistor

Department of Orthopaedic Surgery, Sahlgren Hospital, Gothenburg

A total of 103 patients with total subcutaneous Achilles tendon rupture were randomly allocated to treatment with either equinus plaster or surgery. Five patients out of 60 non-surgically treated sustained re-ruptures whereas two out of 43 operated tendons re-ruptured. In this second

group two patients had deep infections. The rate of complications in both groups was thus equal.

So far 80 patients have been followed up. There is no difference regarding complaints of weakness or stiffness, sick-leave period, return to sports activities, calf circumference, breadth of tendon or range of motion.

Static and dynamic plantar flexion forces were measured with the Cybex II dynamometer. Small tendencies towards better dynamic force in the non-surgically treated and better static force in the surgically treated were not significant.

The study will be completed with electromyography and muscle biopsies, but so far the conclusion is that non-surgical treatment is adequate and gives a functionally good result.

REOPERATION OF TOTAL HIP REPLACEMENTS IN SWEDEN DURING THE PERIOD 1/1/1976-31/8/1977

L. Ahnfelt, G. B. J. Andersson & P. Herberts

A multicenter study was performed with the aid of a questionnaire to assess reoperations after total hip replacements. The investigation was performed as a basis for a prospective multicenter study. Information from 36 out of 41 Swedish departments of orthopaedic surgery revealed that 5073 hip arthroplasties were performed from 1/1/1976 to 31/8/1977, of which 485 were reoperations. The reason for reoperation was infection in 33 per cent and in another 33 per cent "aseptic" loosening. Both prosthetic components were changed in about 50 per cent, the femoral part in 16 per cent, and the cup in 5 per cent. The diagnosis was primary osteoarthritis in 75 per cent, complications after femoral neck fractures in 13.5 per cent, secondary osteoarthritis in 5 per cent and rheumatoid arthritis in 3.5 per cent.

REARTHROPLASTY OF THE HIP JOINT

Richard Wallensten & Elisabeth Olsson

Department of Orthopaedic Surgery, Karolinska Hospital, Stockholm

Out of 366 total hip replacements performed at the Department of Orthopaedic Surgery, between 1973 and 1977, 53 were a change from one prosthesis to another. Between 1 and 4 years after surgery 43 of these patients were re-examined radiologically and clinically. Ratings were obtained for pain, range of motion, gait, activities of daily life, postoperative complications, radiological signs of loosening and the patient's own opinion of the result. The patients were divided into four groups: 1) change from a McKee/Farrar or Ring pros-

thesis to a Charnley or Müller prosthesis, 2) change from one Charnley or Müller to another of the same kind, 3) change from a Moore or Thompson prosthesis or Smith-Petersen cup to a Charnley or Müller prosthesis. Group 4) is composed of 19 patients who had had three or four changes of prosthesis. The indications for change of the prosthesis were loosening together with pain, infection, recurrent dislocation or stiffness in the hip joint. The results can be summarized as follows: 1/2 of the patients had a pain-free joint after surgery; 2/3 had an acceptable range of motion and gait; 2/3 of the patients also considered themselves improved by the operation. The worst results were found in group 4, the best in group 3.

LATE RESULTS OF REVISION ARTHROPLASTY USING A TOTAL HIP PROSTHESIS

Torkel Welin-Berger

Department of Orthopaedic Surgery, St. Görans Hospital, Stockholm

Results of re-operations of 46 hips, where various surgical interventions were replaced with arthroplasty *ad modum* Charnley or Müller, were presented. There were no contra-indications except for a poor general condition of the patient. There were six cases of infections (13 per cent). Follow-up time was 18–48 months. According to the modified system of Merle D'Aubigné, excellent or good results were achieved in 61, fair in 24 and poor in 15 per cent. It was concluded that re-arthroplasty in an unselected material has a high percentage of failures. Preclusion of hips with deep infections in connection with previous major hip surgery and of patients with a sedimentation rate above 40 mm and of hips with X-ray signs of infection would have improved the results considerably, but would also have excluded some hips that turned out to be among those with good results.

PROPHYLACTIC ANTIBIOTICS AGAINST DEEP INFECTIONS AFTER TOTAL HIP REPLACEMENTS

Acke Jernberger, Sven S. Olsson &

Dagny Tryggö

Department of Orthopaedic Surgery, Norrköping

Since 1969, 400 total hip replacements have been performed without the occurrence of any known primary deep infection. The operations have been done with antibiotic prophylaxis consisting of continuous infusion of 20×10^6 I.U. of

penicillin/d for 3 days and dicloxacillin $0.5 \text{ g} \times 4$ for the following 11 days. 216 out of 238 operations with more than 2 years' follow-up time have been examined with regard to complications and functional results. No definite or suspected deep infection was discovered. Fourteen hips have been reoperated on with exchange of a loose femoral component. All loosening have taken place between bone cement and metal. We have not been able to demonstrate bacterial growth in the tissues surrounding the loosened implants. Varus position and insufficient medial cement support of the proximal part of the stem were constant findings in prostheses, where the femoral component later loosened.

PRELIMINARY RESULTS OF A TRUNNION BEARING PROSTHESIS (CHRISTIENSEN) IN TOTAL HIP REPLACEMENT

Ian Goldie, Christina Johansson, Lars Irstam & Ole Roos

Department of Orthopaedic Surgery, Sahlgren Hospital, Göteborg

The Christiansen prosthesis is based on a trunnion bearing principle which considerably diminishes friction. The prosthetic head is designed according to a bushing principle. A cylindrical sleeve is slipped onto the trunnion. This is covered by a metallic casing in the shape of a sphere. With this system the head remains stationary in the cup on loaded flexion and extension.

Fifty-six patients (representing 61 hips) have been operated on. Forty-nine had osteoarthritis, 10 rheumatoid arthritis and 2 morbus Bechterew. Follow-up was between 6 months and 3 years with a mean of 2 1/2 years. There was complete relief of pain in 45 hips. In eight hips there was slight pain after strain; two hips had persistent pain. There was normal function in 40 hips. Fifteen patients used a cane for long walks. There was one deep infection, one early and one late dislocation, two femoral stem loosening, and ectopic bone formation in 11 hips (no clinical symptoms).

PROSPECTIVE MULTICENTER STUDY OF KNEE ARTHROPLASTIES

Göran Bauer, Kaj Knutson & Anders Lindstrand

Department of Orthopaedic Surgery, Lund University Hospital, Lund

Thirty-five departments of orthopaedic surgery are participating in a prospective study of knee arthroplasties. Data are computerized and

presented twice yearly. 1774 arthroplasties have been registered from October 1975 through March 1978. The incidence of deep infection, loosening, wear and fracture of the endoprosthesis in patients followed up at least 1 year is shown here.

One third of the complications were due to deep infection and two thirds to endoprosthesis problems. Patients and surgeon were satisfied with the 1 year result in 78 per cent of the cases.

Diagnosis	Prosthesis	No.	No. of complications	Prosthesis	
				Reinsertion	Removed
<i>Osteoarthritis</i>	Hinged	29	7	4	2
	Non-hinged	23	3	1	—
	Double unicondylar	18	1	1	—
	Unicondylar	133	9	5	2
<i>Rheumatoid arthritis</i>	Hinged	56	8	2	2
	Non-hinged	58	4	1	1
	Double unicondylar	82	6	2	2
	Unicondylar	21	2	2	—
Total		420	40 (=10%)	18 (=4%)	9 (=2%)

HEMATOGENOUS INFECTION AFTER ARTHROPLASTY: AN EXPERIMENTAL STUDY IN THE RABBIT

Gudmund Blomgren & Urban Lindgren
Department of Orthopaedic Surgery, Huddinge University Hospital, Karolinska Institutet, Stockholm

An experimental model with conditions similar to the clinical ones was designed by using human finger joint endoprotheses as knee joint replacement arthroplasties in the right knees of rabbits. The left knees were used for control operations. Bacteraemia was achieved by repeated intravenous injections of a phage-typed strain of *Staphylococcus Aureus* (S.A.).

Four rabbits died in connection with the bacterial injections and all showed growth of the S. A. strain in the arthroplastic knee joint as well as in the control operated left knees. Ten rabbits were killed 3 weeks after the bacterial injections. Seven showed growth of the S. A. strain in their arthroplastic knee joints but the control operated left knees in these 10 rabbits were sterile.

ARTHROSCOPY — CLINICAL AND TECHNICAL CONSIDERATIONS

Evald Johansson
Department of Orthopaedic Surgery, Karolinska Hospital, Stockholm

A consecutive series of 100 arthroscopies of the knee joint performed by one surgeon has been reviewed. The main indication for arthroscopy

was "the problem knee" or acute injuries. The main arthroscopic diagnoses were meniscal, cruciate and/or capsular lesions. The only therapeutic arthroscopies were three percutaneous removals of loose bodies. In 39 patients, arthrogram, arthroscopy and arthrotomy were performed. In these cases the radiological assessment was correct in 22, and incorrect in 17. In altogether 64 patients arthrotomy was performed after arthroscopy. In 55 there was a complete correlation, three were given an incorrect arthroscopic diagnosis, and six arthroscopic investigations were incomplete, all compartments of the knee had not been assessed. The arthroscopic diagnosis has not been checked by arthrotomy in 36 patients. The reason for the failures is discussed and a standardized method of performing arthroscopy is presented.

AN ULTRALIGHT BELOW-KNEE PROSTHESIS

Peter Herberts & Åke Magnusson
Departments of Orthopaedic Surgery, Östra and Sahlgren Hospitals, Göteborg

A new technique for the fabrication of a light below-knee prosthesis has been developed. The final prosthesis consists of a keel, shank, and socket of polypropylene and an external SACH foot which is glued to the plastic keel. The prosthesis is about two and half times lighter than standard prostheses.

Four patients have been fitted and followed for 1 year. They stated that they use the prosthesis all

day long and are able to look after themselves. The patients comments indicate that the prosthesis is very comfortable and it was obvious that the lighter the prosthesis, the easier it is to suspend it on the limb. The decreased pistoning action with a lighter prosthesis accounts for the good control these very old patients (85-90 years) have over the prosthesis. The impression was gained that the ultralight prosthesis conserved energy when the patient walked in contrast to standard prostheses.

The preliminary results indicate that this prosthesis provides better comfort and at least as good function at a lower cost than conventional prostheses.

DIAPHYSEAL BONE STRENGTH ADAPTATION TO RIGID INTERNAL PLATE FIXATION: AN EXPERIMENTAL STUDY ON RABBITS

F. Sigurdsson, P. Låftman & L. Strömberg
Department of Orthopaedic Surgery, Department of Surgery, Karolinska Hospital, and Department of Experimental Surgery, Karolinska Institute, Stockholm

The development of the adverse effects of a rigid internal fixation plate on the strength (measured as maximum torque capacity) of diaphyseal bone, as well as the recovery of bone strength after the removal of the plate, has been studied on rabbits. Due attention had been paid to the effect of the screw holes. On removal of the plate, which had been applied for 12 weeks without previous osteotomy, the bone had decreased in strength by 50 per cent.

After removal of the plate the bone regained its normal strength after only 6 weeks. Furthermore, contrary to the linearly developed weakening, regaining of strength developed non-linearly.

DIAPHYSEAL BONE AT ULTIMATE FAILURE

Pelle Netz, Kjell Eriksson & Lennart Strömberg
Department of Orthopaedic Surgery and Department of General Surgery, Karolinska Hospital, Department of Strength of Materials and Solid Mechanics, The Royal Institute of Technology, and Department of Experimental Surgery, Karolinska Institute, Stockholm

Using a high speed film technique it has been possible to calculate the propagation speed of fractures in fresh diaphyseal canine bones. The film speed used was 5,000 pictures per second. The fractures were found to propagate with a

speed exceeding 300 meters per second. The calculated speed is not in accordance with plastic deformation in canine diaphyseal bone.

MEDULLARY COMPARTMENT OF DIAPHYSEAL BONE AT TORSION

Pelle Netz, Kjell Eriksson & Lennart Strömberg
Department of Orthopaedic Surgery and Department of Surgery, Karolinska Hospital, Department of Strength of Materials and Solid Mechanics, The Royal Institute of Technology and Department of Experimental Surgery, Karolinska Institute, Stockholm

Entire diaphyseal bones, including the medullary cavity, have so far not been the subject of intensive research, and pressure measurements from the closed compartment of the medullary cavity are only made statically, i.e., measurements of the dynamic process when twisting the bone to final fracture have previously not been performed. Deformation of a diaphyseal bone must be followed by a change in the geometry of the medullary cavity and studies of post-traumatic fat embolism have assumed high pressures either in the medullary compartment or in the muscle compartment outside the diaphyseal bone.

Our studies have shown that there is only a limited pressure rise as the bone is twisted to fracture, but before final fracture when the load-deformation curve turns into a non-linear phase, the medullary pressure decreases to a level considerably lower than that of the intact bone.

HOFFMAN INSTRUMENTATION FOR UNSTABLE PELVIC RING FRACTURE — DISCUSSION

Gert Walheim
Department of Orthopaedic Surgery, Karolinska Hospital, Stockholm

In our department we have studied the special form of pelvic instability after parturition. We have developed a method to measure this instability electro-mechanically. One metal pin is put into the os pubis on each side of the symphysis and the movements between the pelvic halves are registered with two transducers connected to a three-channel XY-writer. The measuring is done in three different planes. Curves are produced representing movements within the symphysis with force abduction of flexed hips, with standing on one leg and with walking. One case of severe symptoms from pelvic instability postpartum is presented. After external fixation with a Hoffman instrument all pains

vanished but recurred immediately after extraction of the instrumentation some days later.

HOFFMANN INSTRUMENTATION IN THE TREATMENT OF UNSTABLE PELVIC RING INJURY. A CASE REPORT

Tage Sahlstrand

Department of Orthopaedic Surgery,
Östra Hospital, Göteborg

A case with total disruption of the pelvic ring including rupture of the symphysis and both of the sacro-iliac joints is reported. A complete reduction and effective stabilization was accomplished by means of Hoffmann's external skeletal fixation using the Hoffmann instrumentation. The load-carrying stability was restored after treatment for 6 weeks. This technique seems to offer some definite advantages compared with other methods. The rigid fixation facilitates easy nursing and is convenient for the patient. The sliding bar allows adjustment of the compression. Distraction with the sliding bar during X-ray monitoring gave an indication in the reported case of the load-carrying stability in the supine position before mobilization.

THE HALO IN THE MANAGEMENT OF INSTABLE CERVICAL SPINE LESIONS

Ragnar Kalén & Hans Ersmark

Department of Orthopedics, Danderyd Hospital,
Danderyd

Since 1976 Halo-vests have been used in the treatment of unstable cervical spine lesions at the Orthopedic Clinic, Danderyd Hospital. We have treated 18 cases — 7 with dens fractures and 11 with presumptive unstable traumatic cervical spine lesions. The treatment technique has been 12 weeks in a Halo-vest, and a further 12 weeks with a soft collar. Thirteen cases have completed the treatment and have all healed radiologically, including the seven cases with dens fractures. No serious complications have occurred during treatment. It has been possible for the most part to carry out the treatment in the out patient department, which means an important gain in medical rationalization.

FRACTURES OF THE FEMORAL NECK IN YOUNG ADULTS BETWEEN 17 AND 50 YEARS OF AGE

C. Zetterberg, L. Irstam & G. B. J. Andersson

Department of Orthopaedic Surgery I, Sahlgren Hospital, Göteborg

Fifty-five fractures in 54 subjects (28 women and 26 men) occurring in the years 1960 through 1975, were studied. Forty were caused by falls, 13 by traffic accidents, and two were stress fractures. Fifty per cent of the patients suffered from disease or injury at the time of trauma, 11 per cent had premature old-age pensions and 13 per cent serious alcohol problems. Late segmental collapse occurred in 42 per cent and reoperation was necessary in 30 cases, among these, six arthroplasties. Thirty-nine per cent of the patients were pain-free. Only 18 per cent had an unimpaired ability to work.

COMPUTERIZED TOMOGRAPHY OF THE ANKLE

Ulf Lindsjö, Anders Hemmingsson, Bo Sahlstedt & Göran Danckwardt-Lillieström

Clinics for Orthopaedic Surgery and Radiology,
University Hospital, Uppsala

Images of transverse frontal and saggital sections of the ankle were obtained with an Ohio Nuclear Delta 50 FS. The axial computerized tomograms have several advantages over conventional tomograms. Incongruency due to fractures, arthrosis and synostosis can be visualized with good diagnostic accuracy.

Studies of the talus position in dorsal extension and plantar flexion support Inman's statement that the trochlea, being a section of a frustum of a cone, is always in close contact with both malleolar facets. Metal implants give disturbing shadows.

CT scanning of the ankle can in certain cases give more clinical information than conventional radiologic methods. Close cooperation between the radiologist and the orthopaedic surgeon is necessary. The latter should learn how to operate the display terminal. The images on the screen give much more information than photographs do.

TRIPLANE EPIPHYSEAL ANKLE FRACTURES

Daniel R. Cooperman, Philip G. Spiegel & Gerald S. Laros

Section of Orthopedic Surgery, University of Chicago Hospitals and Clinics, USA

Fifteen patients (average age 13 years 5 months) with triplane fractures are reviewed. This group constitutes 6 per cent of 237 consecutive epiphyseal ankle fractures. Fourteen patients were followed radiologically and 12 clinically for an average of 26 months post-injury. Three patients had premature symmetrical physeal closure without angular deformity and with less than 0.5 cm shortening. Three patients had a 5°–10° external rotation deformity. One of these three patients also had an articular incongruity.

In the five cases where tomograms were used to determine the three dimensional configuration of the fracture, a consistent two part fracture pattern was found. The medial part included the tibial shaft — medial malleolus — anteromedial epiphysis. The lateral part included the remainder of the epiphysis — posterior metaphysis and fibula.

STRENGTH REDUCTION AFTER TOTAL RESECTION OF CAPUT RADII FOLLOWING FRACTURE. FOLLOW-UP OF 28 CASES

Gert Walheim & Håkan Lugnegård

Department of Orthopaedic Surgery, St. Göran's Hospital, Stockholm

There were 22 females and 6 males. All had caput/collum radii fractures. In addition 12 had accompanying fractures (ten in the proximal ulna and two in the capitulum humeri). Elbow strength plus range of motion and grip strength were measured. Four patients had flexion and/or extension defects exceeding 30° and three patients had pronation-supination defects of 30°–115°, but all seven had accompanying fractures of the proximal ulna. Nine patients had valgus deformity and/or valgus instability — valgus deformity 10°–30° in seven cases and instability of 10°–20° in six. Only one patient had definite complaints.

None of the patients had a marked reduction in strength of extension and flexion. Strength reduction of more than 33 per cent was seen in pronation in seven patients; in supination in five patients and in grip strength in nine patients.

Conclusions: After resection of caput radii, we seldom encountered complaints of pain or a restricted range of motion. We frequently encountered valgus deformity and/or instability, and reduction of grip and rotational strength.

EFFECT OF HUMAN GROWTH HORMONE IN THE TREATMENT OF PSEUDARTHROSIS

Ragnar Kalén & Torbjörn Ahl

Orthopaedic Clinic, Danderyd Hospital, Danderyd

To investigate the possibility of influencing the healing of pseudarthrosis by administration of Human Growth Hormone (HGH) we have studied 13 patients, aged 42–70, with clinical and radiological evidence of pseudarthrosis. The patients received, at the earliest 6 months after the fracture, 8 IU of HGH daily during a 1 week period and then 8 IU every second day for another 5 weeks, except for the first three cases who were given half that dosage. In nine cases healing was obtained within 6 months, while in four cases treatment was unsuccessful. No side effects were observed.

Extended trials are now being performed to elucidate whether HGH treatment might be of value as a complement to accepted surgical therapy.

HUMAN LEUKOCYTE INTERFERON

Hans Strander

Radiumhemmet, Karolinska Hospital, Stockholm

Interferon is a protein produced by all cells in the organism exposed to viruses. The molecular weight of the active molecule is approximately 21,000. The amino acid sequence is being elucidated at present. Interferon is known to affect several body functions; the most important effects being anti-viral, growth-inhibitory and immunological. Interferon has been shown to inhibit tumor-growth in experimental animals.

Human leukocyte interferon is produced by exposing white blood cells from blood donors to parainfluenza 1 virus. The cells produce interferon within 24 h and the interferon is then concentrated and purified. The standard preparation employed at the clinic, P-IF, contains 5–20 × 10⁶ interferon units per ml and 4–20 × 10³ interferon units per mg of protein. This preparation has been available for clinical use since 1973. A summary of the various properties of human leukocyte interferon is given.

SIDE EFFECTS OF HUMAN LEUKOCYTE INTERFERON THERAPY

Snorri Ingimarsson & Hans Strander

Radiumhemmet, Karolinska Hospital, Stockholm

Human leukocyte interferon is given by intramuscular injection daily or three times a week:

the dose is $2-3 \times 10^6$ standard units. Twelve distinct signs and symptoms have been recognized as possible side effects of the drug. The three most frequent are fever, local pain and shivering. Partial purification of the interferon eliminated some but not all of the symptoms. So far all the patients have been treated on an ambulatory basis and none has had to discontinue the interferon therapy.

The peripheral blood count has not changed. A slight rise in sedimentation rate was noticed during interferon treatment. It is concluded that long-term therapy with exogenous human leukocyte interferon has so far caused no dangerous nor irreversible side effects in the treated patients.

INTERFERON AS ADJUVANT THERAPY IN OSTEOSARCOMA — 3-YEAR FOLLOW-UP STUDY

Lars-Åke Broström

Department of Orthopaedic Surgery, Karolinska Hospital, Stockholm

Exogenous interferon therapy has been given to a consecutive series of osteosarcoma patients presenting no signs of metastases on admission. The series now includes 34 patients with classical osteosarcoma. It was compared with a "historical" control group of 35 patients and recently with a "concurrent" group of 23 patients who together with the interferon group comprise all osteosarcoma cases in Sweden during the years 1972-75. Neither control group initially showed evidence of metastases or received adjuvant therapy. At the 3-year follow-up the outcome for the concurrent group was twice as good as for the historical group, but analysis of different variables of possible prognostic importance disclosed differences which might contribute to this result. Larger and more malignant tumours were found in the historical group, and the concurrent group received more active treatment of pulmonary metastases with surgery and high-dose chemotherapy. The 3-year follow-up is perhaps too short to permit any definitive inferences, but there are clear numerical differences between the interferon treated and the concurrent control group with regard to absence of metastases (60 per cent as against 35 per cent) and survival rate (70 per cent as against 40 per cent). The study continues and the groups are constantly being added to.

ENDOCRINOLOGICAL ASPECTS IN OSTEOSARCOMA

Lars-Åke Broström

Department of Orthopaedic Surgery, Karolinska Hospital, Stockholm

It has been suggested that hormonal mechanisms may be a factor in the pathogenesis of osteosarcoma and might have a bearing on the course of the disease. The peak incidence coincides with the puberty growth spurt and the tumour is usually located in the metaphyseal region of long bones in the vicinity of the growth zones. A preponderance of tall individuals with osteosarcoma has been reported. Forty-four patients have been treated in Sweden between 1972-1974 for osteosarcoma tumours. Nineteen of these patients could be followed during childhood from birth to the onset of the disease, with respect to longitudinal growth and dental development. No preponderance of tall individuals could be noted in this series of patients, nor any significant difference from expected growth curves at the time of diagnosis. These findings could be confirmed from teeth eruption curves, which show a high correlation with somatic development.

ELECTRON MICROSCOPIC, HISTOCHEMICAL AND BIOCHEMICAL STUDIES IN OSTEOSARCOMA

Tomas Aparisi

Department of Orthopaedic Surgery, Karolinska Hospital, Stockholm

The fine structure of the different cell types has been studied in six human osteosarcomas and the localization of acid and alkaline phosphatase in relation to the subcellular organelles demonstrated. Biochemical studies have been carried out to compare the enzyme activity of acid phosphatase and non-specific alkaline phosphatase between osteosarcomas and other, non-malignant, bone tumours, i.e. giant cell tumour and aneurysmal bone cysts. The results show that a predominant cell type, osteoblast-like, occurs in all the osteosarcomas studied. These cells have a high alkaline phosphatase activity on the plasma membrane. Acid phosphatase activity is only present in lysosome-like structures of some of the cells constituting the tumours. The quantity of acid phosphatase in relation to non-specific alkaline phosphatase seems to be related to the tumour's neoplastic activity.

LOCAL RESECTION OF OSTEOSARCOMA INSTEAD OF AMPUTATION

Ulf Nilsson

Department of Orthopaedic Surgery, Karolinska Hospital, Stockholm

In view of the promising results with interferon as adjuvant therapy for osteosarcoma it was thought possible to avoid amputation. Instead, local resection was resorted to as soon as the topography of the tumour permitted local surgery with a safe margin to the tumour area. Local resection was performed for osteosarcoma mainly in the hip and knee region, but also in some cases for osteosarcomas of the pelvic ring. The defect created by the resection was reconstructed either by different kinds of autogenous bone grafting or with artificial implants, some of them being specially designed to fit into rather big defects. In a total of 15 cases of osteosarcoma, locally resected, five local recurrences have occurred, necessitating subsequent amputation.

COMPLETE REMOVAL OF THE THIRD THORACIC VERTEBRA AND LUNG RESECTION FOR RADIO-RESISTANT GENUINE GIANT-CELL TUMOUR OF THE SPINE

Sven-Erik Larsson

Department of Orthopaedic Surgery, Umeå

Total spondylectomy has been described for LIV (Lièvre et al. 1968), ThXI-LI (Stener & Johnsen 1971) and ThVII (Stener 1971). Vascularization of the medulla is most critical at the level of ThIII. A 22-year-old female received laminectomy in February 1975 and high-voltage radiotherapy and in December 1975 decompression of the medulla because of recurrent paraplegia. Progression and vertebral collapse ThIII necessitated in January 1977 posterior and transthoracic radical extirpation of the tumour which protruded from the dorsum through the mediastinum, infiltrating the lung and completely surrounding the medulla. The third thoracic vertebra was completely removed and parts of the second and fourth vertebrae. Iliac bone blocks reconstructed the body of ThIII stabilized by A. O. plates dorsally. The patient was mobilized after 3 months in a plaster bed. She is walking and well 1½ years after operation and shows complete neurological restitution. She has a stable spine with the plates removed, and full working ability. There are no signs of tumour recurrence or metastasis.

SURGERY OF CHONDROSARCOMA OF THE PELVIS

Sven-Erik Larsson

Department of Orthopaedic Surgery, Umeå

A thorough review of all 163 unequivocal chondrosarcoma cases, recorded in the Swedish Cancer Registry 1958–68, showed that 48 lesions were located in the pelvic bones. Out of the 29 inoperable cases none survived 5 years. Hemipelvectomy performed in 10 cases resulted in a survival rate of 60 per cent; 7 cases having local extirpation or curettage survived in less than 33 per cent.

The pelvic chondrosarcomas were predominantly large tumours, histopathologically of grade III, and some showed dedifferentiation into very malignant neoplasms. Even radical surgery in these cases gives a survival rate of less than 15 per cent according to Marcove et al. (1972). Therefore, advanced pelvic resections were performed in the present material. Two patients with more than 10 cm large tumours of the pubic bone had extensive anterior pelvic resection with good radicality and undisturbed walking ability. One patient with a large tumour of the whole right ilium had a resection through the right sacrum, the pubic bone and the ischium. An endoprosthesis was fixed to the latter bones which made it possible to save the leg with intact neurological and circulatory function. She was able to walk with two crutches. Another patient with a large tumour of the right ilium had a radical resection of the ilium, ischium and pubic bones. His leg was saved with a specially constructed pelvic-hip prosthesis. He could walk on crutches with satisfactory function of the preserved extremity.

Improvement of radical pelvic resection techniques, in some cases with primary prosthetic reconstruction, may thus afford radical tumour removal, good palliation and also improved quality of life for this category of patient.

FURTHER EXPERIENCES WITH ACRYLIC CEMENTATION OF GIANT CELL TUMOURS OF BONE

Björn M. Persson & Anders Rydholm

Department of Orthopaedic Surgery, University Hospital, Lund

After thorough curettage nine cases of giant cell tumour of bone have now been cemented and observed for a period of from 1 to 6 years as presented below. In the beginning this method was supposed to be a salvage procedure, but now

Case	Age	Sex	Localization	PAD	Obs. time (years)	Recurrence	Metastasis
1	66	F	P Tib	Rec GCT	6	—	—
2	31	F	I Sch	Px GCT	5	—	—
3	45	F	P Tib	Sn GCT	5	—	—
4	28	F	D Fem	Sn GCT	5	—	—
5	29	M	P Hum	— GCT	2	—	—
6	25	F	P Fem	— CYS	2	—	—
7	40	F	D Fem	— GCT	1	—	—
8	36	F	D Rad	— GCT	1	—	—
9	30	M	D Fem	Rec GCT	1/2	—	—

it seems to be the method of choice for every giant cell tumour of significant magnitude. If recurrences should appear later all the original possibilities for surgical intervention can still be employed.

FINE NEEDLE ASPIRATION CYTOLOGY IN THE DIAGNOSIS OF TUMOURS OF SOFT TISSUE

Anders Rydholm, Ingrid Idvall, Björn M. Persson & Måns Åkerman

Department of Orthopaedic Surgery and Cytodiagnostic Department, University Hospital, Lund

TECHNETIUM DIPHOSPHONATE SCINTIGRAPHY FOR LOCALIZATION OF A CONCEALED OSTEIOD OSTEOMA

Anders Wigren, Sten Graffman & Bo Sahlstedt
Departments of Orthopaedic Surgery, Oncology and Diagnostic Radiology, Uppsala

An osteoid osteoma in the tibial shaft in a 14-year-old boy was located by technetium diphosphonate scintigraphy. The tumour was masked by extensive osteosclerosis. Neither conventional radiography nor linear tomography revealed it. Several previous operations made the radiographs difficult to interpret. At scintigraphy a high uptake of radioactivity was noted within a defined area of the sclerotic bone. At operation an osteoid osteoma was found in the indicated area. The diagnosis was confirmed histologically. Following surgery the symptoms disappeared. Six months later further symptoms occurred and neither conventional radiography nor computer tomography revealed an osteoid osteoma. Scintigraphy now showed a small area with heavy radioactive uptake 2 cm cranial to that observed at the previous scintigraphy. Tomography with hypocycloid movement in the indicated area then revealed an osteoid osteoma. The nidus was excised and the diagnosis confirmed histologically. Thus in this case the uptake of radioactive technetium by the osteoid osteoma indicated its level exactly within the large area of sclerotic bone, and with a refined tomographic technique the tumour could then be demonstrated.

A consecutive series of 171 fine needle aspiration biopsies in patients referred to the Orthopaedic tumour group, University Hospital of Lund during the years 1973–1977 was analysed as regards the reliability of the method.

Final diagnosis	Cytological diagnosis			Total
	Malignant	Benign	Insufficient material	
malignant	35	4	4	43
benign	6	109	13	128
				171

Final diagnosis was verified by histology (129 cases) or 2 years of clinical observation (42 cases). Sufficient material for cytological diagnosis was obtained in 90 per cent of which 93 per cent were correct. Thus fine needle aspiration biopsy is of considerable value in the planning of surgery. Only when amputation is being considered is cytology supplanted by histology.

OPERATION ON PERIPHERAL NERVE IN
Mb RECKLINGHAUSEN. CONSIDERATIONS
OF TWO CASES

Mohammed Zayer & Åke Kjällquist

Orthopaedic Department, Ängelholm Hospital and
Department of Neurosurgery, Lund University
Hospital

1. A 75-year-old healthy woman with a 3-year history of typical symptoms of a carpal tunnel syndrome in her right hand. At exploration multiple tumours up to the size of small birds' eggs were found in the nerve and were extirpated. Microscopy showed neurofibromatosis. Three months later she was free from symptoms.

2. A 38-year-old woman with pain for 11 years in her left thigh. Seven years previously Mb Recklinghausen was diagnosed. Slight paresis, muscle atrophy and hypaesthesia. Four neurofibromatous tumours of up to hazelnut size were extirpated, followed by definite improvement.

The incidence of Mb Recklinghausen is 1:3000, 5–10 per cent arising specifically in peripheral nerves.

Discussion. Severe pain is an indication for operation which should be done by microsurgical technique, minimizing the risk of functional disability. The risk of malignant transformation has not been documented. A frozen section histological examination is recommended.