

## THE BONE INDUCTIVE CAPACITY OF DECALCIFIED BONE MATRIX MODIFIED BY DIPHENYLHYDANTOIN

JORMA OIKARINEN

Department of Anatomy, University of Oulu, Oulu, Finland

Decalcified bone matrix was prepared from cortical bones of rats premedicated with I) Diphenylhydantoin (DPH), II) DPH + Vitamin D<sub>3</sub>, III) Vitamin D<sub>3</sub> or IV) no premedication for 10 days.

In the donor animals, DPH lowered the serum calcium level, caused a weight loss of 10 per cent, and stopped the growth of the long bones. Vitamin D<sub>3</sub> supplementation normalized the serum calcium concentration but had no effect on the other parameters. Vitamin D<sub>3</sub> alone caused hypertrophy of the growth cartilage, while the bone growth and structure was normal.

The bone inductive capacity of decalcified bone matrix was highest in the DPH group, and the DPH + D<sub>3</sub> group also showed significantly higher values than the D<sub>3</sub> and control groups.

The results of the present study show that the bone inductive capacity of the decalcified bone matrix is independent of Vitamin D<sub>3</sub> metabolism.

*Key words:* bone induction; bone matrix; phenytoin

Accepted 24.i.81

Diphenylhydantoin (DPH), a widely used anticonvulsant, is known to cause osteomalacia and rickets, probably by altering Vitamin D<sub>3</sub> metabolism (Hahn et al. 1972). A direct effect on the bone cells has also been suggested (Hahn et al. 1978). In connective tissue, fibroblast proliferation and increased collagen fiber production has been noticed after treatment with DPH (Angelopoulos 1975).

Decalcified bone matrix is known to be a potent inductor of bone formation (Reddi 1976), both at intraskeletal (Narang et al. 1970, Oikarinen & Korhonen 1979a, b) and extraskeletal sites (Reddi & Anderson 1976). It seems that the inductive substance is a specific protein located in normal bone tissue (Urist et al. 1979).

The aim of the present study was to examine if experimentally induced disturbances in bone growth and differentiation by DPH can modify

the inductive capacity of the decalcified bone matrix.

### MATERIALS AND METHODS

#### *Bone inductive materials*

Twenty Sprague-Dawley male rats, 200-250 g, were used as donors. A single injection of Doxycycline (Doximycin®, Orion), 100 mg/kg, was given intraperitoneally to the rats on the first day of the experiment. Then they were divided into four groups with five animals in each. The weight dispersion of the rats in the different groups was 1) 210-225 g, 2) 200-215 g, 3) 230-250 g and 4) 220-235 g.

The following treatments were given to the test groups: I) DPH (Epanutin Parenteral®, Parke-Davis), 100 mg/kg/day intraperitoneally, II) DPH, 100 mg/kg + Vitamin D<sub>3</sub> (Devitol Forte®, Orion), 50 000 IU/kg/day intraperitoneally, III) Vitamin D<sub>3</sub>, 50 000 IU/kg/day intraperitoneally, and IV) Nothing. The in-

jections were given under ether anaesthesia. On the tenth day the rats were killed by gaseous nitrogen, blood samples were obtained by cardiac puncture and both fibulae of all the rats were taken to determine the long bone growth during the medication period.

In each group all the long bones of the rats were collected and prepared as follows: After removing the metaphyses, soft tissues and bone marrow, the bones were defatted with chloroform-methanol (1:1 mixture) for 1 hour, crushed in distilled water to form particles with a maximal size of  $2 \times 0.5$  mm, and demineralized with 0.6 N HCl at  $+4^\circ\text{C}$  for 24 hours during continuous stirring. The extracted matrix material was washed with distilled water, lyophilized, and stored in sterile vials at  $-20^\circ\text{C}$  until required. The amount of residual mineral was  $1 \pm 0.1$  mg/g matrix, determined by the ashing method (Urist et al. 1970).

The serum calcium concentrations of the donor animals were measured by using an atomic absorption spectrophotometer. The effect of the medication on the longitudinal growth of the long bones was determined by measuring the distance between the epiphyseal plate and the most proximally placed doxycycline marked parts of the fibula under a fluorescence microscope. Also hematoxylin-eosin-stained, plastic embedded sections of the fibulae were prepared.

#### Bone induction test

The operations were carried out under ether anaesthesia and using aseptic techniques. Four pouches were prepared with scissors in the dorsal muscles of the recipient rats. Each pouch was filled with 50 mg of decalcified bone matrix powder and sutured. Twenty-seven male rats of the Sprague-Dawley strain were operated upon, each rat receiving the four different kinds of material obtained from groups from I to IV. After the operation the rats were placed in cages. Water and standard food for laboratory rats (Astra, Sweden) was supplied *ad libitum*. One month later, the rats were sacrificed and the formed bone ossicles from two arbitrarily chosen rats were fixed in neutral formalin. The ossicles from the other rats were collected and their wet and dry weights were determined. After lyophilization, the ossicles were ashed in an electric oven at  $+600^\circ\text{C}$  for 48

hours, and the ashes were weighed. The weight of ash, divided by the weight of implanted matrix (Ash/matrix ratio) indicates the bone inductive capacity of the bone matrix (Urist et al. 1970). From the ossicles fixed in neutral formalin, both decalcified and undecalcified 5  $\mu\text{m}$  paraffin sections were prepared and stained with hematoxylin-eosin and by von Kossa's method, respectively.

## RESULTS

### *The effect of DPH on donor animals*

**Calcium level of serum:** The 10 days of DPH medication lowered the serum calcium concentration significantly, compared with the control group (IV). This change was completely antagonized by Vitamin D<sub>3</sub> administration but Vitamin D<sub>3</sub> alone did not affect the serum calcium level (Table 1).

**Body weight:** The rats receiving DPH alone or combined with Vitamin D<sub>3</sub> lost 10 per cent of their weight, whereas the control animals and the Vitamin D<sub>3</sub>-treated rats gained about the same amount (Table 1).

**Bone growth:** The increase in bone length was strongly retarded in the DPH group. Vitamin D<sub>3</sub> administration caused only a weak stimulation of bone growth. In the D<sub>3</sub> and control groups the bone growth was equal and about tenfold compared with the DPH group (Table 1). Vitamin D<sub>3</sub> alone caused hypertrophy of the epiphyseal cartilage but the structure of the trabecular bone was almost normal. In the DPH and DPH + D<sub>3</sub> groups, the bone trabeculae were thicker and the marrow spaces were wider than in the D<sub>3</sub> and control groups (Figure 1).

Table 1. The influence of DPH and D<sub>3</sub> medication on the donor animals ( $n = 5$  per group). Means  $\pm$  SD

| Medication received  | Body weight change (%) | Serum Ca (mmol/liter) | Bone length growth (mm) |
|----------------------|------------------------|-----------------------|-------------------------|
| DPH                  | $-10 \pm 2.5$          | $2.56 \pm 0.15^*$     | $0.14 \pm 0.02^*$       |
| DPH + D <sub>3</sub> | $-9 \pm 2.4$           | $3.31 \pm 0.40$       | $0.32 \pm 0.02^*$       |
| D <sub>3</sub>       | $+10 \pm 2.0$          | $3.03 \pm 0.44$       | $1.12 \pm 0.05$         |
| Control              | $+10 \pm 1.5$          | $3.01 \pm 0.12$       | $1.25 \pm 0.02$         |

\*  $P < 0.0001$ .

### *The effect of DPH on bone induction*

The ash/wet weight ratios measured from the bone matrix induced ossicles were the same in all the groups except the controls, where the ratio was significantly lower ( $P < 0.0001$ ). The amount of induced bone (ash/matrix ratio) varied from one group to another. The DPH medication caused a significant increase in the bone forming capacity of the matrix and this increase was only

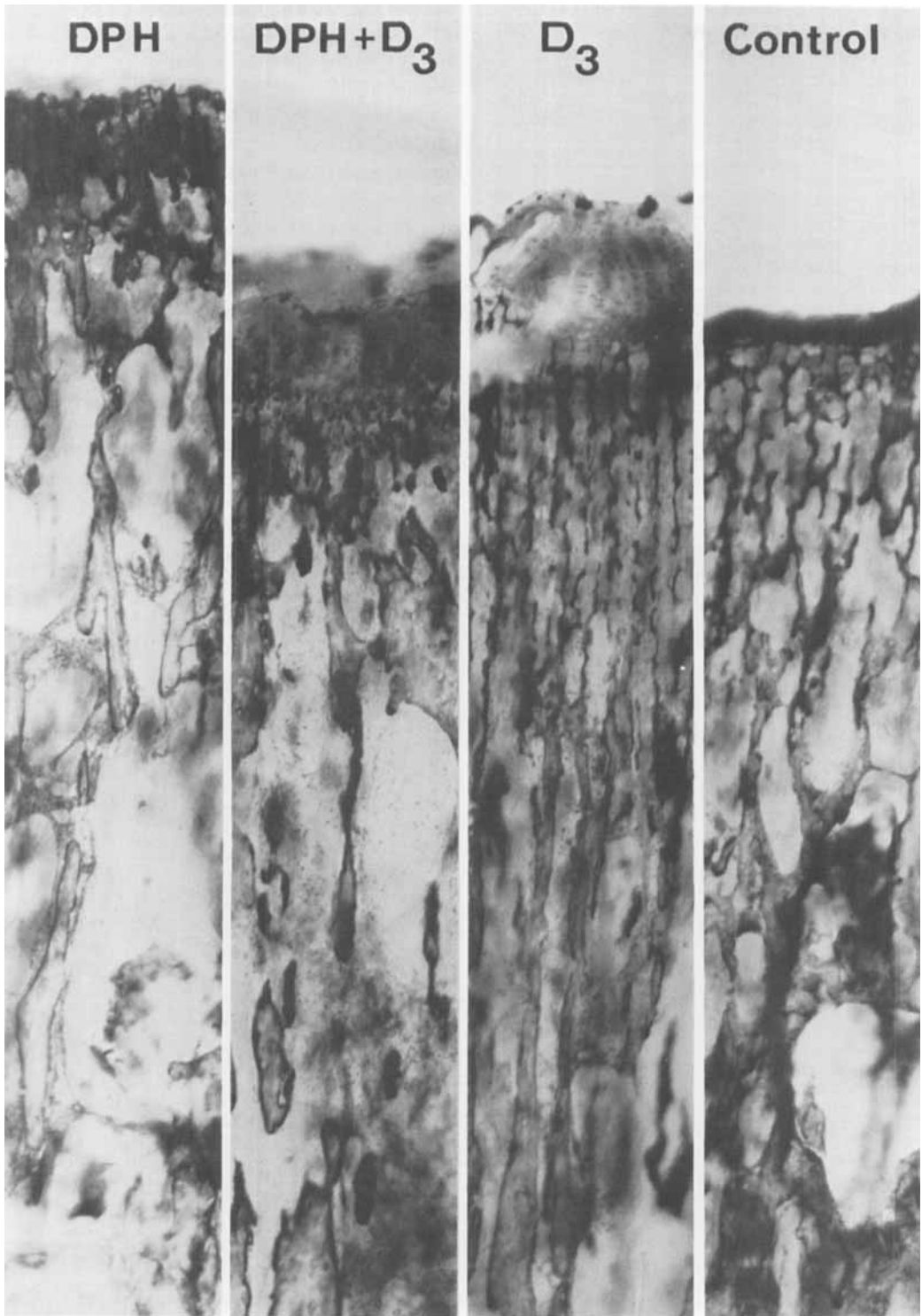


Figure 1. The effect of DPH on bone growth during the medication period. The structure of the trabecular bone is almost normal in the  $D_3$  group, whereas in the DPH and DPH +  $D_3$  groups the trabeculae are thicker and the marrow spaces are wider than in the control specimen (undecalcified plastic-embedded, H-E-stained sections).

Table 2. Bone formation in male rats ( $n = 25$ ) by decalcified bone matrix obtained from pretreated rats. Means  $\pm$  SD

| Donor treatment    | Dry weight/wet weight ratio | Ash/wet weight ratio | mg ash/g matrix |
|--------------------|-----------------------------|----------------------|-----------------|
| DPH                | 0.449 $\pm$ 0.031           | 0.195 $\pm$ 0.028    | 554 $\pm$ 80*   |
| DPH+D <sub>3</sub> | 0.461 $\pm$ 0.029           | 0.195 $\pm$ 0.027    | 544 $\pm$ 60*   |
| D <sub>3</sub>     | 0.488 $\pm$ 0.042           | 0.195 $\pm$ 0.032    | 470 $\pm$ 46    |
| Control            | 0.405 $\pm$ 0.026           | 0.140 $\pm$ 0.021    | 446 $\pm$ 62    |

\* The ash/matrix ratios in the DPH and DPH + D<sub>3</sub> groups differ significantly from the ratios of the D<sub>3</sub> ( $P < 0.004$ ) and Control ( $P < 0.0001$ ) groups (analysis of variance).

slightly reduced by the Vitamin D<sub>3</sub> supplementation. In the D<sub>3</sub> group the amount of induced bone

was not significantly greater than that in the control group, which showed the lowest values (Table 2). All the specimens examined microscopically showed a similar appearance. Advanced matrix resorption and moderate new bone formation were seen. The newly grown bone formed trabeculae or covered the surfaces of the matrix particles (Figure 2). Within the trabeculae, mature bone marrow and fat cells were seen in all the specimens. Chondrocytes were seen in the control (Figure 3) and D<sub>3</sub> groups, located in the old vascular canals and in some resorption cavities of the implanted matrix. No chondrocytes were seen in the specimens of the DPH, and DPH + D<sub>3</sub> groups. The newly grown bone trabeculae with living osteocytes were seen to be completely calcified, when stained by von Kossa's method, whereas the implanted matrix did not stain at all.

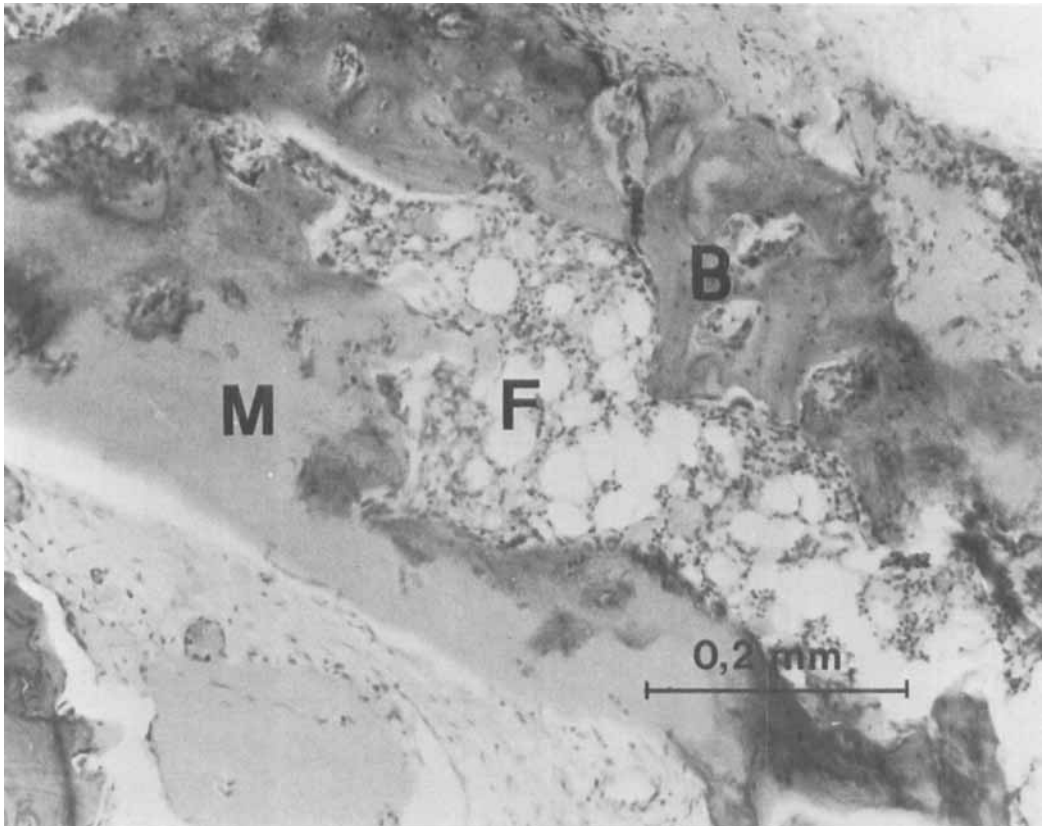


Figure 2. Bone formation and old matrix resorption in the interior of a DPH-matrix-induced ossicle. B = newly formed bone, M = implanted matrix, F = fat cells and bone marrow within the newly formed bone trabeculae. After 1 month, no cartilage cells were seen.

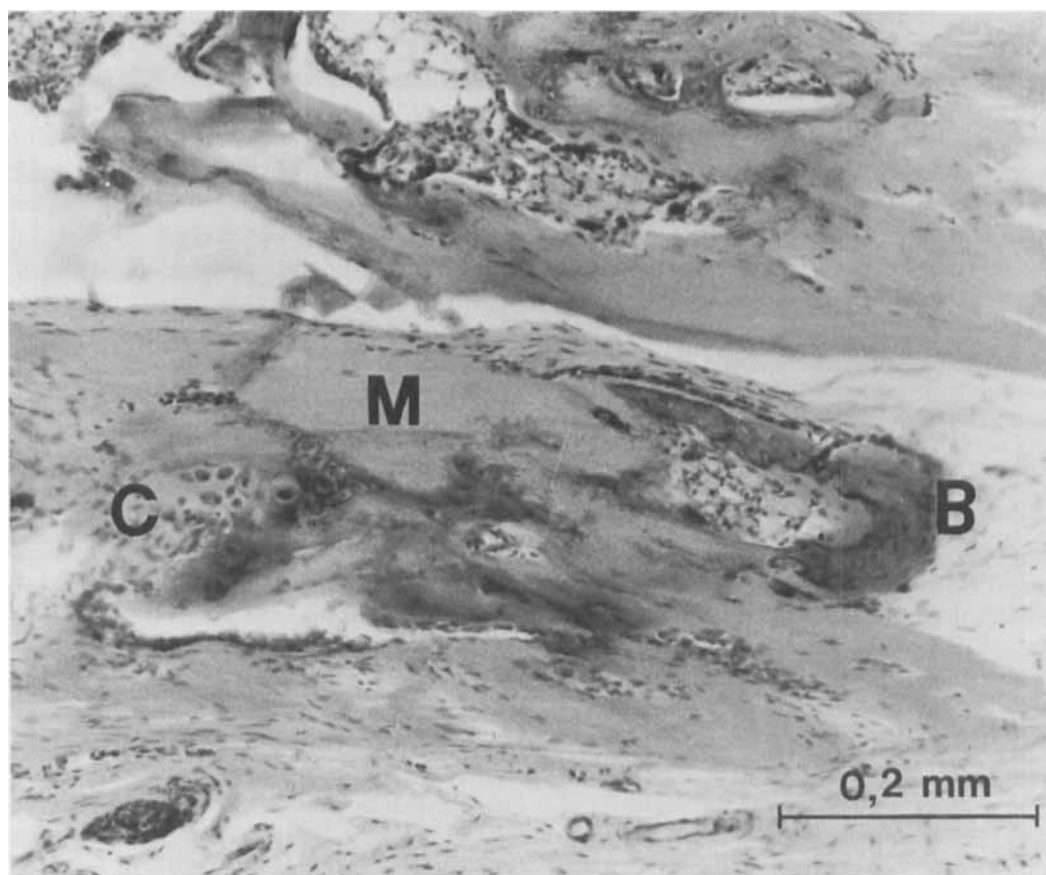


Figure 3. Cartilage cells (C) and newly formed bone (B) induced by decalcified matrix of the control group. M = implanted matrix.

## DISCUSSION

The present study shows that the bone inductive properties of decalcified bone matrix are modified by DPH. Further, the results suggest that DPH has a direct effect on bone tissue, not mediated by Vitamin D<sub>3</sub>.

Urist & Strates (1971) claim that the bone inductive capacity is missing in the bones of subjects with rickets. In the present study, according to other investigations (Gascon-Barré & Côté 1978, Harris et al. 1978, Villareale et al. 1978), DPH-induced "rickets" may have been present but the bone inductive capacity was significantly increased. This indicates that DPH causes changes in the bone different from those found in the animals with rickets caused by Vitamin D de-

ficiency. DPH-induced rickets has been said to be corrected by Vitamin D supplementation in man (Hahn & Halstead 1979). Because the altered metabolism of Vitamin D is thought to be the cause of the bone changes discovered in the patients treated with DPH (Gascon-Barré & Côté 1978, Hahn & Halstead 1979, Bell et al. 1979), Vitamin D supplementation has been recommended to prevent the skeletal disturbances (Johnell et al. 1979, Jowsey et al. 1978). In the present study, the serum calcium concentration was normalized by Vitamin D<sub>3</sub> supplementation, but it only slightly stimulated the growth of bones, did not normalize the bone structure and had an insignificant effect on the bone inductive capacity of the bone matrix. These findings indi-

cate that DPH also has a direct, Vitamin D independent effect on the bone cells, as suggested by Hahn et al. (1978).

The findings in the microscopic examination of the induced ossicles were similar to those previously described (Oikarinen & Korhonen 1979a). Differences in the amount of the induced bone could not be detected by the microscopic method. This is because of the irregularly arranged bone trabeculae and the relatively small sizes of the ossicles studied. In this regard, the ashing method is more reliable, because the implanted matrix does not recalcify, and all the mineral in the ash is derived from the induced bone (Urist et al. 1970).

The effect of DPH may be dose-related. The doses used in this study were selected according to Sotaniemi (1977), who demonstrated that 100 mg/kg/day of DPH intraperitoneally causes maximal deposition of dentine in the rat. The dose is greater than the doses used in patients, but it is comparable to the doses of DPH given to the rats in the investigations of Villareale et al. (1978) (1–2.5 mg/kg diet, gives serum concentration 2–4.7 mg/100 ml), Gascon-Barré & Côté (1978) (50 mg/kg/day per os) and Harris et al. (1978) (up to 500 mg/kg/day per os). These authors demonstrated rickets-like changes of bones. In the present study, a growth arrest, not a typical rickets was caused by the DPH medication, and this was not corrected by Vitamin D<sub>3</sub> supplementation. Also Sotaniemi (1977) reported retardation of weight gain, but the maximal deposition of dentine with the dose of 100 mg/kg/day of DPH. According to Villareale (1978), the width of the epiphyseal plate was increased by DPH. Unfortunately, in the present study, the epiphyses of the fibulae were discarded when obtaining the specimens (only in the D<sub>3</sub> group were remnants of the cartilage seen), and therefore, the changes in the growth cartilage could not be registered. The dose of Vitamin D<sub>3</sub>, also selected according to the works of Sotaniemi (1977), is not physiological, but it caused only the hypertrophy of the growth cartilage, whereas the structure of the cancellous bone was normal.

With the exception of the injection of the oxytetracycline the animals of the control group were not anesthetized or injected during the

medication period when preparing the test materials. It is possible that this can influence the bone growth or the matrix composition. Because the rats of the D<sub>3</sub> group were both anesthetized and injected, and the bone inductive capacity of this group was not significantly greater than that of the controls, the author believes that the few seconds anesthesia as such may not affect the results, and the D<sub>3</sub> group can be regarded as controls in this respect.

Although DPH is known to increase collagen synthesis and the amount of soluble collagen in healing fractures (Gudmundson & Lindgren 1973), more experiments are needed to explain the changes in bone matrix composition or structure resulting in increased bone induction capacity. The increased amount of soluble collagen in the DPH treated matrix may cause a more rapid dissolution of the bone inductive protein, thus making a rapid and effective induction possible. The other explanation is that DPH causes an increase in the synthesis of the bone inductive protein as well as the other connective tissue substances (Angelopoulos 1975). The observation that chondrocytes were not found in the bone pellets induced by the matrix prepared from both of the DPH-treated groups supports the hypothesis of rapid dissolution of the bone inductive protein because, if the induction mechanism is active for a shorter period of time, the formed bone pellet will be more mature 1 month after the implantation.

#### ACKNOWLEDGMENTS

This work was supported by grants from the MATINE of Finland and The Sigrid Juselius Foundation, Finland. The author wishes to thank Dr. Seppo Sotaniemi for useful personal communications and Mrs. Pirkko Peronius and Mr. Juha Tuukkanen for their skilful technical assistance.

#### REFERENCES

- Angelopoulos, A. P. (1975) Diphenylhydantoin gingival hyperplasia. *J. Can. Dent. Assoc.* **41**, 103–106.
- Bell, R. D., Pak, C. Y. C., Zerwekh, J., Barilla, D. E. & Vasko, M. (1979) Effect of phenytoin on bone and Vitamin D metabolism. *Ann. Neurol.* **5**, 374–378.

- Gascon-Barré, M. & Côté, M. G. (1978) Influence of phenobarbital and diphenylhydantoin on the healing of rickets in the rat. *Calcif. Tissue Res.* **25**, 93–97.
- Gudmundson, C. & Lindgren, L. (1973) Does diphenylhydantoin accelerate healing of fractures in mice? *Acta Orthop. Scand.* **44**, 640–649.
- Hahn, T. J., Birge, S. J., Scharp, C. R. & Avioli, L. H. (1972) Phenobarbital-induced alterations in Vitamin D metabolism. *J. Clin. Invest.* **51**, 741–748.
- Hahn, T. J., Scharp, C. R., Richardson, C. A., Halstead, L. R., Kahn, A. J. & Teitelbaum, S. L. (1978) Interaction of diphenylhydantoin (phenytoin) and phenobarbital with hormonal mediation of fetal rat bone resorption in vitro. *J. Clin. Invest.* **62**, 406–414.
- Hahn, T. J. & Halstead, L. R. (1979) Anticonvulsant drug-induced osteomalacia: Alterations in mineral metabolism and response to Vitamin D<sub>3</sub> administration. *Calcif. Tissue Int.* **27**, 13–18.
- Harris, M., Rowe, D. J. F. & Darby, A. J. (1978) Anticonvulsant osteomalacia induced in the rat by diphenylhydantoin. *Calcif. Tissue Res.* **25**, 13–17.
- Johnell, O., Nilson, B. E., Wallöe, A. & Wiklund, P. E. (1979) Bone morphology in epileptics. *Calcif. Tissue Int.* **28**, 93–97.
- Jowsey, J., Arnaud, S. B., Hodgso, S. F., Johnson, K. A., Beabout, J. W. & Wahner, H. W. (1978) The frequency of bone abnormality in patients on anticonvulsant therapy. *Electroencephalogr. Clin. Neurophysiol.* **45**, 341–347.
- Narang, R., Ruben, M. P., Harris, M. H. & Wells, H. (1970) Improved healing of experimental defects in the canine mandible by grafts of decalcified allogenic bone. *Oral. Surg.* **30**, 142–150.
- Oikarinen, J. & Korhonen, L. K. (1979a) Repair of bone defects by bone inductive material. *Acta Orthop. Scand.* **50**, 21–26.
- Oikarinen, J. & Korhonen, L. K. (1979b) The bone inductive capacity of various bone transplanting materials used for treatment of experimental bone defects. *Clin. Orthop.* **140**, 208–215.
- Reddi, A. H. (1976) Collagen and cell differentiation. *Biochemistry of collagen*. Plenum Publishing Corporation, New York.
- Reddi, A. H. & Anderson, W. A. (1976) Collagenous bone matrix-induced endochondral ossification and hemopoiesis. *J. Cell. Biol.* **69**, 557–572.
- Sotaniemi, S. (1977) Effect of diphenylhydantoin on the apposition of dentin. *Proc. Finn. Dent. Soc.* **73**, Suppl. IV.
- Urist, M. R., Jurist, J. M., Dubuc, F. L. & Strates, B. S. (1970) Quantitation of new bone formation in intramuscular implants of bone matrix in rabbits. *Clin. Orthop.* **68**, 279–293.
- Urist, M. R. & Strates, B. S. (1971) Bone morphogenetic protein. *J. Dent. Res.* **50**, Suppl. 6, 1392–1406.
- Urist, M. R., Mikulski, A. & Lietze, A. (1979) Solubilized and insolubilized bone morphogenetic protein. *Proc. Natl. Acad. Sci. USA* **76**, 1828–1832.
- Villareale, M. E., Chiroff, R. T., Bergström, W. H., Gould, L.K. V., Wasserman, R. H. & Romano, F. A. (1978) Bone changes induced by diphenylhydantoin in chicks in a controlled Vitamin D intake. *J. Bone Joint Surg.* **60-A**, 911–916.