

## ROTATIONAL DEFORMITIES AFTER FEMORAL SHAFT FRACTURES IN CHILDHOOD

*A Retrospective Study 27–32 Years after the Accident*

K. J. BROUWER, J. C. MOLENAAR & B. VAN LINGE

Department of Paediatric Surgery and Department of Paediatric Orthopaedics, Sophia Children's Hospital and Neonatal Unit, University Hospital Rotterdam, The Netherlands.

Fifty femoral shaft fractures sustained in childhood and for the most part treated conservatively were studied in retrospect 27–32 years after the accident, with special reference to rotational deformity. Femoral rotation was measured by means of so-called anteversion X-rays according to Dunn-Rippstein, and the same radiological examination was carried out in a control group of 100 adult volunteers. The L/R differences in femoral rotation were studied in the patient group in comparison with the control group.

Persistent rotational dislocation was found in only one case, and had had no demonstrable untoward consequences.

The established view that rotational dislocation is incapable of spontaneous correction is refuted with the aid of clinical and experimental data from the literature and personal observations.

It is concluded that, in the patients studied, good results have been obtained by the conventional traction methods of Bryant and Russel. The use of the so-called "Weber Bock" to replace these methods is therefore not recommended.

*Key words:* children; femur; fracture; rotational dislocation

Accepted 21.v.80

Treatment by means of a simple adhesive plaster traction bandage is pleasant for a child with a femoral shaft fracture and convenient for the surgeon in charge. An angle in the femoral axis can be readily corrected, and there are few complications. The influence of traction on the relative rotation of the fracture fragments, however, is less unequivocal. It is a fair assumption that longitudinal traction should have a corrective effect on it. On the other hand it is often assumed that, during traction, the rotator muscles of the hip exert torsion on the proximal fracture fragment which, in fact, promotes rotational dislocation.

The diagnosis of rotational dislocation during treatment with a plaster traction bandage depends on unreliable clinical and radiological data.

For the diagnosis and correction of rotational deformities during treatment of femoral shaft fractures, Weber designed a traction table (the so-called "Weber Bock") in 1961. Comparative radiological examination during treatment on this table can disclose rotational deformity, which can then be corrected without undue difficulty (Saxer 1974, 1978, Schoppmeier 1977, Weber 1963, 1969).

In view of the fact that normal persons show significant differences in rotation between left and right, the question arises whether exact correction of rotational deformities is really necessary. What are the long-term results in a group of adults who, as children, were treated for femoral shaft fracture by means of an adhesive plaster traction bandage? Can a rotational deformity be

expected to show spontaneous correction after consolidation of the fracture?

It is useful to find the answers to these questions because Weber's method can cause fairly serious complications such as peripheral ischaemia, peroneal nerve lesion and osteomyelitis arising from the nail channel. The last-mentioned complication developed in 6 out of 149 patients treated by Weber (Saxer 1978).

**PATIENTS AND METHODS**

In an effort to collect data on the long-term consequences of rotational dislocation after femoral shaft fracture in childhood, a retrospective study was started late in 1976. The subjects were patients who, during the period 1945 through 1949, had been treated for femoral shaft fracture at Sophia Children's Hospital, Rotterdam (Figure 1 and Table 1).

Of the total of 64 patients, 50 (38 men and 12 women) could be examined. Treatment had been conservative in 46 and operative in 4 cases. Conservative treatment had been Bryant's traction for patients under 4 years old at the time, and Russel's traction for those over 4 years old.

The study comprised the following activities:

- a review of old case records and X-rays;
- orthopaedic examination of the back, pelvic region and lower limbs;
- roentgenography: anteroposterior and lateral X-rays of the femur, anteroposterior X-rays of the knees, and X-rays of the pelvic region according to Dunn-Rippstein, with the aid of which femoral shaft rotation can be measured with sufficient accuracy (Dunlap & Shands 1953, Dunn 1952, Gross & Haike 1970, Rippstein 1955, Ryder & Crane 1953, König 1977, König & Schult 1974).

In addition, a control group of 50 male and 50 female "normal volunteers" aged 20-50 was formed and submitted to the same radiological examination according to Dunn-Rippstein.

**RESULTS**

*Controls*

Apart from the range of the angles of anteversion, it is in particular the individual L/R differences in the control group that are of essential importance in this retrospective study. The principal relevant data are presented in the next two figures (Figures 2 and 3).

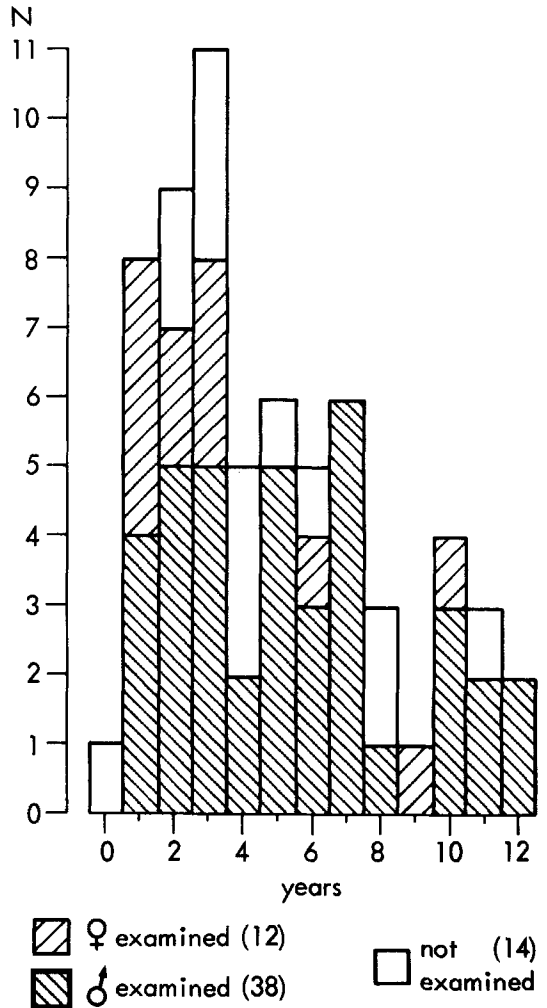


Figure 1. Age and sex distribution in the group of 64 ex-patients with a femoral shaft fracture in childhood, 50 of whom were included in the retrospective study 27-32 years after the accident (38 men and 12 women).

Table 1. Survey of the 14 patients (out of a total of 64) who were lost to or excluded from the retrospective study

Emigrated	5
Refused	4
Deceased	2
Untraceable	1
Osteogenesis imperfecta	1
Severe mental, neurological and motor disorders	1
<b>Total</b>	<b>14</b>

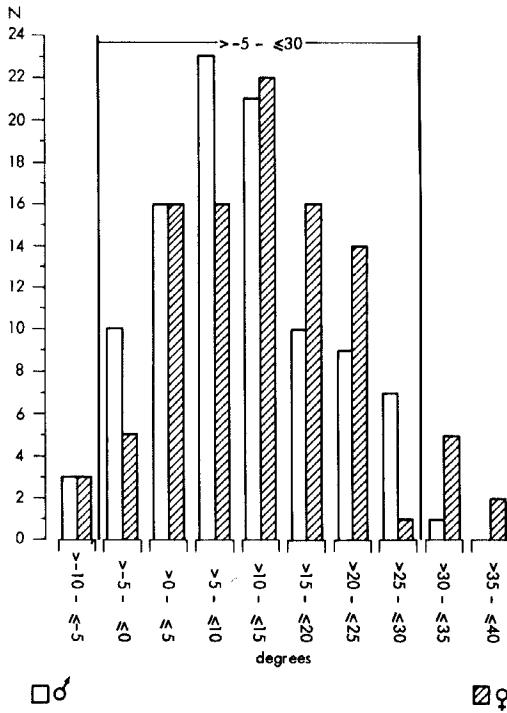


Figure 2. Distribution of the anteversion angles of 100 pairs of femurs, measured in a control group of 50 men and 50 women (aged 20–50 years) without anomalies of the pelvic region and/or lower limbs (further details in the text).

The critical values according to Müller (–5° and +30°, Müller 1971) were exceeded in 14 instances. The men showed a range of 40° (from –9° to +31°), and the range in women was 47° (from –9° to +38°). The mean angle of anteversion in the women exceeded that in the men (12.2° versus 9.6°). The mean angle of anteversion in the entire control group was 10.9°.

The individual differences per pair of femurs exceeded expectations (Best et al. 1971, Von-

tobel et al. 1961, Weber 1963): mean 5° (range from 0° through 15°). The difference exceeded 10° in 10 per cent of the entire group.

Patients

*Subjective complaints, difference in leg length and persistent dislocation:* Interviews revealed that 42 of the 50 patients were free from local complaints. None of the remaining 8 patients with local complaints was significantly hampered in day-to-day activities as a result of these complaints.

The clinical leg length was compared with the contralateral value and then related to the post-consolidation longitudinal dislocation revealed by

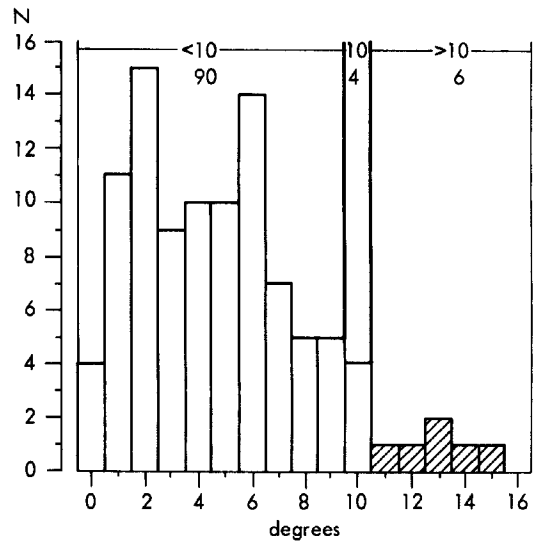


Figure 3. Distribution of the differences in rotation, measured per pair of femurs, in the control group of 50 men and 50 women (aged 20–50 years) without anomalies of the pelvic region and/or lower limbs (further details in the text).

Table 2. Varus and valgus dislocation in 50 femoral shaft fractures sustained in childhood, measured following fracture consolidation and again at the follow-up after 27–32 years. The degree of spontaneous correction is deduced from these two series of measurements

	n	After consolidation range average	At follow-up range average	Spontaneous correction range average
Varus	5	5°–10° 7.4°	0°– 8° 4.6°	0°–8° 2.8°
Valgus	17	5°–14° 9.4°	0°–11° 4.2°	1°–8° 5.2°

the old X-rays. Fracture consolidation was found to have shortened the leg by an average of 3 mm (range from 0 through 15 mm). The difference in clinical leg length at follow-up ranged from -15 through +25 mm, with an average of +8 mm. The difference in longitudinal growth as compared with the contralateral leg, calculated from these data, ranged from -15 through +35 mm, with an average of +11 mm.

With regard to post-consolidation angles, we confined ourselves to deformities of 5° or more. The relevant data are presented in Table 2.

Spontaneous correction of antecurvation and recurvation takes place within the process of physiological femoral curvation, ranging from 0° to 10°. This is why the degree of spontaneous correction cannot be measured exactly. Persistent dislocation in the sagittal plane was assumed to exist when the total curvation of the femur exceeded the range of physiological curvation. Post-consolidation antecurvation was measured on the old X-rays in 13 instances and ranged from 6° through 19°. The follow-up revealed slightly increased femoral curvation (ranging from 11°

Table 3. Distribution of the angles of anteversion measured in 50 patients treated for femoral shaft fracture in childhood, 27-32 years previously.

Angles of anteversion	Range	Average
All femurs	-6° to +33°	+12.5°
Fractured side	-6° to +33°	+12.1°
Unaffected side	-1° to +31°	+12.9°
L/R difference	0° to +26°	5.8°

through 15°) in 7 of these cases. Post-consolidation recurvation was observed on the old X-rays in 4 instances, whereas the follow-up showed a normal femoral curvation in 3 cases and *increased* antecurvation (15°) in one case.

Post-consolidation lateral dislocation was present in no fewer than 54 instances (in one or two of the four directions), but at follow-up always proved to have been completely corrected.

Rotational dislocation was diagnosed by measuring the angles of anteversion on the fracture side and on the unaffected side and comparing them by the radiological method of Dunn-Rippstein. The angles thus measured are presented in Figure 4 and Table 3. The critical values according to Müller were exceeded in six cases (but this involved the unaffected side in two). The measured differences in rotation between fracture side and unaffected side are presented in Figure 5.

The differences ranged from 0° through 26°, and exceeded 10° in six cases. In only one instance did the difference exceed 14° (+26°). The average difference was 5.8°. The angle of anteversion on the fracture side was smaller than that on the unaffected side in 5, and larger in the other 5, out of 10 pairs of femurs with a difference in rotation of 10° or more.

The small group of patients treated by operation showed no deviation from this pattern, the differences in rotation being 2°, 3°, 5° and 14°, respectively. No marked differences between transverse and oblique or spiral fractures are found when the differences in rotation are plotted against the various fracture types (Figure 6).

The literature indicates that severe rotational dislocation is to be expected in particular after

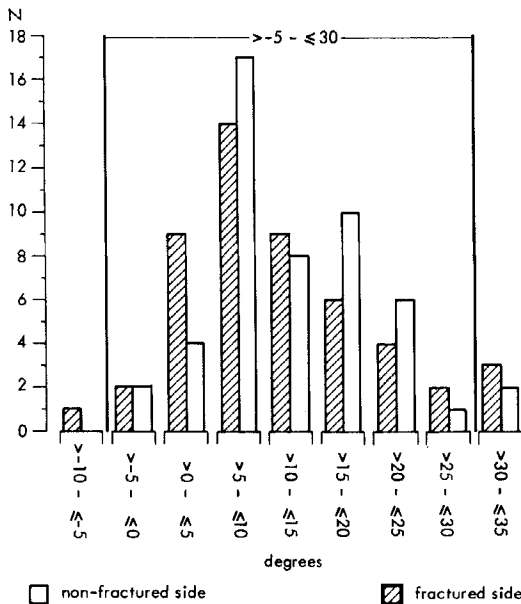


Figure 4. Distribution of the anteversion angles measured in 50 patients treated for femoral shaft fracture 27-32 years previously. Fracture side and unaffected side are depicted side by side for comparison.

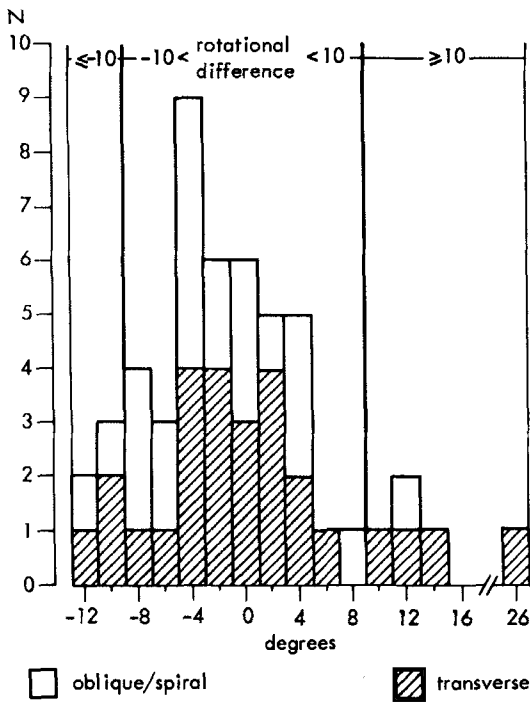


Figure 5. Distribution of the differences in rotation, measured per pair of femurs, in 50 patients treated for femoral shaft fracture 27–32 years previously.

proximal, so-called subtrochanteric fractures (Hildebrandt 1965, Tjong 1974). Fractures of this type were present in only two cases in our series, in which the differences in rotation were 2° and 6°, respectively.

Efforts were also made to establish a possible correlation between the difference in rotation measured and the patient's age at the time of the accident. The difference in rotation averaged 6.4° in the youngest age group (0 through 4 years,  $n = 25$ ), 5.7° in the intermediate age group (5 through 9 years,  $n = 17$ ) and 5.6° in the oldest group (10 years and over,  $n = 8$ ).

Our findings afford no reliable explanation of the cause of the above-mentioned subjective complaints in 8 of the 50 patients. There was no persistent axis dislocation or rotational dislocation. However, 6 of the 8 patients showed a leg length difference of more than 1 cm (1.5 through 2 cm). Such a difference was measured in a total of 18 of the 50 patients. The leg length difference

may therefore be a factor of significance in the aetiology of the subjective complaints.

An evaluation of the X-rays revealed that none of the patients with a difference in rotation exceeding 10° showed signs of premature arthrosis.

The findings obtained can be summarized as follows:

- a significant difference in rotation was found in only one of the 50 patients examined;
- no correlation was found between local complaints and differences of rotation actually measured;
- there were no signs of premature arthrosis based on persistent rotational dislocation;
- the control group showed individual L/R differences in rotation ranging from 0° through 15°, and angles of anteversion ranging from -9° through +38° (average 10.9°).

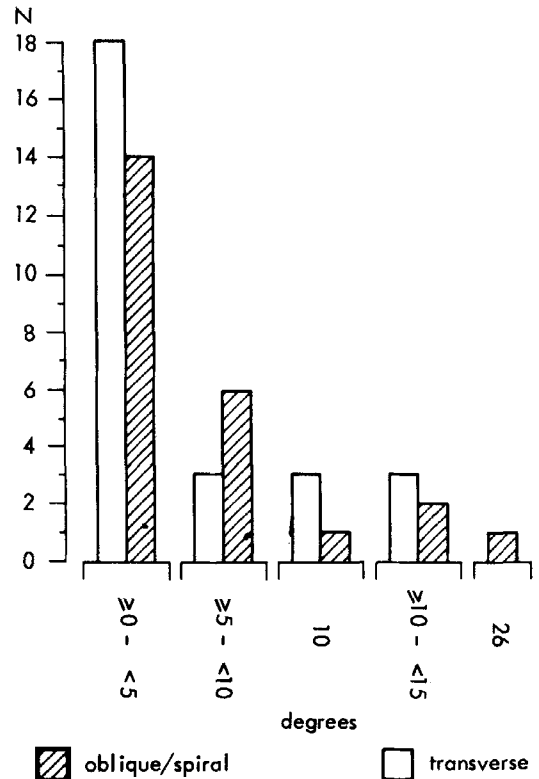


Figure 6. Comparison of the differences in rotation, measured per pair of femurs, related to fracture type (transverse fracture versus oblique or spiral fracture) in 50 patients treated for femoral shaft fracture 27–32 years previously.

## DISCUSSION

High incidences of rotational dislocation after femoral shaft fractures in childhood have been frequently reported since 1961 (Best et al. 1971, Engels et al. 1977, Herzog et al. 1976, Hupfauer & Balau 1971, Klapp et al. 1974, Parvinen et al. 1973, Piroth & Bliesener 1977, Tjong 1974, Verbeek & Bender 1976, Vontobel et al. 1961, Yano & Sawada 1975). The criterion for dislocation used in these reports is a difference in rotation between fracture side and unaffected side of  $10^\circ$  or more (Table 4).

However, the great significance which has been attached to these findings can be disputed on the following grounds:

1. *The criterion for rotational dislocation* – a difference of  $10^\circ$  or more from the contralateral femur – is a random choice. Our control group shows that the physiological difference in rotation ranges from  $0^\circ$  through  $15^\circ$ . The difference was  $10^\circ$  in four instances and exceeded  $10^\circ$  in six. Among the publications on this physiological difference in rotation (Cyvin 1977, De Jong 1968, Löfgren 1956, Wertheimer & Martin 1963), De Jong's study merits special mention in comparison with our findings on differences in rotation after

femoral shaft fractures in childhood (Figures 7 and 8). It is evident that the two series hardly differ. In only one case in our series does persistent rotational dislocation seem plausible (difference in rotation:  $+26^\circ$ ).

Other findings which merit special mention are those reported by Tjong (1974) in a group of 14 femoral shaft fractures specified as "greenstick or incomplete". Rotational dislocation can be regarded as unlikely after such fractures. Yet in four cases the difference in rotation exceeded  $10^\circ$  ( $15^\circ$  in two and  $17^\circ$  in the other two).

2. That *rotational dislocation is incapable of spontaneous correction* (Blount 1955, Ehalt 1961, Müller 1971, Rehn 1974, Weber 1963) has never been demonstrated with certainty. It is a generally accepted fact that, during the growth period, the physiological de-rotation process is markedly influenced by mechanical factors from birth on; many clinical observations confirm this (Axer et al. 1972, Baker et al. 1962, Beals 1969, Fabry et al. 1973, Glauber & Vizkelety 1966). It seems logical that the same mechanical factors also exert their influence on a femur with rotational dislocation, the de-rotation process being enhanced in the case of increased anteversion

Table 4. Survey of the literature on rotational dislocation after femoral shaft fracture in childhood. Rotation measurements were always made by the radiological technique according to Dunn-Rippstein (cf. text). The investigators accepted as criterion for rotational dislocation a difference in rotation of  $10^\circ$  or more between fracture side and unaffected side. The cases with such a difference of  $10^\circ$  or more are categorized in the columns " $\geq 10^\circ$ ", " $\geq 15^\circ$ " and " $\geq 20^\circ$ ".

Author	n	Fol- low-up in years	TREATMENT										
			conservative			operative			incompletely specified				
	n		$>10^\circ$	$>15^\circ$	$>20^\circ$	n	$>10^\circ$	$>15^\circ$	$>20^\circ$	n	$>10^\circ$	$>15^\circ$	$>20^\circ$
Vontobel 1961	52	1-20								52	13	5	2
Hupfauer 1971	53	2-12								53	11	7	5
Best 1972	48	2-7	48	20	15	5							
Parvinen 1973	52	4-14	33	7	3	1							
Tjong 1974	82	1-20	66	19	6	0	19	4	2	0			
Klapp 1974	23	2-14	23	6	1	1							
Yano 1975	31	4-6								31	18	11	4
Herzog 1976	26	8-15					26	5	1	1			
Verbeek 1976	62	1-6	62	23	?	11							
Engels 1977	73	2-11	73	8	?	2							
Piroth 1977	44	2-14	44	7	2	1							

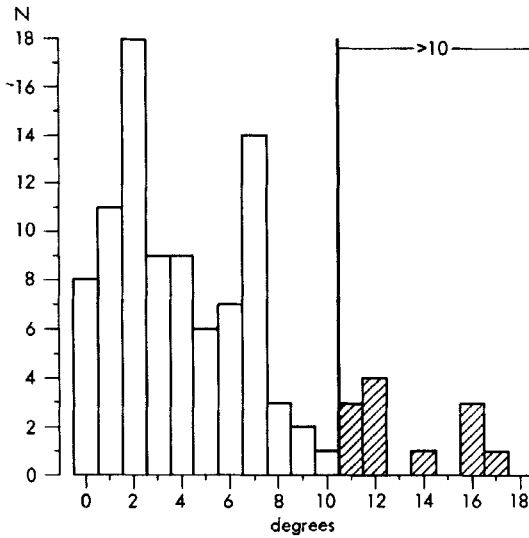


Figure 7. By courtesy of De Jong (1968, cf. References): Distribution of the differences in rotation, measured per pair of femurs, in a group of 100 normal pairs of femurs. Average difference: 5.0°. Difference exceeding 10° in 12 per cent.

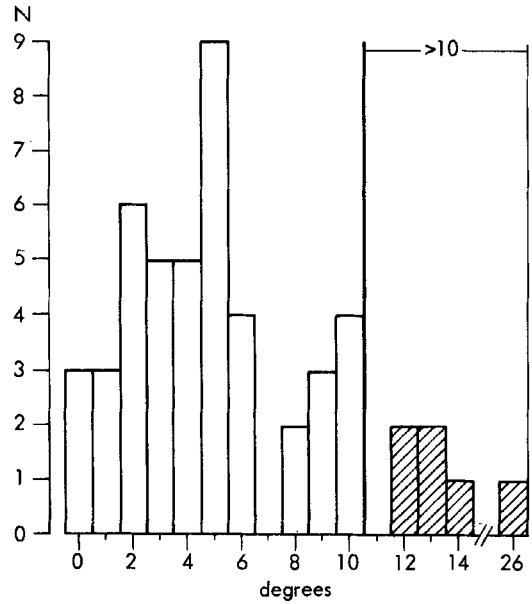


Figure 8. Personal observations: Distribution of differences in rotation, measured per pair of femurs, in the group of 50 patients with a unilateral femoral shaft fracture sustained 27–32 years previously. Average difference: 5.8°. Difference exceeding 10° in 12 per cent. Only one patient (difference in rotation 26°) exceeds the limits of the range in De Jong's series (cf. Figure 7).

and diminished or arrested in the case of decreased anteversion. Animal experiments, too, have clearly demonstrated the influence of mechanical factors on femoral rotation (Appleton 1934, Arkin & Katz 1956, Bernbeck 1949, Le Damany 1903, Schneider 1963). Perhaps this explains why the high incidences of major differences in rotation are mainly reported in the published series with the briefest follow-ups (cf. Table 4). On the other hand, our own findings – few major differences in rotation after a very long follow-up period – are likewise consistent with this explanation.

However, only repeated anteversion measurements in the course of the years after the accident can really prove that spontaneous correction of rotational dislocation is possible. Von Laer (1978) performed such measurements and did in fact demonstrate that major differences diminished gradually and were integrated in the physiological de-rotation process of the growing femur. Von Laer's series was too small to provide more detailed data, e.g. on the degree of spontaneous cor-

rection and the influence on it of the patient's age at the time of the accident.

- That *persistent rotational dislocation leads to premature arthrosis* of adjacent joints is an unverified hypothesis based exclusively on biomechanical considerations (Debrunner 1967, Müller 1971, Nicod 1967, Weber 1961). About the demonstrable consequences of rotational dislocation in our retrospective study we can be brief: the only patient in our series who showed a significant difference in rotation between fracture and unaffected side – a now 35-year-old mason-plasterer – is entirely free from symptoms. Physical and radiological examinations have failed to reveal any untoward consequence of the persistent rotational dislocation, apart from the difference in rotation and some endorotation of the leg in standing and walking. The remaining five patients with a difference in rotation exceeding 10° (cf. Figure 5) likewise show no

demonstrable untoward consequences of a possible rotational dislocation.

## CONCLUSIONS

1. The hitherto accepted criterion for rotational dislocation – 10° or more difference in rotation between fracture side and unaffected side – is inconclusive.
2. There are sound reasons to assume that spontaneous correction of rotational dislocation after femoral shaft fracture in childhood does occur.
3. So far, no clinical evidence has been published to support the hypothesis that persistent rotational dislocation leads to premature arthrosis of adjacent joints.
4. In view of the good results of conventional methods of conservative therapy found in our retrospective study, we maintain that it is unnecessary, or even undesirable, to abandon these methods in favour of the use of Weber's traction table ("Weber Bock").

## ACKNOWLEDGEMENTS

The authors wish to thank the radiological laboratory technicians Miss J. van Wolfswinkel and Mrs J. A. M. de Noorlander-de Bruin for their assistance in the making of the numerous X-rays.

## REFERENCES

Appleton, A. B. (1934) Postural deformities and bone growth. An experimental study. *Lancet* *i*, 451–454.

Arkin, A. M. & Katz, J. F. (1956) The effects of pressure on epiphyseal growth. The mechanism of plasticity of growing bone. *J. Bone Jt Surg.* **38-A**, 1056–1076.

Axer, A., Halperin N. & Itzchak, Y. (1972) Anteversion of the femur in Legg-Calvé-Perthes' syndrome. *Israel J. med. Sci.* **8**, 1733–37.

Baker, L. D., Dodelin, R. & Basset, F. H. (1962) Pathological changes in the hip in cerebral palsy: Incidence, pathogenesis, and treatment. *J. Bone Jt Surg.* **44-A**, 1331–1342.

Beals, R. K. (1969) Developmental changes in the femur and acetabulum in spastic paraplegia and diplegia. *Develop. Med. Child Neurol.* **11**, 303–313.

Bernbeck, R. (1949) Das Problem der Femurtorsion bei Luxationshüften. *Verh. Deutsch. Orthop. Gesellsch.* 37. Kongress (lecture) 201–207, Enke Verlag, Stuttgart.

Best, P. N. B., Verhage, C. Ch. & Molenaar, J. C. (1971) Torsion deviations after conservative treatment of femoral fractures. *Z. Kinderchir.* **11** (Suppl.), 814–821.

Blount, W. P. (1955) *Fractures in children*. Williams and Wilkins Co., Baltimore.

Cyvin, K. B. (1977) A follow-up study of children with instability of the hip joint at birth. *Acta orthop. scand.* Suppl. 166.

Debrunner, M. (1967) *Post-traumatische Achsen Fehlstellungen an den unteren Extremitäten* (Ed. Müller, M. E.) pp. 39–55. Verlag Hans Huber, Bern u. Stuttgart.

De Jong, J. C. D. (1968) De torsio femoris in relatie tot andere kenmerken van het femur. Thesis, Municipal Univ. Amsterdam.

Dunlop, K., Shands, A. R., Hollister, L. C., Gaul, J. S. & Streit, H. A. (1953) A new method for determination of torsion of the femur. *J. Bone Jt Surg.* **35-A**, 289–311.

Dunn, D. M. (1952) Anteversion of the neck of the femur. A method of measurement. *J. Bone Jt Surg.* **34-B**, 181.

Ehalt, W. (1961) *Verletzungen bei Kindern und Jugendlichen*. F. Enke Verlag, Stuttgart.

Engels, M., Lassnig, J. & Manzl, M. (1977) Die konservative Behandlung der Oberschenkelfrakturen. *Z. Kinderchir.* **20**, 79–85.

Fabry, G., MacEwan, G. D. & Shands, A. R. (1973) Torsion of the femur. A follow-up study in normal and abnormal conditions. *J. Bone Jt Surg.* **55-A**, 1726–1738.

Glauber, A. & Vizkelety, T. (1966) The influence of the iliopsoas muscle on femoral antetorsion. *Arch. orthop. Unfall-Chir.* **60**, 71–79.

Gross, F. & Haike, H. (1970) Bestimmung der Genauigkeit und der Fehlerquellen des Rippsteinschen Verfahrens zur Messung der Antetorsion des coxalen Femurendes. *Arch. orthop. Unfall-Chir.* **67**, 234–243.

Herzog, B., Affolter, P. & Jani, L. (1976) Spätfunde nach Marknagelung kindlicher Femurfrakturen. *Z. Kinderchir.* **19**, 74–80.

Hildebrandt, G. (1965) Spätergebnisse konservativ behandelte Oberschenkelfrakturen bei Kindern. *Dtsch. Gesundheitswes.* **20**, 1528–1530.

Hupfauer, W. & Balau, J. (1971) Die konservative Behandlung kindlicher Oberschenkelfrakturen und ihre Ergebnisse. *Mtschr. Unfallheilk.* **74**, 441–456.

Klapp, F., Arfeen, N., Hertel, P. & Scheiberer, L. (1974) Ergebnisse nach konservativer Behandlung der Oberschenkelchaftfraktur im Kindesalter. *Akt. Traumatol.* **4**, 205–210.

König, G. & Schult, W. (1973) Der Antetorsions- und Schenkelhalschaftwinkel des Femur. *Probleme der röntgenologischen Bestimmung und operativen Korrektur*. Enke Verlag, Stuttgart.

- König, G. (1977) Röntgenologische Darstellung des koxalen Femurendes für Winkelmessungen. *Z. Orthop.* **115**, 310–320.
- Laer, von L. (1977) Beinlängendifferenzen und Rotationsfehler nach Oberschenkelschaftfrakturen im Kindesalter. *Arch. orthop. Unfall-Chir.* **89**, 121–137.
- Le Damany, P. (1903a) Les torsions osseuses. Où se font-elles? *J. Anat. (Paris)*, **39**, 313–337.
- Le Damany P. (1903b) Les torsions osseuses: leur rôle dans la transformation des membres. *J. Anat. (Paris)* **39**, 126–165.
- Löfgren, L. (1956) Some anthropometric-anatomical measurements of the femur of Finns from the viewpoint of surgery. *Acta chir. scand.* **110**, 477–484.
- Müller, M. E. (1971) *Die hüftnahen Femurosteotomien, unter Berücksichtigung der Form, Funktion und Beanspruchung des Hüftgelenkes*. Hans Huber Verlag, Bern und Stuttgart.
- Müller, M. E. (1967) *Posttraumatische achsenfehlstellungen an den unteren Extremitäten*. Hans Huber Verlag, Bern und Stuttgart.
- Nicod, L. See Müller, M. E. (1967) pp. 57–77.
- Parvinen, T., Viljanto, J., Paananen, M. & Vilkki, P. (1973) Torsion deformity after femoral fracture in children. *Ann. chir. Gynaec. Fenn.* **62**, 25–29.
- Piroth, P. & Bliesener J. A. (1977) Rotationsfehlstellung nach konservativer Behandlung kindlicher Oberschenkelschaftfrakturen. *Z. Kinderchir.* **20**, 172–180.
- Rehn, J. (1974) *Unfallverletzungen bei Kindern*. Springer Verlag, Berlin, Heidelberg.
- Rippstein, J. (1955) Zur Bestimmung der Antetorsion des Schenkelhalses mittels zweier Röntgenaufnahmen. *Z. Orthop.* **86**, 345–360.
- Ryder, Ch. T. & Crane, L. (1953) Measuring femoral anteversion: the problem and a method. *J. Bone Jt Surg.* **35-A**, 321–328.
- Saxer, U. (1974) Die Behandlung kindlicher Femurschaftfrakturen mit der Vertikalextension nach Weber. *Helv. chir. Acta* **41**, 271–276.
- Saxer, U. (1978) *Die Frakturenbehandlung bei Kindern und Jugendlichen*. (Ed. Weber, B. G., Brunner, Ch. & Freuler, F.) Springer Verlag, Berlin-Heidelberg-New York.
- Schneider, M. (1963) The effect of growth on femoral torsion. An experimental study in dogs. *J. Bone Jt Surg.* **45-A**, 1439–1449.
- Schoppmeier, K. (1977) Die Behandlung kindlicher Oberschenkelschaftbrüche mit dem „Weber-Bock“. Eine Möglichkeit, um Drehverschiebungen mit allen daraus entstehenden Folgen zu vermeiden. *Chirurg* **48**, 348–350.
- Tjong Tjin Tai H. (1974) Femurschaftfracturen bij kinderen. Thesis. R. C. University, Nijmegen. Uitg Elerie, Bennekom.
- Verbeek, H. O. F., Bender, J. & Sawadis, K. (1976) Rotational deformities after fractures of the femoral shaft in childhood. *Injury* **8**, 43–48.
- Vontobel, V., Genton, N. & Schmid, R. (1961) Die Spätprognose der kindlichen dislozierten Femurschaftfraktur. *Helv. chir. Acta* **28**, 655–670.
- Weber, B. G. (1961) Wie kommt der kindliche Einwärtsgang zustande, und was hat er zu bedeuten? *Helv. paediat. Acta* **16**, 82–89.
- Weber, B. G. (1963) Zur Behandlung kindlicher Femurschaftbrüche. *Arch. orthop. Unfall-Chir.* **54**, 713–723.
- Weber, B. G. (1961) Inwieweit sind isolierte extreme Torsionsvarianten der unteren Extremitäten als Deformitäten aufzufassen und welche klinische Bedeutung kommt ihnen zu? *Z. Orthop.* **94**, 287–303.
- Weber, B. G. (1969) Fractures of the femoral shaft in childhood. *Injury* **1**, 65–68.
- Wertheimer, L. G. & Martin, I. V. (1963) Importancia das variacoes dos angulos e diametros do colo e da cabeca do femur nas technicas de osteossintese do colo e de artroplastia do quadril. *Folia clin. biol. S. Paulo* **32**, 115–125.
- Yano, S. & Sawada, M. (1975) Rotationsfehler nach kindlichen Femurschaftfrakturen. *Z. Orthop.* **113**, 119–129.

Correspondence to: K. J. Brouwer, Department of Surgery, Bergweg Ziekenhuis, Bergselaan 62, 3037 CB, Rotterdam, The Netherlands.