

COMPUTED TOMOGRAPHY IN THE ASSESSMENT AND PLANNING OF COMPLICATED TOTAL HIP REPLACEMENT

E. BARMEIR, B. DUBOWITZ & M. ROFFMAN

Departments of Diagnostic Radiology and Orthopaedic Surgery, Johannesburg Hospital and University of the Witwatersrand, Johannesburg, South Africa

Computed tomography (CT) proved useful in the assessment of 14 cases of failed and complicated total hip arthroplasty. CT provided information in the axial plane about the extent of joint pathology and particularly acetabular involvement. The information obtained proved of aid to the orthopaedic surgeon in the operative planning, indicating the best approach and whether bone grafting to the acetabulum was required. In spite of computer artifact created by metallic implants in the scanning field we found that the required information about the bony components of the joint could be obtained.

Key words: acetabulum; computed tomography; hip surgery

Accepted 16.xi.81

Total hip replacement (THR) is a widely used reconstructive procedure in the severely damaged hip joint. Preoperative evaluation of acetabular bone stock as well as the shape and dimensions of the acetabulum and femoral canal are accepted requirements in the planning of this operation (Coventry et al. 1974, Clarke et al. 1976). This is of further value in the selection of a specific type of prosthesis, ensuring the best fit into both acetabulum and femur, thereby decreasing the incidence of stem loosening and femoral fracturing (Murray et al. 1976, Coudane et al. 1980). Thorough preoperative planning is of particular importance in revision total hip arthroplasty, where the anatomy and the landmarks of the joint have been distorted by previous surgery or infection.

The objective of this study was to evaluate the role of CT scanning in providing additional information to that obtained by conventional radiography in the preoperative work-up of failed and complicated THR.

PATIENTS AND METHODS

Between January, 1980 and July, 1981 CT of the hip was performed in 14 patients requiring revision THR, and in cases where it was thought by the clinician and the radiologist that the use of CT would add information to the conventional radiographic findings. The material comprises eight male and six female white patients ranging in age from 30 to 72 years. The scans were done prior to operation following AP and 45° oblique radiographs of the hip in all patients, and arthrography in 12 (11 had previous THR and one patient had previous arthrodesis). Two additional patients were scanned as the plain radiographs suggested complicated hip morphology. One case was of long-standing rheumatoid arthritis with acetabular protrusion, while the second suffered from congenital dislocation of the hip (CDH).

Each patient was examined in the supine position, using a Philips Tomoscan 300 whole body scanner, matrix 256 × 256 (4.2-s scanning time, 3 mm slice thickness and 0 angle of gantry). Scans were obtained at the main acetabular levels (Dubowitz et al. 1981), and were evaluated using a wide window and a high level at the positive mode, to assess bone structure (Shirkhoda et al. 1979). Five illustrative cases are presented, where CT significantly influenced the management.

ILLUSTRATIVE CASE REPORTS

Case 2: A 30-year-old male had sustained a central fracture dislocation of the left hip 2 years previously. Following the injury a total hip arthroplasty was performed. The prosthesis was subsequently removed due to loosening and a revision total hip arthroplasty was performed. The patient presented again with a painful hip. Arthrography demonstrated loosening of the acetabular cup (Figure 1a). CT revealed a large bony defect in the medial acetabular wall (Figure 1b). Based on these findings, the defect was surgically grafted prior to a further THR.

Case 3: A 66-year-old female patient presented with a painful right hip. She had a 25-year history of hip disease. The initial hip pathology could not be determined. The previous management had included a biopsy, radiotherapy, a failed hip arthrodesis, bone grafting and THR. At presentation the prosthesis was clinically loose. Destructive changes were found on radiographs of the joint (Figure 2a) and loosening was confirmed on arthrography. Infection was ruled out by gallium scan and culture. CT scans revealed minimal supportive bone stock at the proposed site for a revision arthroplasty (Figure 2b). Based on these findings and considering the patient's age and mobility it was decided that the case was not suitable for revision arthroplasty. The prosthesis was removed and a Girdlestone procedure was performed.

Case 5: A 38-year-old male patient presented with a painful hip following a left-sided THR 21 months previously. Plain radiographs and arthrography at the time showed loosening of the prosthesis and infection. The septic prosthesis was removed and the area debrided and irrigated (Figure 3a). CT documented marked deficiency and thinning of the medial acetabular wall and the anterior acetabular rim (Figure 3b). The scans confirmed the destruction of the proximal femur. As a result, a Muller anti-protrusion ring was inserted to prevent migration of the prosthesis into the pelvis.

Case 13: A 45-year-old female presented with a painful left hip as a result of congenital dislocation. Plain radiograph demonstrated dislocation of the femoral head and formation of a pseudo-acetabulum (Figure 4a). Preoperative CT scans were performed at the levels of the false and true acetabulae (levels 1 and 2, Figure 4a, respectively). The scan at the level of the pseudo-acetabulum (Figure 4b) demonstrated severe anteversion as well as ectopic bone formation. The scan at the level of the true acetabulum, which was the proposed site for placement of the prosthesis, demonstrated a large false bony shelf of ectopic ossification (Figure 4c). This finding indicated that the shelf of bone created a false acetabular roof at the level of the true acetabulum, and had to be excised in order to provide proper support for the acetabular cup. These CT findings were confirmed at surgery.

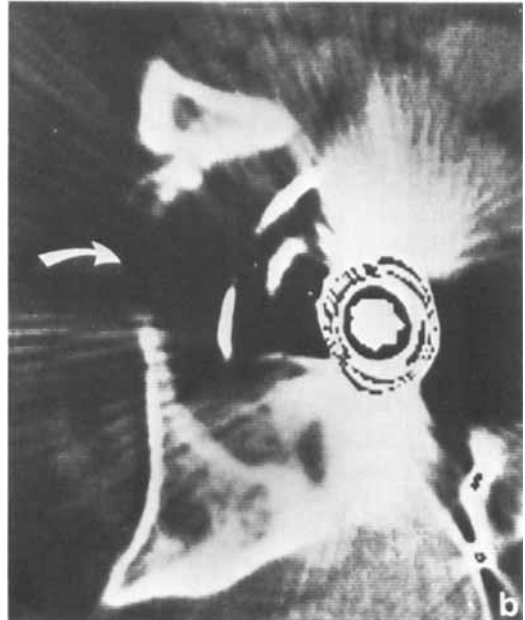
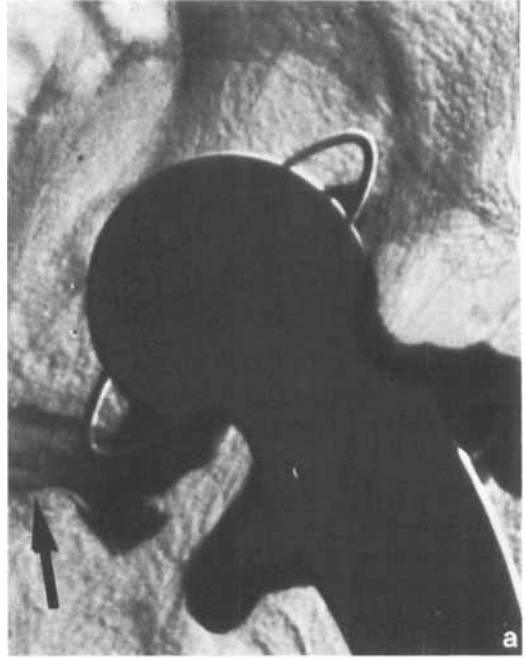

Figure 1 (Case 2). a. Left hip arthrogram demonstrating loosening of the acetabular cup (arrow). b. CT scan of the left hip reveals a large defect of the medial acetabular wall (arrow). This necessitated bone grafting prior to insertion of a further prosthesis.

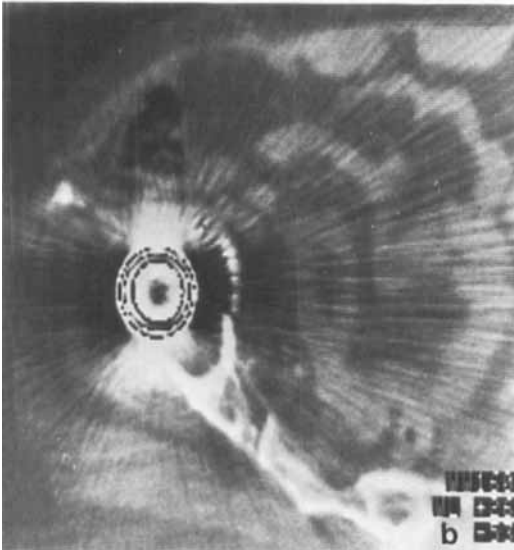
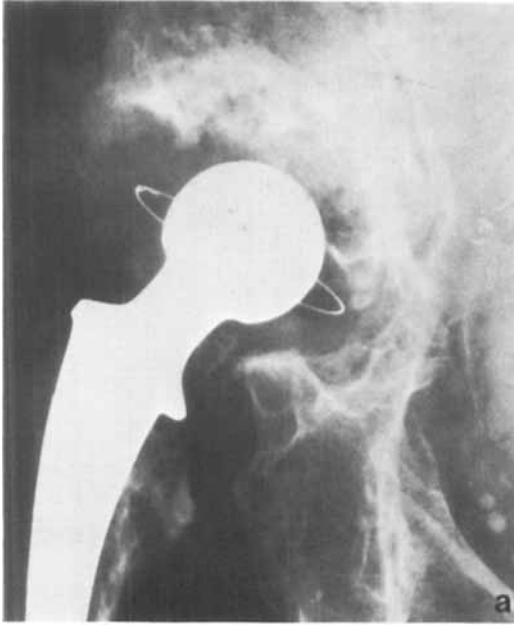

Figure 2 (Case 3). a. Plain radiograph of the right hip shows destructive changes and osteopenia involving the acetabulum. Note difficulty in establishing the completeness of the acetabular fossa. b. CT scan demonstrating minimal amount of bone stock at the proposed site for a revision arthroplasty. In spite of linear computer artifact, created by the metallic prosthesis, the required diagnostic information is obtained.

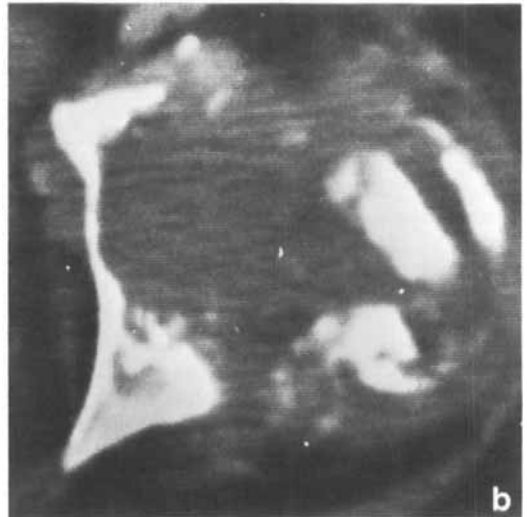
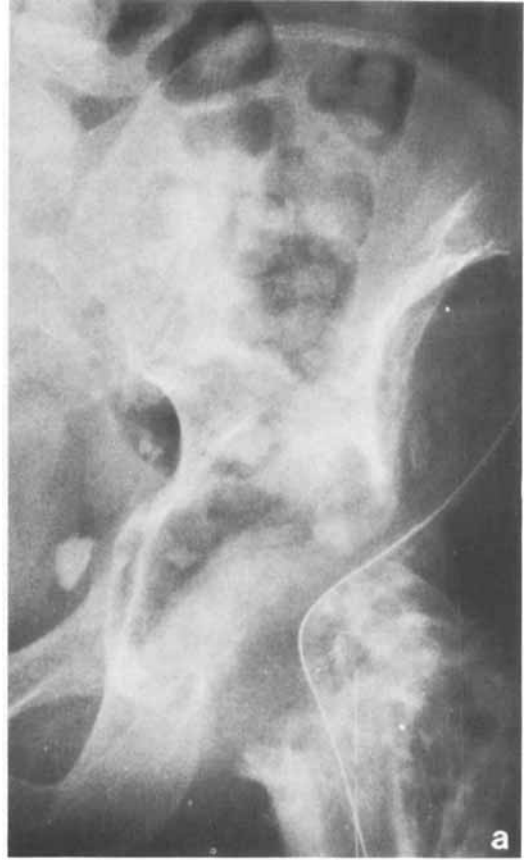

Figure 3 (Case 5). a. Left hip radiograph showing extensive post-infective destructive changes involving the acetabular fossa and femoral head. b. CT scan at the acetabular level delineates the extent of destruction of the medial acetabular wall, anterior acetabular rim and femur.

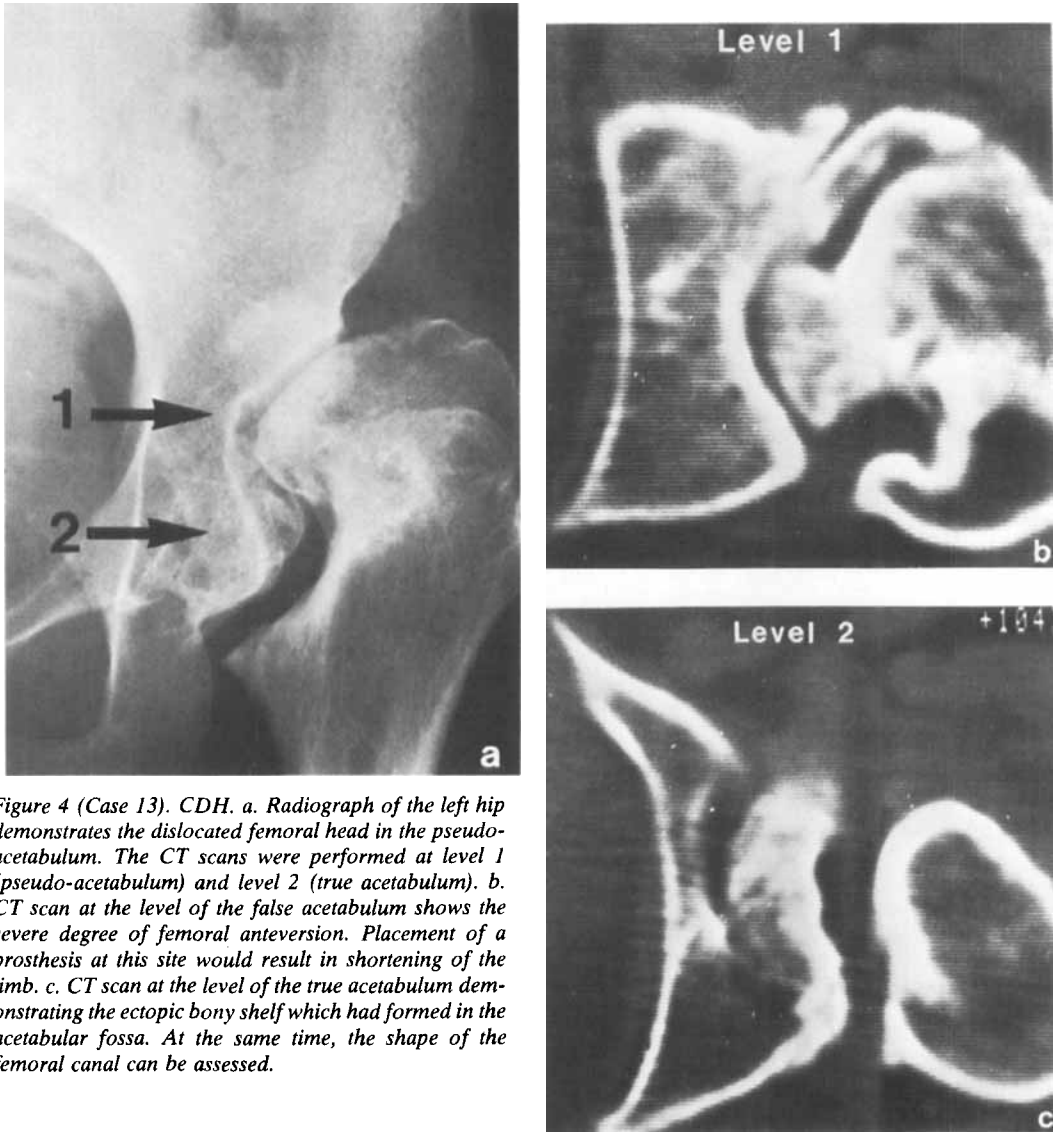


Figure 4 (Case 13). CDH. *a.* Radiograph of the left hip demonstrates the dislocated femoral head in the pseudo-acetabulum. The CT scans were performed at level 1 (pseudo-acetabulum) and level 2 (true acetabulum). *b.* CT scan at the level of the false acetabulum shows the severe degree of femoral anteversion. Placement of a prosthesis at this site would result in shortening of the limb. *c.* CT scan at the level of the true acetabulum demonstrating the ectopic bony shelf which had formed in the acetabular fossa. At the same time, the shape of the femoral canal can be assessed.

Case 14: A 56-year-old female patient presented with a painful right hip. She had a history of 25 years of rheumatoid arthritis. Plain radiographs of the pelvis showed protrusion and fracturing of the right acetabular fossa (Figure 5a). CT scans demonstrated extensive fragmentation and thinning of the protruded medial acetabular wall (Figure 5b, c). This necessitated bone grafting prior to the insertion of the acetabular cup prosthesis.

RESULTS

Table 1 shows the final diagnoses of the 14 patients who underwent surgery, and the contribution of the CT findings to the operative planning. In nine cases CT demonstrated inadequate acetabular bone stock. This led to acetabular bone grafting in seven patients (cases 1, 2, 8, 11, 12, 13 & 14), prior to the insertion of an acetabular cup prosthesis. In case 3 a Girdlestone procedure was decided upon, and in case 5 an

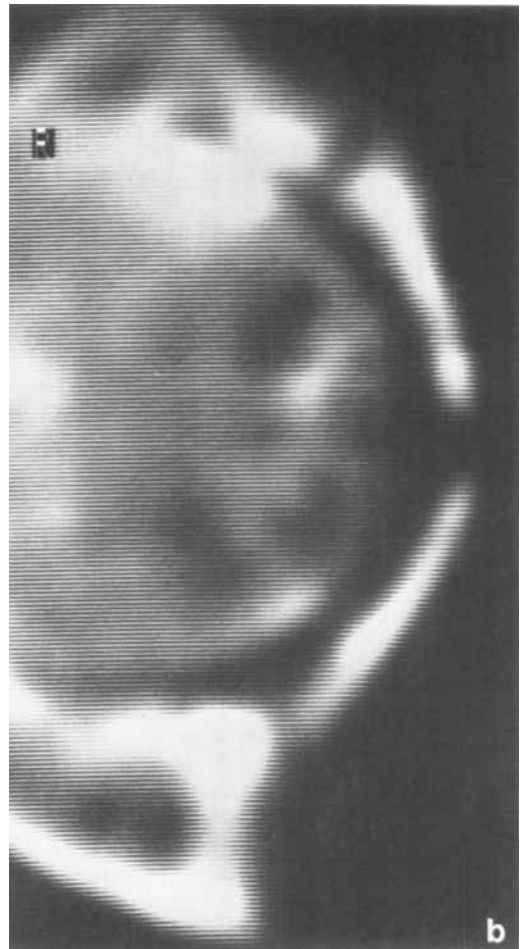
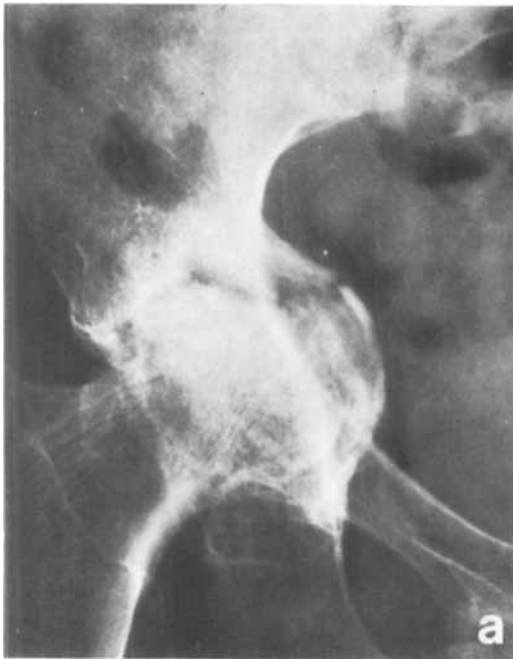

Figure 5 (Case 14). Rheumatoid arthritis. a. Radiograph of the pelvis shows protrusion of the right acetabulum and a fracture. b. CT scan at the acetabular level reveals fragmentation and thinning of the medially protruded acetabulum. Note cystic changes in the femoral head and the fracture of the anterior acetabular rim. These features are not demonstrated adequately by the plain radiograph.

anti-protrusion ring was inserted. In five patients CT showed an intact acetabulum (cases 4, 6, 7, 9 & 10, Table 1). This finding was of particular help in cases 4, 6 and 9 where infection had been documented. CT was useful in case 13, providing additional information about femoral anteversion and intra-articular heterotopic bone formation. In case 14 CT demonstrated acetabular fragmentation, not appreciated on the conventional radiographs.

DISCUSSION

The applications of CT in clinical orthopaedics are constantly increasing. CT is a rapid means of investigation, providing high resolution trans-axial visualization of the hip joint. It allows spatial orientation not available previously from two-dimensional conventional radiography (Blumberg 1980). Accurate measurements of bone thickness, angles and density can be readily made, and the radiation dose is reduced by obtaining only the clinically relevant scan levels. A single cut through the medial acetabular wall is achieved by scanning at the mid-point between the anterior-superior iliac spine and the pubic

Table 1. Summary of cases

Case	Age/Sex	Clinical data	Radiographic findings	CT findings	Treatment
1	58/M	Painful left hip. Previous THR	Infective changes Marked osteoporosis	Destruction of anterior & medial acetabular walls	Bone grafting. Revision THR
2	30/M	Fracture dislocation left hip THR	Loosening of prosthesis	Defect of medial acetabular wall	Bone grafting. Revision THR
3	66/F	Painful right hip. Previous THR	Loosening of acetabular cup	Minimal acetabular bone stock	Removal of prosthesis. Girdlestone procedure
4	55/M	Painful left hip. Previous THR	Infective changes Loosening of prosthesis	Intact medial wall	Antibiotic irrigation. Revision THR
5	38/M	Painful left hip. Previous THR	Osteopenia Loosening of acetabular cup	Thinning of medial & anterior acetabulum	Revision THR. Insertion of Muller anti-protrusion ring
6	62/M	Painful left hip. Previous THR	Infection and extravasated contrast material	Multiple infected bursae anteriorly. Intact acetabular wall	Infected haematomas drained. Antibiotic irrigation. Revision THR
7	50/M	Painful left hip. Previous arthrodesis	Pseudoarthrosis formation	Fusion of femoral head & acetabulum. Pseudoarthrosis of femoral neck	THR
8	53/F	Painful left hip. Previous THR	No loosening Osteopenia	Marked thinning of medial acetabular wall	Bone grafting. Revision THR
9	68/M	Painful left hip. Previous THR	Osteoporosis Infection	Intact acetabulum	Aspiration & antibiotic irrigation. Revision THR
10	73/F	Painful right hip. Previous THR	Loosening of acetabular cup	Intact acetabulum	Revision THR
11	31/M	Painful right hip. Previous THR	Loosening of prosthesis	Large defect in medial acetabular wall	Bone grafting. Revision THR
12	48/F	Painful left hip. Previous THR	Loosening of acetabular cup	Fragmentation & thinning of medial acetabular wall	Bone grafting. Revision THR
13	45/F	CDH Osteoarthritis	Dislocated femur Pseudo-acetabulum formation Osteoarthritis	Marked anteversion Formation of ectopic bone shelf at true acetabulum. Good bone stock	THR Correction of anteversion. Insertion of cup at true acetabulum
14	56/F	Rheumatoid arthritis. Painful right hip	Protrusio acetabulum Linear fracture ? exact site	Fragmentation of protruded acetabulum. Fracture localized to anterior acetabular rim	Acetabular bone grafting. THR

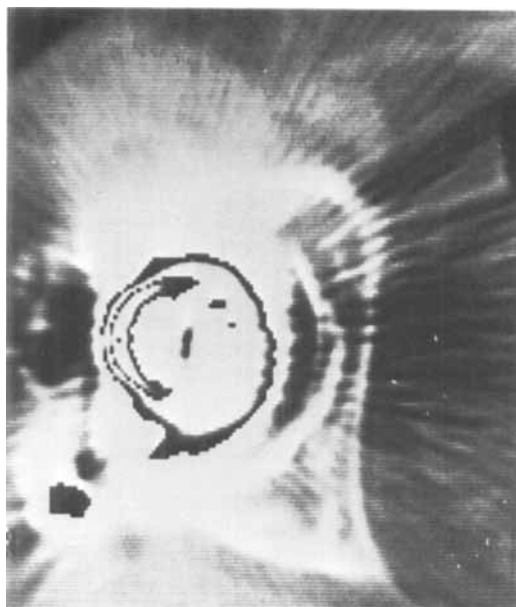


Figure 6 (Case 10). CT scan of the right hip demonstrating intact medial acetabular wall and good bone stock.

tubercle (Dubowitz et al. 1981). CT has already been shown to be of value in hip trauma (Sauser et al. 1980, Shirkhoda et al. 1980), hip dislocation (Padovani et al. 1979), osteochondral graft assessment (Roffman et al. 1981), femoral anteversion and acetabular inclination studies (Weiner & Cook 1980) as well as in delineating tumour extent (Lasda et al. 1978, Heelan et al. 1979, Laursen & Reiter 1980, Federle et al. 1980).

In the assessment of complicated and failed hip arthroplasty the surgeon requires the following information: 1) the extent of involvement of the acetabulum by a pathological process 2) the thickness and shape of the acetabular fossa and femoral canal for the selection of an adequate prosthesis, 3) the amount of bone stock available for fixation of an acetabular cup and 4) whether bone grafting is required as a first surgical step. Our study shows that this information is obtainable by CT scanning of the hip, while extremely difficult to obtain by conventional methods. CT documented the need for acetabular bone grafting by demonstrating destruction and thinning of the acetabular fossa in nine cases.

Thus CT influenced the management, as the performance of an arthroplasty without first grafting this area, or inserting an anti-protrusion ring, would have resulted in failure. CT was a particularly useful modality in assessing the infected joint. By demonstrating intact acetabular fossa and normal thickness of the medial acetabular wall (Figure 6), it obviates the need for bone grafting and confirms that the loosening of the prosthesis is basically mechanical.

Important additional information about femoral anteversion is obtained by scanning through the femoral neck. An optional scan at the level of the femoral shaft, demonstrating the shape of the femoral canal, is of aid in the selection of a specific type of prosthesis. As illustrated in case 13, CT disclosed a marked degree of anteversion of the dislocated femur (Figure 4). In this case CT provided the surgeon with vital information, not only about the right position for insertion of the prosthesis, but demonstrated as well the degree of anteversion of the femoral shaft to be corrected, the need for excision of the abnormal ectopic bony shelf and the adequate bone stock of the true medial acetabular wall.

Our experience correlating CT with surgical findings in 12 cases of failed hip replacement and two cases of complicated hip abnormality suggests that significant additional information is gained preoperatively with the use of this modality. This application of CT, to the best of our knowledge, has not yet been described. The presence of metallic implants in the scanning field creates computer artifact; however, we found that sufficient information about the bony components of the joint could be obtained. Some newer CT scanners have a special algorithm eliminating the artifact from the images, thus improving the picture quality.

We do not advocate the routine use of CT in the assessment of THR. We however suggest that the examination should be tailored and selected for the individual clinical problem.

REFERENCES

- Blumberg, M. L. (1980) Computed tomography and acetabular trauma. *J. Comput. Assist. Tomogr.* **4**, 47-53.

- Clarke, I. C., Gruen, T., Matos, M. & Amstutz, H. C. (1976) Improved methods for quantitative radiographic evaluation with particular reference to total hip arthroplasty. *Clin. Orthop.* **121**, 83-91.
- Coudane, H., Fery, J., Sommelet, J., Lacoste, L. P. & Gaucher, A. (1981) Aseptic loosening of cemented total arthroplasties of the hip in relation to positioning of the prosthesis. *Acta Orthop. Scand.* **52**, 201-205.
- Coventry, M., Beckenbaugh, R. D., Nolan, D. R. & Ilstrup, D. (1974) 2012 total hip arthroplasties: A study of post operative course and early complications. *J. Bone Joint Surg.* **56-A**, 273-284.
- Dubowitz, B., Barmeir, E., Stein, M. & Roffman, M. (1981) Normal axial anatomy of the hip as demonstrated by computed tomography. *Clin. Radiol.* **32**, 663-668.
- Federle, M. P., Moss, A. A. & Margolin, F. R. (1980) Role of computed tomography in patients with "sciatica". *J. Comput. Assist. Tomogr.* **4**(3), 335-341.
- Heelan, R. T., Watson, R. C. & Smith, J. (1979) Computed tomography of lower extremity tumors. *Am. J. Roentgenol.* **132**, 933-937.
- Lasda, N. A., Levinsohn, E. M., Yuan, H. A. & Bunnell, W. P. (1978) Computerized tomography in disorders of the hip. *J. Bone Joint Surg.* **60-A**, 1099-1102.
- Laursen, K. & Reiter, S. (1980) Computed tomography in soft tissue disorders of the lower extremities. *Acta Orthop. Scand.* **51**, 881-885.
- Murray, M. P., Gore, D. R., Brewer, B. J., Zuege, R. C. & Gardner, G. M. (1976) Comparison of functional performance after McKee-Farrar, Charnley and Muller total hip replacement. *Clin. Orthop.* **121**, 33-43.
- Padovani, J., Faure, F., Devred, P., Jacquemier, M. & Sarrat, P. (1979) Use and advantages of CT in testing congenital luxations of the hip. *Ann. Radiol. (Paris)* **22** (2-3), 188-193.
- Roffman, M., Dubowitz, B. & Barmeir, E. (1981) CT assessment of osteochondral grafts. Presented at the 15th International Congress of Radiology, Brussels, June 1981.
- Sausser, D. D., Billimoria, P. E., Rouse, G. A. & Mudge, K. (1980) CT evaluation of hip trauma. *Am. J. Roentgenol.* **135**, 269-274.
- Shirkhoda, A., Brashear, H. R. & Staal, E. V. (1980) Computed tomography of acetabular fractures. *Radiology* **134**, 683-688.
- Shirkhoda, A., Johnston, R. E. & Staal, E. V. (1979) Optimal computed tomography technique for bone evaluation. *J. Comput. Assist. Tomogr.* **3**, 134-139.
- Weiner, D. S. & Cook, A. S. (1980) Practical considerations in the use of computed tomography in the measurements of femoral anteversion. *Isr. J. Med. Sci.* **16**, 288-294.

Correspondence to: Dr. M. Roffman, Department of Orthopaedic Surgery, Medical School, University of the Witwatersrand, Esselen Street, Johannesburg 2000, South Africa