

## MIGRATION OF THE FEMORAL STEM IN HIP ARTHROPLASTIES

### *Analysis of Associations with Structural, Radiological and Follow-up Variables*

ODD SÖREIDE, JOSTEIN LILLESTÖL, ANTTI ALHO & KONRAD HVIDSTEN

Department of Surgery and Diagnostic Radiology, University Hospital, Bergen, and the Norwegian School of Economics and Business Administration, Bergen, Norway.

Medial and/or distal migration of the prosthetic stem was found in 63 out of 337 patients (19 per cent) treated surgically with a Christiansen hemiprosthesis, a Christiansen total hip prosthesis or a Charnley total hip prosthesis.

Fractured bone cement, radiolucent zones at the cement/bone interface, resorption of the femoral calcar and cortical sclerosis were all associated with migration. Varus position of the Christiansen total hip prosthesis was significantly associated with medial migration, and a short stem was significantly associated with distal migration. The other structural variables could not be linked with migration. Distal migration was pain-inducing and was significantly associated with late infection. Medial migration had a less distinct association with pain, and was not correlated with infection. Both medial and distal migration were time-dependent, and 4 or more years after operation about 25 per cent of the prosthetic stems had migrated.

*Key words:* hip prosthesis

Accepted 18.v.81

Endoprosthetic replacement of the hip is a well accepted surgical method, and satisfactory results have been obtained for both total hip replacement and hemiprosthetic replacement. The need for this type of surgery, especially for total hip replacement, is increasing (Hori et al. 1978).

Endoprosthetic replacement is not without hazards. The operation itself can be considered safe and the complications in the immediate postoperative period are not directly life threatening. However, as the follow-up period increases, problems related to implant failure have been encountered, problems which may lead to unsatisfactory function and poor results.

In this paper we will focus on problems related to loosening of the prosthetic stem. Despite numerous follow-up reports many central questions concerning implant failure remain unanswered.

We will try to elucidate the following problems, all related to the femoral component: 1) What

are the X-ray findings associated with femoral stem loosening, and what is their relative importance? 2) Is loosening associated with the structure of the prosthesis, the operative techniques or the complications of the procedure? 3) To what extent do the clinical symptoms and signs correlate with loosening, and is there a time factor associated with loosening of the femoral stem?

### MATERIAL AND METHODS

Three hundred and thirty-seven patients treated surgically with a hip prosthesis during the period 1971-1977 were analysed. (The analysis has been performed retrospectively, and all information was taken from available radiographs and patient records). Of these, 214 patients were treated with a Christiansen hemiprosthesis [117 prostheses with a long stem (160 mm), 97 with a short stem (130 mm)] (Söreide et al. 1975), 84 patients with a Christiansen total hip prosthesis [44 prostheses with a long stem (160 mm), 40 with a short stem (130 mm)] (Sundal et al. 1974) and 29 patients with a

Table 1. Variables under study. Variables 1–7 are radiographic changes related to the prosthetic/cement/bone interfaces. Variables 6–12 are structural variables, and Variables 13–19 are follow-up variables

Variable name		Categories
1. Medial migration	No (0)	Yes (1)
2. Distal migration	No (0)	Yes (1)
3. Cement fracture	No (0)	Yes (1)
4. Radiolucent zones	No (0)	Yes (1)
5. Ectopic bone formation	No (0)	Yes (1)
6. Cortical thickening (sclerosis)	No (0)	Yes (1)
7. Resorption of calcar	No (0)	Yes (1)
8. Cement length	Proximal to tip of stem (0)	To tip or distal (1)
9. Cement quantity	Not optimal (0)	Sufficient (1)
10. Position of femoral stem	Varus (0)	Neutral or valgus (1)
11. Length of stem (in Christiansen prostheses)	Short stem (0)	Long stem (1)
12. Length of neck (in Christiansen total hip prostheses)	Short (0)	Medium (1)
13. Follow-up time	0–12 months (0)	Long (2)
	25–48 months (2)	13–24 months (1)
		≥49 months (3)
14. Patients' personal opinion	Good (0)	Not satisfactory (1)
15. Ability to walk	Normal (0)	Restricted (1)
16. Pain	No (0)	Yes (1)
17. Range of movement	Good (0)	Restricted (1)
18. Infection	No (0)	Yes (1)
19. Reoperation	No (0)	Yes (1)

The numbers given in parenthesis indicate the categories for each variable.

Charnley hip prosthesis (Charnley & Cupic 1973). The follow-up period was from 1–84 months. One hundred and eighty hips were followed up for more than 1 year, 91 for more than 2 years, and 40 for more than 4 years. A total of 52 variables concerning preoperative status, operative and technical data, primary and follow-up X-ray findings as well as clinical follow-up data were collected. The variables submitted for analysis are given in Table 1.

**Radiographic analysis.** The latest available X-rays for each patient were compared with the primary postoperative X-ray films. All X-rays were taken in a standardized way, and the magnification effect varied from 10–20 per cent.

Medial migration, as seen in the a–p view, was recorded in millimetres. The term migration signifies a deviation of the initial stable femoral component, and the migration was measured at the highest lateral point of the prosthetic stem below the collar. The total movement of the stem in relation to the femoral shaft was recorded. The movement components were between stem and cement and/or between cement and bone. Distal migration was recorded as the difference in distance on the X-ray films from the highest medial point of the prosthetic stem to a horizontal line drawn through the tip of the lesser trochanter (a–p view).

Fracture lines in the cement, their locations and their time of appearance were recorded. Appearance of a clear zone between stem and cement laterally was also taken as a sign of cement fracture (Miller et al. 1978). Radiolucent zones were readily observed at the cement/bone interface. A reactive sclerosis was seen in the bone close to the gap. Cortical thickening was observed as irregular changes around the prosthetic stem area, or a localized change laterally near the tip of the stem. Resorption of the calcar was registered medially below the prosthetic collar.

The quantity of cement was taken to be sufficient when the acrylic surrounded the stem from the collar to beyond the tip, and extended to the cortical bone medially and laterally in the a–p view. A deviation of more than 2° of the prosthetic stem axis and the femoral axis from their positions on the primary postoperative radiographs (a–p view) was recorded as either a valgus or varus position of the femoral stem.

The patients' personal opinion was recorded as good, fair or poor. The latter two categories were grouped as not satisfactory. The ability to walk was considered normal when the patient was able to walk out-of-doors without walking aids, and restricted if walking aids were needed or if a more severe limitation in walking ability was present. Pain was recorded as no pain, minor pain when walking, pain restricting walking, and pain at rest.

From the statistical analysis, the dichotomy present/absent was found useful. A good range of motion was considered present if flexion was more than 90° with a flexion contracture of less than 10°. A limitation in movement greater than this was considered as restricted.

*Statistical analysis.* A preliminary screening was performed by pairwise analysis of the variables. The *P*-values for testing no association (based on chi-square analysis) in each two-way table were used as a screening device. The variables were grouped according to the categories given in Table 1. The relationship between the variables found to be of interest were further elucidated by analysing various multidimensional frequency tables based on log-linear models (Fienberg 1977, Søreide 1980). The main purpose was to uncover and quantify the effects of each variable, direct interactions between two variables and higher order interactions between more than two variables. An interaction in this paper is regarded as strong when the effect parameter in the log-linear fit is of a magnitude twice that of the standard error or greater, and weak if it is of a lesser magnitude but still greater than the standard error. A direct association was either positive (0-0; 1-1) or negative (0-1; 1-0) according to the categories given in Table 1. Some of the variables found not to be significant in the preliminary screening were added because of

concern that some secondary effects might be missed in the simple two-way analysis.

The main computations were performed with the ECTA-program package implemented on the UNIVAC-1100 installation at the University of Bergen.

## RESULTS

Objective evidence of migration of the femoral stem was found in 63 of the 337 patients (19 per cent). Medial migration, ranging from 1-28 mm (mean 3.8 mm) was found in 55 patients, and distal migration, ranging from 1-40 mm (mean 10.6 mm) in 36 patients. Tables 2 and 3 give the relationship between the degree of migration and the follow-up period.

### *Femoral stem migration and explanatory variables*

The *P*-values for testing pairwise independence between the roentgenographic variables (1-7)

Table 2. Medial migration and follow-up period (months). Observed counts and columnwise relative frequencies

	Follow-up period				Total
	1-12	13-24	25-48	≥49	
None	152 (96.8)	70 (78.7)	30 (60.0)	29 (72.5)	281 (83.6)
1 mm	5	7	4	2	18
2-4 mm	0 (3.2)	10 (21.3)	10 (40.0)	2 (27.5)	22 (16.4)
≥5 mm	0	2	6	7	15
Total	157	89	50	40	336

Table 3. Distal migration and follow-up period (months). Observed counts and columnwise relative frequencies

	Follow-up period				Total
	1-12	13-24	25-48	≥49	
None	157 (100)	80 (89.9)	34 (66.7)	30 (75.0)	301 (89.3)
1 mm	0	0	1	0	1
2-4 mm	0 (0.0)	2 (10.1)	4 (33.3)	1 (25.0)	7 (10.7)
≥5 mm	0	7	12	9	28
Total	157	89	51	40	337

Table 4. *P*-values for testing independence of the radiographic variables

Variable name	1	2	3	4	5	6	7
1. Medial migration	—	.00	.00	.00	.90	.00	.00
2. Distal migration		—	.00	.00	.95	.00	.00
3. Cement fracture			—	.00	.67	.00	.01
4. Radiolucent zones				—	.60	.00	.09
5. Ectopic bone formation					—	.05	.55
6. Cortical sclerosis						—	.00
7. Resorption of the calcar							—

are given in Table 4. It is seen that ectopic bone formation (5) is the only variable that can be safely excluded as an explanatory variable for migration of the stem ( $P > 0.10$ ). Ectopic bone formation also shows little association with the other variables, except possibly with cortical thickening (6) ( $P = 0.05$ ). There are highly significant associations between the other radiological variables, indicating a possible danger in interpreting the associations solely in terms of two-way analysis.

Medial migration (1) and the radiological variables cement fracture (3), radiolucent zones (4), cortical thickening (6) and resorption of the calcar (7) were further analysed by fitting log-linear models to the data. A model with only first order interactions between each pair of variables (no higher order interactions) gave good fit to the data and is schematically displayed in Figure 1. (The revealed interactions were all positive according to the categories given in Table 1.) Pairs of variables with no apparent direct interaction

are unconnected in Figure 1, and a log-linear model assuming the non-existence of these interactions gave good fit to the data. Thus, medial migration (1) had a strong interaction with cement fracture (3) and resorption of the calcar (7), and a weaker interaction with radiolucent zones (4) and cortical thickening (6). Figure 1 also suggests that the highly significant associations between medial migration (1) and radiolucent zones (4) and between medial migration (1) and cortical thickening (6) shown in Table 4 may be partly explained by the direct interactions between the explanatory variables.

A similar log-linear analysis involving distal migration (2) and the same radiological variables [(3), (4), (6), (7)] has also been performed. The patterns are about the same as for medial migration, the interactions between distal migration and resorption of the calcar are still strong, but the interactions between distal migration and cement fracture, between distal migration and radiolucent zones, and between distal migration

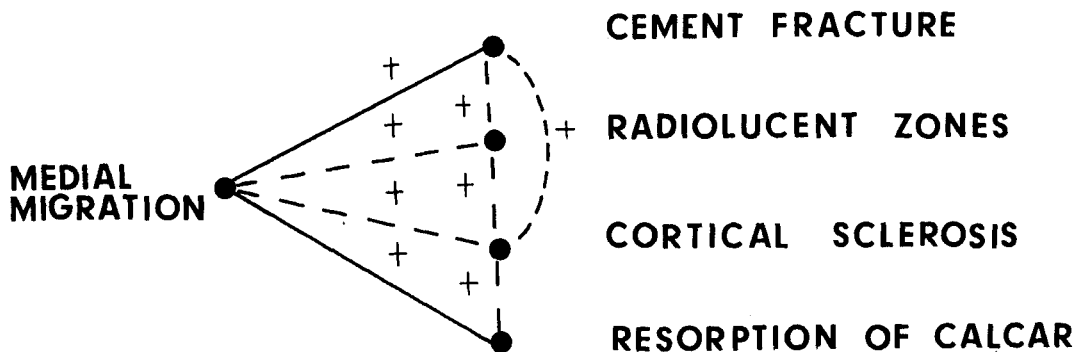


Figure 1. Revealed associations between medial migration and the radiological variables (solid lines = strong associations. Broken lines = weaker associations).



Table 6. Three-way table for observed counts for pain and the migration variables

Pain	Medial migration		Distal migration	
	Absent	Present	Absent	Present
Absent	119	20	129	10
Present	107	31	114	24

association with personal opinion ( $P = 0.02$ ) and pain ( $P = 0.02$ ), and a possible association with ability to walk ( $P = 0.06$ ) and range of movement ( $P = 0.08$ ). All these associations were positive. Table 6 gives the frequency distribution between pain and the migration variables. Distal migration was absent in 93 per cent of the painless hips, and present in 19 per cent of the painful hips, compared to 86 and 23 per cent, respectively, for the patients with medial migration. Infection (18) was significantly associated with distal migration ( $P = 0.02$ ), but not with medial migration ( $P > 0.10$ ). (The infection rate at the end of the follow-up period was 3.3 per cent). Reoperation (19) was significantly associated with distal migration ( $P < 0.01$ ) but not with medial migration ( $P > 0.10$ ).

The associations between each migration variable and the clinical variables (14–17) were further studied by fitting log-linear models to the data. Assuming no higher order interactions, the first order interactions between any pair of the migration and clinical variables were, however, all non-significant in both five-variate models under study. (This can be explained partly by larger standard errors in large models, and partly by the interactions between the clinical variables (Table 5)). Although each migration variable made only a minor contribution towards explaining the clinical symptoms, the total effect was significant as reflected in the two-way analysis.<sup>1</sup>

### Femoral stem migration and follow-up time

Medial and distal migration showed a strong time dependency for all patients ( $P < 0.001$ ) (Tables 2 and 3). The time course relationships were similar (taking standard errors into account).

### DISCUSSION

An analysis of postoperative X-ray changes, and their association with technical and clinical data was the basis of this study. We found dichotomies sufficient for the statistical analysis. The number of relatively short follow-ups, which usually do not give much information, was comparatively high. However, a sufficient number of longer follow-ups was available to give statistically significant information.

The patients treated with a hemiprosthesis belong to a different category from the patients electively treated with total hip prostheses. However, no significant differences were found between these two groups other than technical factors relating to the experience of the operating surgeon, i.e. quantity of cement and position of the femoral stem.

Measurements on X-ray films imply a magnification error which in our laboratory was found to vary from 10–20 per cent. This error is marginal compared to the distinct changes which were found to appear during the follow-up period. Theoretically, it is possible to interpret any X-ray magnification error as migration. However, when in doubt, all available X-ray films were studied, and the progressive nature of the X-ray changes were in all cases readily identified.

In the present study we describe loosening of the femoral stem by migration of the prosthetic stem, in the medial and/or distal direction. The same methodological approach was also chosen by McBeath & Foltz (1979), whereas Weber &

<sup>1</sup> For the patients treated with hemiprosthesis, the interactions between the clinical variables were studied in a previous paper dealing mainly with protrusion (Søreide 1980). We found (by log-linear analysis) that the migration variables were linked to pain and to the other clinical variables via protrusion. We found a positive association between distal migration and protrusion, but not between medial migration and protrusion. In addition, a second order interaction for the group protrusion, medial migration, distal migration was found.

Charnley (1975) suggested that sinking of the prosthetic stem in cases with fractured cement is not identical with a loose prosthetic stem. We have identified the radiographic features associated with migration and have analysed their interactions. Fractured bone cement, radiolucent zones at the cement-bone interface, resorption of the medial femoral neck (calcar) and sclerotic bone reaction at the level of the prosthetic tip are all radiological features associated with migration of the prosthetic stem. Although we readily admit that not all migrating stems are clinically loose, there is evidence (Beckenbaugh & Ilstrup 1978, Gruen et al. 1979, Weber & Charnley 1975) indicating a progression from minimal migration, on the one hand, to an obvious loose stem on the other. Thus by combining all migrating and loose prosthetic stems, we can possibly obtain information concerning radiological and clinical changes associated with loosening. Some details regarding the relative importance of each of the radiological findings have been revealed, with some X-ray findings being found to have a closer association with medial migration than with distal migration. Mendes (1973) has stated that two or more of the radiological findings were present in cases with loosening. This statement can readily be explained by the interactions revealed between the loosening variables, which indicate that if one radiological sign is found, it is also likely that other radiological signs are present.

Among the structural variables we found that a varus position of the Christiansen total hip prosthesis predisposes to medial migration. Weber & Charnley (1975) found that a varus or valgus position of the stem was not associated with fracture of the acrylic cement, which in our view is one of the signs of loosening. Furthermore, Bocco et al. (1977) could not demonstrate any association between a varus position of the stem and resorption of the calcar. The length of the stem does not, in general, seem to be of importance for the occurrence of loosening except that distal migration was less likely with a long stem.

An increase in the rate of radiological loosening has been found with an increasing follow-up period. In the present study, this general picture was the same for hemiprostheses and for total hip prostheses. The incidence was 25 per cent 4 or

more years after operation. However, our data should be treated with care. It is possible that some selection occurred due to more frequent follow-up examinations of patients with migration (note association with postoperative pain). However, although the figure is relatively high, it is not essentially different from the frequencies of loosening reported earlier (Beckenbaugh & Ilstrup 1978, Gruen et al. 1979, Maier et al. 1977, Mendes 1973, Wilson et al. 1972).

Faced with the problem of a time-dependent incidence of loosening and the finding that the structural parameters only play a minor part in explaining migration, we have to focus on the problem of why loosening occurs. In cases with infection the cause-effect is obvious (Charnley & Cupic 1973, Charosky et al. 1973, Maier et al. 1977, Mendes 1973). In our work a similar relationship was also established in cases with distal migrating stems. The other causes of migration and loosening (so-called sterile loosening) are more difficult to explain, and many factors including technical factors, are involved (Miller et al. 1978, Swanson 1978).

We cannot make a significant contribution to the discussion of the loosening process. Our findings showed that infection predisposed to distal migration, but not to medial migration. Medial migration was, on the other hand, associated with a varus position of the prosthetic stem. This may indicate that the loosening and migration process may be different in the two types of migration.

The importance of loosening and migration is put into focus by their relationship with the clinical variables, especially pain. Patterson & Selby Brown (1972) stated that the onset of pain is a symptom of late loosening, and McBeath & Foltz (1979) that loosening was generally detected before it became symptomatic. Charnley & Cupic (1973) found that all failures (i.e. painful hips) had radiological signs. Charosky et al. (1973) found pain to be prominent in patients with loosening, whether this was due to infection or was so-called "sterile" loosening. So far, we cannot give information about the correlation between the degree of migration and the clinical symptoms. It appears that radiological loosening associated with pain have a different and greater

importance than painless radiological loosening.

The practical consequences of our findings are that all patients treated with hip prostheses should be followed up with serial radiographic evaluations to allow early recognition of the onset of the radiological changes related to migration. Maier et al. (1977) found a figure of 30.6 per cent for overall serious complications which gave or will give rise to reoperations. On the other hand, Beckenbaugh & Ilstrup (1978) operated on only one-third of patients with diagnosed loosening.

## REFERENCES

- Beckenbaugh, R. D. & Ilstrup, D. M. (1978) Total hip arthroplasty. A review of three hundred and thirty-three cases with long follow-up. *J. Bone Joint Surg.* **60-A**, 306–313.
- Bocco, F., Langan, P. & Charnley, J. (1977) Changes in the calcar femoris in relation to cement technology in total hip replacement. *Clin. Orthop.* **128**, 287–295.
- Charnley, J. & Cupic, Z. (1973). The five and ten year results of the low-friction arthroplasty of the hip. *Clin. Orthop.* **95**, 9–25.
- Charosky, C. B., Bullough, P. G. & Wilson, P. D. (1973) Total hip replacement failures. A histological evaluation. *J. Bone Joint Surg.* **55-A**, 49–58.
- Fienberg, S. E. (1977) *The analysis of cross-classified categorical data*. The MIT Press.
- Gruen, T. A., McNeice, G. M. & Amstutz, H. C. (1979) "Modes of failure" of cemented stem-type femoral components. A radiographic analysis of loosening. *Clin. Orthop.* **141**, 17–27.
- Hori, R. Y., Lewis, J. L., Zimmermann, J. R. & Compere, C. L. (1978) The number of total joint replacements in the United States. *Clin. Orthop.* **132**, 46–52.
- Maier, S., Griss, P., P., Rahmfeld, T. & Dinkelacker, T. (1977) Nachuntersuchungsergebnisse der totalen Alloarthroplastik der Hüfte unter besonderer Berücksichtigung der Spät komplikationen 4 bis 7 Jahre post operationen. *Z. Orthop.* **115**, 274–283.
- McBeath, A. A. & Foltz, R. N. (1979) Femoral component loosening after total hip arthroplasty. *Clin. Orthop.* **141**, 66–70.
- Mendes, D. G. (1973) Roentgenographic evaluation in total hip replacements. *Clin. Orthop.* **95**, 104–110.
- Miller, J., Burke, D. L., Stachiewicz, J. W., Ahmed, A. M., & Kelebay, L. C. (1978) Pathophysiology of loosening of femoral components in total hip arthroplasty. In: *The Hip*. Proc. of the sixth open scientific meeting of the Hip Society. pp. 64–86, The C. V. Mosby Company, Saint Louis.
- Patterson, F. B. & Selby Brown, C. (1972) The McKee Farrar total hip replacement. Preliminary results and complications of 368 operations performed in five general hospitals. *J. Bone Joint Surg.* **54-A**, 257–275.
- Swanson, S. A. V. (1978) The state of the art in joint replacement. Part 3: Results, problems and trends. *J. Med. Eng. Technol.* **2**, 16–20.
- Sundal, B., Kavlie, H., & Christiansen, T. (1974) Total hip replacement with a new trunnion-bearing prosthesis (The Christiansen prosthesis). A report on the prosthesis and the early results. *Acta Chir. Scand.* **140**, 189–193.
- Søreide, O., Lerner, A. P. & Thunold, J. (1975) Primary prosthetic replacement in acute femoral neck fractures. *Injury* **6**, 286–293.
- Søreide, O. (1980) Treatment of acute femoral neck fractures in the elderly with emphasis on the internal fixation-prosthetic replacement controversy. Thesis, University of Bergen.
- Weber, F. A. & Charnley, J. (1975) A radiological study of fractures of acrylic cement in relation to the stem of a femoral head prosthesis. *J. Bone Joint Surg.* **57-B**, 297–301.
- Wilson, P. D., Amstutz, H. C., Czerniecki, A., Salvati, E. A., & Mendes, D. G. (1972) Total hip replacement with fixation by acrylic cement. A preliminary study of 100 consecutive McKee-Farrar prosthetic replacements. *J. Bone Joint Surg.* **54-A**, 207–236.