

OBSTETRICAL FRACTURE-SEPARATION OF THE UPPER FEMORAL EPIPHYSIS

S. D. THEODOROU, M. N. IERODIACONOU & A. MITSOU

Orthopaedic Department, "A. P. Kyriakou" Children's Hospital, Athens, Greece

During the last 15 years we have treated six neonates with obstetrical fracture of the upper epiphysis of the femur. Two other cases have previously been reported by one of us (S.D.T.) in 1958.

A common characteristic was a difficult and traumatic breech delivery, half the babies being "large-for-dates". The clinical and radiological signs of this injury are described. In two babies there were associated injuries of the same limb whilst two others had congenital dislocation of the contralateral hip.

The prognosis appears to be excellent, in spite of the severity of the injury, and irrespective of treatment.

Key words: epiphysiolysis; fracture-separation; hip; obstetrical; upper femoral epiphysis

Accepted 7.vi.81

Obstetrical epiphysiolysis of the upper femoral epiphysis is a very rare injury and has become even rarer during the last 20 years, when progress in obstetrics has resulted in a decrease in obstetrical injuries. Since Elizalde (1946) recognised this entity, approximately 50 well documented cases have appeared in the literature.

The diagnosis of this injury may be difficult in the first few days of life and this explains the fact that such cases have in the past been described as "pseudodislocations" of the hip (Harrenstein 1929) or traumatic dislocations of the hip (Nathan 1928, Puppel 1930). Besides, the differential diagnosis from congenital dislocation of the hip (C.D.H.) and septic arthritis is indeed difficult, especially if one is not aware of the existence of this injury.

The purpose of this paper is to present six new cases of this injury in addition to the two cases previously reported by one of us (Michail et al. 1958), to stress the importance of history and early clinical signs for the diagnosis of this entity

and to point out its possible association with other obstetrical injuries and congenital dislocation of the hip.

PATIENTS

Over a period of 15 years (1965–1979) six instances of obstetrical fracture separation of the upper femoral epiphysis have been studied in six neonates. Their age at the first examination ranged from 1 day to 1 month with a mean of 11.5 days.

In all cases labour was difficult or protracted. Five were breech deliveries and one was born by Caesarean section. Three of the babies had birth weights greater than 4.5 kg and one was the second of twins. Two neonates had other injuries of the same limb and two had congenital dislocation of the contralateral hip (Table 1).

Clinical features

The main and constant clinical feature was pseudoparalysis of the affected limb. Other clinical features were pain on attempted passive movement and swelling, more obvious in the two babies with other

Table 1. Details of the six cases of obstetrical fracture separation of the upper femoral epiphysis

Case no.	Sex	Age in days	Birth weight in g	Delivery	Affected hip	Associated injuries	Contralateral C.D.H.
1	M	17	4900	Breech	Right	Yes	No
2	F	1	5300	Breech	Left	No	Yes
3	F	3	Twins	Breech	Left	No	Yes
4	F	7	3150	Caesar	Left	No	No
5	F	30	3500	Breech	Left	No	No
6	F	10	4800	Breech	Left	Yes	No

associated injuries. A pseudoclick was elicited in the affected hip in two cases.

Radiological findings

In the first few days of life the X-ray findings were those of varying lateral and upward displacement of the shaft of the femur (Figure 1). Usually after the second week callus formation was obvious on X-ray. This callus in some cases extended down to the mid-shaft of the femur (Figure 2). In one baby a supracondylar fracture of the same femur was also present whereas another

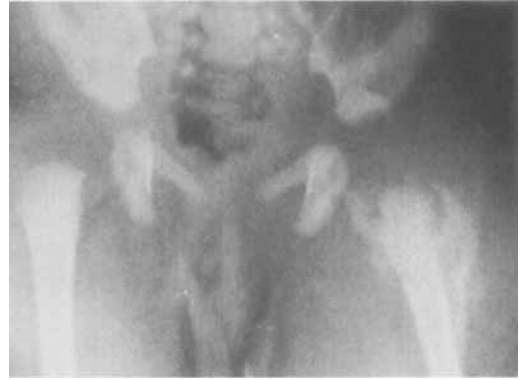

Figure 2. Same patient as in Figure 1. At 2 weeks of age there is already massive callus extending down to the mid-shaft of the femur.

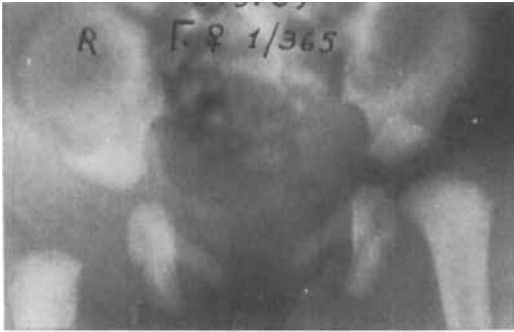

Figure 1. Anteroposterior and lateral X-rays of a 1-day-old girl showing upward and anterior displacement of the shaft of the left femur.

baby had a fracture separation of the lower femoral and upper tibial epiphyses of the same limb. In four out of the six patients the ossific centre of the femoral head appeared early on the affected side and in one baby in particular it was present at the age of 20 days (Figure 3).

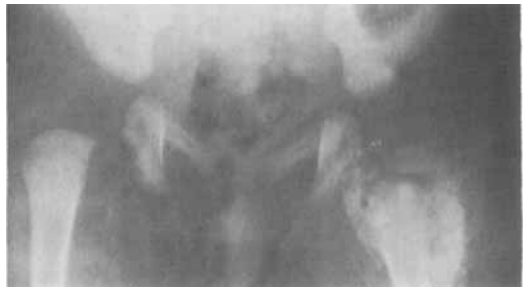
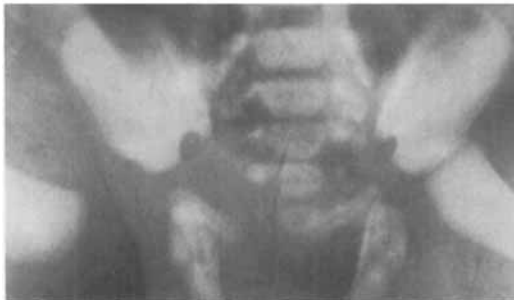
Figure 3. Large ossific centre of the capital epiphysis is present on the affected side at the age of 25 days (same patient as Figures 1 and 2).

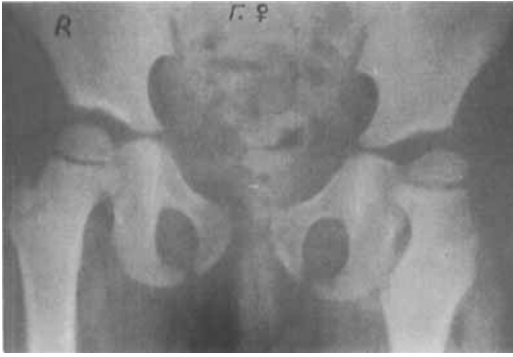

Figure 4. Same patient as Figures 1, 2 and 3 at the time of the final assessment. Valgus deformity of the femoral neck; otherwise a normal hip.

Treatment

The treatment of these six patients was not uniform. Two patients had no treatment at all because they presented relatively late, 10 and 17 days, respectively. Two more were treated with double nappies (they also presented late at 7 and 30 days) and only two were treated with skin traction for a few days followed by a plaster of Paris hip spica for a further 2 weeks. The two babies with C.D.H. had treatment with an abduction splint for a period of 4.5 months.

RESULTS

The age of the patients at the final assessment ranged from 18 months to 5 years with a mean of 2 years and 8 months. The clinical result was excellent in all cases irrespective of treatment. The radiological result was also very satisfactory. In four cases there remained a small valgus deformity of the femoral neck and in one case some lateral bowing of the femoral shaft, but otherwise there was complete anatomical restoration (Figure 4).

DISCUSSION

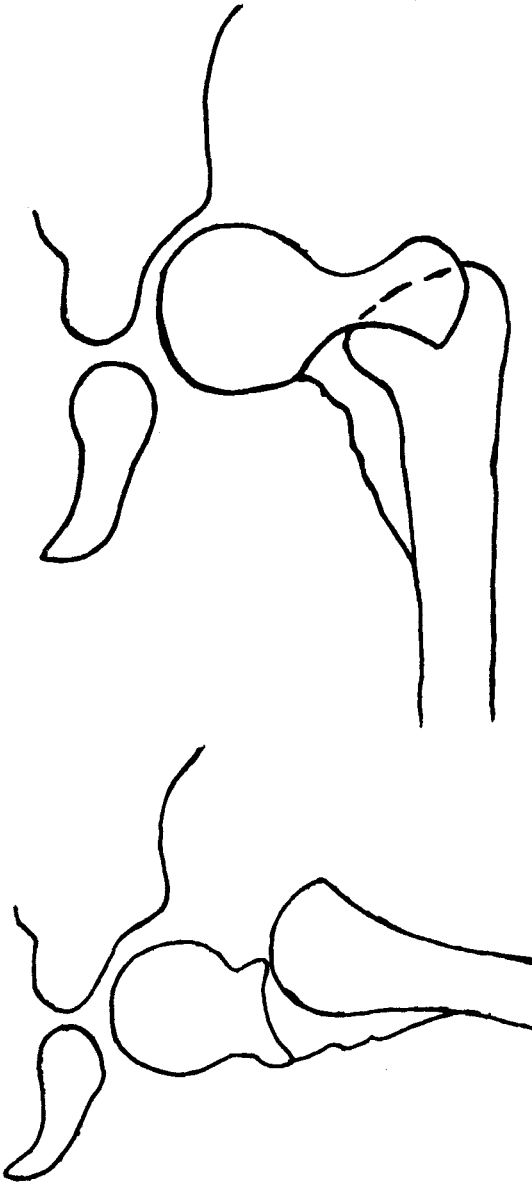
Obstetrical fracture-separation of the upper femoral epiphysis is a very rare injury. Until the radiological appearance of callus formation the diagnosis can be extremely difficult, especially when the clinical findings are not very marked.

The clinical picture of pseudoparalysis and pain on passive movement may lead to the diagnosis of septic arthritis, whereas the early X-ray appearance with upward and lateral displacement of the femur could be misinterpreted as being due to congenital dislocation of the hip. However, the history of a difficult delivery with a breech presentation, in association with the clinical picture, should alert the clinician towards the possibility of an obstetrical injury. In two of our six patients there were other associated fractures of the same limb, a fact which indicates exceptionally traumatic deliveries. When the first signs of callus appear on X-ray the diagnosis should be certain. Usually the callus extends for a considerable distance down the shaft of the femur indicating that the periosteum is stripped off the bone to a considerable extent.

It is interesting that in four of our babies there was an early appearance of the ossific centre of the head of the femur (less than 8 weeks, the earliest being 20 days) on the affected side (Figure 3). The same was noted in one of the cases reported by Michail et al. (1958). A possible explanation for this may be the increased blood supply of the area after the injury. Equally interesting is the association of this injury with congenital dislocation of the hip. Two of our cases had CDH and one of the two cases reported by Michail et al. had subluxation of the contralateral hip (Figure 5). It is possible that the sudden and violent stretching of the capsule of the hip joint due to forced traction at delivery may be a pre-

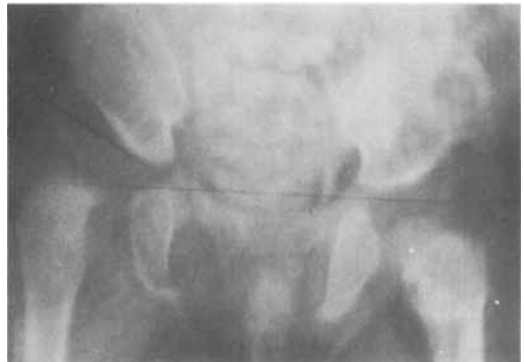

Figure 5. Girl 5.5 months. Dislocation of the contralateral hip which was originally missed.



Figures 6 and 7. Diagrams showing how the shaft of the femur is displaced in relation to its upper epiphysis.

disposing factor in the pathogenesis of CDH in hips already at risk because of genetic or prenatal factors.

With regard to treatment, various methods have been described by a number of authors. It appears, however, that no specific treatment is necessary, since many cases are diagnosed after

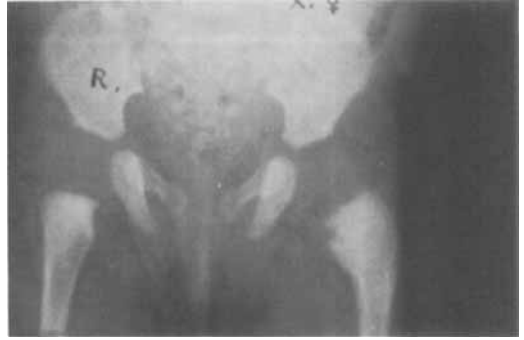

Figure 8. The appearance of the callus is indicative of the displacement and the intact periosteum on the medial and posterior aspects.

the fracture has united and since the final outcome is good irrespective of treatment (Dimitriou 1971 and 1980, Carevic & Strinovic 1977). If, however, the diagnosis is made immediately after birth, skin traction for a few days and a hip spica in slight abduction for 2 weeks appears to be a rational treatment.

Avascular necrosis of the femoral head was not seen in our cases and as far as we know has not been reported in the literature. The anatomy of the epiphysis of the upper end of the femur at birth and the position of the epiphyseal vessels

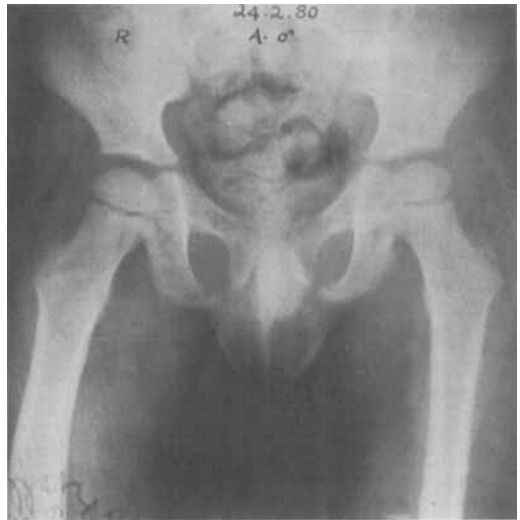

Figure 9. X-rays showing the varus angulation migrating peripherally.

(Trueta 1957, Crock 1967) make this possibility unlikely. It appears that the diaphysis is displaced upwards and forwards leaving behind the capital epiphysis in the acetabulum. The periosteum remains intact on the medial and posterior aspects, thus protecting the posterior epiphyseal vessels (Figures 6, 7, 8).

It has been reported that residual varus deformity of the hip may remain (Mortens & Christensen 1964, Lindseth & Rosene 1971). This was not our experience. On the contrary we found that in most of our cases there was slight valgus deformity of the neck. As shown in Figure 9 the original varus deformity migrates peripherally with the normal growth of the bone and tends to correct with time.

REFERENCES

- Caveric, N. & Strinovic, B. (1977) Folgenlos Angeheilten Geburtstraumatischen Epiphysenlosungen am Proximalen Femur und Humerusende. *Aktuel. Traumatol.* **7**, 103–111.
- Crock, H. V. (1967) *The blood supply of the lower limb bones in man*. E. and S. Livingstone Ltd., Edinburgh and London.
- Dimitriou, J. (1971) Obstetrical injury of the upper femoral epiphysis. *Orthopaedics (Oxford)* **4**, No. 1.
- Dimitriou, J. (1980) Personal communication.
- Elizalde, A. E. (1946) Obstetrical dislocation of the hip associated with fracture of the femur. *J. Bone Joint Surg.* **28**, 838.
- Harrenstein, R. J. (1929) Pseudoluxatio coxae durch Abreissen der Femurepiphysse bei der Geburt. *Brun's Beitr. Klin. Chir.* **146**, 592.
- Lindseth, E. R. & Rosene, Jr. A. H. (1971) Traumatic separation of the upper femoral epiphysis in a new born infant. *J. Bone Joint Surg.* **53-A**, 1641–1644.
- Michail, J. P., Theodorou, S., Houliaras, K. & Siatis, N. (1958) Two cases of obstetrical separation (epiphysiolysis) of the upper femoral epiphysis. *J. Bone Joint Surg.* **40-B**, 477–482.
- Mortens, J. & Christensen, P. (1964) Traumatic separation of the upper femoral epiphysis as an obstetrical lesion. *Acta Orthop. Scand.* **34**, 239–250.
- Nathan, W. (1928) Geburtstrauma und Hüftgelenkverrenkung. *Z. Orthop. Chir.* **49**, 383.
- Puppel, E. (1930) Die Kongenitale Hüftgelenksluxation als Geburtstrauma. *Z. Geburtshilfe Gynaekol.* **97**, 39.
- Trueta, J. (1957) The normal vascular anatomy of the human femoral head during growth. *J. Bone Joint Surg.* **39-B**, 358.

Correspondence to: Professor S. D. Theodorou, M.D., Children's Hospital A. P. Kyriakou, Department of Orthopaedics, Athens 617, Greece