

## CHONDROMALACIA PATELLAE

### *A Radiographic Study of the Femoropatellar Joint*

CLAUS PERRILD, NIELS HEJGAARD & ARNE ROSENKLINT

Department of Radiology, and Department of Orthopaedic Surgery T-3, Gentofte Hospital, University of Copenhagen, Denmark

X-rays of 71 patients operated on for chondromalacia patellae were examined in order to obtain a comprehensive picture of the radiographic changes in this disease. Ninety-seven patients with a normal patellofemoral joint – found at operation – were used as a control group.

We found a significantly higher frequency of patella alta and the presence of Haglund's excavation in patients with chondromalacia but had to conclude that ordinary X-rays cannot be used to confirm the diagnosis chondromalacia patellae.

*Key words:* chondromalacia; knee joint; patella; radiology

Accepted 7.iv.81

It is still debated whether specific radiographic changes are present in chondromalacia of the patella (c.p.). Several authors have found that patella alta is more frequent in patients with c.p. than in healthy controls (Insall et al. 1976, Jackson 1976, Lancourt & Cristini 1975) and this condition was present in as many as 50 per cent of Insall's patients. In Marks' study (Marks & Bentley 1978), however, only women with severe c.p. had a significantly increased incidence of high riding patella. Furthermore, Lund (1978) was unable to demonstrate an association between patella alta and c.p. in his material, Haglund's excavation being the only significant radiographic finding. Ficat et al. (1975) have discussed the lateral hyperpression-hypertension syndrome as a possible cause of c.p. and osteoarthritis of the femoropatellar joint. On skyline view of the patella this author found radiographic changes such as subchondral sclerosis, lateralisation of the bone trabeculae, and internal decalcification, as a sequel to the hyperpression phenomenon.

Generally speaking, the remaining literature on this subject gives the impression that radio-

graphy is of little diagnostic value in c.p. The purpose of this investigation was to obtain a comprehensive picture of the radiographic changes in c.p. as compared to those in a well-defined control group.

#### PATIENTS AND METHODS

The study comprised 71 (40 male and 31 female) patients operated on for symptom-yielding c.p. and, as a control group, 97 (76 male and 21 female) patients who were meniscectomized and in whom meniscal injury was the only lesion found at surgery. Preoperative radiographs including antero-posterior projections, lateral projections, and skyline views, were examined blindly. The parameters used were the excavation of Haglund (1926), patella alta measured by the Insall-Salvati index (1971) as well as by the method of Blackburne & Peel (1977) (Figure 1), the Wiberg patellar type (1941), lateral subluxation measured by the congruence angle (Merchant et al. 1974), hypoplasia of the lateral femoral condyle estimated by the sulcus angle (Brattström 1964), subchondral sclerosis, internal decalcification, lateralisation of the bone trabeculae and signs of osteoarthritis indicated by joint gap narrowing and osteophytosis (Figure 2a, b).

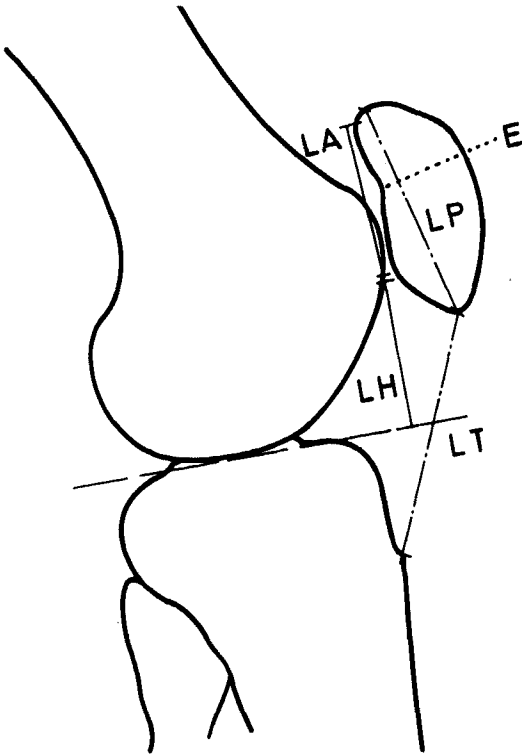


Figure 1. Measurements indicating patella alta.

$$\text{Insall/Salvati index} = \frac{LT}{LP}$$

$$\text{Blackburne index} = \frac{LH}{LA}$$

E = Haglund's excavation.

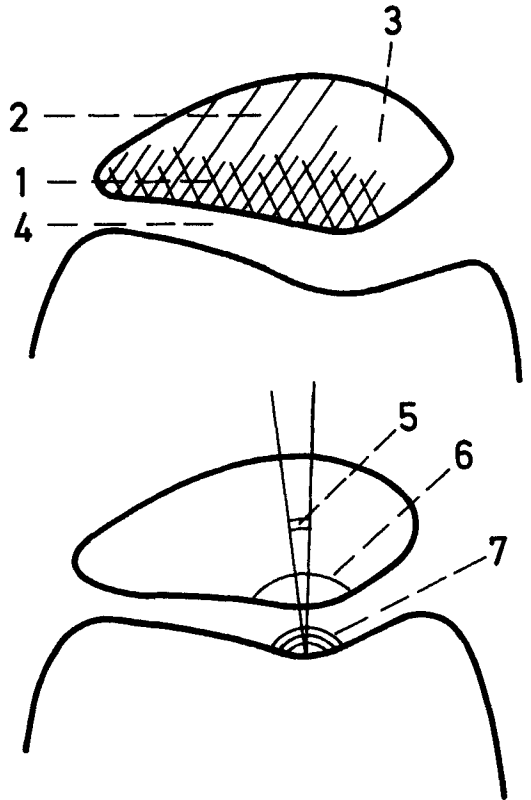


Figure 2a, b. "Merchant"-view of the patellofemoral joint. 1: subchondral sclerosis. 2: lateralisation of cancellous trabeculae. 3: internal decalcification. 4: joint gap narrowing. 5: congruence angle. 6: Wiberg angle. 7: sulcus angle.

Statistical methods

As all parameters showed a non-gaussian distribution the data were analysed by non-parametric tests (chi-square and Mann-Whitney U-test) and the P-values were tabulated. The variability is shown as medians and 2.5/97.5 percentiles.

RESULTS

Table 1 compares the c.p. and the control groups with respect to the different variables. There were significantly more females in the c.p. group, but as no significant sex-related differences were observed the two groups are comparable. There was a higher frequency of Haglund's excavation

in the c.p. group than in the control group. The predictive value of a positive test ( $P_v$  pos.) was  $40/(40+34) = 0.54$ . The predictive value of a negative test ( $P_v$  neg.) was  $31/(31+63) = 0.36$ . As measured by the Insall-Salvati index patella alta was also found significantly more often in the c.p. group than in the control group.  $P_v$  pos. =  $27/(27+26) = 0.50$ ,  $P_v$  neg. =  $44/(44+71) = 0.39$ . By Blackburne's method, however, no significant difference was observed. Neither the scatter diagram nor the calculation ( $R = 0.28$ ) showed a correlation between these two methods. Lesions described by Ficat as due to hyperpression were as frequent in healthy as in diseased knees. No correlation was found between c.p. and patellar dysplasia or lateral subluxation.

Table 1. Comparison of the various parameters in the two groups

Parameters	c.p. Group		Control group		P (Mann-W)
Insall/Salvati ratio	1.17 (0.84-1.49)		1.12 (0.88-1.42)		0.026
Blackburne ratio	0.89 (0.60-1.17)		0.85 (0.58-1.34)		0.532
Congruence angle (degrees)	-4 (-25.4-+15.2)		-4 (-22.2-+10.7)		0.988
Sulcus angle (degrees)	130 (112-146)		130 (118-142)		0.209
Age (years)	33 (15-59)		33 (16-58)		0.876
Joint gap (mm) medial	7 (3.6-11.0)		7 (4.0-10.5)		0.986
Joint gap (mm) lateral	6 (2.6-10.2)		6 (3.0-10.0)		0.161

Parameters	c.p. Group	(Per cent)	Control group	(Per cent)	P (Chi <sup>2</sup> )
Patella alta, Insall/Salvati >1.2	27	(38)	26	(27)	0.025
Patella alta, Blackburne >1.0	7	(10)	19	(20)	0.085
Haglund's excavation	40	(56)	34	(35)	0.010
Subchondral sclerosis	13	(18)	22	(23)	0.830
Osteophytosis	8	(11)	7	(7)	0.650
Lateralisation of trabeculae	1	(1.4)	0	(0)	0.470
Internal decalcification	7	(9)	9	(9)	0.910
1	57	(80)	87	(90)	
Patella type 2	13	(19)	10	(10)	0.240
3	1	(1)	0	(0)	
Sex Male	40	(56)	76	(78)	0.001
Female	31	(44)	21	(22)	

## DISCUSSION

Other authors have investigated and commented upon the radiographic changes in c.p. (Lund 1978, Marks & Bentley 1978). In these studies, however, the patient groups were ill-defined as no attention was paid to the fact that as many as 85 per cent of the symptom-free knees may show cartilage changes (Abernethy et al. 1978) and that 50 per cent of patients with complaints compatible with c.p. may have normal cartilage (Leslie & Bentley 1978). Thus, as the selection cannot be made on clinical findings only, we selected our patients according to well-defined patho-anatomical lesions.

We found no correlation between the two methods for measuring patella alta. However, as several authors (Insall et al. 1976, Jackson 1976, Lancourt & Cristini 1975) consider patella alta to be an important aetiological factor in c.p., it is imperative to choose the method which is most able to indicate the presence of an abnormal patellar level. Therefore, we cannot recommend Blackburne's method even if it is easy to use.

In our material very few patients had bone lesions of the type described by Ficat et al. (1975). This would indicate that only a minority of patients with c.p. also suffer from the lateral hyper-pressure syndrome.

Both Haglund's excavation and patella alta were found more often in patients with c.p. than in the control group. The diagnostic value is doubtful, however, with  $P_v$  neg. = 0.36 and 0.39, respectively.

We conclude that preoperative radiography of patients with c.p. provides a limited number of positive findings, and is unable to confirm the diagnosis of c.p. Nonetheless, Haglund's excavation and patella alta occur more frequently in patients with c.p. than in the normal population.

## REFERENCES

- Abernethy, P. J., Townsend, P. R., Rose, R. M. & Radin, E. L. (1978) Is chondromalacia patellae a separate clinical entity? *J. Bone Joint Surg.* **60-B**, 205-210.
- Blackburne, J. S. & Peel, T. E. (1977) A new method of measuring patella height. *J. Bone Joint Surg.* **59-B**, 241-242.
- Brattström, H. (1964) Shape of the intercondylar groove normally and in recurrent dislocations of the patella. A clinical and X-ray-anatomical investigation. *Acta Orthop. Scand.*, Suppl. 68.
- Ficat, P., Ficat, C. & Bailleux, A. (1975) Syndrome d'hyperpression externe de la rotule (S.H.P.E.). *Rev. Chir. Orthop.* **61**, 39-59.
- Haglund, P. (1926) Die hintere Patellarkontusion. *Zentralbl. Chir.* **28**, 1757-1760.
- Insall, J. & Salvati, E. (1971) Patella position in the normal knee joint. *Radiology* **101**, 101-104.
- Insall, J., Falvo, K. A. & Wise, D. W. (1976) Chondromalacia patellae. A prospective study. *J. Bone Joint Surg.* **58-A**, 1-8.
- Jackson, R. W. (1976) Etiology of chondromalacia patellae. American Academy of Orthopaedic Surgeons. *Instructional Course Lectures*, Vol. **25**, pp. 36-39.
- Lancourt, J. E. & Cristini, J. A. (1975) Patella alta and patella infera. *J. Bone Joint Surg.* **57-A**, 1112-1115.
- Leslie, I. J. & Bentley, G. (1978) Arthroscopy in the diagnosis of chondromalacia patellae. *Ann. Rheum. Dis.* **37**, 540-547.
- Lund, F. (1978) Studies on the patello-femoral joint. Thesis. University of Lund, Sweden.
- Marks, K. E. & Bentley, G. (1978) Patella alta and chondromalacia. *J. Bone Joint Surg.* **60-B**, 71-73.
- Merchant, A. C., Mercer, P. L., Jacobsen, R. H. & Cool, C. R. (1974) Roentgenographic analysis of patellofemoral congruence. *J. Bone Joint Surg.* **56-A**, 1391-1396.
- Wiberg, G. (1941) Roentgenographic and anatomic studies on the femoropatellar joint, with special reference to chondromalacia patellae. *Acta Orthop. Scand.* **12**, 319-410.

Correspondence to: Dr. Niels Hejgaard, Henriettevej 27, DK-2920 Charlottenlund, Denmark