

FILLING OF A BONE DEFECT DURING EXPERIMENTAL OSTEOTAXIS DISTRACTION

A. ALHO*, G. BANG**, E. KARAHARJU** & I. ARMOND*

* Section of Orthopaedics and Traumatology and ** Department of Oral Pathology and Forensic Odontology, School of Dentistry, University of Bergen, Bergen, Norway; and *** Division of Orthopaedics and Traumatology, Surgical Hospital, Helsinki, Finland

Gradual distraction of a tibiofibular bone osteotomy in 14 rabbits was compared with a neutral osteotomy in 14 control rabbits using an osteotaxis device as fixation. The osteotomy was distracted for a period of 8 weeks at a rate of 1 mm/week. The control osteotomies united in 5 to 6 weeks with minimal external callus formation. In the distraction group, the periosteum and endosteum participated in the filling of the distraction gap. The most vigorous osteoblastic activity was observed in the middle of the osteotomy gap (growth zone) where calcification was delayed. In the distraction group the bone united in 6 to 7 weeks, not significantly later than in the controls. Two instances of non-union (2/14) were observed in the distraction group.

Key words: bone; bone lengthening; distraction osteotomy; fracture fixation; osteotaxis; osteotomy

Accepted 16.iii.81

Clinical leg lengthening has been a difficult problem. However, stable fixation devices have made it possible to obtain a gradual lengthening with minimized side effects (Wagner 1977). The indications have been leg length discrepancies after poliomyelitis, developmental anomaly or skeletal trauma. Leg lengthening using osteotomy results in a defect which usually is filled with bone grafts (Wagner 1971, Hendelsohn et al. 1977). However, bone growth in the osteotomy gap can be achieved by maintaining some of the periosteal continuity (Coleman & Noonan 1967, Kawamura et al. 1968). Gradual distraction of an experimental osteotomy at an appropriate rate has been reported to result in a growth stimulation in the gap and in bone union (Ilizarov & Berko 1976).

The present study was carried out in order to compare bone formation during gradual distraction with that obtained with neutral osteotomy and to study this bone formation histologically.

MATERIALS AND METHODS

Twenty-eight adult rabbits weighing 2.9-4.7 kg were used. The osteotaxis device, developed by the authors, was applied during Nembutal anaesthesia (30 mg/kg i.v., adding 6 mg doses when necessary) and local infiltration with Xylocain (20 mg in 2 ml); 1.7 mm Steinmann pins were used (Figure 1). Through an anterior longitudinal incision a transverse tibia osteotomy was performed with an AO oscillating minisaw. The periosteum was interrupted and the fibula broken. The incision was closed with continuous Dexon sutures. The pin holes were covered with penicillin powder. The whole operation area was covered with sterile wadding and a plaster capsule. The capsule was loose in relation to the osteotaxis apparatus. Postoperatively, the rabbits were given glucose solution and nursed in an observation cage. They moved about and took fluid and food the next day and moved normally. No per- or postoperative deaths were experienced. One rabbit was sacrificed because of deep wound infection. Two animals were discarded because they sustained fracture through the distal fixation area.

The legs of the distraction animals were lengthened

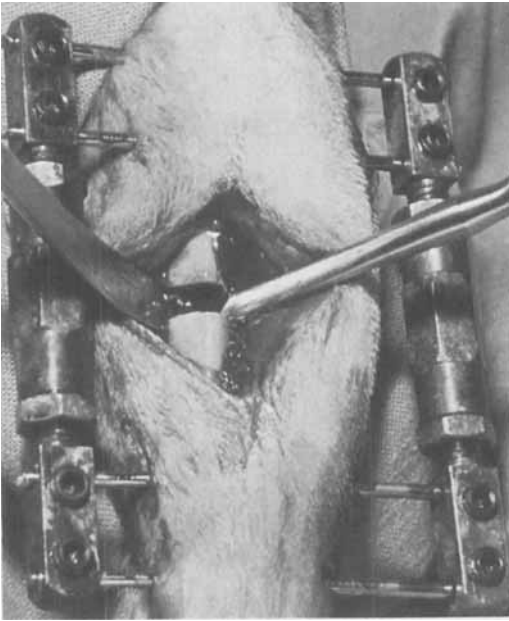


Figure 1. Osteotaxis fixation of a transverse tibiofibular osteotomy. Eight weeks' gradual lengthening, 1 mm/week, resulted in an increase of 11 per cent in the bone length.

at weekly intervals starting from 1 mm; the length increase averaged 9 mm at 8 weeks. In the control animals a neutral contact without compression was maintained between the osteotomy surfaces. X-rays were taken once a week; the distraction osteotomies were studied before and after the lengthening.

For the histological study, the femoral artery was prepared under anaesthesia for perfusion with phosphate buffer and later with formalin in phosphate buffer. The femoral artery and vein were ligated for the purpose of regionalizing the perfusion which was performed under 120 mmHg pressure. After 20 minutes' perfusion the animal was killed with a lethal dose of potassium chloride. The tibio-fibular bone was freed from soft tissue and preserved in formalin. The specimens from 2- to 5-week animals with flexible callus were fixed with the osteotaxis apparatus still in place.

After fixation the tibias were cut into two halves and longitudinal sections were prepared for histology using haematoxylin-eosin and Movat pentachrome stains. For the histological studies one to two animals in each group were sacrificed weekly.

The radiological changes during the bone repair process were studied semiquantitatively. *Periosteal callus* was graded from one to three, four points were given to organized woven bone and five points to remodelled bone. The points of individual animals were averaged in order to get the points of a group at a certain time. *Endosteal callus* could be estimated in the histological sections only. *Filling of the osteotomy gap* proximally and distally was graded in the same way as the periosteal callus. When calcified callus began to fill the

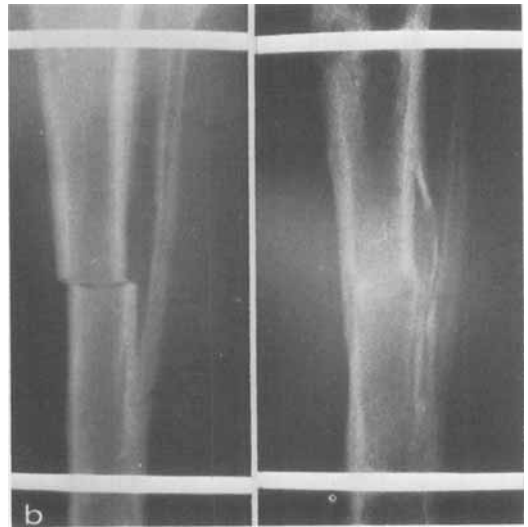
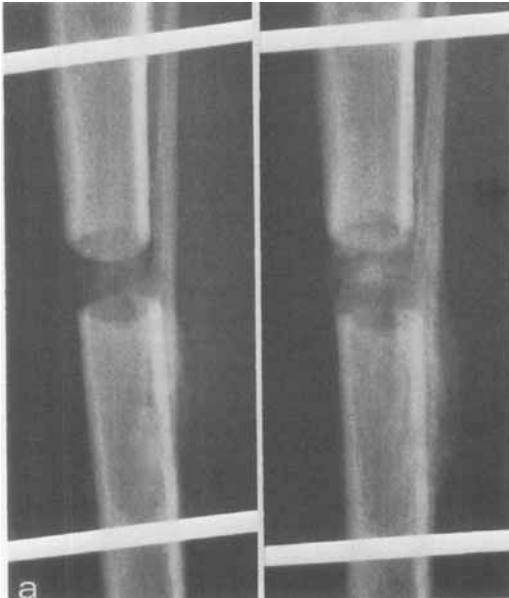
Figure 2. a) In the distraction group, periosteal and endosteal callus participated in the growth bud formation at the proximal and distal osteotomy ends. The growth zone in the middle of the gap consolidated last. Increasing healing at 2 and 4 weeks. b) Control osteotomy at 1 and 7 weeks. The rigidity of the osteotaxis fixation resulted in stress protection osteoporosis with thinning of the cortical bone in both groups.

distraction gap from both osteotomy ends, a non-calcified midzone was observed until full consolidation. This area was called the *growth zone* and was described both radiologically and histologically. *Thinning of cortical bone* both proximally and distally was estimated, comparing the cortical radiographs in the area between the closest osteotaxis fixation pins.

RESULTS

Periosteal callus formation. The first calcification shadows on the X-ray films were seen 2 weeks postoperatively and were distinct at 3 weeks both in the distraction and control groups (Figure 2).

Filling of the osteotomy gap. In the distraction group the periosteal and endosteal callus intermingled with the calcification that occurred in the distraction gap. The radiologically definable non-calcified growth zone in the middle of the osteotomy gap was present, on average, from 2 to 7 weeks (Figure 3).

During the first 3 weeks the consolidation proceeded at an equal rate in the distraction and control animals (Figure 4). Between the third and seventh week there was a tendency for a more pronounced callus formation in the control osteotomies; at 4 weeks the difference between the callus scores of the control osteotomies and

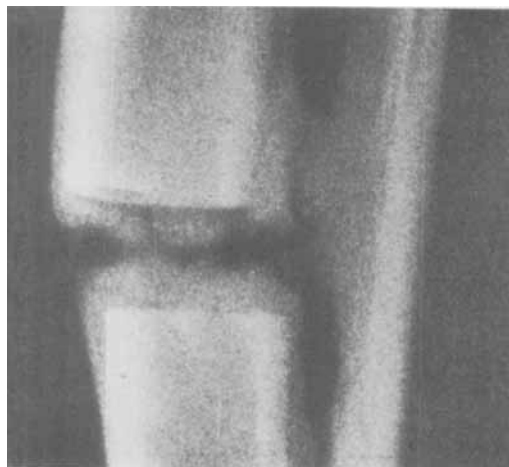


Figure 3. After an osteotomy with distraction, the signs of calcification were distinct 3 weeks postoperatively.

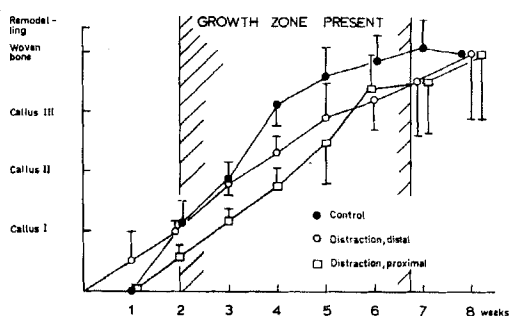
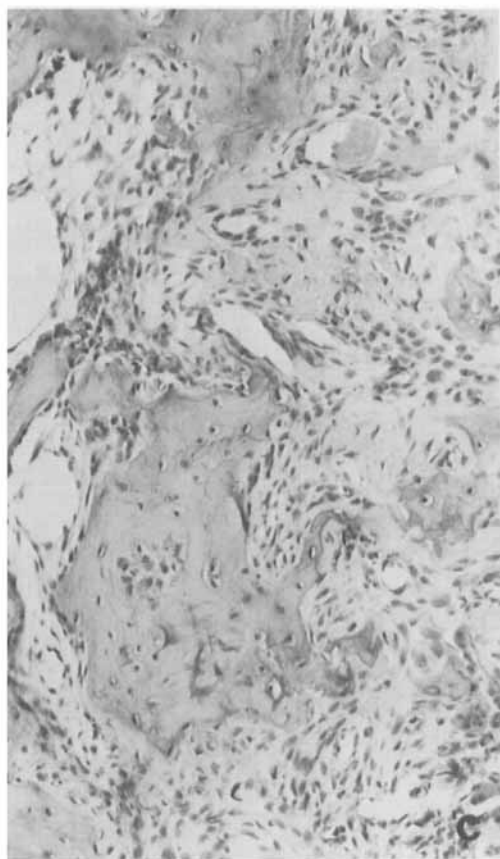
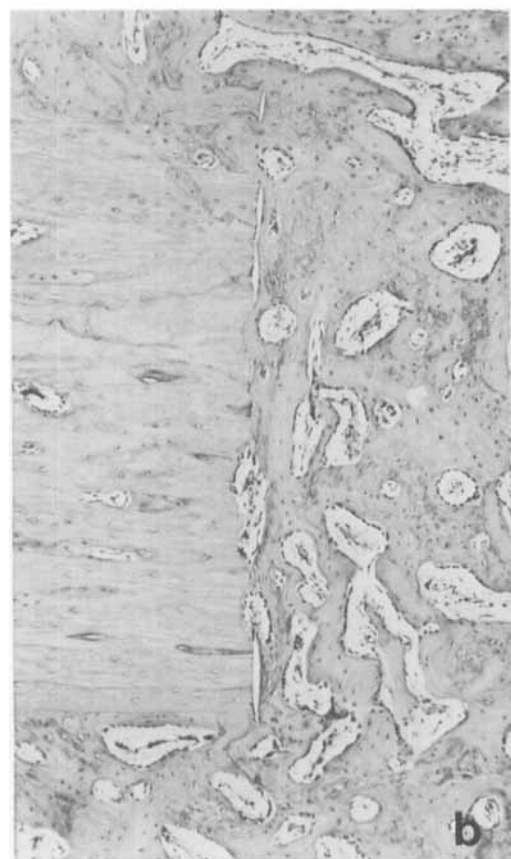
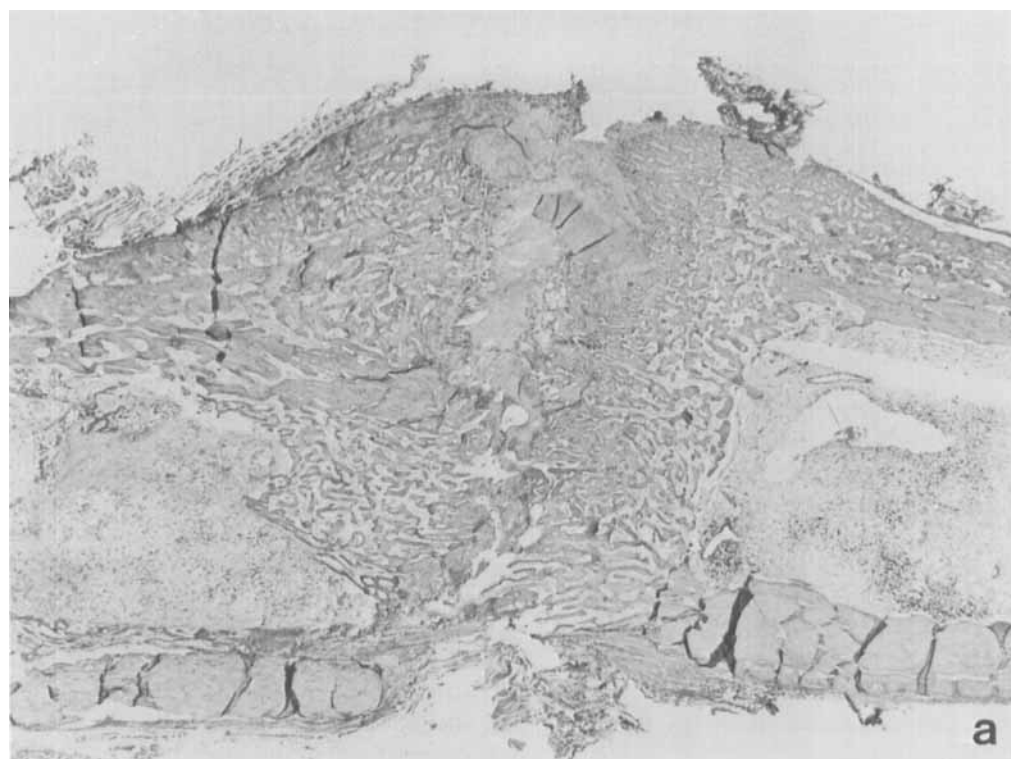


Figure 4. Filling of the distraction gap by callus formation. Open squares represent the proximal callus bud, open circles represent the distal one. Callus formation in the control osteotomies is marked with black circles.

the proximal distraction callus buds was significant ($P < 0.01$). However, the last phase of maturation of the callus to woven bone progressed equally in both groups. Thereafter a remodelling process was observed resulting in a completed repair process in two out of the three control animals which were kept alive until 7 to 8 weeks and in two out of the four such animals in the distraction group. Two distraction cases ended in non-union, one of them with histologically verifiable low grade infection and necrosis in the distraction gap.

In the histological study of the control group a normal pattern of bone healing was observed. The osteotomy ends were usually necrotic in spite of the use of the perfusion fixation technique; however in some preparations osteocytes could be seen in the vicinity of the osteotomy as a sign of a preserved vascular supply of the bone. Both periosteal and endosteal callus formation participated in the bone repair. In the distraction group, a lively callus formation, continuous with the endosteal and periosteal callus, could be seen in the gap (Figure 5). Both osteogenesis and chondrogenesis were observed in the growth area. The most active osteogenesis occurred in the middle of the gap on a plate-like area which we called the *growth zone*.

Thinning of the cortex. At 5 weeks and later, thinning of the cortical bone and osteoporosis were observed proximally and distally on either side of the osteotomy in both groups (Figure 6).



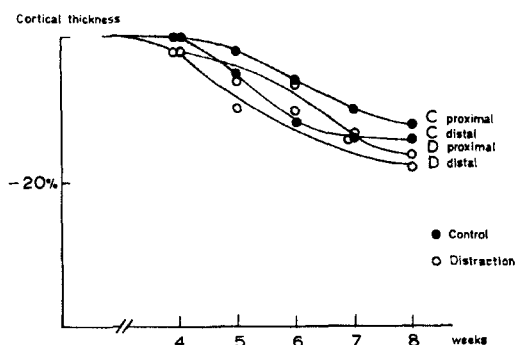


Figure 6. Reduction of the cortical thickness in control and distraction osteotomies.

It was somewhat more noticeable distal to the osteotomy. Both resorption and cortical apposition were observed around osteotaxis pins, without a uniform pattern; in two cases the resorption could be connected with pin track infection.

DISCUSSION

Earlier experiments with diaphyseal bone lengthening to compensate for a leg length discrepancy were often hampered by complications and the method was more or less abandoned (Sofield et al. 1958). New stable osteotaxis devices (Anderson 1952, Rezaian 1971, Wagner 1971), however, made further development possible. Bone lengthening has been studied both clinically (Anderson 1952, Coleman & Noonan 1967, Kawamura et al. 1968, Gross 1971, Rezaian 1976, Wagner 1977) and experimentally (Kawamura et al. 1968, Shtin & Nikitenko 1975, Ilizarov & Berko 1976). In clinical series, lengthening in children using a closed osteoclasis technique with preservation of the periosteal tube has been possible and osteogenesis has been stimulated to such an extent that bone grafting has not been necessary (Anderson 1967). The Wagner (1971) technique involves bone grafting

after completed lengthening both in children and in adults.

In the clinical series the optimal diurnal rate of lengthening has been adjusted to 1.5 mm and the total lengthening has been between 10 and 20 per cent of the bone's original length (Coleman & Noonan 1967, Gross 1971). Rezaian (1976) used a lengthening rate of 1.25 mm/day ending at the same total lengthening. In canine experiments a diurnal rate of 0.5 per cent of the bone length, corresponding to 1.5 mm/day in man, has been found optimal (Shtin & Nikitenko 1975, Ilizarov & Berko 1976) and it has been possible to lengthen the bone by 20 per cent.

In their radiological studies, Ilizarov & Berko (1976) found a mid-zone which they considered active and responsible for the excess growth.

In our study, using adult rabbits and a weekly distraction of 1 mm (1.25 per cent of the bone length) for 8 weeks, we achieved a lengthening of 11 per cent. A modification of the Rezaian (1971) osteotaxis device was found reliable. Comparing the rate of bone repair we observed a stimulation by distraction based on the fact that only at one time, 4 weeks after the osteotomy, a significant difference was found in the consolidation rate between the neutral and distracted osteotomies. The later maturation occurred equally in both groups.

The distraction gap gradually filled with callus in which both periosteum and endosteum participated. This healing process progressed equally at both osteotomy ends leaving a non-calcified zone in the middle of the distraction gap. At a later stage of distraction, the osteogenic activity was strongest in this "growth zone". Some chondrogenesis was observed as well.

Stability of the fixation by osteotaxis resulted in cortical thinning comparable with the thinning after metal plate fixation (disuse atrophy) (Paavolainen et al. 1978). Whether this had a harmful effect on the osteogenetic process cannot be determined from the present results.

Figure 5. a) Osteotomy gap after distraction filled with new bone due to very active endosteal and periosteal callus formation (5 weeks postoperatively). The plate-like growth zone is seen between the proximal and distal callus bud (H & E \times 8.5). b) The distraction gap is filled with newly formed woven bone continuous with the severed bone (H & E \times 60). c) The most recently formed and most immature bone is found in the middle of the distraction gap (H & E \times 150).

We assume that it is possible to optimize bone lengthening in a way that makes the filling of the gap possible without bone grafting, which in the clinical context reduces the morbidity of the procedure remarkably. Our weekly lengthening may not have been ideal because we achieved a lengthening which was less than in earlier experimental reports and, at the same time, there were two non-unions among the 14 distraction cases.

CONCLUSIONS

Gradual distraction of the tibiofibular bone of adult rabbits (1 mm/week) using osteotaxis stimulates endosteal and periosteal callus formation, which results in filling of the distraction gap in a time period which is comparable with healing of an osteotomy gap in neutral contact. Fixation by osteotaxis was stable enough to result in stress protection osteoporosis and thinning of the cortical bone.

New bone formation continues for the longest time in the growth zone in the middle of the distraction gap, mainly through direct osteogenic activity and partly via chondrogenesis.

ACKNOWLEDGEMENTS

We would like to thank Dr. J. Christensen, M.D. for methodological and Mrs. Elly Soltvedt for technical assistance. Financial support was obtained from the Norwegian Council for Science and the Humanities and the Finnish Norwegian Medical Foundation.

REFERENCES

- Anderson, W. V. (1952) Leg lengthening. In: Proceedings of the British Orthopaedic Association. *J. Bone Joint Surg.* **34-B**, 150.
- Anderson, W. V. (1967) Lengthening of the lower limb: Its place in the problem of limb length discrepancy. In: *Modern trends in orthopaedics* (Ed. Graham, W. D.) Vol. 5, pp. 1–22.
- Coleman, S. S. & Noonan, T. D. (1967) Anderson's method of tibial-lengthening by percutaneous osteotomy and gradual distraction. *J. Bone Joint Surg.* **49-A**, 263–279.
- Gross, R. H. (1971) An evaluation of tibial lengthening procedures. *J. Bone Joint Surg.* **53-A**, 693–700.
- Hendelsohn, P., Hohmann, D. & Weigert, M. (1977) Subtrochanteric shortening and lengthening osteotomy. In: *Progress in orthopaedic surgery*, Vol. 1: Leg length discrepancy/The injured knee (Ed. Hungerford, D. S.) pp. 63–69. Springer-Verlag, Berlin, Heidelberg, New York.
- Illizarov, G. A. & Berko, V. G. (1976) Roentgenographic dynamics of the bone regenerative development in elongation of the hip in experiment. *Ortopedia* **12**, 25–31.
- Kawamura, B., Hosono, S., Takahashi, T., Tano, T., Kobayashi, Y., Shibata, N. & Shinoda, Y. (1968) Limb lengthening by means of subcutaneous osteotomy. *J. Bone Joint Surg.* **50-A**, 851–878, 963.
- Paavolainen, P., Karaharju, E., Slätis, P., Ahonen, J. & Holmström, T. (1978) Effect of rigid plate fixation on structure and minimal content of cortical bone. *Clin. Orthop.* **136**, 287–293.
- Rezaian, S. M. (1971) The effect of new external bonefixator on the treatment of fractures of long bones. *Ann. R. Coll. Surg. Engl.* **48**, 336–343.
- Rezaian, S. M. (1976) Tibial lengthening using a new extension device. Report of thirty-two cases. *J. Bone Joint Surg.* **58-A**, 239–243.
- Shtin, V. P. & Nikitenko, E. T. (1975) The rate of the distraction in elongation of the long tubular bones. *Ortopedia* **10**, 40–44.
- Sofield, H. A., Blair, S. J. & Millar, E. A. (1958) Leg lengthening: A personal follow-up of forty patients some twenty years after the operation. *J. Bone Joint Surg.* **40-A**, 311–322.
- Wagner, H. (1971) Operative Beinverlängerung. *Chirurg* **42**, 260–266.
- Wagner, H. (1977) Surgical lengthening and shortening of femur and tibia. In: *Progress in orthopaedic surgery*, Vol. 1: Leg length discrepancy/The injured knee (Ed. Hungerford, D. S.) pp. 71–94. Springer-Verlag, Berlin, Heidelberg, New York.