

RESECTION OF THE LATERAL END OF THE CLAVICLE *A 3 to 30-Year Follow-Up*

CLAES J. PETERSSON

Department of Orthopaedic Surgery, Malmö General Hospital (University of Lund), Malmö, Sweden

Fifty patients, operated on with resection of the clavicle, were evaluated postoperatively after an average of 9 years. There was no significant difference between the traumatic and non-traumatic group. The initial results did not alter significantly with time. Nearly half of the patients with poor outcome had psychiatric or alcoholic problems. Radiographic examination of 30 shoulders showed newly formed bone at the resected clavicle in one third and radio-opaque deposits in the resection gap in another third. These findings were consistent with good outcome.

Key words: acromioclavicular joint; clavicle; dislocation; fracture; osteoarthritis; osteolysis

Accepted 11.vi.83

In 1941, Gurd and Mumford independently reported success with resection of the lateral end of the clavicle for both early and late cases of acromioclavicular separation. Many authors since that time have advocated the procedure for traumatic lesions of the acromioclavicular joint (Accardo 1960, Sage & Salvatore 1963, Weaver & Dunn 1972, Murphy et al. 1975, Rausching et al. 1980) and for non-traumatic painful conditions of the acromioclavicular joint (Wagner 1953, Worcester & Green 1968, Kessel & Watson 1977, Watson 1978, Cahill 1982). The results presented have been uniformly satisfying with very few failures reported. The follow-up periods, however, have mostly been short, seldom exceeding 5 years.

At the Department of Orthopaedic Surgery, Malmö General Hospital, resection of the lateral clavicular end has been performed since 1950. The operation has been performed both in traumatic acromioclavicular lesions and in patients with non-traumatic pain and disability in the acromioclavicular joint.

The purpose of the present study was to

evaluate the results after resection of the lateral clavicle, to investigate if there were any differences in the results in the long-term follow-up and to compare the results in a group of patients operated on because of trauma to the acromioclavicular joint with those of another group operated on due to acromioclavicular pain, not associated with trauma.

MATERIAL AND METHODS

The original group consisted of 58 men and 15 women with an average age of 45 years, operated on during the period 1950–1979 by 33 different surgeons. At these operations 1–2 cm of the clavicles had been resected lateral to the coracoclavicular ligaments. In three patients with acute separation of the acromioclavicular joint, resection of the clavicle had been combined with transposition of the acromial end of the coracoacromial ligament into the medullary canal of the clavicle, according to Weaver & Dunn (1972). One patient had been operated on earlier with stabilization of the acromioclavicular joint due to dislocation and four patients had been operated on earlier with various methods because of fracture of the clavicle.

Table 1. Characteristic of the patients

	N	Men/Women	Age at operation	Age at follow-up	Duration of preoperative symptoms (months)
Non-traumatic group	16	11/5	49±13	56±13	16 (4-72)
Traumatic group	34	28/6	42±14	51±13	12 (0-60)
Total	50	39/11	44±14	53±13	

The patients were re-examined in 1982. The average time interval between operation and evaluation was then 9 years. Of the original 73 patients, 14 had died and 9 were lost to follow-up for other reasons. Fifty patients with 51 operated clavicles were therefore available for evaluation. In 17 patients the follow-up period was 10 years or longer, on average 17 years. Thirty-four patients had been operated on because of traumatic conditions in the acromioclavicular joint, and the non-traumatic group consisted of 16 patients (Table 1). All acromioclavicular joints had been radiologically examined preoperatively. The preoperative roentgenograms had shown cystic rarefaction of the lateral clavicular end in six cases of the non-traumatic group and in three of the acromioclavicular joint of the traumatic group not associated with fracture or dislocation.

The initial results at the end of the convalescence, on average 10 weeks postoperatively, were assessed from the records. Those patients who were then satisfied with the operation and who had returned to their former work were rated pleased; the remainder were rated not pleased.

Six patients were interviewed by questionnaire. For the remainder, the rating of the results was based on interview and physical examination and the results were classified with respect to patient satisfaction and the total range of elevation and abduction of the arm. The rating of patient's satisfaction included pain and function.

In 30 patients, radiological examination of the acromioclavicular region was performed.

RESULTS

At the follow-up evaluation, 37 patients with 38 operated clavicles were pleased with the results of the operation. However, in this group 11 patients had some residual symptoms and were rated fair. There was no significant difference between the shoulders operated on less than 10 years before the follow-up and those with a follow-up period of 10 to 30 years. (Table 2)

The results in the non-traumatic and traumatic groups are compared in Table 3. The differences

Table 2. Comparison between the results in the patients with a short-term follow-up and those with a long-term follow-up. The differences are insignificant

Follow-up interval Range years	Average years	N	Results		
			Good N	Fair N	Poor N
3-9	5	34	18	9	7
10-30	17	17	9	2	6
Total		51	27	11	13

Table 3. Comparison between the results in the non-traumatic and traumatic groups. There are no significant differences between the groups, nor are there any differences between the early results and the follow-up results

	Early results assessed from records		Results at follow-up		
	Pleased N	Not pleased N	Good N	Fair N	Poor N
Non-traumatic group	13	3	10	4	2
Traumatic group	24	11	17	7	11

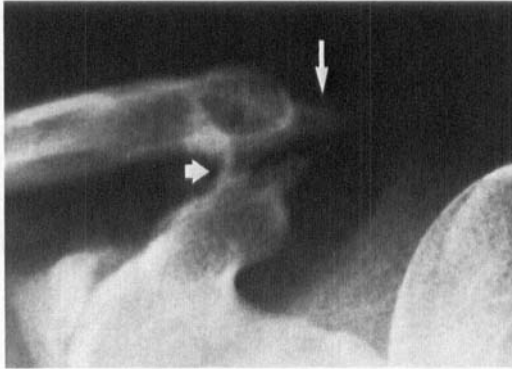


Figure 1. Radiograph of the left acromioclavicular joint of a 40-year-old woman operated on 3 years earlier with resection of the clavicle and transposition of the coracoacromial ligament. There is new bone formation into the resection gap from the clavicle (long arrow) and also between the clavicle and the coracoid process (fat arrow). The follow-up result was rated good.

in the results are insignificant. Also, in Table 3 the early results in the two groups at the end of the convalescence are compared with those of the follow-up evaluation. There was no significant difference between the early results of the traumatic and non-traumatic group, nor did the early results change with time. At the physical examination three patients, rated poor, presented painful indurated scars over the acromioclavicular joint. Another three patients had slight, non-painful scar induration. They were all rated poor. In the remainder of the patients the scars were painless and well healed. In no case was there any instability in the operated shoulder. Four patients, rated poor, complained of weakness and easily-caused fatigue in the operated arm and two patients, rated fair, had slight weakness when working with the arm overhead. No other patient, irrespective of rating, had experienced weakness of the arm as a major problem.

In 13 patients the results were rated poor. Five patients in this group had been operated on due to persistent pain in the acromioclavicular region after fracture of the clavicle and three of these cases had been operated earlier with open reduction and different osteosynthetic procedures. Six patients with poor results had alcoholic or psychiatric problems, as compared with eight patients in the group with good or fair results.

Nine of the patients with poor results were already dissatisfied at the end of convalescence.

The radiological investigation showed a persistent gap between the resected clavicle and the acromion in all cases. In 10 shoulders there were bone spurs on the clavicle (Fig. 1) and radio-opaque deposits were registered between the resected bone ends in 10 cases.

There was no correlation between the results of the clinical examination and the presence of newly formed bone spurs or radio-opaque deposits on the radiological images, nor was there any difference in new bone formation between the traumatic and the non-traumatic groups.

DISCUSSION

Wagner (1953) reported results after partial claviclectomy for treatment of a variety of lesions during an 8-year-period. He had used the operation for traumatic lesions in 24 cases and the results were rated good in 21 and poor in three. He also reported a non-traumatic group consisting of 17 patients and in these patients the results were good in 14 cases and fair in three. Sage & Salvatore (1963) analysed the results after lateral resection in 13 patients with acromioclavicular separation and with an average follow-up of 26 weeks. They encountered excellent results in 69%, good in 15% and poor in 8%. Worcester & Green (1968) reported uniformly good results in 56 patients operated on for osteoarthritis in the acromioclavicular joint on average 4.5 years before follow-up. Watson (1978) described excision of the outer end of the clavicle in severe refractory painful arc syndrome. Twelve patients were followed for more than a year postoperatively. Nine were then free of symptoms and three had less pain on movement than preoperatively. Cahill (1982) reported his results after resection of the lateral clavicle in distal osteolysis in male athletes. He had followed 19 patients for an average of 7 years. Four had mild pain and two had moderate pain at follow-up.

In the present investigation, 50 patients with 51 operated clavicles were evaluated for an average of 9 years postoperatively. Twenty-seven

were absolutely free of symptoms and were rated good, another 11 were pleased with the operation and had returned to work but had some mild or moderate complaints about their operated joints and were rated fair. Thirteen patients were rated poor. This failure rate exceeds that in earlier reports. In the present study most failures were already apparent at the end of the convalescence and the incidence of failures did not increase with time. Two of the 16 patients operated on because of non-traumatic pain in the acromioclavicular joint were rated poor as compared with $11/35$ in the traumatic series. This difference, however, was not significant. Nearly half of the patients with poor results had concomitant psychiatric or alcoholic disease and one patient had cervical spondylosis with neck and shoulder pain. Another striking feature in the patients with poor outcome was that several had been operated on due to persistent pain after fracture of the clavicle and three of these patients had been operated on earlier with a poor result.

The results of the radiological examination indicate that new bone formation at the resected end of the clavicle in one third of the cases and deposition of radio-opaque material in the resection gap in another third is compatible with good results. The results of this study suggest that three out of four patients operated on with resection of the lateral end of the clavicle will be satisfied with the result and that the initial result does not deteriorate with time. It seems possible to improve on these results with proper patient selection.

ACKNOWLEDGEMENT

Financial support was obtained from the Herman Järnhardt Foundation and the Faculty of Medicine, University of Lund.

REFERENCES

- Accardo, N. J. (1960) The Gurd-Mumford procedure for acromioclavicular dislocations. *Bull. Tulane University Med. Fac.* **20**, 41–46.
- Cahill, B. R. (1982) Osteolysis of the distal part of the clavicle in male athletes. *J. Bone Joint Surg.* **64-A**, 1053–1058.
- Gurd, F. B. (1941) The treatment of complete dislocation of the outer end of the clavicle. *Ann. Surg.* **113**, 1094–1098.
- Kessel, L. & Watson, M. (1977) The painful arc syndrome. Clinical classification as a guide to management. *J. Bone Joint Surg.* **59-B**, 166–172.
- Mumford, E. B. (1941) Acromioclavicular dislocation. A new operative treatment. *J. Bone Joint Surg.* **23**, 799–802.
- Murphy, O. B., Bellamy, R., Wheeler, W. & Brower, T. D. (1975) Post-traumatic osteolysis of the distal clavicle. *Clin. Orthop.* **109**, 108–114.
- Rausching, W., Nordesjö, L. O., Nordgren, B., Sahlstedt, B. & Wigren, A. (1980) Resection arthroplasty for repair of complete acromioclavicular separations. *Arch. Orthop. Traumat. Surg.* **97**, 161–164.
- Sage, F. P. & Salvatore, J. E. (1963) Injuries of the acromioclavicular joint: A study of results in 96 patients. *Sth. Med. J.* **56**, 486–495.
- Wagner, C. J. (1953) Partial claviclectomy. *Am. J. Surg.* **85**, 259–265.
- Watson, M. (1978) The refractory painful arc syndrome. *J. Bone Joint Surg.* **60-B**, 544–546.
- Weaver, J. K. & Dunn, H. K. (1972) Treatment of acromioclavicular injuries, especially complete acromioclavicular separation. *J. Bone Joint Surg.* **54-A**, 1187–1194.
- Worcester, J. N. & Green, D. P. (1968) Osteoarthritis of the acromioclavicular joint. *Clin. Orthop.* **58**, 69–73.