

## OSTEOCHONDROGENESIS OF FREE PERIOSTEAL GRAFTS IN THE RABBIT ILIAC CREST

JENS M. RUBAK

Department of Orthopaedic Surgery, Aarhus County Hospital, Aarhus, Denmark

The influence of the bone marrow, cortical bone and apophyseal cartilage of the iliac crest on osteochondrogenesis from free autogenous periosteal grafts was studied histologically in 8-week-old rabbits. Tibial periosteum was transplanted around the iliac crest, from which the periosteum had been removed from the inner side, periosteum and cortical bone in an area on the outer side and perichondrium from the apophyseal cartilage. Most bone formation occurred in the area with periosteum in contact with the bone marrow of the cancellous bone. By means of an isolating Nucleopore filter<sup>®</sup>, it was revealed that the most vigorous of this bone formation originated from the periosteal graft. Further, it was noted that in the series with the Nucleopore filter, bone formation was slower than in the series without the filter, suggesting some inductive factors. No bone formation occurred in the apophyseal area.

*Key words:* differentiation; osteochondrogenesis; periosteal graft.

Accepted 11.vi.83

The known prerequisites for bone formation are proper osteogenic cells, proper environment and stimulating factors. The cambium layer of free periosteal grafts contains osteogenic cells (Ritsilä et al. 1972, Poussa 1981). The environmental influence on the differentiation of osteochondrogenic cells in periosteal grafts was shown in the studies of Uddströmer (1977), Rubak (1980) and Poussa et al. (1981). The stimulating factors in osteogenesis are, however, still obscure. In this respect the role of bone marrow has been controversial (Burwell 1964).

The purpose of the present investigation was to study the effect of bone marrow in cancellous bone, cortical bone and the apophyseal area of the iliac crest on the differentiation of periosteal cells.

### MATERIAL AND METHODS

The experimental material comprised 76 iliac crests in 38 eight-week-old rabbits. The operations were performed under circumstances as described in a previous study (Rubak 1982). On the iliac crest the muscle tissue was incised and the perichondrium on the apophysis, the periosteum of the inner and outer side of the ileum was removed. Further, the cortical bone was resected on the outer side in an area of 4 × 8 mm. A free periosteal graft from the medial facet of the tibia was transplanted around the iliac crest. The cambium layer was facing the cartilage of the apophysis, the cortical bone on the inner side and the bone marrow of the cancellous bone on the outer side of the iliac crest. The muscle tissue was resutured around the iliac crest with 4-0 Vicryl<sup>®</sup> (Series 1, Figure 1). In Series 2, a Nucleopore filter<sup>®</sup> with a pore size of 0.4 µm, impenetrable to cells and vessels, was placed between the iliac crest and the periosteal graft (Figure 1). The animals were killed in equal numbers 1, 2, 4, 5, 8, 14 and 21 days post-operatively. Series 1 and 2 each comprised 14 rabbits. In 10 rabbits used as a control group (Series 3), the

operation procedure was the same except that no graft and no filter were applied. These animals were killed in equal numbers 1, 4, 8, 14 and 21 days postoperatively. The histological specimens were prepared using the same method as in a previous study (Rubak 1982) and stained with Alcian blue and hematoxylin eosin.

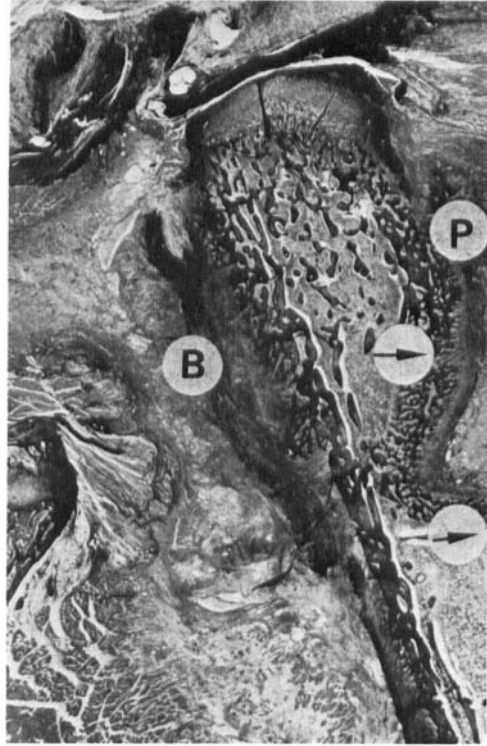
**RESULTS**

*Series 1*

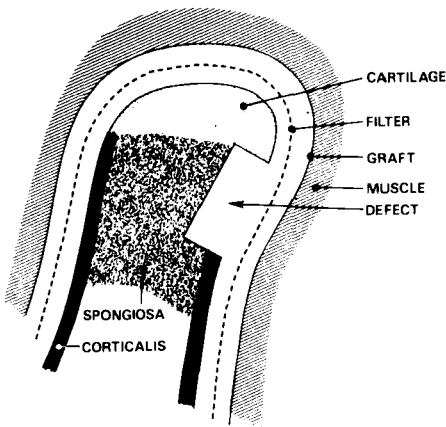
*1-4 days:* After 2 days proliferation of the cambium layer cells was observed. The periosteal graft was seen bulging into the cancellous bone, probably compressed by the surrounding muscles. From the fourth day postoperatively, vigorous bone formation from the graft had formed an immature bone bridge crossing the defect. The bone bridge was bulging into the cancellous bone (Figure 2). On the medial side of the iliac crest, bone formation was observed but in a much smaller amount. No bone formation was seen in the apophyseal cartilage area.

*5-8 days:* The vigorous bone formation continued in the defect area as well as around the defect and on the medial side of the iliac crest. No bone formation was seen in the apophyseal cartilage area.

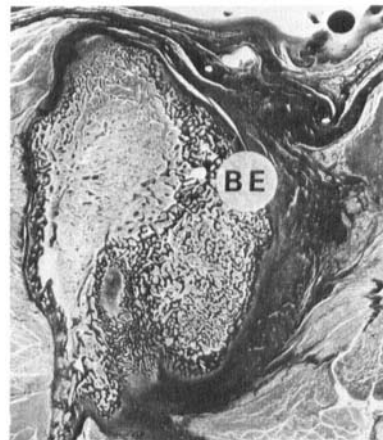
*14-21 days:* The most active bone formation was still seen on the lateral side of the iliac crest



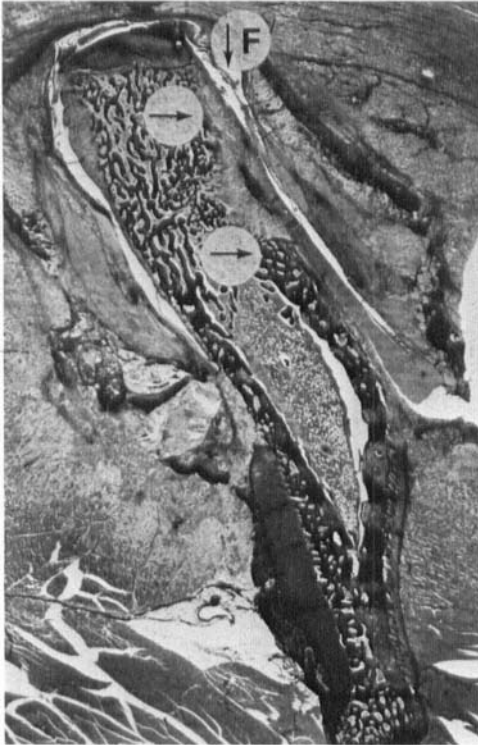
*Fig. 2. Histological picture of the iliac crest 4 days after periosteal transplantation (Series 1). A new bone bridge formed from the periosteal graft (P) is seen bulging into the defect (between the arrows). On the medial side some bone formation is observed (B). (Alcian blue stain, × 7).*



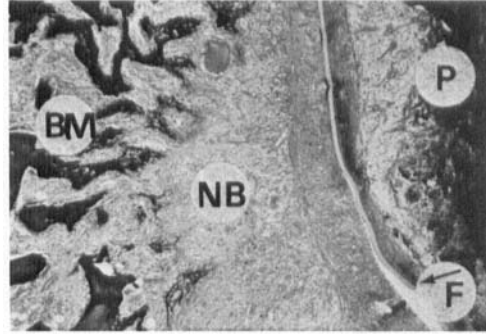
*Fig. 1. Schematic presentation of the method. A rabbit's right iliac crest cut vertically with the medial side to the left and the lateral side with the defect to the right.*



*Fig. 3. Histological picture of the iliac crest 21 days after periosteal transplantation (Series 1). A tumor-like bone exostosis (BE) is seen on the right. (Alcian blue stain, × 5).*



a



b

Fig. 4. (a) Histological picture of the iliac crest 4 days after periosteal transplantation (Series 2). The defect between the arrows is clearly visible. Nucleopore filter® (F). (Alcian blue stain,  $\times 7$ ). (b) Detail of the defect. Periosteal graft (P). Incipient new bone formation (NB) from bone marrow (BM) is observed. Filter (F). (Alcian blue stain,  $\times 34$ ).

where the defect was made. In this period a tumor-like bone exostosis was formed on the lateral side (Figure 3). No bone formation was observed in the apophyseal cartilage area.

### Series 2

*1–4 days:* Proliferation of the periosteal cambium layer cells was observed but no new bone bridge crossing the defect was seen (Figure 4a). The defect was filled with granulation tissue and some bone formation seemed to occur, originating from the bone marrow (Figure 4b).

*5–8 days:* Inside the Nucleopore filter, the defect was partly filled with bone with a structure resembling that of the trabecular bone in the cancellous bone. Outside the filter, the periosteal graft had formed cartilage facing the filter and new bone was observed toward the muscle tissue (Figure 5a, 5b). No bone formation was observed in the apophyseal cartilage area.

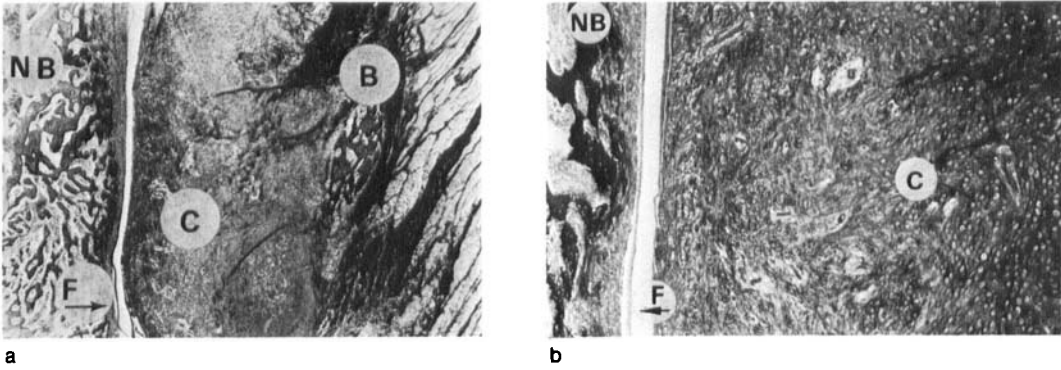
*14–21 days:* The defect was reconstructed with bone. Outside the filter, a large “cartilage-bone ossicle” was formed with cartilage facing the filter and bone toward the muscle tissue (Figure 6a, 6b). On the medial side of the iliac crest, bone formation was found only on the outside of the filter, together with some cartilage formation.

### Series 3

*1–4 days:* Postoperative haemorrhage was seen. After 4 days there was some beginning of bone formation in the defect, but no bone bridge crossing the defect was observed (Figure 7).

*5–8 days:* The defect was partly filled with woven bone; on the medial side of the iliac crest some bone formation was also found, but to a much lesser degree.

*14–21 days:* The defect was reconstructed and the wall was found to be thicker, as it was before



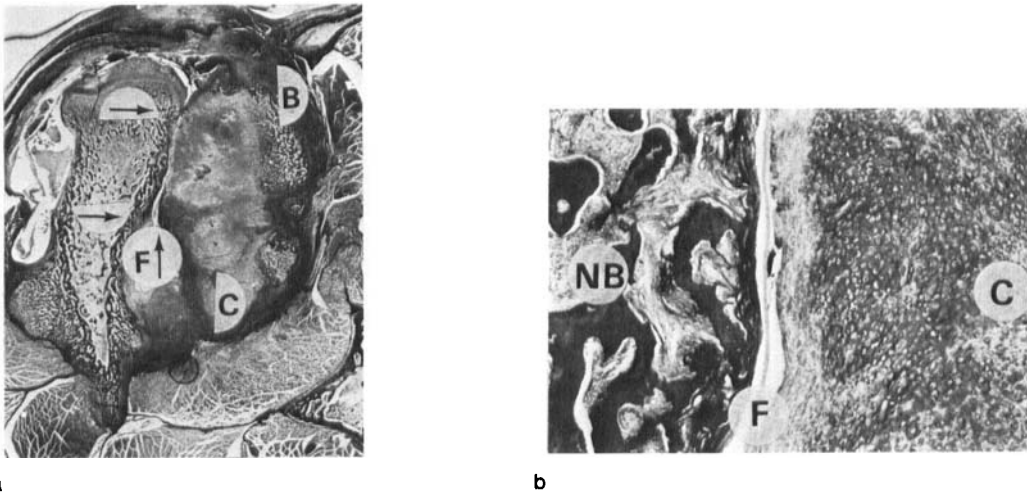
**Fig. 5.** (a) Histological picture from the defect area 8 days after periosteal transplantation (Series 2). Trabecular new bone (NB) is observed in the defect. On the lateral side of the filter (F), cartilage (C) and some bone (B) are observed. (Alcian blue stain,  $\times 8.5$ ). (b) Detail picture showing the formed cartilage (C) and new bone (NB). (Alcian blue stain,  $\times 56$ ).

the operation. No tumor-like exostosis or ossicle was observed. On the medial side some bone formation took place; in the apophyseal cartilage area no bone formation was observed (Figure 8). No complication such as infection was observed.

**DISCUSSION**

Previous studies have demonstrated the bone-forming capacity of free periosteal grafts in animals, where bone was formed through a cartilage

interface in bony or muscular environment (Ritsilä et al. 1972, Alhopuro 1978, Poussa 1981). The influence of different environmental conditions on the proliferation of the periosteal cells has been observed in studies of Ritsilä & Alhopuro (1973), Rubak (1980), Poussa et al. (1981). Burwell (1966) transplanted bone marrow into a muscular environment and found its bone-forming capacity very poor, whereas autologous bone marrow combined with homologous physically or chemically treated bone, produced bone in 98% of the grafts. He interpreted this as an



**Fig. 6.** (a) Histological picture of the iliac crest 21 days after periosteal transplantation (Series 2). The defect between the arrows is reconstructed. On the outer side of the filter (F) an ossicle is seen, cartilage (C), bone (B). (Alcian blue stain,  $\times 5$ ). (b) Detail picture showing new bone (NB), filter (F) and newly formed cartilage (C). (Alcian blue stain,  $\times 34$ ).

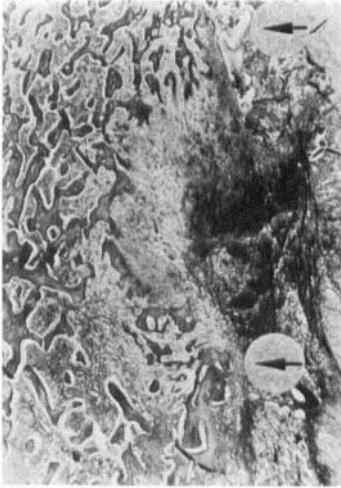


Fig. 7. Histological picture from the defect area after 4 days in the control group (Series 3). No new bone bridge is seen in the defect (between arrows). (Alcian blue stain,  $\times 8.5$ ).

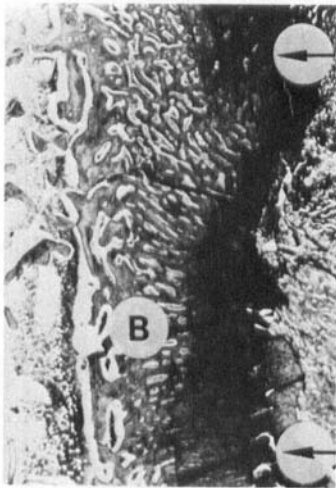


Fig. 8. Histological picture from the defect area after 21 days in the control group (Series 3). The defect area (between arrows) is reconstructed with bone tissue (B). (Alcian blue stain,  $\times 8.5$ ).

induction phenomenon, which here meant the induction of homologous bone on autologous bone marrow. The importance of bone marrow as an osteogenic factor is further confirmed in studies of Boyne (1970) and Cummine & Nade (1977). Uddströmer & Ritsilä (1979) studied the indi-

vidual role of periosteum, cortical bone and bone marrow in repair of defects in long bones. They found the periosteum to be the most important factor in the new bone formation.

In the present study the defect was repaired with new bone in a few days, obviously formed from the periosteal graft (Series 1). In Series 2, the bone formation was slower and the structure of the formed bone, containing cartilage, was different from that in Series 1. It was further observed that in both series most bone formation occurred on the side of the iliac crest with the defect, leaving the periosteal graft in contact with the bone marrow. On the medial side of the iliac crest with the periosteal graft in contact with cortical bone, the formation of new bone was slower and smaller in amount. The same observation was made in Series 3.

These findings may be due to various factors. On both sides of the iliac crest, well vascularized muscle tissue provides sufficient oxygen pressure, which is favourable for bone formation (Basset 1962). However, vascularization and oxygen pressure might be better on the side with the bone marrow than on the cortical bone, resulting in less bone formation in the latter place. Further, it is known that the induction and osteogenic capacity of cortical bone is insignificant when compared with that of bone marrow (Urist & McLean 1952, Burwell 1964, 1966, Cummine & Nade 1977). The filter hindered direct cell contact between the periosteal and bone marrow cells and obstructed vascularization from the bone marrow, which might explain the slower bone formation in Series 2. Whether the filter disturbs some induction effect from the bone marrow could not be answered in the present study. Most writers believe that the osteogenic induction principle depends on a diffusible protein substance (Friedenstein 1973, Lindholm & Urist 1980, Urist 1980) and not on direct cell contact as proposed by Weiss (1950).

In the present study the defect was repaired with bone resembling the membranous structure of the iliac bone, although the periosteal graft was taken from a hyalin-preformed bone. This environmental influence on bone formation was also observed in studies of Ritsilä & Alhopuro (1973) and Kufass (1981), who used tubular

periosteum in reconstruction of tracheal defects and found formation of membranous bone.

The absence of bone formation in the apophyseal area might be explained by the environmental influence in this cartilage area. However, no cartilage formation was observed, as seen in studies with periosteal grafts in chondrotrophic environments (Rubak 1980, Poussa et al. 1981, Rubak 1982, Rubak et al. 1982a, 1982b). This might be explained by the fact that the suturing of the muscle tissue across the iliac crest caused compression so that the nutritive circulation in the area was disturbed, resulting in no tissue formation at all.

From the present study, it can be concluded that within a few days free periosteal grafts from tibia in contact with bone marrow cells of the iliac crest produced a vigorous bone formation process structurally like membranous bone. The Nucleopore filter effectively hindered this cell proliferation, either by blocking some induction principle, direct cell contact, or by obstructing the vascularization of osteogenesis. These observations may be of importance in the clinical application of the osteogenic effect of the periosteal graft, as in the repair of pseudoarthrosis.

## REFERENCES

- Alhopuro, S. (1978) Premature fusion of facial sutures with free periosteal grafts. *Scand. J. Plast. Reconstr. Surg.* Suppl. 17.
- Basset, C. A. L. (1962) Current concepts of bone formation. *J. Bone Joint Surg.* 44-A, 1217-1244.
- Boyne, P. J. (1970) Autogenous cancellous bone and marrow transplants. *Clin. Orthop.* 73, 199-209.
- Burwell, R. G. (1964) Studies in the transplantation of bone. *J. Bone Joint Surg.* 46-B, 110-140.
- Burwell, R. G. (1966) Studies in the transplantation of bone. *J. Bone Joint Surg.* 48-B, 532-566.
- Cummine, J. & Nade, S. (1977) Osteogenesis after bone and bone-marrow transplantation. *Acta Orthop. Scand.* 48, 15-24.
- Friedenstein, A. J. (1973) Determined and inducible osteogenic precursor cells. In: *Hard tissue*, pp. 169-185. Ciba Symposium II, Assoc. Scientific Publ., Amsterdam.
- Kufass, T. (1981) Tracheal reconstruction with free periosteal grafts. Academic Diss. Helsinki.
- Lindholm, T. S. & Urist, M. R. (1980) A quantitative analysis of new bone formation by induction in composite grafts of bone marrow and bone matrix. *Clin. Orthop.* 150, 288-300.
- Poussa, M., Rubak, J. M. & Ritsilä, V. (1981) Differentiation of the osteochondrogenic cells of the periosteum in a chondrotrophic environment. *Acta Orthop. Scand.* 52, 235-239.
- Poussa, M. (1981) Osteochondrogenic activation of mesenchymal cells in periosteal grafts. Academic Diss. Helsinki.
- Ritsilä, V., Alhopuro, S. & Rintala, A. (1972) Bone formation with free periosteum. *Scand. J. Plast. Reconstr. Surg.* 6, 51-56.
- Ritsilä, V. & Alhopuro, S. (1973) Reconstruction of experimental tracheal cartilage defects with free periosteum. *Scand. J. Plast. Reconstr. Surg.* 7, 116-119.
- Rubak, J. M. (1980) Reconstruction of the experimental condylar cartilage defect of the knee joint with free periosteal grafts. Paper read at the XLth Congress of the Scand. Orthop. Assoc. June, 1980, Helsinki.
- Rubak, J. M. (1982) Reconstruction of articular cartilage defects with free periosteal grafts. *Acta Orthop. Scand.* 53, 175-180.
- Rubak, J. M., Poussa, M. & Ritsilä, V. (1982a) Chondrogenesis in repair of articular cartilage defects by free periosteal grafts in rabbits. *Acta Orthop. Scand.* 53, 181-186.
- Rubak, J. M., Poussa, M. & Ritsilä, V. (1982b) Effects of joint motion on the repair of articular cartilage with free periosteal grafts. *Acta Orthop. Scand.* 53, 187-191.
- Uddströmer, L. (1977) Periosteal activity in new bone formation and growth of suture-bone grafts. *Acta Univ. Ups. Abstracts of Uppsala Diss. Faculty of Medicine no.* 285.
- Uddströmer, L. & Ritsilä, V. (1979) Healing of membranous and long bone defects. An experimental study in growing rabbits. *Scand. J. Plast. Reconstr. Surg.* 13, 281-287.
- Urist, M. R. & McLean, F. C. (1952) Osteogenetic potency and new-bone formation by induction in transplants to the anterior chamber of the eye. *J. Bone Joint Surg.* 34-A, 443-476.
- Urist, M. R. (1980) In: *Fundamental and clinical bone physiology*, pp. 331-368. J. P. Lippincott, Toronto.
- Weiss, P. (1950) Perspectives in the field of morphogenesis. *Q. Rev. Biol.* 25, 177-198.