

## USE OF INSTILLATION-SUCTION TECHNIQUE IN TREATMENT OF CHRONIC OSTEOMYELITIS

HUBERT N. OGUACHUBA

Orthopaedic Unit, Department of Surgery, University of Jos, Jos Plateau State, Nigeria

Willenegger's closed instillation-suction technique for the treatment of chronic bone infection is described in which infected bone is first exposed and all sequestra removed. Two drainage tubes are perforated, inserted and brought out through the skin between 3 and 4 cm from the wound. The perforated portions of the tubes are laid close to the infected area and the wound closed in layers. One tube is connected to a drip bottle containing antibiotic solution and the second to a continuous suction pump. Closed continuous steady flow instillation-suction is thus established. The results of 28 cases are presented out of which 26 cases showed clinical resolution of the infection.

*Key words:* osteomyelitis

Accepted 1.i.83

Instillation-suction technique developed by Willenegger in the treatment of chronic osteomyelitis is of great importance. In his method the infected areas of bone are reached by a continuous flow of antibiotics or other solution and the debris is withdrawn by continuous suction. According to Willenegger every chronic osteomyelitis must be drained and the drainage should guarantee a mechanical outflow (Willenegger & Roth 1962). In the management of chronic osteomyelitis the Willenegger technique has been employed.

### PATIENTS AND METHODS

Pre- and postoperative radiographs and full bacteriological investigations were carried out.

#### *Operation*

The diseased bone is fully exposed and all sequestra are removed. All cavities are deroofed, if present, and curetted.

Openings are made into the medullary cavity. The irrigation tubes are inserted. The irrigation tubes are

those from an ordinary blood-giving set, the diameter of the drainage tube about 4 mm.

The point of the inlet irrigation tube is passed into the depth of the wound and is brought out through the skin about 3-4 cm from the incision edge. Two tubes are positioned so that the perforated sections of each lies close to the diseased bone as shown in Figure 1. Incision

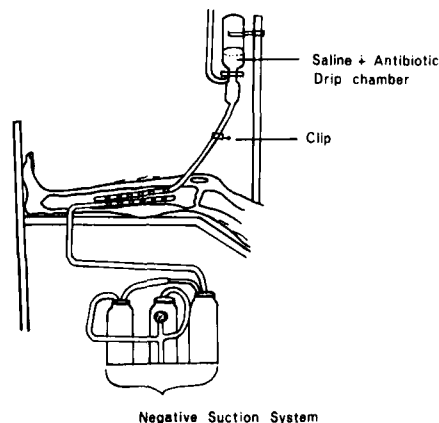


Figure 1. Shows diagram of the irrigation-suction technique for the treatment of chronic osteomyelitis.

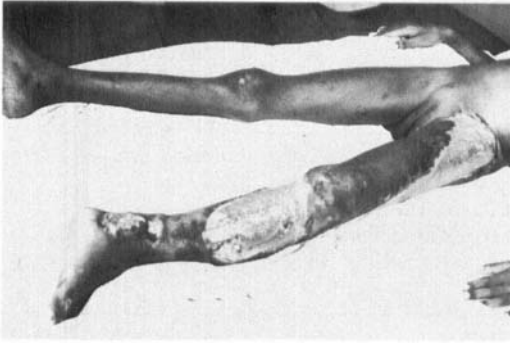


Figure 2. Case No. 227244 shows grossly infected compound fracture of the tibia and infected wound on the upper quadrant and lateral aspect of left thigh with large skin defect two weeks after admission. She was mismanaged by a native doctor before admission into our hospital.

wound are carefully closed in layers to avoid leaks. Tubes are sutured to the skin. The inlet irrigation tube (instillation tube) is connected to the drip bottle of normal saline/ringer solution containing a broad spectrum antibiotic solution. The outlet irrigation tube is connected to the suction pump as shown in Figure 1.

#### Postoperative care

The first 48 h are the most difficult. During the period a certain amount of bleeding occurs, especially in patients with sickle cell disease. One litre of normal saline/Ringer solution is allowed to run for 8 h.

Once a week a portion of fluid is taken from the outlet irrigation tube for culture and sensitivity – bacteriological examination. When the results are available appropriate antibiotics are applied. No fixed length of time for the treatment is given. When the bacteriological investigations show no bacterial growth from culture taken, the inlet irrigation tube is removed, but the outlet tube and the vacuum suction system are maintained until there is no further drainage. Routinely, 3 mega units Crystapen® (crystalline penicillin) 500 ml and streptomycin 1 g/500 ml are added to the irrigating fluids in the first 48 h.

## RESULTS

From 1978 to 1981 28 cases of chronic osteomyelitis were treated at the University of Nigeria Teaching Hospital, Enugu, Anambra State, Nigeria (Tables 1 and 2). Two cases of failure were recorded.

In 13 cases (Nos. 185253, 188413, 155396,

199998, 227242, 125809, 200154, 193567, 202677, 155396, 190579, 171310 and 227244) patients received various treatments from non-medically trained people like traditional healers (native doctors), chemists and herbalists. This has prolonged our period of treatment and also has made our operations much more difficult.

In two cases Nos. 171310 and 227244 the use of instillation-suction technique saved the patients' leg and arm from being amputated. Five cases (Nos. 149841, 208368, 204402, 196970 and 216655) received conventional treatment from other hospitals before being treated with instillation-suction technique in our hospital.

The assessment of any method of treatment of chronic osteomyelitis is complex and the course of the disease unpredictable (Taylor & Maudsley 1970). Clinical resolution was achieved with the instillation-suction technique in 26 of the 28 cases of chronic osteomyelitis which were resistant to conventional methods of treatment. No recurrences were seen during the observation period. In one case (No. 125809) the instillation-suction drains worked for 48 hours and then became blocked. On examination it was found that the patient has pulled both the inlet and outlet drains almost out and therefore the instillation-suction system was abandoned. The second failure was case No. 196970 in which the infection lasted over 7 years and a sequestrectomy was performed in another University Teaching Hospital which failed. Two months after the second operation there was a recurrence. Radiological examination 8 months later showed healthy new bone formation but there was a sequestrum in the distal portion of left femur and discharging sinus on the medial aspect of the left femur. Apparently not all the sequestra were removed during the second operation because of the very long period of infection.

## CONCLUSIONS

Instillation-suction technique has enabled us to resolve most of the chronic osteomyelitis infections, especially those that have resisted conventional methods of treatment.

Table 1. Patient data on 28 cases of chronic osteomyelitis treated by Willenegger's instillation-suction technique

Patient's hospital No.	Age (years)	Site of infection	History of infection	Other operations performed for infection
181862	9	Femur	Patient first seen on 28/5/79 before irrigation. Patient had swollen right knee, tender and warm to touch 2 months ago. Also had fever. Three months later discharging sinus right thigh. X-ray confirms chronic osteomyelitis right femur.	Incision and drainage
185253	16	Humerus	Admitted on 4/7/79. Started 2 years before with fever, pain and swelling left elbow joint. 1 year later discharging sinus from upper $\frac{1}{3}$ medial aspect of left humerus. X-ray confirms chronic osteomyelitis left humerus.	Left humerus incised locally by a native doctor
190579	7	Tibia	Admitted on 10/9/79. Started 1 year ago with fever, pain and swelling right knee joint. Patient had been receiving treatment from a native doctor prior to admission. X-ray confirms chronic osteomyelitis right tibia with sequestrum.	None
188413	4	Humerus	Admitted on 6/7/79. Had fever followed by pain and swelling right upper $\frac{1}{3}$ of humerus 2 years ago. X-ray confirms chronic osteomyelitis right humerus.	Incision and drainage done locally by a native doctor
149841	18	Femur	Admitted on 1/3/78. Had abscess both thighs since 1975. Later right thigh started discharging pus. X-ray confirms chronic osteomyelitis right femur.	Incision and drainage performed in another hospital
227244	12	Tibia	Patient sustained a simple closed fracture of the left tibia in November 1979. Treated by a native doctor and the simple fracture resulted in an open, grossly infected compound fracture of the tibia. Admitted early January 1980 with septicæmia. Sequestrectomy and irrigation performed 4 weeks later.	
208368	12	Tibia	Admitted on 17/4/80. Illness started with multiple abscesses right leg with fever and rigor in December 1979. Illness complicated with septicæmia and lung abscess. Patient recovered but an abscess on right tibia developed into an ulcer and persisted in spite of treatment. X-ray confirms chronic osteomyelitis right tibia.	Had sequestrectomy in another hospital
216690	2	Right femur and left femur	Admitted on 6/8/80. Lower $\frac{1}{3}$ of both femurs swollen, tender and warm to touch. Patient is suffering from sickle cell disease. Genotypes: SS. X-rays show chronic osteomyelitis both femurs with pathological fractures both femurs. Patient has discharging sinuses both femurs.	None

Patient's hospital No.	Age (years)	Site of infection	History of infection	Other operations performed for infection
204402	16	Tibia	Admitted on 28/2/80. Illness started 1 year ago with fever followed by pain and swelling of left tibia. Hospitalised at another hospital. Later a boil formed on medial aspect of upper 1/3 of left leg – was incised and since then has been discharging pus. X-ray confirms chronic osteomyelitis left tibia with a large sequestrum situated in the upper 1/3 of left tibia shaft.	Incision and drainage performed at another hospital
139270	6	Tibia	First seen on 20/9/77. Illness started a week before with fever followed by pain, swelling and tenderness of left tibia. Had a history of trauma left tibia X-ray of 28/4/79 shows chronic osteomyelitis with two large sequestra and three discharging sinuses left tibia. Sequestrectomy and irrigation performed on 25/6/79.	
128006	9	Humerus	Patient first attended on 20/4/77. Patient gave a history of a fall 6 weeks before thereby injuring her left upper arm. X-ray of 1/10/79 shows severe chronic osteomyelitis with three discharging sinuses. Sequestrectomy and irrigation performed on 8/10/79.	
155396	20	Tibia	First attended on 4/5/78. Illness started with fever, and later followed by left ankle pain, swelling and tenderness 1 year ago. Patient has a discharging sinus on left tibia X-ray show chronic osteomyelitis left tibia.	Incised two times by a native doctor
166668	12	Femur and Ulna	Patient first attended on 29/9/78. Patient had a discharging sinus lower 1/3 of left thigh following four incisions in left thigh made by a native doctor for "rheumatism" 3 years before. Left ulna also had a discharging sinus. X-ray shows chronic osteomyelitis of left femur and left ulna.	Four incisions carried out by a traditional healer (Native doctor) on left thigh
227242	5	Humerus	Admitted on 12/1/81 with discharging sinus left upper arm since 1 year ago. Patient has been receiving treatment for 2 years from a native doctor. X-ray confirms chronic osteomyelitis of humerus.	
125809	16	Tibia	Patient first seen on 10/3/77. Had history of fever, followed by pain, swelling, tenderness and warmth of left leg 1 year ago. Left leg was incised by a chemist. Incision wound has long since healed but her left leg has continued to swell. Patient managed conservatively. February 1979 recurrent swelling left leg. Radiological examination confirms chronic osteomyelitis left lower 1/3 of tibia.	Incision performed by a chemist

Patient's hospital No.	Age (years)	Site of infection	History of infection	Other operations performed for infection
196970	16	Femur	First attended on 28/11/79. Left thigh has been discharging pus for seven years. Started first with fever followed by pain and swelling of left thigh. Radiological examination confirms chronic osteomyelitis of distal $\frac{1}{3}$ of left femur. Sequestrectomy and irrigation performed on 5/6/80.	In May 1978 – sequestrectomy (L) femur performed at Lagos University Teaching Hospital
200154	6	Femur	First attended on 9/1/80 with a discharging sinus on right thigh, dating back 1 year ago. Started with fever and followed by pain, swelling and loss of function of right leg. Child has prior to admission into our hospital been receiving treatment from a native doctor. On examination child has also a shortening of right lower limb. X-ray shows chronic osteomyelitis with angulation distal end of right femur with a sequestrum. Sequestrectomy and irrigation performed on 17/780.	
202196	3	Calcaneus	First attended on 7/2/80 with discharging sinus left ankle. Radiological examination shows chronic osteomyelitis left calcaneus.	
216655	7	Humerus Tibia	Patient first seen on 6/8/80 with multiple discharging sinuses (4 sinuses) right tibia and a discharging sinus humerus. Illness started 18 months ago. X-ray confirms chronic osteomyelitis of right humerus and right tibia.	Had two sequestrectomies previously at two hospitals
193567	7	Tibia	Patient first attended on 23/5/78. Illness started 4 months ago with fever, pain and swelling left leg. Prior to presentation to our hospital patient has been receiving native treatment from a herbalist. After incision by the herbalist discharging sinus has developed on left tibia. Radiological examination shows chronic osteomyelitis left tibia.	Left leg incised at home by herbalist
156355	13	Tibia	First attended on 11/5/78 – patient had fever, followed by lower limb pain 2 weeks ago. Had also cough 5 days ago. On presentation patient had swelling and tenderness left leg – worse over the popliteal area and calf muscle – patient could not stand or walk on affected limb. No history of trauma. Radiological examination of 17/11/78 showed chronic osteomyelitis involving primarily the upper part of the left tibia and lower femur.	Left knee aspiration on 7/6/78
202677	15	Femur	First attended on 18/2/80 – 3 years ago patient suddenly developed fever, followed by pain and swelling at the back of the lower end of left thigh. Radiological examination showed multiple areas of bone destruction (sequestra) and new bone formation.	Incised by a native doctor

Patient's hospital No.	Age (years)	Site of infection	History of infection	Other operations performed for infection
138396	18	Tibia	Admitted on 7/9/79 with a short history of fever, jaundice and an acute inflammatory swelling over right upper tibia. Patient has sickle cell disease. Genotype: SS. X-ray of 10/8/80 showed severe chronic osteomyelitis with discharging sinus right tibia.	
171310	39	Femur	Patient first seen on 14/12/78 with discharging sinus right thigh. Right thigh has been discharging sinus for 2 years. No history of trauma. Has been receiving native treatment from a traditional healer prior to presentation in our hospital. Also had severe fever at onset of illness. X-ray shows chronic osteomyelitis affecting the entire diaphysis of right femur.	
217032	10	Tibia	Patient first seen on 13/8/80. Three month history of swelling left leg. X-ray shows extensive destruction of left tibia.	
155396	20	Tibia	First attended 4/5/78. Illness started 1 year ago with fever, pain and swelling left ankle. Later started discharging pus. Radiological examination shows chronic osteomyelitis in the lower 1/3 of left tibia and subperiosteal bone formation in the distal fibula.	Had two previous incisions by a native doctor at home
145480	19	Tibia	Admitted on 16/12/77. Patient had a traffic accident and thereby sustained a compound fracture of right tibia and fibula and a dislocation of the ankle joint. On 20/12/77 the infected wound was debrided, dislocation of the ankle reduced and above knee plaster of Paris applied with a POP window left open for dressing. X-ray of 12/10/79 shows chronic osteomyelitis with discharging sinus right tibia.	
210142	8	Fibula	Patient first seen on 13/1/80. Illness started with fever, followed by pain, swelling, tenderness and warmth right foot – 1 year ago. Patient has sickle cell disease – genotype: SS. Radiological examination of 29/5/80 showed osteolytic destruction and irregular bone formation and pathological fracture of right fibula suggesting chronic osteomyelitis.	

Table 2. Results of 28 cases of chronic osteomyelitis treated by Willenegger's instillation-suction technique

Hosp. no.	Organisms	Duration of infection before irrigation – Suction	Period of follow up	Present state	Result
181862	<i>Staphylococcus aureus</i>	7 months	2½ years	No recurrence	Good
185253	<i>Staphylococcus aureus</i>	32 months	2 <sup>2</sup> / <sub>3</sub> years	No recurrence	Good
190579	<i>Staphylococcus aureus</i>	19 months	2 <sup>2</sup> / <sub>3</sub> years	No recurrence	Good
188413	<i>Staphylococcus pyogenes coliform</i>	2½ years	3 months	No recurrence	Fair
149841	<i>Staphylococcus aureus</i> <i>Streptococcus species</i>	3½ years	2½ years	No recurrence	Good
227244	<i>Staphylococcus aureus</i>	7 months	1 <sup>5</sup> / <sub>6</sub> years	No recurrence	Good
208368	<i>Pseudomonas species</i> <i>Coliform species</i>	4 months	1 <sup>7</sup> / <sub>12</sub> years	No recurrence	Good
216690	<i>Staphylococcus aureus</i>	34 months	<sup>3</sup> / <sub>4</sub> years	No recurrence	Good
204402	<i>Staphylococcus aureus</i>	1 <sup>3</sup> / <sub>4</sub> years	2 <sup>5</sup> / <sub>6</sub> years	No recurrence after second treatment	Good
139270	<i>Staphylococcus aureus</i>	2 <sup>2</sup> / <sub>3</sub> years	<sup>3</sup> / <sub>4</sub> years	No recurrence	Good
128006	<i>Staphylococcus aureus</i>	1½ years	5 months	No recurrence	Good
155396	<i>Coliform species</i> <i>Staphylococcus</i>	3½ years (Femur) 3 <sup>2</sup> / <sub>3</sub> years (ulna)	1¼ years	No recurrence	Fair
166668	<i>Staphylococcus aureus</i>	2½ years	3 months	No recurrence	Good
227242	<i>Staphylococcus aureus</i>	3 <sup>7</sup> / <sub>12</sub> years	2½ years	Recurrence	Failed
125809	<i>Staphylococcus aureus</i>	7 <sup>7</sup> / <sub>12</sub> years	1½ years	Recurrence	Failed
196970	<i>Staphylococcus aureus</i>	1½ years	5 months	No recurrence	Good
200154	<i>Proteus species</i> <i>Coliform species</i> <i>Staphylococcus aureus</i>	4 months	4 months	No recurrence	Good
202196	<i>Staphylococcus aureus</i> <i>Coliform organisms</i>	19 months	1½ years	No recurrence	Good
216655	<i>Staphylococcus aureus</i> <i>Coliform bacilli</i>	2 years	6 months	No recurrence	Good
193567	<i>Staphylococcus aureus</i>	1 year	1 year	No recurrence	Good
156355	<i>Staphylococcus aureus</i>	3½ years	1½ years	No recurrence	Good
138396	<i>Staphylococcus aureus</i>	1 year	8 months	No recurrence	Good
171310	<i>Staphylococcus aureus</i>	2½ years	7 months	No recurrence	Good
171310	<i>Coliform organisms</i>	5 months	1 <sup>7</sup> / <sub>12</sub> years	No recurrence	Good
217032	<i>Staphylococcus aureus</i>	1 <sup>5</sup> / <sub>12</sub> years	5 months	No recurrence	Good
155396	<i>Staphylococcus aureus</i>	1 <sup>10</sup> / <sub>12</sub> years	1½ years	No recurrence	Fair
145480	<i>Staphylococcus aureus</i>	1½ years	1¼ years	No recurrence	Good
210142	<i>Staphylococcus aureus</i>	3 months	2½ years	No recurrence	Good

## REFERENCES

- Taylor, A. R. & Maudsley, R. H. (1970) Instillation-suction technique in chronic osteomyelitis. *J. Bone Joint Surg.* **52-B**, 88–92.
- Willenegger, H. & Roth, W. (1962) Die antibakterielle Spüldrainage chirurgischer Infektionen. *Dtsch. Med. Wochenschr.* **87**, 1485.

Correspondence to: Hubert N. Oguachuba, M.Sc. M.D. (FA.f.Chir.), FWACS, Department of Surgery, Faculty of Medical Sciences, University of Jos, P.M. 2084, Jos Plateau State, Nigeria.