

TOTAL HIP REPLACEMENT IN JUVENILE CHRONIC ARTHRITIS

BRYNJÓLFUR MOGENSEN, HÅKAN BRATTSTRÖM, LEIF EKELUND* & LARS LIDGREN

Departments of Orthopaedic Surgery and Diagnostic Radiology*, University of Lund, Lund, Sweden

Fifty total hip replacements in 33 patients with juvenile chronic arthritis were performed over a 10-year period with good pain reduction, increased hip motion but only a moderate increase in walking capacity. The average age at operation was 26 years and the average follow-up time 77 months.

Six hips (patients) have been reoperated, one for infection, one for suspected infection and four due to mechanical loosening. Loosening was revealed radiographically in 10 hips at follow-up. Lack of cement cover and varus position was the main reason for loosening of the femoral stem.

Considering the high loosening rate it is probable that at least one revision arthroplasty will be necessary in the future.

Key words: hip prosthesis; juvenile chronic arthritis

Accepted 16.ix.82

The 10–15 years of experience with total hip replacement (THR) have been promising but the failure rate has increased with time mainly due to mechanical loosening (Charnley 1979, Salvati et al. 1981). Most young patients will therefore probably outlive their prosthesis.

In patients with juvenile chronic arthritis (JCA) there are also often special problems such as anaesthetic difficulties, severe multiple joint involvement, protrusio acetabuli, soft bone tissue and small skeletal size. A custom-made prosthesis is often necessary.

Only a few short-term reports (Arden & Ansell 1978, Bisla et al. 1976, Chandler & Dickson 1974, Colville & Raunio 1979, Halley & Charnley 1975, Klassen et al. 1979, Singsen et al. 1978, Sledge 1977) and one 5-year follow-up study (Chandler et al. 1981) on THR in patients below the age of 30 are available.

The aim of this study is to present our results of

50 THR in patients with JCA with an average follow-up time of 77 months.

PATIENTS AND METHODS

During the past 10 years (1970–1979) 50 THR (Figure 1) in 33 patients with JCA were performed at the Departments of Orthopaedic Surgery and Rheumatology, University Hospital in Lund, Lund, Sweden. The average age of the patients at operation was 26 years (range 15–51 years). Nineteen were female and 14 male. The THR was performed on the right side in 26 hips and on the left side in 24 hips.

All the patients had juvenile chronic arthritis (Wood 1978). At follow-up 28 (41 hips) of the patients were classified as having juvenile rheumatoid arthritis (JRA) and five patients ankylosing spondylitis (nine hips, Table 2., Nos. 5, 7, 8, 9, 11, 12, 19, 24, 43). All the patients had polyarthritis at follow-up. The duration of the disease at operation averaged 18 years (range 6–49 years) and the duration of hip symptoms 13 years (range 1–49 years). Pain and/or poor motion was the

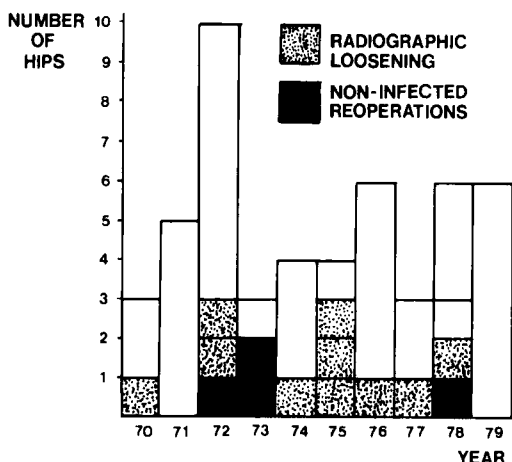


Figure 1. Fifty THR in JCA. The annual number of operations, radiographic loosening and non-infected reoperations during a 10-year period.

main indication for THR in 36 hips, and severe contractures and poor motion for another 14 hips.

Twenty-eight operations had been performed previously in 24 hips: Cup arthroplasty in 6, synovectomy in 4, osteotomy of the proximal femur in 2, hip arthrodesis in 1, Girdlestone in 1, Chiari osteotomy in 1, acetabular roof plasty in 1, arthroscopy in 1 and soft tissue releasing operations in 11 hips.

The scoring system suggested by Merle d'Aubigné & Postel (1954) as modified by Charnley (1972) has been used for evaluation (Table 1). The functional classifica-

tion of the American Rheumatoid Association (ARA) (Steinbrocker et al. 1949) was also used.

Standard AP and lateral radiograms were obtained with the patients in a supine position preoperatively, postoperatively, within 6 months, later as needed and at follow-up. In three patients, radiograms obtained within 12 months from the last clinical evaluation were used.

The preoperative radiograms were evaluated according to Larsen et al. (1977) using a six-grade scale where stadium 0 is normal and stadium 5 reveals mutilating changes.

The prosthetic components were considered to be loose if there was a radiolucent zone of more than 2 mm locally or all around the cement or between the cement and the components.

The cement cover around the components and the position of the components were evaluated and correlated to the radiolucent zones and to the clinical findings.

Valgus and varus position of the femoral stem was determined by its orientation to the longitudinal axis of the femur as revealed by the AP radiograms.

Surgical and anaesthetic remarks

Thirty-five of the THR were performed under intubation anaesthesia. There were difficulties in intubation in seven of these cases and a fiberoendoscope had to be used. In seven cases intubation was tried but could not be performed. Inhalation anaesthesia was used in eight cases. Epidural anaesthesia alone was used for two patients and epidural combined with inhalation anaesthesia for five.

The lateral incision was used in 39 hips combined

Table 1. Numerical classification of the clinical state of affected hip joints

Score	Pain	Range of movement, degrees	Walking
1	Severe and spontaneous	0- 30	Few yards or bedridden. Two sticks or crutches
2	Severe on attempting to walk. Prevents all activity	31- 60	Time and distance very limited with or without sticks
3	Tolerable, permitting limited activity	61-100	Limited with one stick (less than 1 h) Difficult without a stick Able to stand long periods
4	Only after some activity	101-160	Long distance with one stick Limited without a stick
5	Slight or intermittent Pain on starting to walk but getting less with normal activity	161-210	No stick but a limp
6	No pain	211-260	Normal

Table 2. Classification* of pain, range of movement and walking capacity in 50 THR in 33 patients

No. of hips	Type of prosthesis**	Side	Follow-up, months	Pain			Range of movement		Walking	
				Before operation	After operation	Follow-up	Before operation	Follow-up	Before operation	Follow-up
1	MKF	L	140	2	6	6	1	4	2	4
2	MKF	L	136	1	5	5	2	6	2	3
3	MKF	R	126	1	6	5	2	5	1	3
4	MKF	R	133	6	6	6	1	3	4	4
5	MKF	R	127	2	6	5	1	6	1	3
6	MKF	R	68	2	5	4	4	5	2	3
7	MKF	R	120	5	6	6	1	4	2	4
8	MKF	L	120	5	6	6	1	4	2	4
9	MKF	L	114	3	6	6	1	5	3	4
10	MKF	L	106	2	5	5	3	5	2	4
11	MKF	R	115	2	6	6	1	6	2	5
12	MKF	R	113	3	6	6	1	4	3	4
13	MKF	R	114	3	6	5	1	4	2	5
14	MKF	R	108	2	6	6	1	4	2	2
15	MKF	R	107	3	6	6	1	5	2	4
16	MKF	L	107	3	6	6	2	4	2	4
17	HM	L	107	5	5	5	3	3	1	1
18	MKF	L	102	2	5	5	2	4	2	2
19	MKF	L	103	2	6	5	2	6	2	3
20	HA	R	65	5	6	3	3	3	1	1
21	HA	R	99	1	6	3	4	4	1	2
22	HA	L	82	3	6	6	1	4	1	1
23	HA	R	84	4	6	6	1	4	1	1
24	H	L	84	6	6	6	1	5	3	5
25	HA	L	83	4	6	6	1	3	1	1
26	MKA	R	76	5	6	6	1	6	2	3
27	HA	L	74	1	6	6	2	5	1	2
28	HA	R	71	1	6	6	2	5	1	2
29	MKA	R	72	2	6	4	1	3	2	3
30	HA	R	65	2	6	4	3	6	2	3
31	HA	L	62	4	6	6	1	4	2	4
32	HA	L	63	2	6	5	3	5	2	3
33	HA	L	57	6	5	6	1	3	1	1
34	HA	R	59	4	6	6	2	4	2	4
35	B	L	56	2	5	5	2	6	2	3
36	MKA	R	54	2	6	6	2	5	2	4
37	MKA	L	51	2	6	6	2	5	2	4
38	MKA	R	51	2	6	6	2	5	2	4
39	MKA	L	13	2	4	2	4	5	3	3
40	HA	L	43	1	6	5	2	5	1	2
41	L	L	34	2	6	6	2	5	2	3
42	L	R	36	2	6	5	2	4	2	2
43	L	R	34	2	5	5	4	5	2	3
44	MKA	L	35	3	5	4	2	3	4	3
45	L	R	31	1	6	6	4	4	2	2
46	HA	R	30	1	6	6	1	4	1	1
47	HA	L	24	2	6	6	1	6	1	1
48	L	L	25	4	5	5	1	4	1	5
49	L	R	25	4	5	5	1	4	1	5
50	L	R	24	1	6	6	2	5	2	2
Average			77	2.7	5.7	5.3	1.8	4.5	1.9	2.8

* The classification of Merle d'Aubigné & Postel as modified by Charnley, see Table 1.

** See surgical remarks.

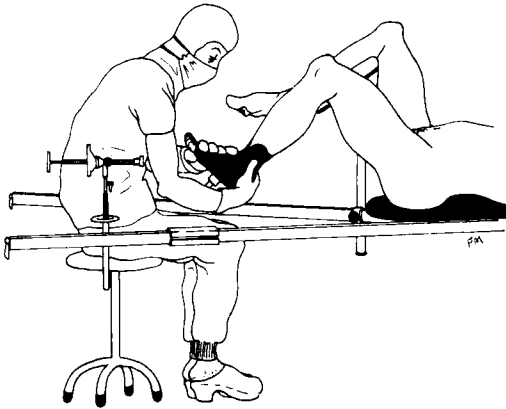


Figure 2. The patient on the traction table and an unsterile assistant manipulating the leg.

with trochanter osteotomy in one of the hips. The postero-lateral incision was used in 11 hips.

For 11 patients with severe bilateral hip and knee contractures, the special lay-up technique of the patient on the operation table was needed using an unsterile assistant according to McKee-Farrar (McKee & Watson-Farrar 1966) with a minor modification (Figure 2).

Soft tissue releasing operations were necessary in 19 of the THR to correct flexion and/or adduction deformities. Nine hips were clinically ankylotic. In one patient out of 11 with severe acetabular protrusion a spongy bone transplantation from the femoral head to the acetabular floor was performed. The following prostheses were used: McKee-Farrar (MKF) 18, Howse Arden (HA) 15 (small prosthesis, designed for JCA), McKee-Arden (MKA) 7, Lubinus (L) 7, Howse (H) 1, Howse mini (HM) 1 and Brunswick (B) 1 (Table 2). Four of the small femoral stems had to be decreased further preoperatively to fit the inner femoral diameter in our patients and twice it was necessary to reduce the external diameter of the already small acetabular cup. Both hips were operated on in the same session in one patient. In six patients both hips were operated on during the same hospital stay.

In 41 replacements adequate antibiotic prophylaxis was given with cloxacillin 1 g \times 4 times daily (Ericson et al. 1973). The first injection was given at the time of premedication and continued for 1 week. Four patients were given antibiotics during the procedure and five received no antibiotics at all.

An abduction pillow was used 14 nights postoperatively. Exercises were started on the day after the operation and weight-bearing as soon as possible. Hydrotherapy was used in most cases after wound healing.

RESULTS

The preoperative anaesthetic time averaged 65 min (range 25–155 min) and the average operation time was 155 min (range 55–255 min). The preoperative bleeding was 1675 ml (range 500–5900 ml) and the total bleeding 2115 ml (range 855–6575 ml).

The total hospital stay was on an average 56 days (range 14–297 days). Five patients stayed more than 100 days and often several other procedures were performed during the same hospital stay.

Early complications

The femoral shaft was perforated once during reaming but this was observed and the prosthesis could be cemented in a good position. One patient with severe acetabular protrusion had a fracture of the acetabular wall during the operation which eventually healed. One patient had a severe anaphylactic reaction due to dextran infusion but recovered.

There were two postoperative dislocations (nos. 30, 34), one during physiotherapy after 3 days and one after 2 months. Both were reduced under general anaesthesia and treated with traction for 3 weeks without further dislocations. The lateral angle was 60 degrees of both cups and one was also retroverted.

In two patients (three hips, nos. 33 and 31, 34, Table 2) it was necessary to mobilize the hips postoperatively under general anaesthesia.

Late complications

There was one deep infection in a patient who did not receive any preoperative antibiotics (no. 6, Table 2). The patient was almost painfree (grade 5) in the beginning but later had increasing pain (grade 4), progressing radiolucent zones and subsidence of the femoral stem. Revision arthroplasty with gentamicin cement was performed after 68 months with good results until the patient fell and sustained a femoral fracture below the femoral stem 34 months after the revision arthroplasty. *Propionibacterium acnes* was cultured in three out of five tissue biopsies at

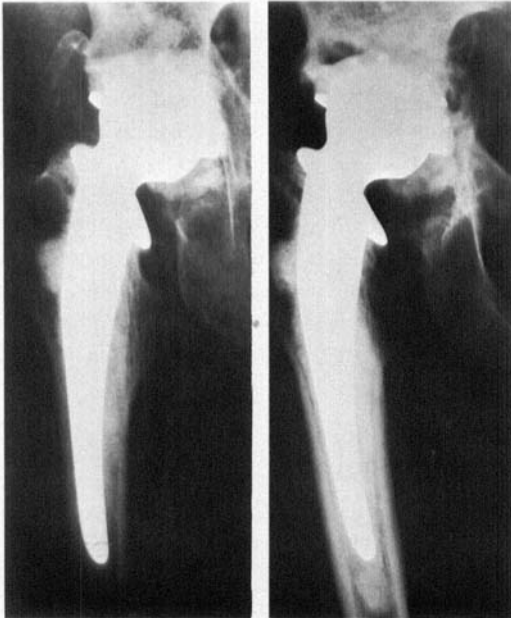
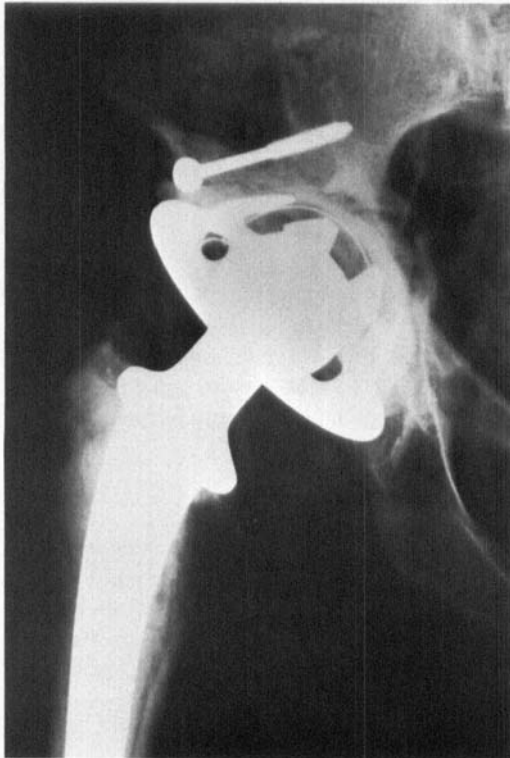

Figure 3a. The McKee-Farrar prosthesis and adequate acetabular bone stock.

Figure 3b. Migration, protrusion and loosening of the cup. At the time of the revision arthroplasty there were three large perforations in the pelvis and an unhealed fracture of the posterior inferior part of the acetabulum.

Figure 3c. Bone from the iliac crest and an Eichler ring were used to build up a new acetabulum and a Lubinus prosthesis inserted.



reoperation (Kamme & Lindberg 1981). After 4 months of traction without any tendency to bone healing this patient was again reoperated with a

300 mm Lubinus prosthesis with good results at follow-up after 21 months. Five tissue biopsies were negative at the second revision arthroplasty.

In another patient (no. 39, Table 2) deep infection was suspected. He was never painfree after the THR and the radiograms revealed progressing irregular radiolucent zones (>2 mm) between the cement and the femoral shaft (Bergström et al. 1974, Tehranzadeh et al. 1981). Erythrocyte sedimentation rate was 91 mm at 13 months when revision arthroplasty with gentamicin cement was performed with good results 31 months later. Five tissue biopsies were negative possibly due to an unfortunate cloxacillin prophylaxis at the time of premedication at reoperation.

Clinical loosening

Three acetabular cups, one metal (no. 13) and two polyethylene (no. 20, 44), loosened and were reoperated after 114 (Figures 3a, b, c), 65 and 35 months respectively. In one of the revised hips (no. 20) there is a radiolucent zone of more than 2 mm around the socket 4 years later but the hip is painfree. In one patient operated with a Howse Arden prosthesis (no. 21) the femoral stem loosened and was replaced after 99 months.

Gradually increasing pain at weight-bearing was the main reason for reoperation in these cases.

Clinical follow-up

The average clinical follow-up was 77 months (range 13–140 months). The shortest follow-up time was 24 months in the patients who were not

reoperated (Table 2). All but one (no. 30) of the non-reoperated patients were satisfied with the pain relief at follow-up. The grade of pain was on an average 2.7 points before the THR and at follow-up 5.3 points, all patients included (Table 2).

The range of movement increased from an average of 1.8 to 4.5 points but 22 hips were in class 1 before the THR (Table 2) and nine of these were ankylotic. There was a flexion contracture in 43 hips an average of 30° (range 10–70) before the THR but only 6° at follow-up (range 0–30). Compared with their hip mobility at discharge, the patients usually had the same or better range of flexion at follow-up. Even the patients with ankylosing spondylitis had the same range of motion at follow-up as when they left the hospital.

Walking was only moderately improved due to multiple joint involvement (Table 2), but the patients considered the improvement very important. Eight operations including the THR had been performed on average (range 2–26) at follow-up.

Nineteen of the patients lived or tried to live an active sex-life before the arthroplasty but 16 had problems due to pain, stiffness or both. All but one were more satisfied with their sex-life after the THR due to the pain relief and/or better hip mobility.

At follow-up 13 patients worked, 11 patients had some kind of pension, seven patients studied and two were housewives.

The patients were on the average in ARA class 3.1 before the operation and in class 2.7 at follow-up.

All of the patients not reoperated were satis-

fied with the overall results of the THR at follow-up. Four (nos. 6, 13, 20, 21) of the six reoperated patients were satisfied with both the results of the primary THR and the revision and would have a new THR under the same circumstances. One (no. 39) was pleased with the results of the revision arthroplasty. The remaining reoperated patient (no. 44) was dissatisfied with both the primary and the revision arthroplasty mainly due to poor range of motion.

Radiographic features

Thirty-seven hips were in stadium four (8 hips) or five (29 hips) preoperatively according to Larsen et al. and of these, four were ankylotic. Three hips were in stadium three. Preoperative radiograms of four hips were not available and six hips were previously operated with a Smith-Petersen cup. In 11 hips acetabular protrusion (Hastings & Parker 1975) was present prior to THR and in six there were lateral subluxations of the femoral head.

Thirty-seven of the acetabular cups were cemented within 45° ± 10° of latero version, six cups in more than 55° and seven in less than 35°. Four cups were cemented in retro version. Radiolucent cement was used in the three first hips.

The migration or radiographic loosening in 10 hips is summarized in Table 3.

In three of the 11 hips (nos. 23, 27, 28) the initial protrusio increased slightly with time and one Howse Arden cup (no. 23) was loose (2–5 mm zone) but painfree after 84 months.

One of the hips (no. 40, pain grade 5) had a 7

Table 3. Radiographic loosening in 10 total hip replacements

Acetabular socket		Femoral component	
Adequate bone stock for socket cover	23	Sufficiently cemented	30
1 loose		1 loose	
Protrusio acetabuli	11	Insufficiently cemented	14
2 migrated		4 subsided and loose	
1 migrated and loose		Radiolucent cement	3
1 loose		1 loose	
Lateral subluxation	6		
2 loose			

mm zone medial of the acetabular cup at 43 months. A Howse Arden cup had been used and the spongy bone of the femoral head transplanted to the acetabular wall

Of the six hips with lateral subluxation, one acetabular socket (no. 20) and one femoral stem (no. 21) had been replaced. Two acetabular sockets (no. 17, 29) and one femoral stem (no. 36) were radiographically loose at follow-up. One patient with lateral subluxation which was bilaterally operated had loosening on the left side (no. 17) after 107 months and the other hip (no. 20) had been previously replaced after 65 months.

In one laterally subluxated hip (no. 29) Chiari osteotomy was performed to create a better bone support of the acetabular socket. McKee-Arden arthroplasty was carried out when the osteotomy had healed. There was a radiolucent zone and poor cement support lateral of the socket from the beginning and the socket was loose at follow-up 72 months later. Periodically the patient has had a slight pain and the feeling of locking in the hip; he is waiting for reoperation.

In one patient bilaterally operated with a McKee-Farrar prosthesis (nos. 6, 10) both components of the left side were loose (no. 10) after 106 months. The cup had also migrated centrally. The patient is waiting for a reoperation. The other hip (no. 6) was earlier reoperated because of infection.

Twenty-one of the femoral stems were cemented in varus, 16 in a neutral position and 13 in a valgus position. In 17 hips the cement did not cover the prosthesis distally and/or around the tip (16 hips) or proximally medially (1 hip). The radiograms revealed radiolucent zones of more than 2 mm in five out of 15 hips (infected hips excluded) with lack of cement cover around the femoral stem and one of these (no. 21) was replaced because of symptomatic loosening. Thirteen of the 15 femoral stems were in varus.

In one sufficiently cemented prosthesis out of 30 (no. 36) the radiograms revealed a radiolucent zone of more than 2 mm proximally laterally and a cement fracture above the tip but the zone has been unchanged the last 2 years ($P < 0.05$).

In three hips (no. 27, 28, 30) all in varus with no cement cover lateral of the femoral tip, the

stem had subsided at least 10 mm at follow-up after 74, 75 and 65 months respectively. One (no. 30) had moderate pain (grade 4). In one hip (no. 3) where radiolucent cement was used, the stem subsided 7 mm during the first 6 years but has been unchanged the last 5 years. Both components had migrated or were radiographically loose in altogether three hips. Resorption of the femoral calcar (2–15 mm) was observed in six hips. In the hip with 15 mm of resorption the femoral stem was in varus from the beginning with no cement support medially.

Heterotopic ossification grade 3 (Rosendahl et al. 1977) was found in two hips (nos. 38, 44) and caused decreased motion in one hip (no. 44).

No correlation was found between previous hip surgery and radiographic loosening or reoperation.

Small prostheses custom-made for juvenile chronic arthritis were used in 16 hips. Of the 14 cases of clinical and radiographic loosening (infections excluded) eight concerned the small prostheses ($P < 0.05$).

Patients with radiographic loosening had on an average pain grade 5.2 at follow-up compared with 5.7 of the radiographic non-loose THR.

Three patients with bilateral THR (nos. 6 & 10, 17 & 20, 27 & 28) had clinical or radiographic complications on both sides.

DISCUSSION

Most patients with JCA have a favourable prognosis (Hanson et al. 1977). Hip involvement is, however, common in those left with long-standing arthritis (Isdale 1970, Rombouts & Rombouts-Lindemans 1971) and is the major cause of limited locomotion (Arden & Ansell 1978, Isdale 1970).

The survival of THR was analysed by Dobbs and the results indicated that for metal-on-metal prosthesis the probability of survival was one third after 20 years and three fourths for metal-on-plastic. The predominant reason for failure was loosening and the annual reoperation rate tended to increase with time. Halley & Charnley speculated that there are 25–30 years of function before wear necessitates revision.

One has to remember that although the 10-year result of THR is favourable this is only about one fourth of the expected length of life for a patients with JCA. Long-term results of revision arthroplasties due either to mechanical loosening or infections are not available for patients with either good or poor bone quality. Joint replacement will thus still be a controversial subject in JCA until more is known about the long-term results. The average follow-up of 77 months in our study is the longest reported for patients with JCA.

The clinical results in this study concerning pain relief (2.7 to 5.3 points), increased range of hip motion (1.8 to 4.5 points) (Table 2) and decreased flexion contractures (30° to 6°) were satisfactory. The gain in walking capacity was moderate (1.9 to 2.8 points) although appreciated by the patients and influenced by multiple joint involvement.

On the average eight operations had been performed on the patients at follow-up. The quality of sex-life improved after the THR but the functional status was almost unchanged. This is in accordance with the observations of Baldrsson.

Six hips had been reoperated (Figure 1), two after infections, and four because of loosening. The results after revision arthroplasty are promising so far. In 10 hips there was radiographic loosening (Figure 1) and two of these patients are waiting for reoperation.

There were more reoperations and cases of radiographic loosening in this study than in the short-term reports (Arden & Ansell 1978, Bisla et al. 1976, Chandler & Dickson 1974, Colville & Raunio 1979, Halley & Charnley 1975, Klassen et al. 1979, Singsen et al. 1978, Sledge 1977) but the number is much lower than the actual or potential failure rate of 57 per cent in a 5-year follow-up study reported by Chandler et al. (1981).

Contrary to other reports, previous hip surgery did not affect the loosening rate (Carlsson & Gentz 1980, Chandler et al. 1981) or the infection rate (Poss & Sledge 1981).

The varus position of the femoral stem was common (21/50) and more than half of the

prostheses in varus had also had lack of cement cover. There was a good correlation between lack of cement cover and radiographic loosening and this has also been reported earlier (Beckenbaugh & Ilstrup 1978, Carlsson & Gentz 1980, Moreland et al. 1980, Olsson et al. 1981).

The grade of pain relief was lower (5.2 points compared with 5.7 points) in the group with radiographic loosening. The same was observed by Beckenbaugh & Ilstrup (1978) and Carlsson & Gentz (1980).

Five of the six hips with lateral subluxation prior to THR were loose clinically or radiographically. In three of these hips the acetabular socket was loose.

It is of great importance to create good lateral support when the acetabulum is deficient. The femoral head can be used for this purpose, as described by Harris et al. (1977).

We found a higher failure rate for small prostheses. The explanation could be related to the disease with poor bone quality. The skeletal size caused difficulties in obtaining a good position of the femoral stem and cement coverage. The prosthetic design with an acetabular snap-fit cup and the wedges of the femoral stem may contribute especially in combination with inadequate cement support.

The technique of insertion and cementing has changed during the last decade and with new prosthetic design it is very likely that the results will be better in the future.

If possible, it is important to delay THR for the youngest patients.

Arthroscopy of the hip gives good information about the cartilage and the synovial membrane and should be used early to decide synovectomy (Holgersson et al. 1981). Synovectomy of the hip in JCA gives good pain relief for three fourths of the patients for several years and should always be considered before THR is performed if the cartilage destruction is not great (Mogensen et al. 1982). In the young patients with JCA where THR has to be performed, both the patient and the surgeon should be aware that although the short-term results are satisfactory at least one revision arthroplasty will probably be necessary in the future mainly due to mechanical loosening.

REFERENCES

- Arden, G. P. & Ansell, B. M. (1978) *Surgical management of juvenile chronic polyarthritis*. Academic Press, London; Grune & Stratton, New York.
- Baldursson, H. (1980) Hip replacement with the McKee-Farrar prosthesis in rheumatoid arthritis. *Acta Orthop. Scand.* **51**, 639–648.
- Beckenbaugh, R. D. & Ilstrup, D. M. (1978) Total hip arthroplasty. A review of three hundred and thirty-three cases with long follow-up. *J. Bone Joint Surg.* **60-A**, 306–313.
- Bergström, B., Lidgren, L. & Lindberg, L. (1974) Radiographic abnormalities caused by post-operative infection following total hip arthroplasty. *Clin. Orthop.* **99**, 95–102.
- Bisla, R. S., Inglis, A. E. & Ranawat, C. S. (1976) Joint replacement surgery in patients under thirty. *J. Bone Joint Surg.* **58-A**, 1098–1104.
- Carlsson, A. S. & Gentz, C.-F. (1980) Mechanical loosening of the femoral head prosthesis in the Charnley total hip arthroplasty. *Clin. Orthop.* **147**, 262–270.
- Chandler, H. P. & Dickson, D. B. (1974) Total hip replacement in young patients. *Am. Acad. Orthop. Surg. Instruct. Course Lect.* **23**, 184–194.
- Chandler, H. P., Reineck, F. T., Wixson, R. L. & McCarthy, J. C. (1981) Total hip replacement in patients younger than thirty years old. *J. Bone Joint Surg.* **63-A**, 1426–1434.
- Charnley, J. (1972) The long-term results of low-friction arthroplasty of the hip performed as a primary intervention. *J. Bone Joint Surg.* **54-B**, 61–76.
- Charnley, J. (1979) *Low friction arthroplasty of the hip*. Springer-Verlag, Berlin.
- Colville, J. & Raunio, P. (1979) Total hip replacement in juvenile rheumatoid arthritis. *Acta Orthop. Scand.* **50**, 197–203.
- Dobbs, H. S. (1980) Survivorship of total hip replacements. *J. Bone Joint Surg.* **62-B**, 168–173.
- Ericson, C., Lidgren, L. & Lindberg, L. (1973) Cloxacillin in the prophylaxis of postoperative infections of the hip. *J. Bone Joint Surg.* **55-A**, 808–813.
- Halley, D. K. & Charnley, J. (1975) Results of low friction arthroplasty in patients thirty years of age or younger. *Clin. Orthop.* **112**, 180–191.
- Hanson, V., Kornreich, H., Bernstein, B., Koster King, K. & Singsen, B. (1977) Prognosis of juvenile rheumatoid arthritis. *Arthritis Rheum.*, Suppl. 2, **20**, 279–284.
- Harris, W. H., Crothers, O. & Oh, I. (1977) Total hip replacement and femoral head bone-grafting for severe acetabular deficiency in adults. *J. Bone Joint Surg.* **59-A**, 752–759.
- Hastings, D. E. & Parker, S. M. (1975) Protrusion acetabuli in rheumatoid arthritis. *Clin. Orthop.* **108**, 76–83.
- Holgerson, S., Brattström, H., Mogensen, B. & Lidgren, L. (1981) Arthroscopy of the hip in juvenile chronic arthritis. *J. Pediatr. Orthop.* **1**, 273–278.
- Isdale, I. C. (1970) Hip disease in juvenile rheumatoid arthritis. *Ann. Rheum. Dis.* **29**, 603–608.
- Kamme, C. & Lindberg, L. (1981) Aerobic and anaerobic bacteria in deep infections after total hip arthroplasty. *Clin. Orthop.* **154**, 201–208.
- Klassen, R. A., Parlasca, R. J. & Bianco, A. J. (1979) Total joint arthroplasty. Applications in children and adolescents. *Mayo Clin. Proc.* **54**, 579–582.
- Larsen, A., Dale, K. & Eek, M. (1977) Radiographic evaluation of rheumatoid arthritis and related conditions by standard reference films. *Acta Radiol. Diag.* **18**, 481–491.
- McKee, G. K. & Watson-Farrar, J. (1966) Replacement of arthritic hips by the McKee-Farrar prosthesis. *J. Bone Joint Surg.* **48-B**, 245–259.
- Merle d'Aubigné, R. & Postel, M. (1954) Functional results of hip arthroplasty with acrylic prosthesis. *J. Bone Joint Surg.* **36-A**, 451–475.
- Mogensen, B., Brattström, H., Ekelund, L., Svantesson, H. & Lidgren, L. (1982) Synovectomy of the hip in juvenile chronic arthritis. *J. Bone Joint Surg.* **64-B**, 295–299.
- Moreland, J. R., Gruen, T. A., Mai, L. & Amstutz, H. C. (1980) Aseptic loosening of total hip replacement: incidence and significance. *The Hip*. Proceedings of the Eighth Open Scientific Meeting of The Hip Society, pp. 281–291.
- Olsson, S. S., Jernberger, A. & Tryggö, D. (1981) Clinical and radiological long-term results after Charnley-Müller total hip replacement. *Acta Orthop. Scand.* **52**, 531–542.
- Poss, R. & Sledge, C. B. (1981) Total hip replacement in rheumatoid arthritis. *Reconstr. Surg. Trauma* **18**, 139–146.
- Rombouts, J. J. & Rombouts-Lindemans, C. (1971) Involvement of the hip in juvenile rheumatoid arthritis. *Acta Rheum. Scand.* **17**, 248–267.
- Rosendahl, S., Krogh Christoffersen, J. & Nørgaard, M. (1977) Para-articular ossification following hip replacement. *Acta Orthop. Scand.* **48**, 400–404.
- Salvati, E. A., Wilson, P. D., Jolley, M. N., Vakili, F., Aglietti, P. & Brown, G. C. (1981) A ten-year follow-up study of our first one hundred consecutive Charnley total hip replacements. *J. Bone Joint Surg.* **63-A**, 753–767.
- Singsen, B. H., Isaacson, A. S., Bernstein, B. H., Patzakis, M. J., Kornreich, H. K., King, K. K. & Hanson, V. (1978) Total hip replacement in children with arthritis. *Arthritis Rheum.* **21**, 401–406.
- Sledge, C. B. (1977) Joint replacement surgery in juvenile rheumatoid arthritis. *Arthritis Rheum.* **20**, 567–572.
- Steinbrocker, O., Traeger, C. H. & Batterman, R. C. (1949) Therapeutic criteria in rheumatoid arthritis. *J. Am. Med. Assoc.* **140**, 659–662.
- Tehranzadeh, J., Schneider, R. & Freiburger, R. H. (1981) Radiological evaluation of painful total hip replacement. *Radiology* **141**, 355–362.
- Wood, P. (1978) Special meeting on: nomenclature and classification of arthritis in children. In *Eular Bulletin*. Monograph. series no. 3 (Ed. Munthe, E.), pp. 47–50. Eular Publishers, Basel.