

Distraction of the growth plate

Experiments in pigs and sheep

Distraction of the growth plate of the distal radius was performed on 15 pigs and 10 sheep of growing age. The separation of the plate from the metaphysis occurred within 4-6 days after the operation. The distraction rate was 1-1.5 mm/day and was continued for 1-3 weeks. Consolidation of the separation area occurred within 6 weeks. Oxytetracycline bone labelling showed that the ossification developed toward the centre of the separation line from the metaphysis and from the inner layer of the periosteum as well as from the physeal side. The growth of the bone continued after the distraction procedure and in most cases the growth plate was open when examined radiologically after the distraction.

Distraction of the growth plate is a relatively new method for leg lengthening (Ilizarov & Soybelman 1969, Monticelli & Spinelli 1981b). This method has recently been used in veterinary surgery in treating bone inequalities and angular deformities, e.g. carpal valgus of osteodystrophic dogs (Paatsama et al. 1983).

Experimental studies have revealed somewhat conflicting results concerning the effects of the distraction on the further growth of the limb. According to Letts & Meadows (1978), there is a risk of premature closure of the growth plate. On the other hand, in the experiments of Monticelli & Spinelli (1981a), the growth of the bone was usually not disturbed. It has been shown that healing of the separation area occurs rapidly by enchondral ossification without any notable periosteal callus formation (Monticelli et al. 1981).

Material and methods

Distraction of the growth plate with an external fixation device was performed on 15 pigs and 10 sheep of growing age. In pigs we used the Hoffman external fixation system with distraction bars. The distraction device used in the sheep is shown in Figure 1. The device, developed by the authors, is based on the Rezaian-Karaharju frame. The age of the pigs varied from 10 to 16 weeks, while the sheep were 8 to 16 weeks old at the beginning of the distraction procedure. In the present study we used

**Jari Peltonen,
Ilkka Alitalo,¹
Erkki Karaharju &
Harri Heliö**

Department of Orthopaedics and Traumatology, University Central Hospital, Topeliuksenkatu 5, SF-00260 Helsinki 26, Finland and ¹College of Veterinary Medicine, Department of Surgery, Helsinki, Finland

the distal radial growth plate for distraction. The healing of the distracted area was studied radiologically and by means of oxytetracycline (OTC) bone labelling (Milch et al. 1958). The pigs were operated under general anaesthesia and the sheep were sedated for the operation by giving 0.3 ml of 2% xylatsin solution (Rompun®) i.v.

Surgical procedure

Two 1.7 mm Kirschner pins were drilled percutaneously through the growth plate of the distal radius and one or two 2 mm pins through the diaphysis. The external fixation frame was applied and the distraction performed gradually at a rate of 1-1.5 mm/day.

Diaphyseal osteotomy of the ulna and resection of a 5 mm thick disc of the bone were performed on seven of the pigs.

An acute separation of the growth plate from the metaphysis was induced at the primary operation in three of the sheep. The acute separation was done by immediately continuing the distraction until the epiphysiolysis occurred.

The gradual distraction was continued for 1-3 weeks and the distraction device was kept in place until there was radiologically observable consolidation of the separation area. The force needed for the separation was semiquantitatively evaluated from the force needed to turn the distraction bars and from the bending of the pins. The animals were given a therapeutic dose of dihydrostreptomycin procaine-penicillin (Streptocillin®) i.m. during the operation and daily for a week postoperatively. Radiographs

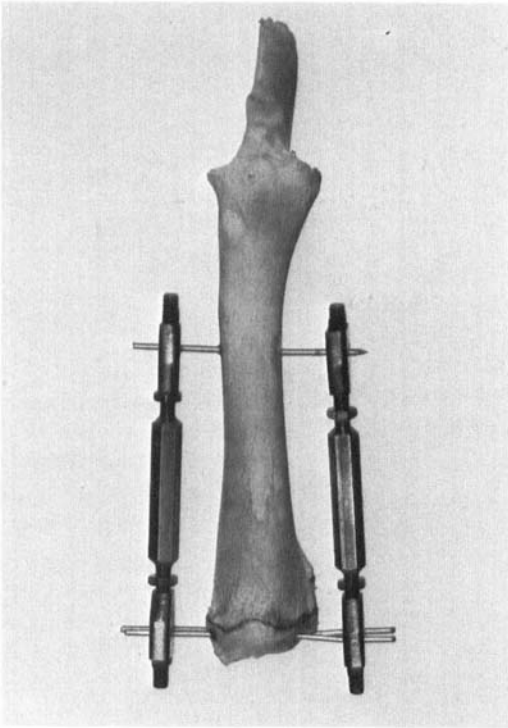


Figure 1. The compression-distraction device applied to a radius of a sheep.

were taken immediately after operation to check the correct position of the pins.

Both forelimbs of the animals were radiographed weekly. The film focus distance was 1 m. The length of the radius was measured and the consolidation of the separation area was estimated from the a-p projections of the radiographs. The non-operated radius was used as a control. After removal of the distraction device, the growth of the limb was followed radiologically.

Oxytetracycline (OTC) bone labelling was used to study the bone formation in the separation area. The animals were given oxytetracycline (Terramycin®) 50 mg/kg i.m. 1–4 weeks before being killed. The bone preparations were sawn longitudinally and photographed in reflected fluorescent light.

Results

The separation of the growth plate from the metaphysis occurred within 4–6 days after the distraction was started (Figure 2). When the distraction was performed gradually the sepa-

ration occurred easily. On the other hand, when epiphysiolysis was induced during the primary operation, clearly more force was needed to achieve the separation. The osteotomy of the diaphysis of the ulna of seven pigs did not affect the separation of the growth plate of the radius.

The initial lengthening of the porcine radius varied from 3 to 20 mm and the distraction length in sheep varied from 6 to 20 mm. The consolidation of the separation area started from 4 weeks postoperatively and the ossification was radiologically well developed at 6–8 weeks after the operation. Figure 3 shows the situation 10 weeks postoperatively. No notable differences appeared between the pigs and sheep as regards the consolidation time of the distracted area. In pigs a quite marked callus formation around the physal area was noticed during the healing of the separation line.

One to two weeks after the operation on the pigs and 3 weeks after the operation on the sheep, a cortical thickening of the pin tract in the diaphysis could be seen, increasing as the

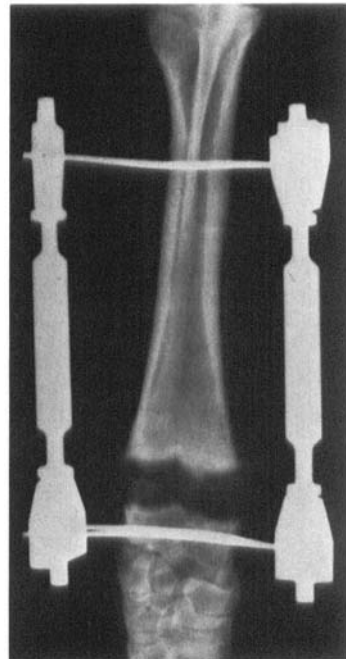


Figure 2. Separation of the epiphysis from the metaphysis occurred within 4–6 days after the operation.

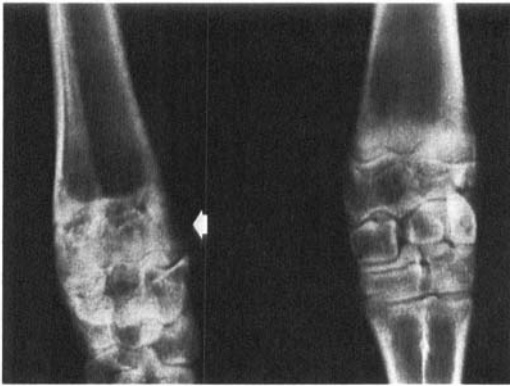

Figure 3. Consolidation of the distracted area (arrow) 10 weeks postoperatively.

external fixation proceeded. After the distraction device was removed, the length gained was slightly reduced during the following 1–2 weeks. The longitudinal growth of the operated radius of the ten animals followed after removal of the device, continued in eight cases.

The follow-up time of the pigs varied from 1 to 14 weeks after the operation. The lengthening of the ovine radius succeeded in all cases. After the distraction procedure, the growth plate was radiologically open at 12 weeks postoperatively.

OTC fluorescence of the bone preparations showed that the consolidation of the separation area developed gradually from the inner layer of the periosteum and from the metaphysis as well as from the side of the growth plate. Figure 4 shows the growth of both the operated

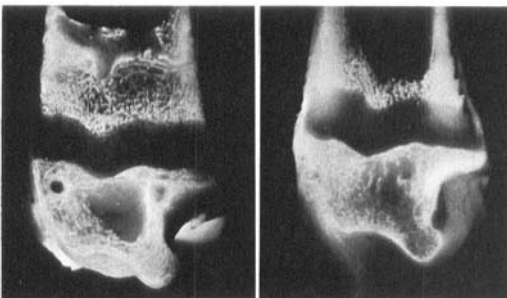


Figure 4. OTC fluorescence of the longitudinally sawn bone shows the distraction area filled with trabecular bone. The dark zone represents the epiphyseal growth of the distal radius after tetracycline injection 4 weeks before killing. The control ovine radius is on the right.

and non-operated radius after the distraction area had healed. The physeal growth is the same in both bones.

Complications

Growth disturbance occurred in three pigs. In one pig, a premature closure of the distal and proximal growth plate occurred 6 weeks after the operation. In one pig, fusion of the proximal growth plate was observed radiologically 6 weeks postoperatively. In one pig, the longitudinal growth of the distracted radius was retarded after the device was removed.

Three pigs died 1–3 days postoperatively, not directly as a result of the operation, before the separation occurred. In two of the pigs, there was mild infection in the diaphyseal pin tract and in the physeal area, and in one, severe arthritis of the carpus. Two diaphyseal fractures of the radius also occurred during the distraction procedure in the pigs. No complications were observed among the sheep.

Discussion

The principle of distraction of the growth plate using external fixation has proved to be suitable both clinically and in experimental studies of limb lengthening (Ilizarov & Soybelman 1969, Monticelli & Spinelli 1981a, b, Peltonen et al. 1982, Paatsama et al. 1983). The separation of the growth plate from the metaphysis by gradual distraction results in a Salter-Harris type 1 epiphysiylisis. The stability of the distraction frames used in the present study proved to be sufficient to permit the healing of the distracted area after the lengthening procedure.

In this study we found that the force needed for the separation was different when comparing gradual distraction to distraction epiphysiylisis during the primary operation. It is possible that the mechanism of separation is different in gradually applied distraction from that in a sudden breaking force which occurs in traumatic epiphysiylisis. It was also found that the separation occurred with a milder distractive force in young animals (sheep of 8–10 weeks of age).

Noble et al. (1982) have studied the differences in the breaking force of the growth plate *in vitro* and *in vivo*. Fishbane & Riley (1978) used continuous traction to achieve the separation. They observed a rapid separation and healing of the gap without complications.

The consolidation of the separation area developed gradually towards the centre of the separation line. Alho et al. (1982) have shown that the same kind of healing process develops endosteally in diaphyseal osteotomies that have been distracted using an external fixation device. Monticelli et al. (1981) found that the ossification starts 4 weeks after the operation. The results in our study are in agreement with these observations.

OTC fluorescence studies revealed that osteogenesis develops, forming trabecular bone to fill the distracted area. The ossification was well advanced at 8 weeks after the operation.

It is not known exactly how the distraction affects the growth plate of the operated bone. The differences that have been noted with regard to the possibility of premature closure after the distraction may be due to the use of different experimental animals and to the different rates of distraction that have been used (Ring 1958, Fishbane & Riley 1978, Letts & Meadows 1978, Monticelli & Spinelli 1981a). In our study there were more complications among the pigs. In pigs there was also a premature fusion of both the distal and proximal growth plates of the operated radius. The mechanism of this phenomenon is obscure. In most of the experiments the growth plate remained open and functionally intact after the distraction procedure.

From the clinical point of view, timing of the lengthening procedure is not unambiguous. The consequences of the premature closure are more injurious in the active growth period than near skeletal maturity. It also remains to be investigated whether distraction can be used in correcting angular deformities in the area of the growth plate.

References

- Alho, A., Bang, G., Karaharju, E. & Armond, I. (1982) Filling of a bone defect during experimental osteotaxis distraction. *Acta Orthop. Scand.* **53**, 29–34.
- Fishbane, B. M. & Riley, L. H. Jr. (1978) Continuous transphyseal traction: Experimental observations. *Clin. Orthop.* **136**, 120–124.
- Ilizarov, G. A. & Soybelman, L. M. (1969) Some clinical and experimental data concerning bloodless lengthening of lower extremities. *Eksp. Khir. Anesteziol.* **4**, 27–32.
- Letts, R. M. & Meadows, L. (1978) Epiphysiolysis as a method of limb lengthening. *Clin. Orthop.* **133**, 230–237.
- Milch, R. A., Rall, D. P. & Tobie, J. E. (1958) Fluorescence of tetracycline antibiotics in bone. *J. Bone Joint Surg.* **40-A**, 897–910.
- Monticelli, G. & Spinelli, R. (1981a) Distraction epiphysiolysis as a method of limb lengthening. Experimental study. *Clin. Orthop.* **154**, 254–261.
- Monticelli, G., Spinelli, R. & Bonucci, E. (1981) Distraction epiphysiolysis as a method of limb lengthening. Morphologic investigations. *Clin. Orthop.* **154**, 262–273.
- Monticelli, G. & Spinelli, R. (1981b) Distraction epiphysiolysis as a method of limb lengthening. Clinical applications. *Clin. Orthop.* **154**, 274–285.
- Noble, J., Diamond, R., Stirrat, C. R. & Sledge, C. B. (1982) Breaking force of the rabbit growth plate and its application to epiphyseal distraction. *Acta Orthop. Scand.* **54**, 13–16.
- Paatsama, S., Alitalo, I., Kärkkäinen, M. & Skutnabb, K. (1983) Die Distraction der Wachstumsfuge der Ulna zur Verhütung der Vorwärtsbeugung der Radius bei osteodystrophen Deutschen Doggen. *Kleintierpraxis* **28**, 207–212.
- Peltonen, J., Karaharju, E., Alitalo, I. & Heliö, H. (1982) Experimental epiphyseal distraction in sheep and pigs. 41st NOF congress, Stockholm, p. 1.
- Ring, P. A. (1958) Experimental bone lengthening by epiphyseal distraction. *Br. J. Surg.* **46**, 169–173.