

# Surgery of the brachial plexus

The principles and difficulties of surgery of brachial plexus lesions in 52 cases are reported. In 22 cases there was avulsion of one or more roots. Six lesions were infraclavicular. Reconstruction by means of autologous grafts was performed in 24 cases, neurolysis in 14 cases, direct suture in two cases, and intercostal neurotization in 12 avulsion cases. Fifty-one patients were evaluated on average 4 years after the operation. The result was good in 19 cases, fair in 13 cases and poor or nil in 19 cases. Regained function was best at the level of the elbow. Functional recovery of M. biceps after fascicular grafting was achieved in 16 cases. In neurotization cases, functional recovery was achieved in four cases.

**Kauko A. Solonen**  
**Martti Vastamäki**  
**Bengt Ström**

The Orthopaedic Hospital of  
the Invalid Foundation,  
Helsinki, Finland

Correspondence: Martti Vastamäki, M.D., Elotie IA2, SF-20780 Kaarina, Finland

Trauma to the brachial plexus commonly results in a disabling condition. It is caused by many types of injuries. By far the commonest of these are traction injuries, which comprise about 80 per cent of the cases (Narakas 1978). They may belong to all groups of the Sunderland (1951) or Seddon (1975) classification and extend along one or more of the neural components of the plexus.

In the last 20 years, certain technical advantages have accrued from microsurgical techniques connected with safe, long-duration anaesthesia and the methods used in fascicular free nerve grafting.

Many authors have reported acceptable results of plexus surgery (Millesi 1977, Dolnitsky 1980, Gilbert et al. 1980, Jamieson & Hughes 1980, Lejeune et al. 1980, Solonen et al. 1980, Narakas 1980 and 1981, Alnot et al. 1981). However, Rorabeck & Harris (1981) have reported that operation does not affect the prognosis of brachial plexus injury.

## Patients and methods

From 1970 to 1981, 52 patients with different types of brachial plexus lesions were operated on at the Orthopaedic Hospital of the Invalid Foundation, Helsinki. Only one patient was unavailable for follow-up control. The average follow-up time was 4 years.

There were 42 male and 10 female patients (mean age 23 years). Two patients were over 50 years of age

and three were infants. There were 33 traffic accidents, eight sharp lesions, three gun shot injuries, three obstetric lesions, three falls and two compression injuries. Seven patients had a rupture of the subclavian or axillary artery and nine had a clavicular fracture. The right upper limb was injured in 26 cases, the left in 26 cases. In all cases, primary treatment had taken place at another hospital.

At the first admission complete neurological examination was carried out. The muscles were tested, and a grading using the 0-5 formula was made. ENMG was carried out in all cases. Sensory nerve action potentials were looked for. A histamine response test was performed, and sudomotor activity was discovered by means of the Ninhydrin test. The sensory function was documented by mapping the areas of absent or deficient sensitivity to touch or pain, and if necessary, by a two point discrimination in the hand. The neck, shoulder region and thorax were x-rayed and myelography was carried out in patients who were suspected of having root avulsions.

A coherent logical picture of all the objective findings was constructed. The injury was most often supraclavicular, being at the preforaminal level in six, at root level in 31, and at cord level in nine, as well as being infraclavicular in six cases.

The preoperative distribution and extension of paralysis are shown in Table 1. Preforaminal avulsions were diagnosed in 22 patients. Avulsion of all five roots was seen in five cases and avulsion of four roots in four cases. The operative delay varied from 1 week to 48 months (mean 8 months).

In all cases the operation was carried out under general anaesthesia but without relaxation. A supine position with a small bag under the neck was

Table 1. Preoperative distribution and extension of paralysis

	Complete	Partial
C5 – C6	15	4
C5 – C6 – C7	7	1
C7 – C8 – T1	1	
C8 – T1	1	
C5 – T1	22	1

Complete: Complete palsy at least at one level (shoulder, elbow, wrist, hand).

Partial: Muscle action at least M1 – muscle contraction without effect – at all levels.

Table 2. Types of operation performed

Procedure	No. of patients
External neurolysis	10
Fascicular neurolysis	4*
Direct suture	2
Fascicular grafting	24**
Intercostal neurotization	12***
	52

\* In two cases direct suture of some fascicles was performed.

\*\* In four intercostal neurotization cases fascicular grafting of some parts of the plexus was performed.

\*\*\* In seven neurotizations intermediate grafts were used.

Table 3. Level of reconstruction

Level	No. of cases
Roots	
C 5	6
C 6	1
C 5–6	11
C 5–7	4
Cords	4
Distal plexus	2
	28

adopted. An operating microscope was invariably used and the atraumatic technique was a guiding principle. Meticulous haemostasis was done by bipolar microcoagulation. Electrical stimulation was applied. The operative findings were documented on a chart during the operation.

The operative procedure adopted for our patients was external and sometimes fascicular neurolysis, direct suture, interfascicular grafting, or neurotiza-

tion by transposition of intercostal nerves. In many cases a combination of these procedures was used. External neurolysis was the sole procedure in 10 cases only, where there was pain and a decrease in muscular power caused by scar entrapment, e.g. after a fracture of the clavicle (Table 2). Osteotomy of the clavicle was carried out in 15 cases and the osteosynthesis was performed at the end of the operation with an AO-compression plate that had been adjusted, temporarily fixed and removed before the osteotomy.

We attempted to reach the damaged region of the trunk or cord, beginning the preparation from the undamaged part. The fascicular topography of each plexus is individual, and we tried to identify the fasciculi according to both the local anatomy and earlier clinical findings. In many cases we were not able to clarify the continuity of the fascicular pattern, despite stimulation and high magnification. An evaluation of the condition of the proximal end was often quite difficult.

Fascicular grafting was performed in 28 cases. Reconstruction took place in most cases at the level of roots 5–6 (Table 3). In most cases the grafts were harvested from the sural nerve. The grafts were fixed between the receiving fascicle ends with 8/0–11/0 nylon sutures.

Neurotization with intercostal nerves was carried out in 12 cases. Intercostal nerves 2–7 were used. In seven cases, lengthening in order to obtain a quite loose, new nervous pathway that would not rupture when the patient was coughing or vomiting, was achieved with free grafts. The connexion was made in three cases with the distal ends of the trunks or cords and in nine cases with the individual nerves, musculocutaneous, median, axillary and suprascapular. Neurotization was carried out only when avulsion of the corresponding roots was proved.

After the operation, the upper limb was immobilized in a Velpeau dressing for 3–4 weeks. Passive maximal shoulder movements were avoided for a few more weeks, but controlled physiotherapy was continued for 6 months or more. For the purpose of this report, the patients were examined by the authors.

## Results

Good results included cases where a useful function, i.e. power M4, was achieved at least at one of the functional levels (shoulder, elbow, wrist, hand). The result was classified as fair if active motion against gravity was achieved to reach positions of functional value, i.e. with power M3. The result was considered poor if

Table 4. Results of operative treatment

	Good	Fair	Poor or nil
Supraclavicular			
Neurolyses	5	3	3
Grafts or sutures	9	8	5
Intercostal neurotizations	3		9
Infraclavicular			
Neurolyses	2	1	
Grafts and sutures		1	2
Total	19	13	19

the patient could sustain no active movement against gravity. In many cases the result was nil (Table 4). We never achieved an unquestionable function of the intrinsic muscles of the hand after reconstruction of traction injuries in supraclavicular lesions, although we did so in one infraclavicular case. The sensibility of the hand, if completely lost was never regained.

In one fourth of the patients with paralytic biceps, muscle M4 power was achieved (Figure 1, Table 5). This was classified as a good result.

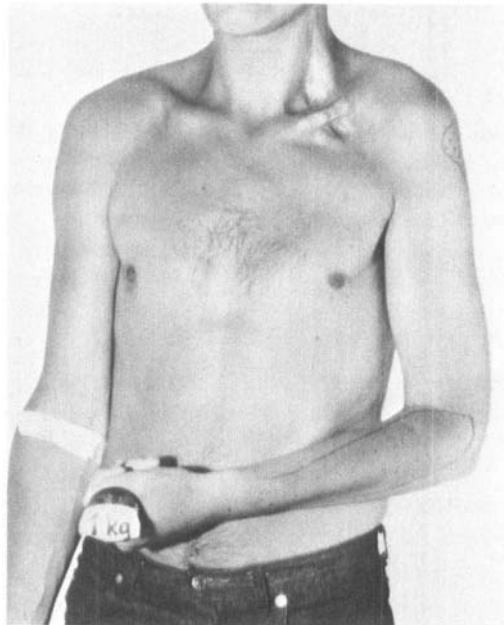


Figure 1. A 19-year-old man sustained a rupture of the fifth, sixth and seventh cervical roots in a traffic accident. Fascicular grafting of these roots was performed 3 months later. After 2 years the patient was able to lift a weight of 1 kg with the wrist flexors and biceps muscle.

Table 5. Function after fascicular grafting

	Level			
	Shoulder	Elbow	Wrist	Hand
Good (M4–M5)	0	6	1	0
Fair (M3)	3	10	3	2
Poor (M1–M2)	8	2	1	2
Nil (M0)	13	8	3	1

Function (flexion, extension, abduction or rotation) was M0 at time of the operation.

Table 6. Regained increase of function in 14 neurolysis cases (M0 → M5)

Steps	Shoulder	Elbow	Wrist	Hand
4	2	4	0	0
3	3	0	1	1
2	1	1	1	1
1	2*	1+2*	2*	2*
0	3**	1+2**	2**	2**

\* From M4 to M5.

\*\* M0 or M1.

Table 7. Function after intercostal neurotization

	Level			
	Shoulder	Elbow	Wrist	Hand
Good (M4–M5)	0	3	0	0
Fair (M3)	1	0	0	0
Poor (M1–M2)	2	2	1	0
Nil (M0)	5	4	1	1

The recovery of a paralytic shoulder was unsatisfactory on the whole. In two patients direct suturation was carried out because of iatrogenic discission of the cranial trunk (C5–C6) 1 and 12 weeks earlier, respectively. In both cases good power was achieved in the deltoid and spinatus muscles. After reconstruction of the corresponding parts of the plexus, not more than grade M3 was achieved in three cases. This, however, was enough to prevent the subluxation of the glenohumeral joint.

In those patients with traction injury where serviceable results were achieved, the operative delay was on average 4 months less than in those patients without benefit of treatment. In the 14 cases of neurolyses, a good or fair result was achieved in 11 cases (Table 6). The poor results were probably caused by an er-

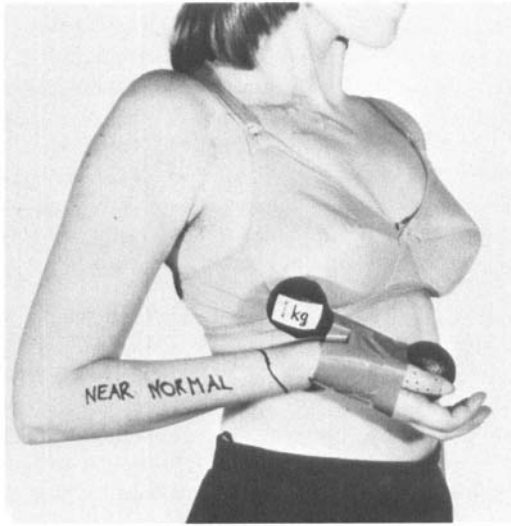


Figure 2. A 19-year-old woman sustained a rupture of the fifth and an avulsion of the other cervical roots in a traffic accident. Reconstruction of the fifth root and inter-costal neurotization of the musculocutaneous nerve was performed. After 2 years the patient was able to lift a weight of 1 kg with the biceps muscle and there was sense of identification in the hand.

roneous intraoperative evaluation of the extent of the destruction.

Our series includes three infants with brachial birth palsy. They were operated on at the ages of 2–3 months. The results on these patients were quite useful (Solonen et al. 1981).

In the group of neurotization patients, only one fourth gave a good or useful result (Figure 2, Table 7). Only in those cases where neurotization was accomplished for individual peripheral nerves did we get useful results.

## Discussion

Despite the fact that the brachial plexus contains 100 000 to 160 000 axons (Bonnell 1977), only a few hundred seem to be needed to reinnervate efficiently a poorly differentiated muscle like a biceps humeri. Thousands of nerve fibres are needed to restore the function of the intrinsic muscles of the hand or to give the hand a tactile gnosis. The number of axons growing down along the brachial plexus and its peripheral continuation diminishes; the end organs undergo degeneration, and the dener-

vated muscles degenerate irreversibly in about 2 years. Consequently, after a severe plexus lesion the hand can never regain its intricate motor or sensory function.

The nerve cells that regenerate and build up the new axons are known to have a vigorous regenerative power. However, both Narakas and Wynn-Parry (Narakas 1978) have established that  $\frac{1}{4}$  or  $\frac{1}{3}$  of patients with a severe traction injury of the brachial plexus do not spontaneously recover at all or recover only one basic function, such as elbow-function.

It is often impossible to evaluate exactly the extent of the damage and a successful direct suture is rarely possible. Due to fascicular devascularization, neurolysis may do more harm than good. After a traction trauma to the plexus the decision as to where to limit the revision of a traumatized part of the plexus for anastomosing with free grafts or for neurotization is often pure guesswork.

We discovered that the results were worse than we had anticipated, although in certain cases they may still improve somewhat over the next few years. At the beginning of our series, we certainly attempted to do too much and due to lack of experience were not able to evaluate the operative findings and possibilities correctly. We probably sometimes made an attempt at reconstruction in cases of 2-level injuries at one level only. In some cases there may also have been undetected avulsions with roots still lying in their foramina. Root avulsion must be suspected when there has been severe pain soon after the accident, if there is paralysis of the rhomboids, levator scapulae and serratus anterior muscles and if there is Horner's syndrome. We did not have the necessary equipment for recording somatosensory evoked potentials intraoperatively (Landi et al. 1980).

Surgery, even microsurgery, has limited possibilities in the treatment of brachial plexus injuries. One must be fully aware that delay can have deleterious effects, especially if the damaged pathways lead to distal parts of the extremity. After about 9 months there is seldom any justification for operating on a plexus patient.

Many authors share the opinion that the best time to operate is as early as possible after

the indications have been confirmed, i.e. 2 weeks to 2 months after the trauma, when it has been discovered that a lesion has occurred, that spontaneous recovery is impossible and that the patient is a suitable object for major surgery (Narakas 1978, Alnot et al. 1981).

Reconstructive surgery of the brachial plexus is difficult. Opinions on the operative indications as well as on the prognosis of the plexus injuries are still quite controversial and confusing. In severe cases one can never achieve excellent results with the present surgical techniques.

Early surgery certainly is important, but how early is still open to question. An exact preoperative diagnosis should always be obtained. The surgical team should be well trained and capable of exact preoperative and intraoperative evaluation of the observations. Microsurgical techniques can give useful results, especially in lesions affecting the pathways from the upper three roots. It seems to us that before we can achieve a really satisfactory improvement in our results we must discover a way or find a factor to direct and hasten the regeneration of a damaged nerve cell soon after the injury has occurred.

## References

- Alnot, J. Y., Jolly, A. & Frot, B. (1981) Traitement direct des lésions nerveuses dans les paralysies traumatiques du plexus brachial chez l'adulte. *Intern. Orthop.* **5**, 151–168.
- Bonnell, F. (1977) Configuration interne histophysiologique du plexus brachial. *Rev. Chir. Orthop.* **63**, 35–38.
- Dolnitsky, O. V. (1980) Microsurgical operations on the brachial plexus in children. *Klin. Khir.* **6**, 22–25.
- Gilbert, A., Khouri, N. & Carlioz, H. (1980) Exploration chirurgicale du plexus brachial dans la paralysie obstétricale. *Rev. Chir. Orthop.* **66**, 33–42.
- Jamieson, A. & Hughes, S. (1980) The role of surgery in the management of closed injuries to the brachial plexus. *Clin. Orthop.* **147**, 210–215.
- Landi, A., Copeland, S., Wynn-Parry, C. & Jones, S. (1980) The role of somatosensory evoked potentials and nerve conduction studies in the surgical management of brachial plexus injuries. *J. Bone Joint Surg.* **62-B**, 492–496.
- Lejeune, G., Carlier, A., Leclercq, D. & Khuc, T. (1980) Concepts récents sur le traitement des lésions du plexus brachial. *Rev. Med. Liège* **35**, 327–343.
- Millesi, H. (1977) Surgical management of brachial plexus injuries. *J. Hand Surg.* **5**, 367–379.
- Narakas, A. (1978) Surgical treatment of traction injuries of the brachial plexus. *Clin. Orthop.* **133**, 71–90.
- Narakas, A. (1980) The surgical treatment of traumatic brachial plexus lesions. *Intern. Surg.* **65**, 521–527.
- Narakas, A. (1981) Brachial plexus surgery. *Orthop. Clin. North Am.* **12**, 303–323.
- Rorabeck, O. & Harris, W. (1981) Factors affecting the prognosis of brachial plexus injuries. *J. Bone Joint Surg.* **63-B**, 404–407.
- Seddon, H. (1975) *Surgical disorders of the peripheral nerves*, 2nd edn. Churchill Livingstone, Edinburgh, London and New York.
- Solonen, K. A., Ryöppy, S. & Telaranta, T. (1980) Early reconstruction of the brachial plexus after birth injuries. *Acta Orthop. Scand.* **51**, 365.
- Solonen, K. A., Telaranta, T. & Ryöppy, S. (1981) Early reconstruction of birth injuries of the brachial plexus. *J. Pediatr. Orthop.* **1**, 367–370.
- Sunderland, S. (1951) A classification of peripheral nerve injuries producing loss of function. *Brain* **74**, 491–516.