

Stress fracture of the mid-tibial shaft

In a series of 151 tibial stress fractures in athletes and joggers, seven were located at the mid-third of the diaphysis. The diagnosis was made radiographically several months after the onset of symptoms; a transverse fissure line or gap was noted in the middle of the hypertrophied anterior tibial cortex. Histologic examination of a biopsy of the fracture line showed features resembling pseudoarthrosis. All the patients returned to physical activities.

Key words: athletic injury; fracture; overuse injury; pseudoarthrosis; stress fracture.

Most stress fractures of the tibia are located medioposteriorly at the upper or lower third of the tibia (Devas 1975, Meurman 1981). There have been few reports of stress fractures located at the anterior mid-shaft (Burrows 1956, Morris & Blickenstaff 1967, Devas 1975, 1980, Orava et al. 1978, Villiger & Uehlinger 1978, Williams 1980). The defective adaptation caused by hard and long-lasting physical activity is said to cause "fatigue infarction" of the anterior middle cortex (Burrows 1956, Uehlinger 1969). A series of these uncommon stress fractures is presented here.

Patients

Seven patients with stress fracture located at the anterior cortex of the mid-tibia were seen and treated during a 7-year period. They comprised 2.4 per cent of all stress fractures and 4.6 per cent of the 151 stress fractures of the tibia seen in athletes and joggers during the same time. No soldiers were included in the series.

The mean age of the patients was 31 (24-39) years, and all but one were men (Table 1). All the patients trained regularly. No sudden changes had occurred in their training programs and none had had direct trauma.

The diagnosis of the patients treated conservatively was made 2-3 months from the onset of symptoms. In other patients, on average 7 (2-12) months passed before the diagnosis was made.

S. Orava & A. Hulkko

Department of Surgery, Keski-Pohjanmaa Central Hospital, Kokkola, Finland

The main symptom was a diffuse dull pain in the leg, intensified by physical activity. Patients had no symptoms during daily life. The thickened anterior tibia was tender on palpation, especially after exercise.

Radiographically, a small fissure line developed transversely at the mid-tibia (Figure 1). Tomography showed the fissure to extend half-way through the cortex. In two cases the diagnosis was made by tomography when conventional radiographs showed only thickened cortex. Bone scan (Technetium^{99m}) performed in three cases at about 8 months from the onset of the symptoms clearly showed locally increased uptake at the area of the fissure line.

In five cases a biopsy of the fissure line was obtained and transversal drilling with a 2.5 mm drill of the hypertrophied anterior cortex was performed. In one case a complete fracture occurred through the site of the biopsy; it was treated by bone grafting and plaster immobilization and healed uneventfully. Two of the fractures were treated by rest from physical activity for at least 3 months; in others, the initial as well as the consecutive training pauses were only 1-2 months. After treatment, all patients returned to athletic activities.

The histological examination showed fibrotic tissue, sclerotic cortical bone and new bone formation with osteoblastic activity. The changes resembled pseudoarthrosis.

Discussion

The diagnosis of mid-tibial stress fracture is based on the clinical symptoms and radio-

Table 1. Details of the patients with stress fracture of the anterior mid-tibia

Case	Age	Sex	Sport	Months between onset of symptoms and diagnosis	Type and months of treatment
1	38	m	Jogging	12	Biopsy and bone grafting 12
2	31	m	Middle distance running	2	Conservative
3	30	m	Soccer, Jogging	7	Biopsy and drilling 9
4	26	f	Sprinting	2	Biopsy and drilling 7
5	31	m	Pole vault	3	Conservative
6	30	m	Pole vault	2	Biopsy and drilling 14
7	39	m	Jogging, volley ball	10	Biopsy and drilling 11

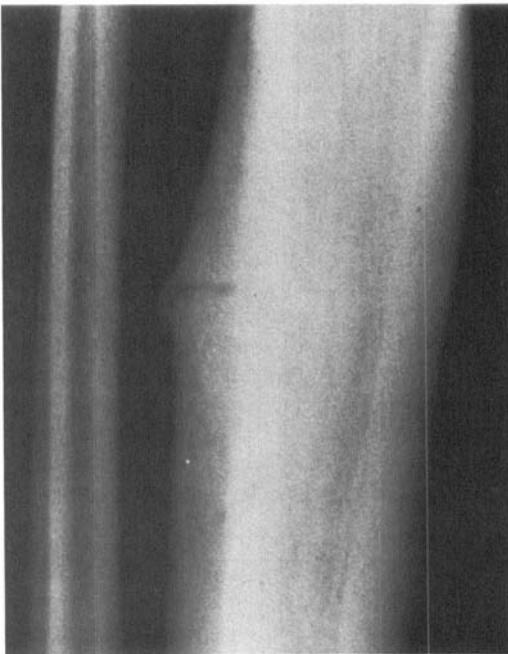


Figure 1. A-P radiograph of the mid-tibia showing a transverse stress fracture.

graphic thickening of the anterior cortex of the tibia with a fissure. In athletes as well as in recruits, thickening of the cortex may occur without any fissure and adaptative periosteal irregularities are common (Kuusela 1980, Williams 1980, Miranova et al. 1982). The

thickening of the anterior tibial cortex may be painful during exercise, and the differential diagnosis to a stress fracture is not possible until a fissure is seen in conventional radiographs or in tomograms. The fissure develops slowly, periosteal reaction is usually minimal, and a bone scan clearly shows an increased local uptake of the tracer at the fissure site (Wilcox et al. 1977, Kuusela 1980). The spindle-like cortical thickening narrows the medullary canal of the tibia.

The delay in diagnosis is caused by the symptoms resembling other more common overuse injuries of the leg. In the surgically treated cases the right diagnosis was made from 2 to 12 months from the onset of the symptoms. The initial rest from physical activity had been too short. The new rest periods were also too short. The patients who were treated conservatively were told to avoid running and jumping for 3 months and start gradually increasing training after that. After drilling and biopsy, the patients had a rest from athletic activities for 4–5 months.

Transverse stress fractures of the mid-tibia can be divided into three groups. In adolescent athletes, overuse or recurrent small injuries may cause anterior tibial crest stress injury (Uehlinger 1969, Zweymüller & Frank 1974, Villiger & Uehlinger 1978). In adult athletes, the anterior cortex is slowly hypertrophied and a fissure develops in it (Burrows 1956, Orava

et al. 1978). In soldiers, this stress fracture appears sooner, callus is seen at both sides of the bone and there is a risk of a complete fracture (Wilcox et al. 1977, Meurman 1981). By comparison, the patients of the present series were older. These chronic stress fractures can be called a "pseudoarthrosis" of the mid-tibia.

In the differential diagnosis osteoid osteoma, periosteal sarcoma, chronic osteomyelitis, monostotic fibrous dysplasia, severe osteoporosis and osteomalacia, Paget's disease and bone metastases must be considered (Uehlinger 1969, Zimmer 1982). Therefore, biopsy is recommended during surgery.

References

- Burrows, H. J. (1956) Fatigue infarction of the middle of the tibia in ballet dancers. *J. Bone Joint Surg.* **38-B**, 83-94.
- Devas, M. (1975) *Stress fractures*. Churchill Livingstone Ltd., Edinburgh.
- Devas, M. (1980) Stress fractures in athletes. *Medisport* **2**, 262-268.
- Kuusela, T. (1980) Stress fractures. A radionuclide, roentgenological and clinical study of Finnish conscripts. Thesis, *Ann. Med. Milit. Fenn.* **55**, suppl. 2a.
- Meurman, K. O. A. (1981) Stress fractures in soldiers. An analysis of 986 consecutive cases. Thesis. *Acta Univ. Ouluensis Med.* **78**.
- Mironova, Z. S., Merculova, R. J. & Pavlova, M. N. (1982) Chronic microtrauma of the locomotor apparatus of the lower extremities. XXIInd World Congress on Sports Medicine, Vienna, Austria.
- Morris, J. M. & Blickenstaff, L. D. (1967) *Fatigue fractures. A clinical study*. Charles C. Thomas, Springfield, Illinois.
- Orava, S., Puranen, J. & Ala-Ketola, L. (1978) Stress fractures caused by physical exercise. *Acta Orthop. Scand.* **49**, 19-27.
- Uehlinger, E. (1969) Die Überlastungsschäden des Skelettes in anatomischer Sicht. *Verhandl. Dtsch. Gesells. Orthop. Traum.* **3**, 290-301.
- Villiger, J. J. & Uehlinger, E. (1978) Posttraumatische dissezierende Riesenzell dystrophie der rechten Tibia. *Arch. Orthop. Traum. Surg.* **91**, 157-159.
- Wilcox, J. R., Moniot, A. L. & Green, J. P. (1977) Bone scanning in the evaluation of exercise-related stress injuries. *Radiology* **123**, 699-703.
- Williams, J. G. P. (1980) *A colour atlas of injury in sport*. Wolfe Medical Publ. Ltd., London.
- Zimmer, E. A. (1982) *Grenzen des normalen und Anfänge des Pathologischen im Röntgenbild des Skelettes*. 12th ed. G. Thieme, Stuttgart-New York.
- Zweymüller, K. & Frank, W. (1974) Ermüdungsbrüche der Tibia im Kindesalter. *Z. Orthop.* **112**, 450-460.