

Spontaneous bilateral distal femoral physiolysis due to scurvy

A bilateral distal femoral epiphysiolysis was observed in a 28-month-old child suffering from scurvy. We explain the mechanisms of the separation of the epiphysis due to loss of strength in the calcification zone of the cartilage columns.

Key words: epiphysis, slipped; femur; physiolysis; scurvy.

**Jacobo Nerubay &
David Pilderwasser¹**

Department of Orthopaedic Surgery, The Chaim Sheba Medical Center and The Sackler School of Medicine, Tel Hashomer 52621, Israel and ¹Department of Orthopaedics, Hillel Yaffe Hospital, Hadera, Israel

Scurvy is currently a very rare disease in the West. The radiographic characteristics have been fully reported and separations of the physes are known to occur (Banks 1943). The diagnosis is based on the radiographic changes that occur in the distal ends of long bones, specifically in the knee region.

An interesting case of bilateral physiolysis of the distal end of the femur is presented.

Case report

A 28-month-old boy was admitted to the paediatric department with a 2-month history of loss of appetite and weight. On examination he was found to be dehydrated, with bleeding gums, rosary at the costochondral junction, and swollen knees with a flexion contracture of 30°.

The radiographic examination showed a bilateral distal physiolysis of the femur with signs of ossifying subperiosteal hematoma (Figure 1) and the chest film showed the ossifications in the costochondral junction (Figure 2). A diagnosis of scurvy was made and the child was treated with parenteral fluids and 200 mg of vitamin C daily, supplemented with oral intake of orange juice. The child recovered slowly and 3 weeks later, under general anaesthesia, a closed reduction of the epiphysis failed and an open reduction was performed. Ten months later the knees have a full range of movement and no visible deformity (Figures 3-4).

Discussion

Epiphyseal separation is known to occur in scurvy but very few reports have appeared in the literature. Silverman (1963) reported a case of distal femoral physiolysis in 1953, with a gross deformity of the epiphyseal ossification centre, and 17 years later he reported (Silverman 1970) the same case, showing an extraordinary recovery of the epiphyseal lesion. Silverman concluded that permanent deformities resulting from scurvy are extremely rare. In 1959, Warkany reported a slipped epiphysis of the proximal humeral head, and we report here a bilateral distal femoral physiolysis which seems to be extremely rare.

Vitamin C is essential for the integrity of the intercellular substance, specifically for collagen formation and matrix elaboration in both cartilage and bone. Deficiency of vitamin C results in a failure of formation of the osteoid matrix and not in the mineralization of calcification, causing disruption in endochondral bone formation. In the physis the palisade of cartilage cells is formed as usual, but the osteoblasts are incapable of forming bone matrix, resorption of the cartilagenous matrix slows, and consequently there is persistence of the cartilage which becomes patchily or completely calcified. Fibroblasts proliferate in the scorbutic zone and form a loose, disorganized

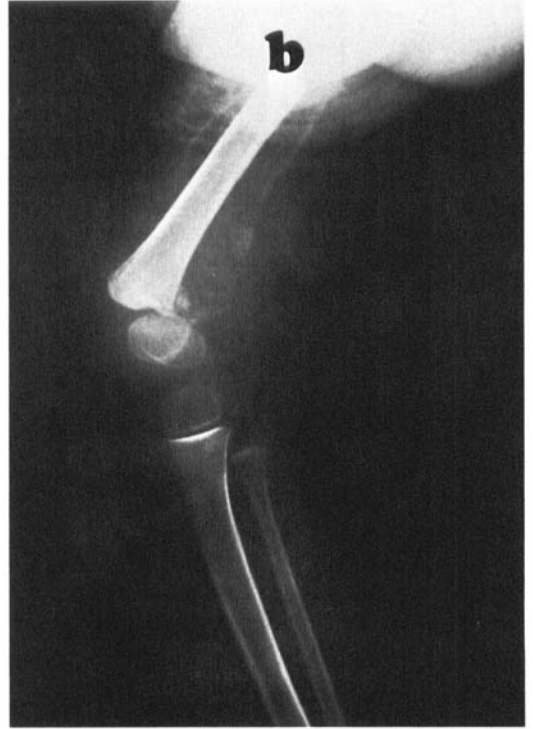
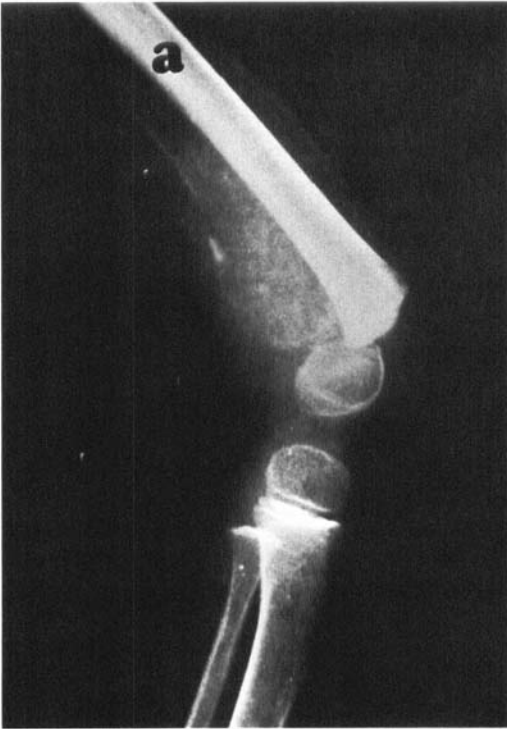
Figure 1. Roentgenographs showing the displaced distal femoral epiphysis with a typical ossifying subperiosteal hematoma.

a. Right knee;
b. Left knee.

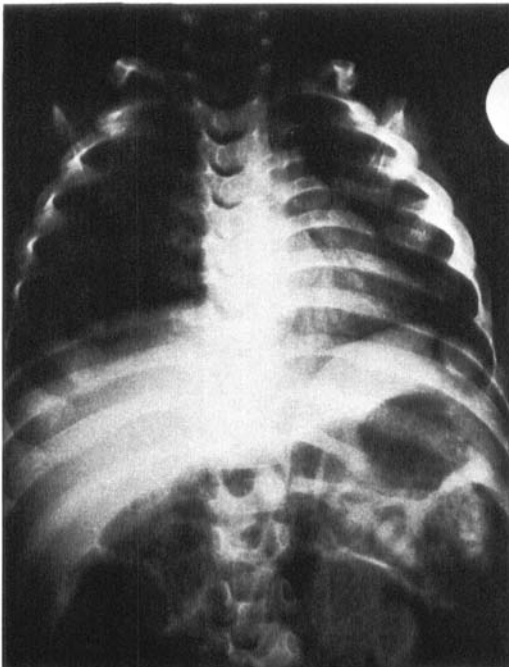


Figure 2. Classical ossification in the costochondral junction on the chest X-ray.

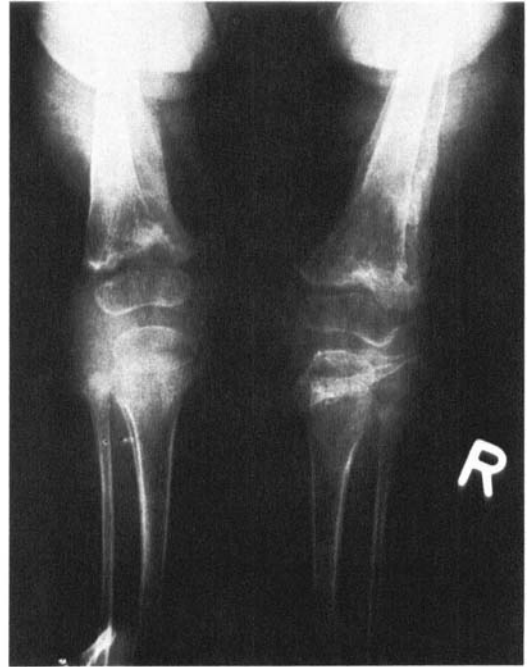

Figure 3. Antero-posterior film showing the epiphysis in good alignment.

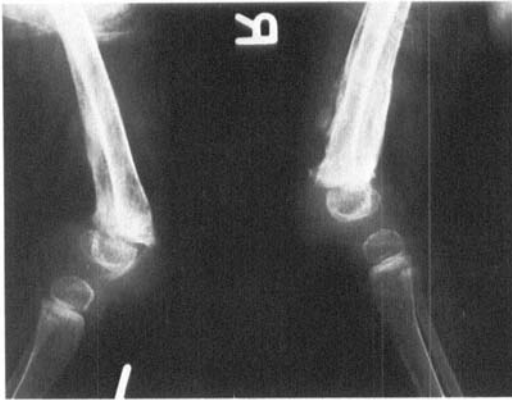

Figure 4. Lateral view of both knees showing good position of the epiphysis and sclerosis of adjacent metaphyseal bone.

connective tissue; because no collagen is formed, the structural strength is decreased and the stress of weight-bearing or muscular tension may produce physiolysis. Stability depends upon the calcified cartilagenous matrix which is not an adequate substitute for normal bone. The poorly formed capillaries rupture

easily due to deficiencies in the cement substance, and the loosely attached periosteum predisposes to extensive subperiosteal haematomas.

This case report has been presented to highlight a historical disease in which community health education plays an important preventative role and where specific therapy is dramatic in cases of failure to thrive.

References

- Banks, S. W. (1943) Bone changes in acute and chronic scurvy. *J. Bone Joint Surg.* **35**, 553–565.
- Silverman, F. N. (1963) An unusual osseous sequel to infantile scurvy. *J. Bone Joint Surg.* **35-A**, 215–230.
- Silverman, F. N. (1970) Recovery from epiphyseal invagination: sequel to an unusual complication of scurvy. *J. Bone Joint Surg.* **52-A**, 384–390.
- Warkany, J. (1959) Scurvy. In: (Ed. W. E. Nelson) *Textbook of Pediatrics*, 7th edn. pp. 368–377. W. B. Saunders Company, Philadelphia.