

# A case of scapho-capitate fracture

A case of scapho-capitate fracture syndrome is reported. The capitate had the characteristic "cut-off-top-of-an-egg" radiographic appearance. We performed open reduction and pin fixation of the two fractures with an excellent result.

Correspondence: Department of Plastic Surgery, Odense Sygehus, DK-5000 Odense C, Denmark.

**Tune Ipsen**  
**Claus Falck Larsen**

Department of Orthopaedic Surgery, Odense University Hospital, Odense, Denmark

## Case report

Nicholson (1940) described a case of concurrent fracture of the scaphoid and capitate with 180 degrees rotation of the proximal capitate fragment. Sixteen cases have been described since then (Adler & Shaftan 1962, Stein & Siegel 1969, Meyers et al. 1971, Monahan & Galasko 1972, Newman & Watt 1980, El-Khoury et al. 1982).

A 16-year-old male fell 6 meters from a roof. He sustained hyperextension injuries to both wrists, with marked pain and tenderness, and limited motion. Radiograms revealed fracture of the scaphoid bilaterally, associated with capitate fracture on the left side (Figure 1). Initially, closed reduction of the capitate fracture by traction through the third finger was attempted without success. An open reduction

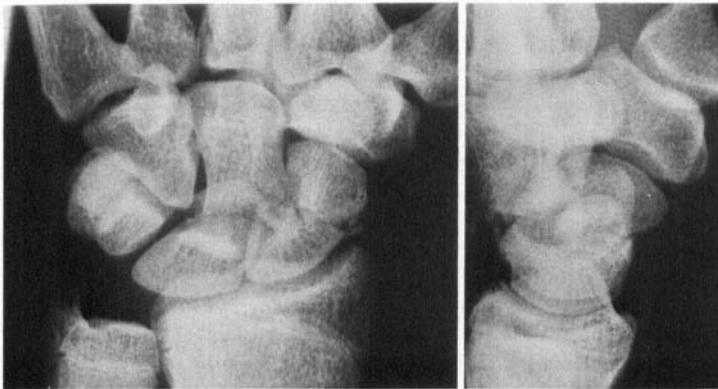


Figure 1. The left hand immediately after injury. The scaphoid and the capitate fractures are seen in both projections. In the lateral projection, the capitate has the characteristic "cut-off-top-of-an-egg".

Figure 3. The K-wires have been removed and the fractures are seen in good position 8 weeks postoperatively.

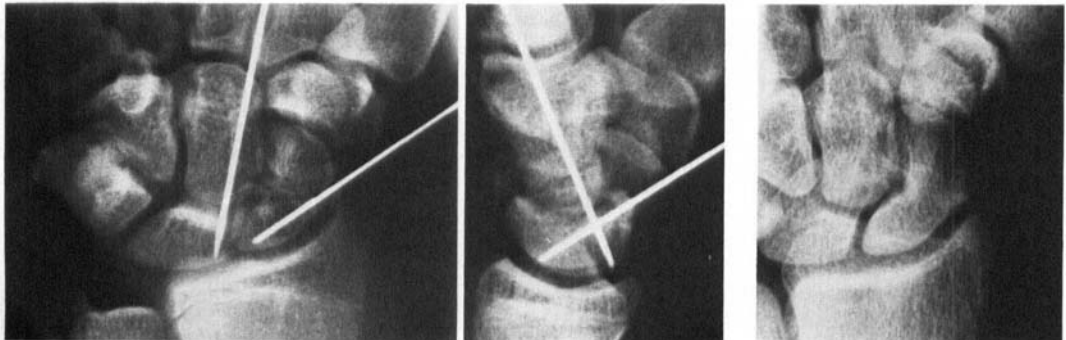


Figure 2. Scaphoid and capitate fractures stabilized by K-wires

was then performed under general anaesthesia. The proximal fragment of the capitate was easily brought into position through a dorsal transversal incision. Both fractures were stabilized by pin fixation (Figure 2). A long plaster cast was applied with the wrist in slight volar flexion and ulnar deviation. The fracture of the right scaphoid was treated closed.

Eight weeks later, radiograms revealed union of all fractures (Figure 3). The pins were removed and the left wrist was immobilized with a short plaster splint for another 4 weeks. At this time the patient had no symptoms in his wrists. Wrist movements were recorded in degrees (right/left) as follows: extension 80/70, flexion 50/60, radial deviation 10/10, ulnar deviation 30/30. Grip strength was 0.9 kp/cm<sup>2</sup> on both sides. One year later the patient was completely asymptomatic, at work, and radiograms showed united fractures without degenerative changes or necrosis.

## Discussion

It is believed that the scapho-capitate fracture follows acute high-energy hyperextension trauma and longitudinal compression of the wrist (Stein & Siegel 1969, Monahan & Galasko 1972). Ulnar deviation as well as radial deviation during hyperextension may contribute to the injury.

Adler & Shaftan (1962) reviewing the literature found 11 cases of scapho-capitate fracture. They believe that it is underdiagnosed by orthopaedic surgeons as well as by radiologists. Some cases may be found only because the patients complain of pain after treatment of scaphoid fractures. The blood supply to the prox-

imal part of the capitate radiates from the middle third of the bone without any collateral supply (Barber 1972). Untreated 180 degree dislocation therefore frequently causes joint incongruity and necrosis with long-standing discomfort and pain.

Open treatment has become increasingly common since 1971 (Meyers et al. 1971, Monahan & Galasko 1972, El-Khoury et al. 1982). Although the small numbers reported do not show any significant trend, our case supports primary open reduction and stabilization with K-wires under the control of an image intensifier.

## References

- Adler, J. B. & Shaftan, G. W. (1962) Fractures of the capitate. *J. Bone Joint Surg.* **44-A**, 1537-1547.
- Barber, H. (1972) The intraosseous and arterial anatomy of the adult human carpus. *Orthop. Oxford* **3**, 1-20.
- El-Khoury, G. Y., Usta, H. Y. & Blair, W. F. (1982) Naviculocapitate fracture-dislocation. *AJR* **139**, 385-386.
- Meyers, M. H., Wells, R. & Harvey, J. P. (1971) Naviculo-capitate fracture syndrome. *J. Bone Joint Surg.* **53-A**, 1383-1385.
- Monahan, P. R. W. & Galasko, C. S. B. (1972) The scapho-capitate fracture syndrome. *J. Bone Joint Surg.* **54-B**, 122-124.
- Newman, J. H. & Watt, I. (1980) Avascular necrosis of the capitate and dorsal dorsi-flexion instability. *The hand* **12**, 176-178.
- Nicholson, C. B. (1940) Fracture dislocation of the os magnum. *J. Roy. Nav. Med. Serv.* **26**, 289-291.
- Stein, F. & Siegel, M. W. (1969) Naviculocapitate fracture syndrome. *J. Bone Joint Surg.* **51-A**, 391-395.