Acta Orthop Scand *56*, 506–508, 1985

Dental bacteremia – a neglected cause of arthroplasty infections?

Three hip cases

We report on three patients with late hip replacement infection. The micro-organism was microaerophilic *Streptococcus viridans*, an oral organism, in all patients. Dental procedures had preceded the onset of the hip infection in all cases, and severe periodontal disease was observed on subsequent admissions.

Christian Lindqvist
Pär Slätis[1]

Department of Maxillofacial Surgery, and [1]Division of Orthopaedic Surgery and Traumatology,
University Central Hospital,
Kasarmikatu 11–13,
SF-00130 Helsinki, Finland

Since the origin of bacterial spread cannot be established in 20–40 per cent of patients with joint replacement infections of hematogenous origin, it has recently been suggested that many of these infections are of dental origin (Little 1983).

This report was prompted by three cases of late total hip replacement infections; in each case dental treatment preceded the joint infection.

Case reports

Case 1

In July 1981, a 67-year-old man had a total hip replacement for arthrosis. Prophylactic antibiotics including erythromycin were administered for 1 day pre-, and 3 days postoperatively. The postoperative course was uneventful and the hip became pain-free. In January 1984 the patient experienced pain in the hip, ESR rose to 130 mm/h and the radiographs suggested infection. At rereplacement in March 1984 purulent exudate was found around the prosthesis; culture revealed micro-aerophilic streptococcus (*Streptococcus viridans*).

The patient reported that during autumn 1983 he had had several dental appointments with extraction of teeth, calculus removal and curettage. No prophylactic antibiotics had been administered. The orthopantomogram showed recent tooth extractions and severe periodontal disease (Figure 1). All his teeth were extracted in April 1984.

After rereplacement with antibiotic cement, the ESR remained high. Radiography of the hip showed signs of progressive loosening and the implants were extracted in November 1984. Again a micro-aerophilic streptococcus was cultivated from aspirate and bone samples in the joint region. The wound eventually healed and the ESR returned to normal.

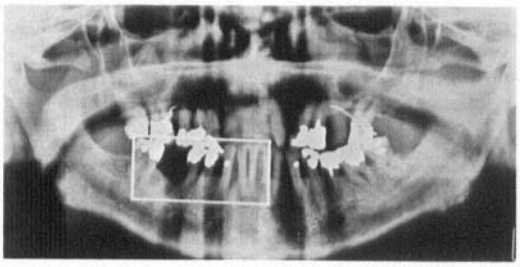

Figure 1. Case 1. Orthopantomogram taken at the time of exchange of joint prosthesis. Severe periodontal disease is evident; much restorative dental work has been done. A mucosal swelling is seen in the right maxillary sinus.

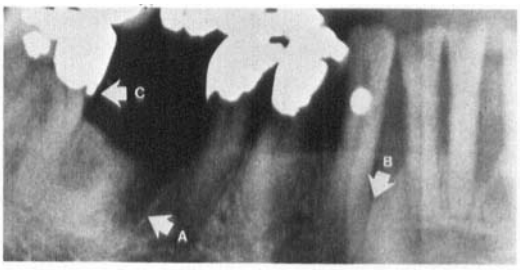

Close-up A. Signs of recent tooth extraction.
B. Deep vertical bone resorption extending to the apical third of the roots indicating severe chronic infections.
C. Overhang of the filling substance which leads to periodontal infection by promoting plaque formation.

Case 2

In October 1982, a 66-year-old woman had total hip replacement for post-traumatic arthrosis. Prophylactic antibiotics including dicloxacillin were given pre- and postoperatively. Four days post-operatively a maxillary incisor tooth with an artificial crown fractured and the coronal two thirds of the tooth were removed. The root was left and the patient was advised to seek dental care after leaving the hospital.

The postoperative course was uneventful, though some months after the operation the patient had pain in the operated hip. Radiographically there were no signs of infection. The ESR was elevated and an antibiotic was instilled. The patient subsequently became free of pain but the ESR remained elevated, severe anemia ensued and the general condition deteriorated. A number of medical tests were done but not until October 1984 was an infection of the replacement radiographically evident and the prosthesis removed. Osteitis was found in the proximal part of the femur, and culture showed *Streptococcus viridans*. An orthopantomogram revealed the root of the incisor tooth and also severe periodontal disease. The teeth were extracted and after a Girdlestone procedure, the ESR decreased and the general condition of the patient improved dramatically.

Case 3

An 84-year-old woman, with bilateral coxarthrosis had total replacements, in October 1978 of the left hip and in January 1979 of the right hip. In May 1979 the left hip became painful, and in June 1979 the implant was exchanged, because of mechanical loosening. During the operations the patient received a prophylactic intramuscular injection of streptomycin. Postoperatively the patient still had slight pain in both hips, but clinically and radiographically there were no signs of infections or loosening. In October 1984 four teeth were extracted for severe periodontitis. No prophylactic antibiotic was given. One month later the patient had fever, and pain appeared in the right hip. ESR rose to 70 mm/h. The hip was aspirated of large amounts of pus, from which *Streptococcus viridans* was cultured. The orthopantomogram revealed recent tooth extractions, four remaining teeth with advanced destructive periodontal lesions, and one tooth with a periapical radiolucency.

Discussion

Earlier studies reporting a dental origin for hematogenous THR infections have comprised patients with acute dental infections only (Carlson et al. 1977, Ahlberg et al. 1978, Blomgren 1981). In our patients micro-aerophilic viridans streptococci were cultivated from the infected implant area in each case. The viridans streptococcus-microbe is abundant in the upper respiratory tract and especially in the oral cavity (Horder 1909). Dental extractions and manipulations preceded the THR infection in our three cases and all patients had severe periodontal disease. A number of investigations have shown that bacteremia follows not only dental manipulations, but can also follow the mere chewing of gum or vigorous tooth brushing (Round et al. 1936, Murray & Moosnick 1941, Cobe 1954, Diener et al. 1964, Rise et al. 1969). This is especially true for periodontitis patients.

In cases of advanced periodontitis the total infectious area around all the teeth easily corresponds to the size of the palm of the hand (Ainamo 1980). The periodontal disease is associated with a complex microflora in which more than 250 bacterial species can be found (Slots et al. 1983). Recent studies show, however, that the proportion of gram-negative anaerobic organisms increases markedly in the subgingival microflora with increasing severity of periodontal disease (Socransky et al. 1977). The occurrence of anaerobes in blood cultures after dental extractions has been reported to be as high as 84 per cent (Head et al. 1984). Serious attention has been paid to this fact since anaerobic bacteria have been identified as the causative factor in many cases of bacterial endocarditis (Geraci et al. 1980, Nord 1982). Late infections of total joint replacements could consequently also be of oral origin, and the entry of bacteria into the circulation is possible not only as the result of dental extractions, but also a number of everyday oral hygiene procedures, especially in individuals with advanced periodontal disease.

To diminish the risk of dental bacteremia in patients undergoing joint replacement operations, our observations suggest that before a total hip replacement, a dental check-up should be made. Postoperatively, all dental treatments potentially causing bacteremia should be made under antibiotic prophylaxis.

References

Ahlberg, Å., Carlsson, Å. S. & Lindberg, L. (1978) Hematogenous infection in total joint replacement. *Clin. Orthop.* **137**, 69–75.

Ainamo, J. (1980) Gingival infections. A review. (In Finnish). *Duodecim* **96**, 542–550.

Blomgren, G. (1981) Hematogenous infection of total joint replacement. An experimental study in the rabbit. *Acta Orthop. Scand.* **52**, Suppl. 187. 1–64.

Carlsson, Å., Lidgren, L. & Lindberg, L. (1977) Prophylactic antibiotics against early and late deep infections after total hip replacements. *Acta Orthop. Scand.* **48**, 405–410.

Cobe, H. M. (1954) Transitory bacteremia. *Oral Surg.* **7**, 609–615.

Diener, J., Schwartz, S. M., Shelanski, M. & Steinberg, G. (1964) Bacteremia and oral sepsis with particular reference to the possible reduction of systemic disease originating from the oral cavity. *J. Periodont.* **35**, 236–241.

Geraci, J. E., Wilson, W. R. & Washington, H. J. A. (1980) Infective endocarditis caused by Actinobacillus actinomycetemcomitans. *Mayo Clin. Proc.* **55**, 415–420.

Horder, T. J. (1909) Infective endocarditis. *Q. J. Med.* **2**, 290–324.

Head, T. W., Bentley, K. C., Millar, E. P. & deVries, J. A. (1984) A comparative study of the effectiveness of metronidazole and penicillin V in eliminating anaerobes from postextraction bacteremias. *Oral Surg.* **58**, 152–155.

Little, J. W. (1983) The need for antibiotic coverage for dental treatments of patients with joint replacements. *Oral Surg.* **55**, 20–23.

Murray, M. & Moosnick, F. (1941) Incidence of bacteremia in patients with dental disease. *J. Lab. Clin. Med.* **26**, 801–802.

Nord, C. E. (1982) Anaerobic bacteria in septicaemia and endocarditis. *Scand. J. Infect. Dis.* **31**, 95–104.

Rise, E., Smith, J. F. & Bell, J. (1969) Reduction of bacteremia after oral manipulations. *Arch. Otolaryngol.* **90**, 198–201.

Round, H., Kirkpatrick, H. J. R. & Hails, C. G. (1936) Further investigations on bacteriological infections of the mouth. *Proc. R. Soc. Med.* **29**, 1552–1556.

Slots, J. Rosling, B. G. & Genco, R. J. (1983) Suppression of penicillin-resistant oral *Actinobacillus actinomycetemcomitans* with tetracycline. *J. Periodont.* **54**, 193–196.

Socransky, S. S., Manganiello, A. D., Propas, D., Oram, V. & van Houte J. (1977) Bacteriological studies of developing supragingival dental plaque. *J. Periodont. Res* **12**, 90–106.